HAL
open science

The relationship between liver disease stage and liver fibrosis: a tangled web

Giacomo Germani, Andrew Kenneth Burroughs, Amar Paul Dhillon

To cite this version:

Giacomo Germani, Andrew Kenneth Burroughs, Amar Paul Dhillon. The relationship between liver disease stage and liver fibrosis: a tangled web. Histopathology, 2010, 57 (6), pp.773. 10.1111/j.1365-2559.2010.03609.x . hal-00574821

HAL Id: hal-00574821

https://hal.science/hal-00574821

Submitted on 9 Mar 2011

HAL is a multi-disciplinary open access archive for the deposit and dissemination of scientific research documents, whether they are published or not. The documents may come from teaching and research institutions in France or abroad, or from public or private research centers.

L'archive ouverte pluridisciplinaire **HAL**, est destinée au dépôt et à la diffusion de documents scientifiques de niveau recherche, publiés ou non, émanant des établissements d'enseignement et de recherche français ou étrangers, des laboratoires publics ou privés.

The relationship between liver disease stage and liver fibrosis: a tangled web

Journal:	*Histopathology*
Manuscript ID:	HISTOP-05-10-0258
Manuscript Type:	Review
Date Submitted by the Author:	04-May-2010
Complete List of Authors:	Germani, Giacomo; Royal Free Hospital, The Royal Free Sheila Sherlock Liver Centre and University Department of Surgery UCL Burroughs, Andrew Kenneth; Royal Free Hospital, The Royal Free Sheila Sherlock Liver Centre and University Department of Surgery UCL Dhillon, Amar; Royal Free and University College Medical School, Department of Cellular Pathology, Royal Free Campus
Keywords:	liver, fibrosis, stage, collagen proportionate area, image analysis

Review

The relationship between liver disease stage and liver fibrosis: a tangled web

Giacomo Germani[1], Andrew K. Burroughs[1], Amar P. Dhillon[2]

[1] The Royal Free Sheila Sherlock Liver Centre and University Department of Surgery UCL, and Royal Free Hospital, London, UK

[2] Department of Cellular Pathology, UCL Medical School, Royal Free Campus, Rowland Hill Street, London, UK

For Peer Review

Corresponding Author

Prof. Amar Paul Dhillon
Department of Cellular Pathology
UCL Medical School
Royal Free Campus
Rowland Hill Street
London NW3 2PF
UK
email :a.dhillon@medsch.ucl.ac.uk

Abstract

The structural consequences of chronic liver disease are described as a series of liver disease "stages" with scarring and architectural change that eventually destroys and replaces the normal lobular structure of the liver. Fibrosis ("excess collagen") and stage have been confused in histological staging systems. Fibrosis is part of increasing liver disease stage, but fibrosis and stage are different. Staging liver disease is important in routine histopathological assessment. Measurement of liver fibrosis is another process. The collagenous proportion of a liver biopsy (collagen proportionate area, CPA) correlates with hepatic venous pressure gradient (HVPG), which is of recognised prognostic value. CPA at 1 year post-transplantation in HCV infected patients predicts subsequent clinical decompensation. CPA in cirrhotic patients predicts decompensation more accurately than staging or HVPG. The "cirrhosis" stage category has poor prognostic power, and CPA effectively substages cirrhosis. CPA improves the description of liver disease stage. Proper validation of antifibrotic treatments and "non-invasive markers of liver fibrosis" requires measurement of liver fibrosis (and not liver biopsy stage scores). It is unacceptable for the words "fibrosis" and "score" to remain next to each other. There are benefits of properly understanding liver fibrosis and liver disease stage and properly assessing each of them.

For Peer Review

What do we mean by "liver fibrosis"?

The first histological scoring system to systematically evaluate the histological activity of chronic hepatitis was described in 1981 by Knodell et al..[1] The scoring system used numerical categorical labels, which were a shorthand for a subjective description of specific histological features observed in liver biopsies. Numerical categorical labels have also been used in

subsequent histological "scoring" systems used to describe systematically chronic "hepatitis activity".

Knodell et al.,[1] evaluated the histological features of chronic hepatitis as potential prognostic markers, based on the understanding current at that time of the pathophysiology of chronic aggressive hepatitis. In 1981 aetiologically the literature was mainly about autoimmune hepatitis and HBV infection. Occasionally drug toxicity was identified. Knodell et al.[1] studied 14 liver biopsy specimens from five patients with asymptomatic chronic active hepatitis. One patient had HBV and the other four were "presumed to be cases of non-A, non-B chronic hepatitis". When Crawford studied "Citation Classics in Hepatopathology" in 2006, the paper by Knodell et al.[1] achieved the highest "number of citations".[2]

Thus, the Knodell ''histological activity index'' system (HAI) was proposed and promulgated. The Knodell system evaluated separately, each of four histopathological axes (periportal ± bridging necrosis, intralobular degeneration/focal necrosis, portal inflammation, and "fibrosis"), and assigned a "numerical" score to each. To enhance the discriminant potential of the system, the difference between mild and serious disease was accentuated by eliminating the "number" (category) 2 from the scoring system for each histopathological axis. By omitting "2", the Knodell system allows a "simple" and practical everyday use of the system, by providing a gap between no/insignificant and appreciable/severe visual change for each axis of assessment i.e. 0/1 vs 3/4, (with some additional options for periportal ± bridging necrosis which was thereby given extra weight, because at that time, it was considered the most important determinant of chronic aggressive hepatitis). The score is therefore discontinuous, which has been considered a drawback by some. This objection is redundant when one considers that in any case the numerical labels are not measurements of a continuous variable. A more pernicious fault was the labelling as "fibrosis" of the axis of assessment which subsequently became known as the disease

For Peer Review

"stage" (which is a blend of features relating to fibrosis and architectural changes resulting in the effacement of the normal lobular structure of the liver). This confusion has persisted to the present day. In recent times use of categorical labels of scoring systems, as numerical measurements of a continuous variable, has been appreciated as being conceptually incorrect. This realisation will help to avoid misunderstandings between histopathologists and clinicians, as well as statistical errors in handling histopathological data. Similarly, the formal acknowledgement of the essential difference between liver fibrosis and liver disease stage, should result in better understanding, and benefits in framing research, and validation of "non invasive markers" of fibrosis. These considerations are relevant to several issues:

Firstly the currently used histological hepatitis scoring systems, which include the Ishak[3], the METAVIR scoring systems[4], and other hepatitis scoring systems, use the same principles to describe the "stage" of the liver disease. In all systems the ''stage'' or ''fibrosis'' score comprise a mixture of features. Notably, no individual feature is related specifically to the amount of fibrous tissue in a liver biopsy sample. For example, in the Ishak system the higher scores depend more on the degree of nodularity and on architectural changes, rather than the amount of fibrous tissue.

Secondly these histological staging systems have been misunderstood by many clinicians. There has been inappropriate use statistically, of the histological stage "scores", which are documented in many publications, including randomized controlled trials. As noted above, histological stage scores describe features that depend on architectural changes and not only on the degree of fibrosis. In addition they are descriptive notations so that, at best, they are ordered categorical data and not numbers. The "number" assigned in the stage score is not a measurement. The "number" is a shorthand label, as explained above, for a morphological description. Thus the scores are categories and not a range of numbers with any known

For Peer Review

arithmetical relationship to each other ie. stage 2 is not half of stage 4. Therefore only statistical methods appropriate for ordered categorical assignments should be used to evaluate stage "scores".[5] This particular attribute of the nature of histological scoring has not been understood by many investigators. Virtually none of the extensive literature on the subject, particularly in clinical trials of antiviral therapeutic agents, has avoided this statistical error. What should be done is to convert categorical data into frequency data, in order to evaluate scores in an appropriate statistical manner.

A third issue is that a scoring system devised for one particular liver disease is not necessarily applicable to a different aetiology. Thus, a scheme designed for the assessment of steatohepatitis, for example by Brunt et al.[6] is not suitable for the assessment of chronic viral hepatitis, for which scoring systems such as the Knodell or Ishak are used, because fibrosis develops and progresses in different ways in these diseases.

The misuse of histopathological scoring systems confounds efforts to understand the natural history of different types of liver disease. Natural history studies, such as rate of accumulation of fibrosis, should be based on specific measurement of fibrosis with long term longitudinal follow up. Clinical outcomes of cohorts of patients with disease of defined aetiology should be studied. Generalisations, extrapolated from ideas derived from a historical and limited understanding of pathophysiology of undefined causes of liver disease, should not be used.

For Peer Review

Histopathological measurement of liver fibrosis

One might argue about the definition of liver fibrosis, but one convenient and widely accepted proposal is:[7]

Fibrosis is *''the presence of excess collagen due to new fiber formation.''*

In order to validate surrogate markers of fibrosis such as serum markers[8] or liver stiffness measurement (transient elastography),[9] and to evaluate changes with treatment that affect fibrosis, a precise assessment of the amount of liver fibrosis is required. This can be performed only with a proper measurement of liver collagen.

The amount of collagen can be measured in tissue homogenates using biochemical methods, but this destroys the tissue, without the possibility of obtaining further information from the biopsy, which is unsatisfactory in the assessment of a diagnostic liver biopsy.

Histological evaluation of fibrosis is usually performed using trichrome or reticulin stains. Each of these stains identify collagen to some extent, but the amount of trichrome or reticulin staining does not necessarily correspond quantitatively with the amount of hepatic collagen.[10] The picroSirius red technique has been shown to be more suitable for quantitative assessment. Sirius red has an affinity for most hepatic collagens, including types I and III [11, 12]; and the binding correlates with biochemical hydroxyproline assay under standardized laboratory conditions.[13] The quantity of bound stain also correlates well with biochemically determined collagen content and morphometrically determined hepatic fibrosis, and the method appears to be reliable and reproducible.[14, 15] Thus Sirius red staining is the preferred histochemical method when quantifying liver fibrosis, even though the staining may not be stoichiometric.[11]

The routine histopathological analysis of liver biopsies is not compromised by computer-assisted digital image analysis of Sirius red stained histological sections; this additional analysis can be performed simply, to measure liver biopsy fibrosis specifically. The evaluation is based on segmentation of digital images to measure the area of collagen, as well as the area of tissue, producing a ‘‘fibrosis ratio’’ or proportion of the area of the biopsy occupied by collagen (collagen proportionate area, CPA) [16, 17]. With this technique structural collagen (e.g. blood vessel wall, large septal portal tracts), which is irrelevant to disease processes and other areas that

For Peer Review

confound analyses (e.g. subcapsular fibrous tissue which often exaggerates the degree of fibrosis compared to deeper parts of a diseased liver) are edited from the measurement.[10]

Image analysis studies have evaluated fibrosis in many liver conditions[14, 16-22]. Published range from 1–7% CPA in normal liver, to 12–36% in cirrhosis. However, the results of these studies are not directly comparable, due to the differences in the technology and methodology used (Table 1).

Some of these studies [19, 22-28] tried to correlate the image analysis measurements (digital image analysis, DIA) of fibrosis with the categorical stage scores, with different results. Manabe et al.[23] found that CPA did not correlate well with the components of the Knodell scoring system. However, the same group later described a more complex scoring system, which correlated with Sirius red staining on the one hand, and Knodell stage scores on the other.[29] The correlation between semiquantitative scoring system and surface density of total collagen was 0.73 ($p<0.00001$). In the study by Pilette et al.[22] there was a good correlation between the semi-quantitative fibrosis score (Knodell and Metavir (modified) scoring systems) and the area of fibrosis ($r=0.84$, $p<0.0001$). Kage et al.,[19] evaluating the correlation between CPA and a modified stage score, based on the Desmet and Scheuer systems, found that there was a significant correlation in both hepatitis C and B patients (HCV: $r=0.75$, $p<0.001$; HBV: $r=0.67$, $p<0.001$ on the Spearman rank test). In the study by O'Brien et al.[21] a correlation was found between image analysis measurements and Ishak stage score. However it was restricted to biopsy specimens with Ishak stage scores in the range 3 to 6 (Spearman correlation coefficient between stage score and fibrosis ratio was 0.66; $p<0.001$), whereas among biopsy specimens with Ishak stage scores in the range 0 to 3 it was only 0.14 (p = ns). Although later studies[24-27] showed good correlations between quantitative morphometric data and Ishak scores of fibrosis, in the study by Maduli et al.[28] the fibrosis ratios observed with morphometry correlated poorly with the Ishak staging

For Peer Review

score. The discrepancies between stage and fibrosis DIA are not surprising once the difference between fibrosis measurement and stage scoring is appreciated (Figure 1). The overlapping of the fibrosis measurements between stage scores should be recognised as a biological reality, that could be informative, representing, as it does, additional information.

Up to now in clinical settings, image analysis has been used infrequently. Four studies have used morphometry to study changes in hepatic fibrosis after alpha interferon therapy.[18, 23, 30, 31] One study has used morphometry to study disease progression in untreated patients with chronic hepatitis C,[19] and one evaluated the fibrosis progression in patients with treatment-refractory chronic hepatitis C enrolled in a placebo-controlled clinical trial of interferon gamma-1b (IFN-g1b).[32] In the study by Goodman et al.[32] morphometry was found to be a more sensitive tool than histological staging to demonstrate fibrosis progression, because changes in collagen content between baseline and week 48 were more evident than changes in Ishak score. In the study by Fontana et al.,[24] the computerized morphometric assessment was evaluated in 386 patients with chronic hepatitis C with an Ishak stage score of at least 3. The relationship between serum markers and quantitative hepatic collagen content was also determined. A significant relationship between hepatic collagen content and the Ishak stage scores was shown ($r=48$, $p<0.0001$). There was a weaker relationship with cirrhosis compared to a panel of markers of fibrosis. These studies[24, 32] evaluated patients with either Ishak stage ≥ 2[32] or Ishak stage ≥ 3.[24] In these studies the image analysis methodology did not express the amount of collagen as a simple proportionate area (the thickness of the histological section (for which a specialized microscope is needed) was used to calculate the quantity of collagen).

When methodology and study population are (more or less) aligned, the data are more coherent. For example, even though Bedossa et al.[16] used large tissue blocks (surgical resection cases from patients with HCV infection, without editing of structural collagen, and METAVIR

For Peer Review

staging), while Calvaruso et al.[17] used transjugular liver biopsies of post- transplant HCV patients, and Ishak staging, both groups used Sirius red staining and expressed their results as CPA. The range of CPA from normal liver (mean 2% vs. 2.7%) to HCV cirrhosis (25.1% vs. 22.6%) is similar, and as far as the intermediate METAVIR and Ishak stages can be compared, the CPAs appropriate to each is also similar.

Recently Gailhouste et al.[33] proposed a new approach to the analysis of liver fibrosis. This process is based on an application of multiphoton microscopy enabling the observation of unstained samples using endogenous sources of nonlinear signals such as Two-Photon Excitation Fluorescence (TPEF) and Second Harmonic Generation (SHG). They applied this method to 119 biopsies from patients with chronic liver disease showing that this approach allows a measurement of fibrosis that correlates with the "Fibrosis"-Metavir (stage) score (rho = 0.75, $p<0.0001$). They were able to distinguish patients with Metavir stage F0,1 vs. F2,3,4 (AUROC = 0.88, $p<0.0001$) and F0,1,2,3 vs. F4 (AUROC = 0.89, $p<0.0001$).

Relationship between liver disease stage, fibrosis and prognosis

Clinical outcome in chronic progressive liver disease has been related most often to hepatic venous pressure gradient (HVPG), which is a good predictor of survival and decompensation in cirrhotic patients.[34-37] The clinical application of HVPG measurement has been demonstrated in patients transplanted for HCV liver disease.[38, 39] Also the prognostic value of HVPG has been evaluated in patients with HBV-related cirrhosis treated with lamivudine.[40]

One of the first papers which explored the relationship between liver histopathology and HVPG was that of van Leeuwen et al.,[41] who investigated HVPG and evaluated its relationship to histological features of the stage of chronic liver disease. They evaluated 49 patients, divided into four main groups (near normal liver, chronic active hepatitis, chronic hepatitis in transition to

For Peer Review

cirrhosis and cirrhosis). A HVPG of more than 5 mmHg was always associated with significant liver disease on liver biopsy. Blasco et al.[39] explored the diagnostic value of HVPG to identify patients at risk of severe HCV recurrence after liver transplantation. A positive association was seen between the median HVPG and the liver disease stage. Although the presence of significant "fibrosis" (METAVIR F2-F3) 1 year after transplantation predicted clinical decompensation (AUC: 0.80), an HVPG ≥6 mmHg more accurately (AUC: 0.96) identified patients at risk of clinical disease progression. These findings were confirmed by Samonakis et al.[38] in 90 consecutive liver transplanted patients for HCV-related cirrhosis who found that HVPG correlated with Ishak stage (r =0.73, p<0.001).

In another paper[42] the role of three serum markers (hyaluronic acid, amino-terminal propeptide of type-III procollagen, tissue inhibitor of matrix metalloproteinase type-1) at 3, 6 and 12 months after liver transplantation was examined in 133 liver transplanted patients with HCV recurrence, to evaluate patients at risk of developing significant "fibrosis" and portal hypertension. The AUROC curve of the three serum markers for METAVIR stage F≥2 at 3, 6, and 12 months after transplantation was 0.67, 0.77, and 0.78 respectively. In the group with HVPG ≥ 6mmHg at the same time points, AUROC curves were 0.75, 0.87, and 0.90 respectively, which were significantly better than values obtained with the three previously published scores of "non-invasive makers of liver fibrosis" (AST/ALT ratio[43] (0.55, 0.57, 0.80), AST/platelet ratio[43] (0.44, 0.45, 0.45), Benlloch score[44] (0.54, 0.58, 0.71)) in this population.

Vizzuti et al.[45] compared liver stiffness measurement (LSM) and HVPG in predicting severe portal hypertension in 61 consecutive patients with HCV-related chronic liver disease. A strong relationship between liver stiffness measurement and HVPG measurements was found in the overall population ($r = 0.81$, $P < 0.0001$). However, although the correlation was excellent for HVPG values less than 10 or 12mmHg ($r = 0.81$, $P = 0.0003$ and $r = 0.91$, $P < 0.0001$,

For Peer Review

respectively), it was weaker for higher values of HVPG. The AUROC for the prediction of HVPG >10 and >12 mm Hg were 0.99 and 0.92, respectively and at LSM cutoff values of 13.6 kPa and 17.6 kPa, the sensitivity was 97% and 94%, respectively. Carrion et al.[46] evaluated the diagnostic accuracy of LSM to assess the severity of hepatitis C recurrence after liver transplantation in the same cohort studied by Blasco et al..[39] They found a close direct correlation between liver stiffness and HVPG (Pearson coefficient 0.84; p<0.001) and the AUC for diagnosis of portal hypertension (HVPG≥6 mmHg) was 0.93. In order to discriminate between rapid and slow "fibrosers", the same author[47] evaluated liver stiffness after liver transplantation in 84 liver transplanted patients with HCV-recurrence. The accuracy of liver stiffness at identifying patients with portal hypertension (HVPG≥6 mmHg) at 1 year after liver transplantation improved over time. The AUROC curves at 3,6,9 and 12 months after liver transplantation identifying patients with portal hypertension, were 0.72, 0.77, 0.80 an 0.92 in the test group (n=50) and 0.58, 0.79, 0.84 and 0.93 in the validation group (n=34) respectively. These latter studies did not evaluate histology.

The relationship between collagen proportionate area (CPA) and HVPG has been studied by Calvaruso et al.[17] in a cohort of 115 liver transplanted patients with HCV recurrence. CPA had a stronger relationship with HVPG than did Ishak stage and CPA was independently associated, by logistic regression, with HVPG≥6mmHg (odds ratio, 1.206; 95%CI [1.094-1.331]; p<0.001), and HVPG ≥10mmHg - clinically significant portal hypertension (odds ratio, 1.105; 95%CI [1.026-1.191]; p<0.009). CPA measured in 1 year post-transplant biopsies in 96 patients after liver transplantation for HCV was found to predict later clinical decompensation[48]. CPA measurement was highly predictive with good sensitivity (90%) and specificity (97.8%), and was better at this prediction than either Ishak stage or HVPG. CPA and HVPG together at 1 year post transplantation correctly identified all but one patient who decompensated at later time points.

For Peer Review

The relationships between CPA, LSM, HVPG and Ishak stage have been assessed in 45 HCV transplanted patients.[49] Univariately CPA, Ishak stage, and LSM were associated with portal hypertension (HVPG ≥6mmHg), whereas multivariately CPA was the only independent factor (OR 1.377,95% CI: 1.137-1.169; p=0.001). CPA had a better association than Ishak stage or LSM, with HVPG ≥6mmHg and HVPG ≥10 mmHg. LSM had a better correlation with CPA than with HVPG. As CPA is a continuous variable measuring only collagen, it represents a better histological index for the validation of LSM and other non-invasive markers of fibrosis, than stage scores.

For Peer Review

Histological substaging of cirrhosis by measuring fibrosis

Cirrhosis is defined histologically as "a diffuse process characterized by fibrosis and the conversion of normal liver architecture into structurally abnormal nodules".[7] The word "cirrhosis" has been considered sufficient to describe both a pathological and clinical condition, and to have some prognostic importance, with an implication historically that cirrhosis represents "end stage disease". Nowadays however, the "one-stage description" of cirrhosis has become inadequate, especially considering that better prediction of outcome is needed to provide individualized therapy.[50] In compensated cirrhosis patients with an HVPG <10mmHg have a 10% probability of developing clinical decompensation during 4 years of follow-up, compared to 40% of patients with an HVPG ≥10mmHg .[51] In patients transplanted for HCV related cirrhosis the cumulative probability of developing clinical decompensation is 22% during the year following a diagnosis of recurrence of compensated cirrhosis with a probability of developing decompensation of 40% at 5 years.[52] Specific histological features of cirrhosis have infrequently been linked to clinical outcomes. Any additional histological characterisation, which permits a

better prognostic evaluation of cirrhosis (i.e. subclassification or substaging of cirrhosis) would be helpful clinically.

There is evidence that both HVPG and liver disease grade and stage correspond with haemodynamic (portal hypertension) and clinical features of chronic liver disease. If additional and better correlation can be established between portal pressure and specific histologic features, such as fibrosis (which contributes to the increased intrahepatic vascular resistance in chronic liver disease), the possibility exists of an improved characterisation of cirrhosis, and of quantifying cirrhosis "severity". In this way, we could re-introduce into the histopathological evaluation of cirrhosis the previously recognised important facet of portal hypertension, but which fell into abeyance with the dominance of the current morphological definition of cirrhosis.[7]

In patients with liver cirrhosis simple histological features that are undervalued at present may have important prognostic implications. Kutami et al.[53] reported, in abstract form, a series of 302 transjugular liver biopsies, finding that "fibrosis" scores derived from nodule size, and thickness of fibrous septa correlated with HVPG, ascites, INR, bilirubin and inversely with albumin. With a similar approach, Nagula et al.[54] evaluated 43 patients with biopsy-proven cirrhosis and HVPG measurements within 6 months of the biopsy, showing that septal thickness (p=0.03), small nodularity (p=0.003), loss of portal tracts (p=0.01), inflammation (p=0.04) and alcoholic aetiology (p=0.01) were correlated with the presence of clinically significant portal hypertension ≥10 mmHg. However, small nodules and thick septa were the only parameters independently predictive of clinically significant portal hypertension. Kumar et al.[55] evaluated 47 patients with biopsy-proven cirrhosis and HVPG measurements. Nodule size, loss of portal tracts and central veins, portal inflammation, periportal inflammation, bile duct proliferation, lobular inflammation, ballooning, fatty change, cholestasis and septal thickness were scored. On multiple ordinal regression analysis, small nodule size (p=0.009) and thick septa (p=0.011) were

For Peer Review

significantly associated with the presence of clinically significant portal hypertension. In these studies, neither the exact dimension of the nodules nor the septal thickness is stated. Even within a limited sample of liver, nodules of different sizes, and septa of different thicknesses are apparent, and although an "average" nodular size/septal thickness can be assigned subjectively, this remains an imprecise evaluation. Nodule size was defined in these studies according to the width of needle biopsy specimens (not specified in the studies), with a small nodule being comparable to the width of the biopsy (a large nodule being considered larger than biopsy width). In their discussion Nagula et al. [54] state that small nodules are <1.0mm and large nodules are >2mm; and thin septa are <0.2mm while thick septa are >0.4mm.

Viola et al.[56] (from the same group as Nagula et al. [54]) defined retrospectively the cut-off between thin and thick septa at 169.01 µm, evaluating 115 patients with cirrhotic biopsies. The median septal width of all fibrous septa per slide was greater in patients who developed decompensation compared to those who remained compensated (212.56 µm vs. 156.59 µm, $p<0.001$). Patients with thick septa (≥169.01 µm) had a significantly higher probability of decompensating. They found that fibrosis area, defined as the percentage of the total biopsy area, was not related to clinical decompensation, but the data are in abstract form, so is not clear how fibrosis area was assessed.

In any event, regardless of the complexities of variations in septal thickness/nodule size within any given biopsy determined either morphometrically or subjectively, a moments reflection reveals that CPA records the reciprocal balance between nodule size and septal fibrosis: a high CPA will integrate and accurately reflect the overall fibrosis in biopsies with small-ish nodules/thick-ish septa, and conversely a low CPA will characterise biopsies with large-ish nodules/thin-ish septa. In the study by Calvaruso et al.[57] in patients with Ishak stage 5 and 6 disease, clinically significant portal hypertension (OR 1.081; CI: 1.001 –1.166; $p = 0.046$)

For Peer Review

and HVPG (r= 0.65; p<0.001) each had a statistically significant relationship with CPA. The data suggest strongly that CPA is a useful histological variable that substages cirrhosis with a continuous scale and with good applicability and also predicts clinical outcomes.[58]

Fibrosis measurement has implications for the currently fashionable idea that cirrhosis might be reversible.[59, 60] Fibrosis should correspond more to the "fixed" component of portal hypertension than to any haemodynamic component of cirrhosis that might respond to vasodilator treatment. When the aetiological agent can be eliminated and when effective antifibrotic agents are available, if fibrosis is measured properly, regression of fibrosis might be documented, with or without reduction of portal hypertension. To date this has not been done. Regression of the cirrhotic "stage" will require another separate evaluation with particular regard to sampling error, decrease of portal venous pressure, and improvement of clinical aspects of cirrhosis and prognosis. Studies of "cirrhosis regression" have not yet addressed these issues, and all too often have confused apparent regression of fibrosis with regression of cirrhosis stage.

For Peer Review

Conclusion

Since liver disease "stage" was called "fibrosis" by Knodell et al.[1] there has been conflation of the two terms. In the context of chronic liver disease the terms "fibrosis" and "score" should not be contiguous. Liver disease stage definitions include fibrosis, but liver disease stage depends to a great extent on architectural changes as well. Histopathological assignment of liver disease stage is a different process from the measurement of liver fibrosis. The two processes are complementary and each adds value to the liver biopsy assessment. As they are different assessments, the correlation between stage and fibrosis measurement is imperfect. The range of fibrosis (collagen proportionate area, CPA) seen within each liver disease stage represents biological reality, rather than constituting a confusing overlap between stages. The amount of

liver fibrosis reflects intrahepatic vascular resistance and portal hypertension as CPA correlates with hepatic venous pressure gradient. Thus CPA could help to refine the prognostic value of each liver disease stage in individual patients. CPA measured at 1 year post transplantation in patients with HCV infection predicts clinical decompensation in later years. CPA stratifies clinically important prognostic groups within the stage category of cirrhosis, and can be used to define clinically relevant cirrhosis "substages". Proper measurement of liver fibrosis is relevant for the evaluation of antifibrotic treatments and "non-invasive markers of liver fibrosis" which hitherto have been "validated" incorrectly with liver biopsy stage scores. It is necessary to understand that liver fibrosis is an important aspect of the development of cirrhosis but they are not exactly the same thing.

For Peer Review

Figure 1 (reproduced from Standish RA et al.[10]).

Histopathological chronic liver disease stage "scores" are descriptive categorical assignments which are different from liver fibrosis measurements.

Appearance	Ishak stage: Categorical description	Ishak stage: Categorical assignment	Fibrosis measurement*
	No fibrosis (normal)	0	1.9%
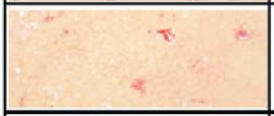	Fibrous expansion of some portal areas ± short fibrous septa	1	3.0%
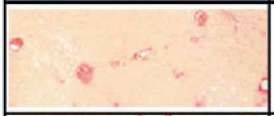	Fibrous expansion of most portal areas ± short fibrous septa	2	3.6%
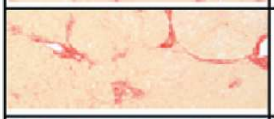	Fibrous expansion of most portal areas with occasional portal to portal (P-P) bridging	3	6.5%
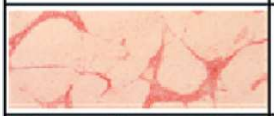	Fibrous expansion of portal areas with marked bridging (portal to portal (P-P) as well as portal to central (P-C))	4	13.7%
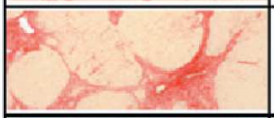	Marked bridging (P-P and/or P-C), with occasional nodules (incomplete cirrhosis)	5	24.3%
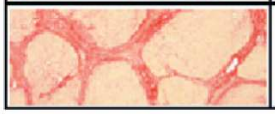	Cirrhosis, probable or definite	6	27.8%

***Proportion (%) of area of illustrated section showing Sirius red staining for collagen (collagen proportionate area).**

Table 1. Studies of CPA liver fibrosis (image analysis) vs. stage of liver disease.

Author	Year	Stain	Magnification; and fields measured	Section thickness	Number of samples	Liver disease: aetiology and stage	CPA % (mean±SD)
Jimenez[14]	1993	Masson's trichrome	64x; 5 random areas per biopsy	4µm	38	(Alcoholic) steatosis Chronic hepatitis [40] (Alcoholic) fibrosis Cirrhosis (various aetiologies, mainly alcohol)	4.07±1.07[a] 9.06±1.04[b] 17.2±3[c] 24.7±2.7[d]
Nohlgard[20]	1993	picroSirius red	6.5x; "Four or more different fields corresponding to an average of 25 mm^2"	4µm	46	Normal I (Roenigk stage) IIIA IIIB IV	0.9±0.1 11.4±2.1 9.3±1.4 24.0±4.9 11.8±2.7
Kage[19]	1997	Azan	40x; whole area (biopsies with ≥5 portal tracts)	4µm	74 93	("Desmet & Scheuer stage") 1 HBV 2 3 4 1 HCV 2 3 4	Estimated from Fig1[19] 3±0.8 3±0.9 6.5±2 7.3±2.2 2.1±1.4 2.5±1 5.1±1.9 8.1±4.2
Duchatelle[18]	1998	picroSirius red	25x; whole area (biopsies "at least 1cm long")	4µm	64	HCV (Knodell stage) 0-1 3-4	 1.86±1.56 4.07±3.19
Pilette[22]	1998	picroSirus red	100x; whole area (biopsies with 12±5 portal tracts)	3µm	232	ALD, HBV, HCV (Modified Metavir stage) 0 1 2 3 4 5	Estimated from Fig1[22] 7±4 8±4 11±4 19±12 20±8 36±9
O'Brien[21]	2000	Masson's trichrome	40x; whole area (biopsies 10mm long and ≤3 portal tracts)	5µm	230	HCV (Ishak stage) 0 1 2 3 4 5 6	 3±0.3 5.6±0.6 7.0±0.6 6.0±0.5 11.9±0.7 15.3±1 28.6±1.7
Bedossa[16]	2003	picroSirius red	100x;	5µm	17	HCV (Metavir stage)	

For Peer Review

			"virtual" biopsies of various sizes created from 2x3cm tissue blocks from surgical resections			0 1 2 3 4	2±0.14 3.4±0.25 5.8±0.7 14.7±0.77 25.1±1.44
Calvaruso[17]	2009	picroSirius red	1x; whole area (biopsies >12mm long)	4µm	225	HCV (Ishak stage) 0 1 2 3 4 5 6	 2.7±2 3.7±3 5.8±3.5 6.6±4.1 9.4±4.8 14±8.1 22.6±11.3

[a]≡66.5±4.6 ; [b]≡76.4±6.5; [c]≡125.2±13.9; [d]≡152.6±11 µg collagen/mg protein[14]

For Peer Review

References

1. Knodell RG, Ishak KG, Black WC *et al.* Formulation and application of a numerical scoring system for assessing histological activity in asymptomatic chronic active hepatitis. *Hepatology*. 1981; **1**; 431-435.

2. Crawford JM. Evidence-based interpretation of liver biopsies. *Lab Invest*. 2006; **86**; 326-334.

3. Ishak K, Baptista A, Bianchi L *et al.* Histological grading and staging of chronic hepatitis. *J Hepatol*. 1995; **22**; 696-699.

4. Intraobserver and interobserver variations in liver biopsy interpretation in patients with chronic hepatitis C. The French METAVIR Cooperative Study Group. *Hepatology*. 1994; **20**; 15-20.

5. Lagging LM, Westin J, Svensson E *et al.* Progression of fibrosis in untreated patients with hepatitis C virus infection. *Liver*. 2002; **22**; 136-144.

6. Brunt EM, Janney CG, Di Bisceglie AM, Neuschwander-Tetri BA, Bacon BR. Nonalcoholic steatohepatitis: a proposal for grading and staging the histological lesions. *Am J Gastroenterol*. 1999; **94**; 2467-2474.

7. Anthony PP, Ishak KG, Nayak NC, Poulsen HE, Scheuer PJ, Sobin LH. The morphology of cirrhosis. Recommendations on definition, nomenclature, and classification by a working group sponsored by the World Health Organization. *J Clin Pathol*. 1978; **31**; 395-414.

8. Burroughs AK, Cholongitas E. Non-invasive tests for liver fibrosis: encouraging or discouraging results? *J Hepatol*. 2007; **46**; 751-755.

9. Castera L, Forns X, Alberti A. Non-invasive evaluation of liver fibrosis using transient elastography. *J Hepatol*. 2008; **48**; 835-847.

10. Standish RA, Cholongitas E, Dhillon A, Burroughs AK, Dhillon AP. An appraisal of the histopathological assessment of liver fibrosis. *Gut*. 2006; **55**; 569-578.

11. Puchtler H, Meloan SN, Waldrop FS. Are picro-dye reactions for collagens quantitative? Chemical and histochemical considerations. *Histochemistry*. 1988; **88**; 243-256.

12. Rojkind M, Ponce-Noyola P. The extracellular matrix of the liver. *Coll Relat Res*. 1982; **2**; 151-175.

13. James J, Bosch KS, Aronson DC, Houtkooper JM. Sirius red histophotometry and spectrophotometry of sections in the assessment of the collagen content of liver tissue and its application in growing rat liver. *Liver*. 1990; **10**; 1-5.

14. Jimenez W, Pares A, Caballeria J *et al.* Measurement of fibrosis in needle liver biopsies: evaluation of a colorimetric method. *Hepatology*. 1985; **5**; 815-818.

For Peer Review

15. Lopez-De Leon A, Rojkind M. A simple micromethod for collagen and total protein determination in formalin-fixed paraffin-embedded sections. *J Histochem Cytochem*. 1985; **33**; 737-743.

16. Bedossa P, Dargere D, Paradis V. Sampling variability of liver fibrosis in chronic hepatitis C. *Hepatology*. 2003; **38**; 1449-1457.

17. Calvaruso V, Burroughs AK, Standish R *et al.* Computer-assisted image analysis of liver collagen: relationship to Ishak scoring and hepatic venous pressure gradient. *Hepatology*. 2009; **49**; 1236-1244.

18. Duchatelle V, Marcellin P, Giostra E *et al.* Changes in liver fibrosis at the end of alpha interferon therapy and 6 to 18 months later in patients with chronic hepatitis C: quantitative assessment by a morphometric method. *J Hepatol*. 1998; **29**; 20-28.

19. Kage M, Shimamatu K, Nakashima E, Kojiro M, Inoue O, Yano M. Long-term evolution of fibrosis from chronic hepatitis to cirrhosis in patients with hepatitis C: morphometric analysis of repeated biopsies. *Hepatology*. 1997; **25**; 1028-1031.

20. Nohlgard C, Rubio CA, Kock Y, Hammar H. Liver fibrosis quantified by image analysis in methotrexate-treated patients with psoriasis. *J Am Acad Dermatol*. 1993; **28**; 40-45.

21. O'Brien MJ, Keating NM, Elderiny S *et al.* An assessment of digital image analysis to measure fibrosis in liver biopsy specimens of patients with chronic hepatitis C. *Am J Clin Pathol*. 2000; **114**; 712-718.

22. Pilette C, Rousselet MC, Bedossa P *et al.* Histopathological evaluation of liver fibrosis: quantitative image analysis vs semi-quantitative scores. Comparison with serum markers. *J Hepatol*. 1998; **28**; 439-446.

23. Manabe N, Chevallier M, Chossegros P *et al.* Interferon-alpha 2b therapy reduces liver fibrosis in chronic non-A, non-B hepatitis: a quantitative histological evaluation. *Hepatology*. 1993; **18**; 1344-1349.

24. Fontana RJ, Goodman ZD, Dienstag JL *et al.* Relationship of serum fibrosis markers with liver fibrosis stage and collagen content in patients with advanced chronic hepatitis C. *Hepatology*. 2008; **47**; 789-798.

25. Hui AY, Liew CT, Go MY *et al.* Quantitative assessment of fibrosis in liver biopsies from patients with chronic hepatitis B. *Liver Int*. 2004; **24**; 611-618.

26. Lazzarini AL, Levine RA, Ploutz-Snyder RJ, Sanderson SO. Advances in digital quantification technique enhance discrimination between mild and advanced liver fibrosis in chronic hepatitis C. *Liver Int*. 2005; **25**; 1142-1149.

27. Levine RA, Sanderson SO, Ploutz-Snyder R *et al.* Assessment of fibrosis progression in untreated Irish women with chronic hepatitis C contracted from immunoglobulin anti-D. *Clin Gastroenterol Hepatol*. 2006; **4**; 1271-1277.

For Peer Review

28. Maduli E, Andorno S, Rigamonti C *et al.* Evaluation of liver fibrosis in chronic hepatitis C with a computer-assisted morphometric method. *Ann Ital Med Int*. 2002; **17**; 242-247.

29. Chevallier M, Guerret S, Chossegros P, Gerard F, Grimaud JA. A histological semiquantitative scoring system for evaluation of hepatic fibrosis in needle liver biopsy specimens: comparison with morphometric studies. *Hepatology*. 1994; **20**; 349-355.

30. Caballero T, Perez-Milena A, Masseroli M *et al.* Liver fibrosis assessment with semiquantitative indexes and image analysis quantification in sustained-responder and non-responder interferon-treated patients with chronic hepatitis C. *J Hepatol*. 2001; **34**; 740-747.

31. Sakaida I, Nagatomi A, Hironaka K, Uchida K, Okita K. Quantitative analysis of liver fibrosis and stellate cell changes in patients with chronic hepatitis C after interferon therapy. *Am J Gastroenterol*. 1999; **94**; 489-496.

32. Goodman ZD, Becker RL, Jr., Pockros PJ, Afdhal NH. Progression of fibrosis in advanced chronic hepatitis C: evaluation by morphometric image analysis. *Hepatology*. 2007; **45**; 886-894.

33. Gailhouste L, Le Grand Y, Odin C *et al.* Fibrillar collagen scoring by second harmonic microscopy: a new tool in the assessment of liver fibrosis. *J Hepatol*. 2010; **52**; 398-406.

34. Triantos CK, Nikolopoulou V, Burroughs AK. Review article: the therapeutic and prognostic benefit of portal pressure reduction in cirrhosis. *Aliment Pharmacol Ther*. 2008; **28**; 943-952.

35. Burroughs AK, Groszmann R, Bosch J *et al.* Assessment of therapeutic benefit of antiviral therapy in chronic hepatitis C: is hepatic venous pressure gradient a better end point? *Gut*. 2002; **50**; 425-427.

36. Armonis A, Patch D, Burroughs A. Hepatic venous pressure measurement: an old test as a new prognostic marker in cirrhosis? *Hepatology*. 1997; **25**; 245-248.

37. Burroughs AK, Thalheimer U. HVPG in 2010: optimal measurement is key. *Hepatology*. 2010; in press.

38. Samonakis DN, Cholongitas E, Thalheimer U *et al.* Hepatic venous pressure gradient to assess fibrosis and its progression after liver transplantation for HCV cirrhosis. *Liver Transpl*. 2007; **13**; 1305-1311.

39. Blasco A, Forns X, Carrion JA *et al.* Hepatic venous pressure gradient identifies patients at risk of severe hepatitis C recurrence after liver transplantation. *Hepatology*. 2006; **43**; 492-499.

40. Manolakopoulos S, Triantos C, Theodoropoulos J *et al.* Antiviral therapy reduces portal pressure in patients with cirrhosis due to HBeAg-negative chronic hepatitis B and significant portal hypertension. *J Hepatol*. 2009; **51**; 468-474.

For Peer Review

41. van Leeuwen DJ, Sherlock S, Scheuer PJ, Dick R. Wedged hepatic venous pressure recording and venography for the assessment of pre-cirrhotic and cirrhotic liver disease. *Scand J Gastroenterol*. 1989; **24**; 65-73.

42. Carrion JA, Fernandez-Varo G, Bruguera M *et al.* Serum fibrosis markers identify patients with mild and progressive hepatitis C recurrence after liver transplantation. *Gastroenterology*. 2010; **138**; 147-158.

43. Toniutto P, Fabris C, Bitetto D *et al.* Role of AST to platelet ratio index in the detection of liver fibrosis in patients with recurrent hepatitis C after liver transplantation. *J Gastroenterol Hepatol*. 2007; **22**; 1904-1908.

44. Benlloch S, Berenguer M, Prieto M, Rayon JM, Aguilera V, Berenguer J. Prediction of fibrosis in HCV-infected liver transplant recipients with a simple noninvasive index. *Liver Transpl*. 2005; **11**; 456-462.

45. Vizzutti F, Arena U, Romanelli RG *et al.* Liver stiffness measurement predicts severe portal hypertension in patients with HCV-related cirrhosis. *Hepatology*. 2007; **45**; 1290-1297.

46. Carrion JA, Navasa M, Bosch J, Bruguera M, Gilabert R, Forns X. Transient elastography for diagnosis of advanced fibrosis and portal hypertension in patients with hepatitis C recurrence after liver transplantation. *Liver Transpl*. 2006; **12**; 1791-1798.

47. Carrion JA, Torres F, Crespo G *et al.* Liver stiffness identifies two different patterns of fibrosis progression in patients with hepatitis C virus recurrence after liver transplantation. *Hepatology*. 2010; **51**; 23-34.

48. Manousou P, Burroughs A, Isgro' G *et al.* Computer asisted imagenalysis of liver collagen at one year biopsy can predict clinical outcome in HCV post LT patients *Hepatology*. 2009; **50**; 302A-303A.

49. Isgro' G, Calvaruso V, Manousou P *et al.* Correlation of Ishak stage, transient elastography, HVPG and collagen proportionate area in HCV transplanted patients. *Hepatology*. 2009; **50**; 481A-482A.

50. Garcia-Tsao G, Friedman S, Iredale J, Pinzani M. Now there are many (stages) where before there was one: In search of a pathophysiological classification of cirrhosis. *Hepatology*. 2010; **51**; 1445-1449.

51. Ripoll C, Groszmann R, Garcia-Tsao G *et al.* Hepatic venous pressure gradient predicts clinical decompensation in patients with compensated cirrhosis. *Gastroenterology*. 2007; **133**; 481-488.

52. Kalambokis G, Manousou P, Samonakis D *et al.* Clinical outcome of HCV-related graft cirrhosis and prognostic value of hepatic venous pressure gradient. *Transpl Int*. 2009; **22**; 172-181.

For Peer Review

53. Kutami R, Girgrah N, Wanless I *et al.* The Laennec grading system for assessment of hepatic fibrosis: validation by correlation with wedged hepatic vein presure and clinical features. *Hepatology*. 2000; **32**; 407A.

54. Nagula S, Jain D, Groszmann RJ, Garcia-Tsao G. Histological-hemodynamic correlation in cirrhosis-a histological classification of the severity of cirrhosis. *J Hepatol*. 2006; **44**; 111-117.

55. Kumar M, Sakhuja P, Kumar A *et al.* Histological subclassification of cirrhosis based on histological-haemodynamic correlation. *Aliment Pharmacol Ther*. 2008; **27**; 771-779.

56. Viola A, Jain D, Garcia-Tsao G. Quantitative histological assessment in cirrhosis: septal thickness predicts clinical decompensation. *J Hepatol*. 2009; **50**; S94.

57. Calvaruso V, Grillo F, Manousou P *et al.* Liver collagen proportionate area and hepatic venous pressure gradient to sub-classify cirrhosis: proof of concept in HCV infected liver transplant recipients with allograft cirrhosis. *Hepatology*. 2008; **48**; 1043A.

58. Germani G, Dhillon A, Andreana L *et al.* Histological subclassification of cirrhosis. *Hepatology*. 2010; in press.

59. Desmet VJ, Roskams T. Cirrhosis reversal: a duel between dogma and myth. *J Hepatol*. 2004; **40**; 860-867.

60. Perez-Tamayo R. Cirrhosis of the liver: a reversible disease? *Pathol Annu*. 1979; **14**; 183-213.

For Peer Review