



HAL
open science

Images in vascular medicine

Stefan Ockert, Dittmar Böckler, Marika Ganten, Hardy Schumacher, Jens-Rainer
Allenberg

► **To cite this version:**

Stefan Ockert, Dittmar Böckler, Marika Ganten, Hardy Schumacher, Jens-Rainer Allenberg. Images in vascular medicine. *Vascular Medicine*, 2006, 11 (2), pp.131-132. <10.1191/1358863x06vm649xx>. <hal-00572135>

HAL Id: hal-00572135

<https://hal.science/hal-00572135v1>

Submitted on 1 Mar 2011

HAL is a multi-disciplinary open access archive for the deposit and dissemination of scientific research documents, whether they are published or not. The documents may come from teaching and research institutions in France or abroad, or from public or private research centers.

L'archive ouverte pluridisciplinaire **HAL**, est destinée au dépôt et à la diffusion de documents scientifiques de niveau recherche, publiés ou non, émanant des établissements d'enseignement et de recherche français ou étrangers, des laboratoires publics ou privés.

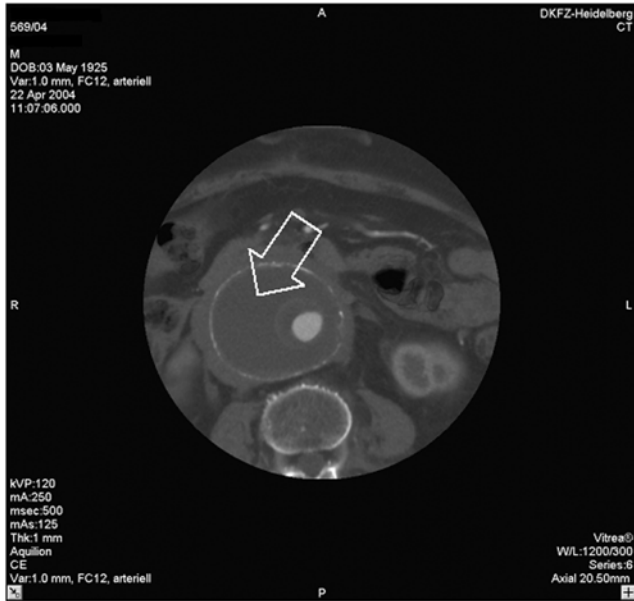


HAL Authorization

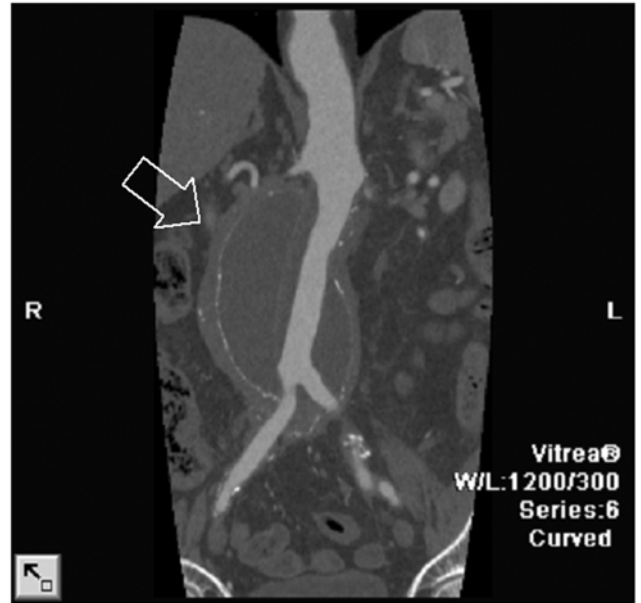
Images in vascular medicine

Persistent sac enlargement after conventional replacement of an inflammatory aortic aneurysm

Stefan Ockert^a, Dittmar Böckler^a, Marika Ganten^b, Hardy Schumacher^a and Jens-Rainer Allenberg^a



Panel A



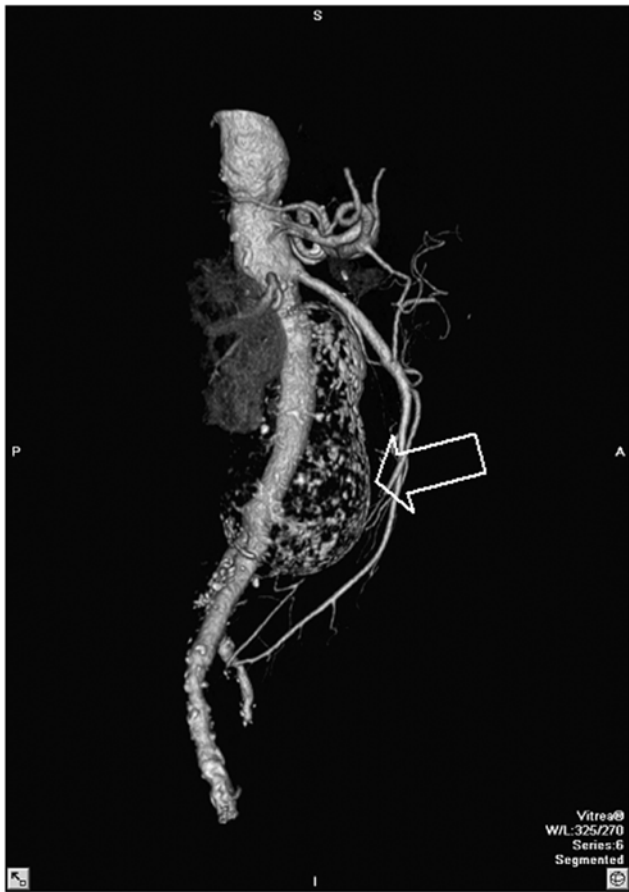
Panel B

A 78-year-old patient was treated for a symptomatic inflammatory aortic aneurysm of 8 cm in diameter in November 2002. He underwent an uncomplicated open aortic repair with implantation of an 18 × 9 mm bifurcated Dacron prosthesis. Fifteen months after the operation ultrasound examination detected a persistent aneurysm without shrinking. For further investigation a 16-row multidetector computed tomography was performed. The analysis of the CTA showed an expanded aneurysm sac around the perfused prosthesis (Panel A,

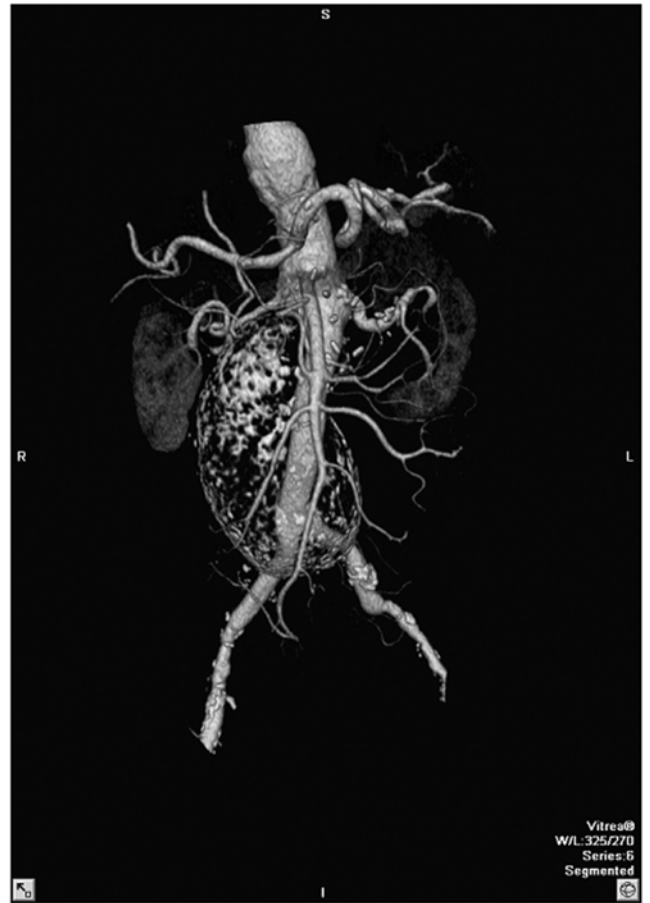transverse CTA: arrow shows the sac; Panel B, coronal CTA: arrow shows persistent inflammation). Contrast medium extravasation into the sac as an indication of active bleeding could not be detected. The aortic wall demonstrated a thickening of 3–5 mm as a sign of persistent inflammation. A 3D CTA volume rendering reconstruction shows the expanded aneurysm sac with intense calcification of the aortic wall (Panel C, lateral view: arrow shows calcification of the aneurysm sac; Panel D, anterior-posterior view).

^aDepartment of Vascular and Endovascular Surgery, University of Heidelberg, Heidelberg, Germany; ^bDepartment of Radiology, German Cancer Research Center (DKFZ), Heidelberg, Germany

Address for correspondence: Stefan Ockert, Department of Vascular and Endovascular Surgery, University of Heidelberg, Im Neuenheimer Feld 110, 69120 Heidelberg, Germany. Tel: +49 6221 56 6249; Fax: +49 6221 56 5423; E-mail: stefan_ockert@med.uni-heidelberg.de



Panel C



Panel D

'Images in vascular medicine' is a regular feature of *Vascular Medicine*. Readers may submit original, unpublished images related to clinical vascular medicine to: Mark A Creager, Editor in Chief, *Vascular Medicine*, Brigham and Women's Hospital, 75 Francis Street, Boston, MA 02115, USA.