



HAL
open science

Images in vascular medicine

Nenad S Ilijevski, Sandra Radak, Bozidar Novakovic, Ana Miholjcic, Djordje Radak

► **To cite this version:**

Nenad S Ilijevski, Sandra Radak, Bozidar Novakovic, Ana Miholjcic, Djordje Radak. Images in vascular medicine. *Vascular Medicine*, 2006, 11 (1), pp.51-51. 10.1191/1358863x06vm638xx . hal-00572132

HAL Id: hal-00572132

<https://hal.science/hal-00572132>

Submitted on 1 Mar 2011

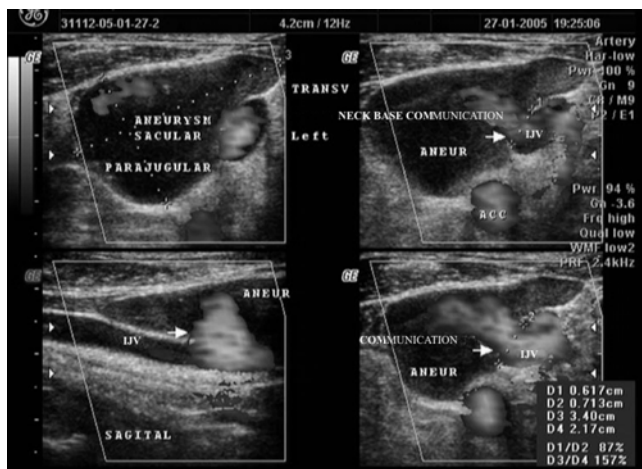
HAL is a multi-disciplinary open access archive for the deposit and dissemination of scientific research documents, whether they are published or not. The documents may come from teaching and research institutions in France or abroad, or from public or private research centers.

L'archive ouverte pluridisciplinaire **HAL**, est destinée au dépôt et à la diffusion de documents scientifiques de niveau recherche, publiés ou non, émanant des établissements d'enseignement et de recherche français ou étrangers, des laboratoires publics ou privés.

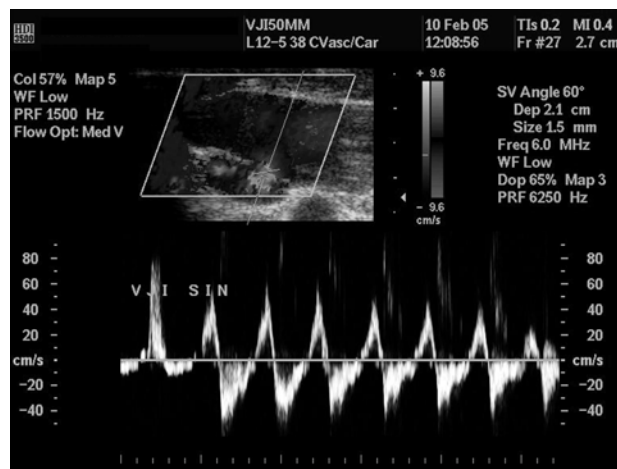
Images in vascular medicine

Jugular vein aneurysm – ultrasonographic evaluation

Nenad S Ilijevski^a, Sandra Radak^a, Bozidar Novakovic^b, Ana Miholjic^b and Djordje Radak^a



Panel A



Panel B

A 55-year-old man presented with an enlarging painless mass in the base of the left side of the neck. His left thyroid lobe had been resected for goiter 16 years ago.

Ultrasonography revealed an aneurysm in the shape of a triangle in the transverse plane and ovoid shape in the saggital plane, 42 × 34 × 21 mm in size, closely attached to the lateral aspect of the internal jugular vein (IJV) (Panels A and B). At the junction of the middle and the distal third of this aneurysm, a communication with the IJV was seen, 6–7 mm in diameter. High-velocity blood flow was registered within the central part of the aneurysm, and much slower flow near the aneurysmal wall, causing a 'pseudothrombosis' effect. The flow through the aneurysmal neck was bidirectional and respiratory phase-dependent (Panel B).

Surgery was performed with resection of the aneurysm and lateral suture of the jugular vein. No thrombus was found within the aneurysm, and there was no reaction in the surrounding tissue to connect the previous neck surgery with the aneurysm formation. Pathologic examination showed all layers of a normal vein, with endothelial continuity and fibroblastic proliferation and some mixed muscle layers.

Jugular vein aneurysms are rarely seen,^{1,2} and most frequently have been described in children. They appear to have a benign natural history, and should be excised only if symptomatic, enlarging or disfiguring.³ Duplex 3D ultrasonography was a reliable technique for diagnosis and sufficient for surgical treatment of the problem.

References

- 1 Calligaro KD, Ahmad S, Dandora R et al. Venous aneurysms: surgical indications and review of the literature. *Surgery* 1995; **117**: 1–6.
- 2 Fitoz S, Atasoy C, Yagmurly A, Erden I, Akyar S. Gadolinium-enhanced three-dimensional MR angiography in jugular phlebectasia and aneurysm. *Clin Imaging* 2001; **25**: 323–26.
- 3 Hopsu E, Pitkaranta A. Jugular vein aneurysm or phlebectasia. *Am J Surg* 2004; **188**: 622.

^aDedinje Cardiovascular Institute, Vascular Surgery Clinic and ^bAnalife Practice, Belgrade, Serbia and Montenegro

Address for correspondence: Nenad Ilijevski, Dedinje Cardiovascular Institute, Milana Tepica 1, 11000 Belgrade, Serbia and Montenegro. Tel: +381 11 3601 700; Fax: +381 11 3601 711; E-mail: ilijevskidr@yubc.net