HAL open science

Images in vascular medicine

H Gutierrez, J Sanz, S Dellegrottaglie, S Rajagopalan

To cite this version:

H Gutierrez, J Sanz, S Dellegrottaglie, S Rajagopalan. Images in vascular medicine. Vascular Medicine, 2006, 11 (1), pp.49-50. 10.1191/1358863x06vm631xx . hal-00572131

HAL Id: hal-00572131

https://hal.science/hal-00572131v1

Submitted on 1 Mar 2011

HAL is a multi-disciplinary open access archive for the deposit and dissemination of scientific research documents, whether they are published or not. The documents may come from teaching and research institutions in France or abroad, or from public or private research centers.

L'archive ouverte pluridisciplinaire **HAL**, est destinée au dépôt et à la diffusion de documents scientifiques de niveau recherche, publiés ou non, émanant des établissements d'enseignement et de recherche français ou étrangers, des laboratoires publics ou privés.

Vascular Medicine 2006; **11**: 49–50

Images in vascular medicine

Giant coronary aneurysm due to Kawasaki's disease

H Gutierrez[a], J Sanz[b], S Dellegrottaglie[b] and S Rajagopalan[b]

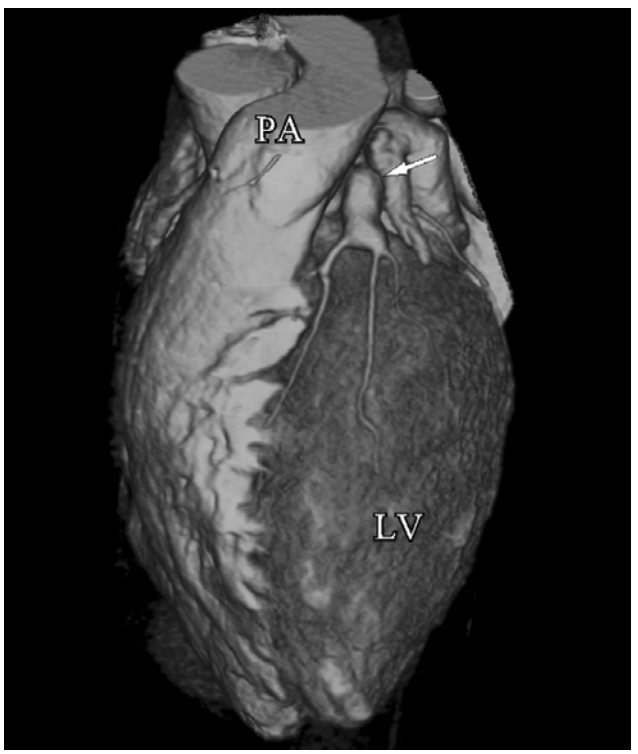

Panel A

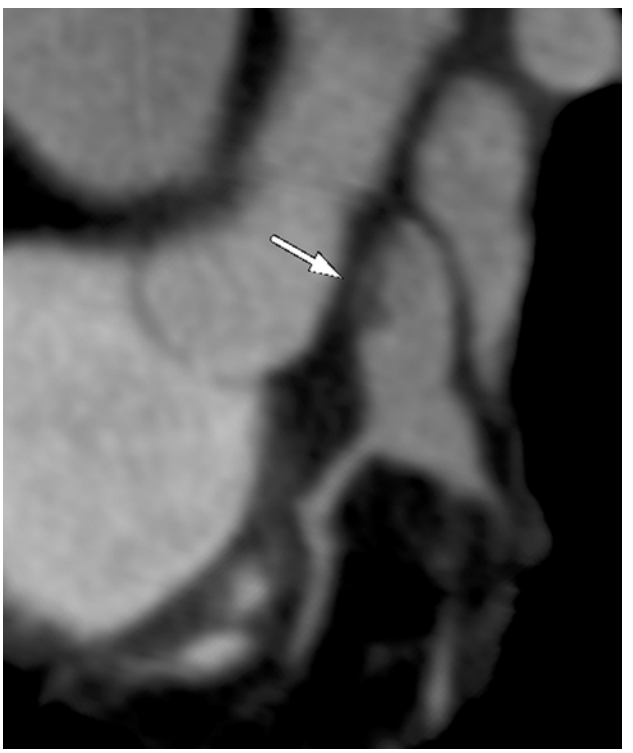

Panel B

A 24-year-old Caucasian woman presented to her physician for a follow-up evaluation of Kawasaki's disease. She had a prior diagnosis of Kawasaki's disease resulting in an aneurysm of the left anterior descending artery (LAD) diagnosed by invasive arteriography 6 years previously but was otherwise asymptomatic. Multidetector computed tomography (MDCT) coronary angiography was performed using the following parameters: 80 ml of contrast followed by 50 ml of saline (rate 3.5 cc/s), rotation time = 0.42 s, collimation = 16 × 0.75 mm, tube current = 400 mAs, voltage = 120 kV, pitch = 0.31. MDCT revealed a giant coronary aneurysm (19 × 9 mm) in the proximal segment of the LAD, involving the origin of a diagonal branch (arrow in Panel A, which shows a 3-dimensional volume rendered reconstruction; PA: pulmonary artery; LV: left ventricle). A small filling defect was noted in the anteromedial inner aspect of the aneurysm in maximum intensity projection (MIP) images, a finding compatible with mural thrombosis (arrow in Panel B). Three other serial aneurysms were seen in the proximal and middle segments of the right coronary artery (8.6 × 4.5 mm, 14 × 6.5 mm and 14 × 10 mm, from proximal to distal, respectively) as shown by the arrows in Panel C (3-dimensional volume

[a]Cardiology Department, Hospital 12 de Octubre, Madrid, Spain; [b]Zena and Michael A Wiener Cardiovascular Institute/Marie-Josee and Henry R Kravis Center for Cardiovascular Health, Mount Sinai School of Medicine, New York, USA

Address for correspondence: Sanjay Rajagopalan, Mount Sinai School of Medicine, One Gustave L Levy Place, New York, NY 10029-6574, USA. Tel: +1 212 241 7911; Fax: +1 212 423 9488; E-mail: sanjay.rajagopalan@mssm.edu

© 2006 Edward Arnold (Publishers) Ltd

10.1191/1358863x06vm631xx

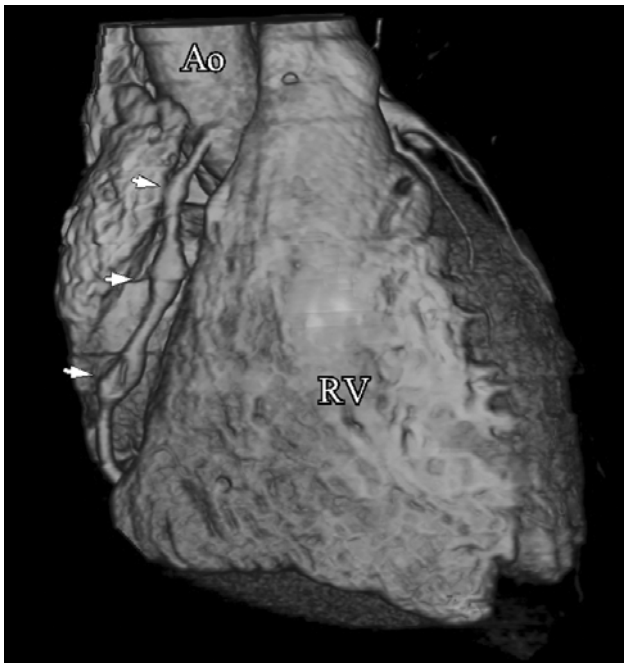

Panel C

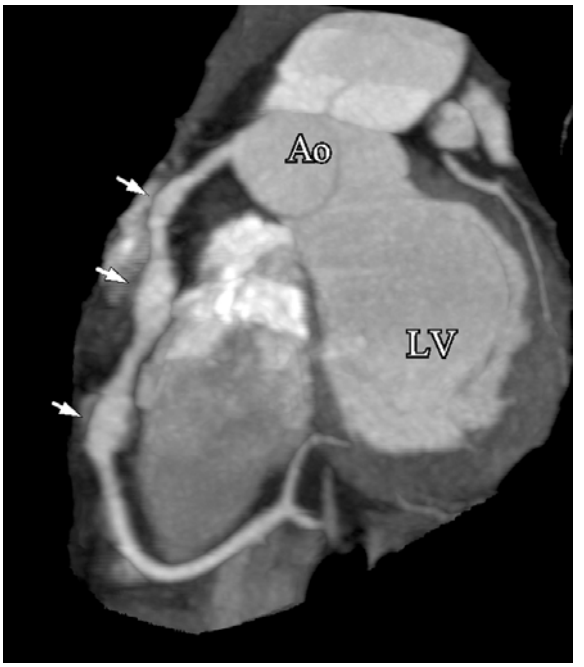

Panel D

rendered image. RV: right ventricle; Ao: aorta) and Panel D (MIP reconstruction. LV: left ventricle; Ao: aorta). No other coronary abnormalities were noted. The patient was referred for coronary artery bypass artery grafting of the LAD and right coronary artery (RCA).

MDCT is a useful tool in the follow up of patients with coronary aneurysms due to Kawasaki's disease. It enables accurate measurement of the diameter of the aneurysms and assessment of the serial changes for determination of optimal timing for surgery.

Acknowledgements

Dr Gutierrez is a Cardiology Fellow and his work is supported by a grant from the Spanish Society of Cardiology. Dr Sanz is a Post-Doctoral Research Fellow and his work is supported by a research grant from the Spanish Society of Cardiology ('Beca para la Formación en Investigación Post-Residencia'). Dr Dellegrottaglie is a Post-Doctoral Research Fellow and his work is supported by a grant from the Italian Society of Cardiology.

'Images in vascular medicine' is a regular feature of *Vascular Medicine*. Readers may submit original, unpublished images related to clinical vascular medicine to: Mark A Creager, Editor in Chief, *Vascular Medicine*, Brigham and Women's Hospital, 75 Francis Street, Boston, MA 02115, USA.