HAL
open science

Renal artery thrombosis in acute type B aortic dissection: what do you do?

Dittmar Böckler, Jens Rainer Allenberg, Hardy Schumacher

To cite this version:

Dittmar Böckler, Jens Rainer Allenberg, Hardy Schumacher. Renal artery thrombosis in acute type B aortic dissection: what do you do?. Vascular Medicine, 2005, 10 (3), pp.237-238. 10.1191/1358863x05vm619xx . hal-00572128

HAL Id: hal-00572128

https://hal.science/hal-00572128v1

Submitted on 1 Mar 2011

HAL is a multi-disciplinary open access archive for the deposit and dissemination of scientific research documents, whether they are published or not. The documents may come from teaching and research institutions in France or abroad, or from public or private research centers.

L'archive ouverte pluridisciplinaire **HAL**, est destinée au dépôt et à la diffusion de documents scientifiques de niveau recherche, publiés ou non, émanant des établissements d'enseignement et de recherche français ou étrangers, des laboratoires publics ou privés.

Vascular Medicine 2005; **10**: 237–238

Images in vascular medicine

Renal artery thrombosis in acute type B aortic dissection: what do you do?

Dittmar Böckler, Jens Rainer Allenberg and Hardy Schumacher

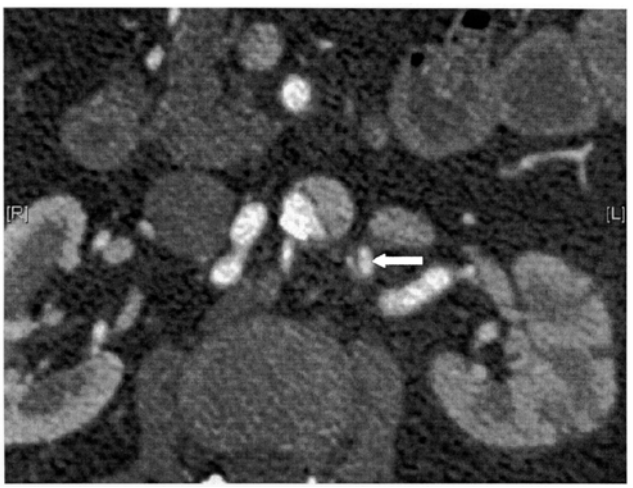

Figure 1A The arrow indicates dissection of the left renal artery. Note minor contrast enhancement of the left kidney. Computed tomographic angiography: axial view.

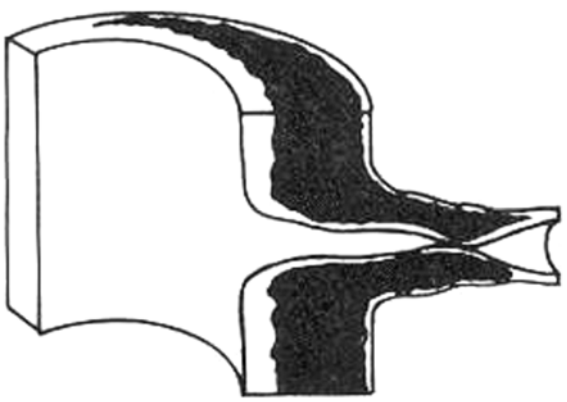

Figure 1B Dissecting membrane causing renal artery occlusion.

Figure 2 Arrow indicates a thrombus in the left renal artery distal to the dissecting membrane. Magnetic resonance angiography: maximal intensity projection.

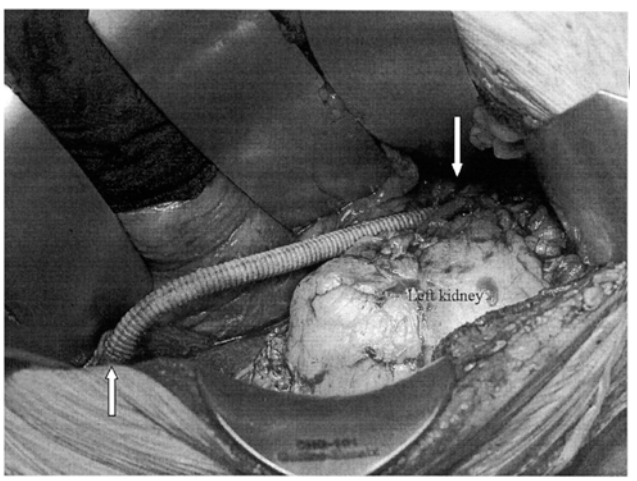

Figure 3 Intraoperative view of the iliac-renal bypass graft. Upward pointing arrow: iliac anastomosis; downward pointing arrow: renal anastomosis.

Department of Vascular and Endovascular Surgery, University of Heidelberg, Heidelberg, Germany

Address for correspondence: Dittmar Böckler, Department of Vascular and Endovascular Surgery, University of Heidelberg, Im Neuenheimer Feld 110, 69120 Heidelberg, Germany. Tel: +49 6221 566249; Fax: +49 6221 566423; E-mail: dittmar_boeckler@med.uni-heidelberg.de

© 2005 Edward Arnold (Publishers) Ltd

10.1191/1358863x05vm619xx

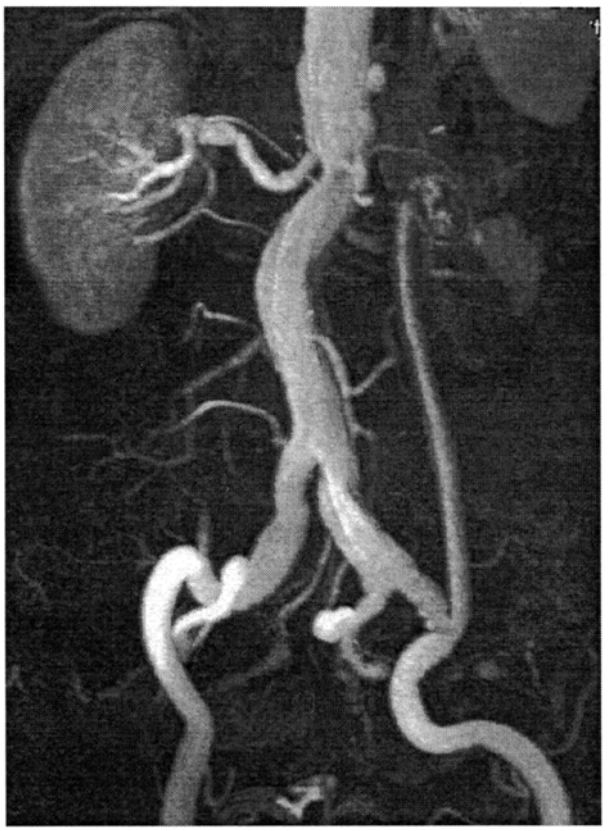

Figure 4A Magnetic resonance angiography: postoperative maximal intensity projection.

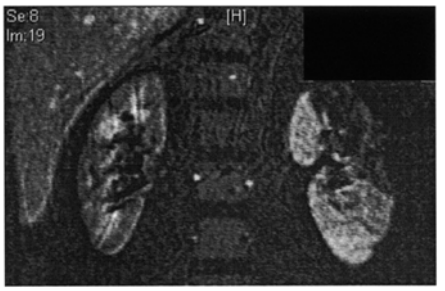

Figure 4B Note left upper segmental kidney infarction. Magnetic resonance angiography.

A 68-year-old man with an acute onset of chest pain was admitted to hospital. No signs of myocardial ischemia were identified on electrocardiography or by blood tests. Physical examination was unremarkable and chest radiography was normal. A computed tomographic (CT) scan confirmed acute aortic dissection type B. The dissecting membrane had extended from the false lumen into the origin of the left renal artery (Figure 1A and B). Distally, appositional thrombus formation was seen in the left proximal renal artery (Figure 2). Contrast enhancement of the left kidney was reduced. The current creatinine level was 1.3 mg/dl. The patient underwent immediate uncomplicated renal artery prosthetic bypass reconstruction using a retroperitoneal approach (Figure 3). Postoperative magnetic resonance angiography imaging demonstrated bypass patency and segmental renal infarction (Figure 4A and B). Creatinine and urea levels showed no significant postoperative elevation. The patient was transferred back to the intensive care unit for aggressive antihypertensive treatment.