



HAL
open science

Images in vascular medicine

Dittmar Böckler, Jens-Rainer Allenberg, Hans-Ulrich Kauczor, Hendrik von Tengg-Kobligk

► **To cite this version:**

Dittmar Böckler, Jens-Rainer Allenberg, Hans-Ulrich Kauczor, Hendrik von Tengg-Kobligk. Images in vascular medicine. *Vascular Medicine*, 2005, 10 (1), pp.61-62. 10.1191/1358863x05vm581xx . hal-00572111

HAL Id: hal-00572111

<https://hal.science/hal-00572111>

Submitted on 1 Mar 2011

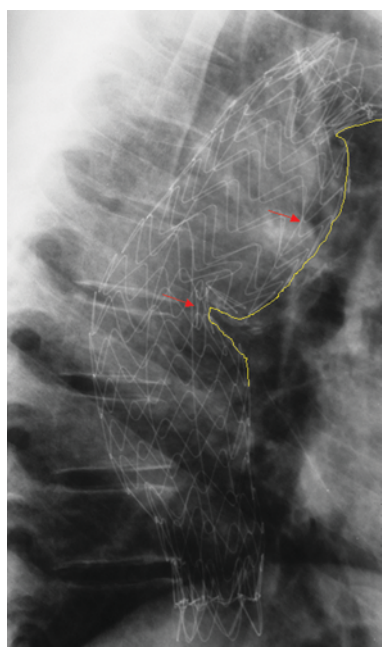
HAL is a multi-disciplinary open access archive for the deposit and dissemination of scientific research documents, whether they are published or not. The documents may come from teaching and research institutions in France or abroad, or from public or private research centers.

L'archive ouverte pluridisciplinaire **HAL**, est destinée au dépôt et à la diffusion de documents scientifiques de niveau recherche, publiés ou non, émanant des établissements d'enseignement et de recherche français ou étrangers, des laboratoires publics ou privés.

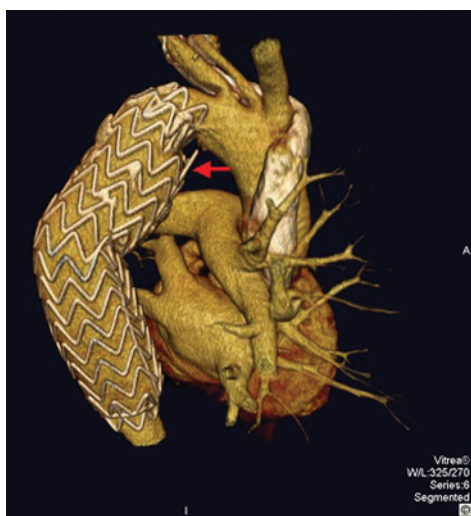Images in vascular medicine

Postprocessing 'fly-through' of multislice computed tomography after thoracic endografting

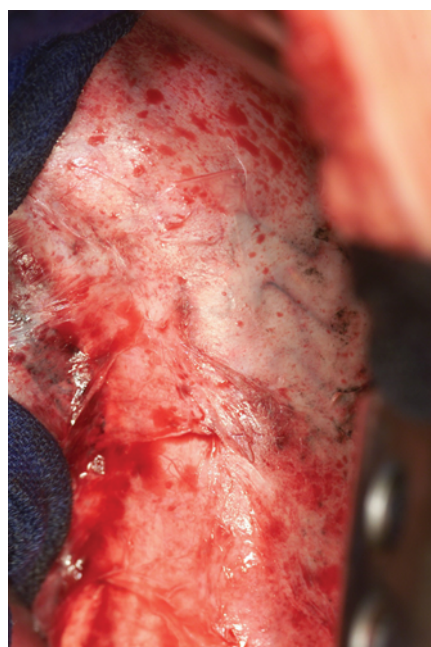
Dittmar Böckler^a, Jens-Rainer Allenberg^a, Hans-Ulrich Kauczor^b and Hendrik von Tengg-Kobligh^b



Panel A



Panel B



Panel C

A 43-year-old man was treated for chronic pseudoaneurysm after traumatic aortic transection by endografting (TAG Excluder; WL Gore & Assoc., Flagstaff, AZ, USA). At 50 months after endovascular repair, a spine wire fracture of the stent-graft was diagnosed on plain X-ray. The chest X-ray, left–anterior 45° view (Panel A) demonstrates kinking, 'herniation' and spine wire fracture. Red arrows indicate the wire fragments and the yellow line the protrusion into the former pseudoaneurysm sac due to severe oversizing. Clinical and radiological signs on a standard computed tomography (CT)-scan were suspicious for stent-graft

^aDepartment of Radiology, German Cancer Research Center, Heidelberg, Germany; ^bDepartment of Vascular and Endovascular Surgery, University of Heidelberg, Germany

Address for correspondence: Dittmar Böckler, Department of Vascular and Endovascular Surgery, Chirurgische Universitätsklinik Heidelberg, Im Neuenheimer Feld 110, 69120 Heidelberg, Germany. Tel: +49 6221 566249; Fax: +49 6221 565423; E-mail: dittmar_boeckler@med.uni-heidelberg.de

Video footage of this can be seen at <http://www.vascularmedjournal.com> by clicking on the 'Additional material' button.



Panel D

infection. For preoperative evaluation, the patient underwent multislice computed tomography (MSCT) 3D-angiography (Aquilion 16, Toshiba Medical Systems, Corp., Otawara, Japan) of the thorax. CT-scan with a collimation of 1 mm revealed air around the stent-graft. Postprocessing on a Vitrea2 workstation (v3.5; Vital Images Inc., Plymouth, MN, USA) using surface-rendering confirmed the extracorporated proximal spine wire fragment (Panel B). The fly-through tool allowed 3D endoluminal evaluation of the stent-graft. Kinking of the stent-graft was demonstrated as well as spine wire fracture showing the proximal end penetrating the aortic wall (Movie 1; yellow arrow). After anterolateral thoracotomy, the wireforms of the stent-graft shined through the inflammatory aortic wall. The device seemed to be well incorporated (Panel C). No infection signs were observed. Conversion of the stent-graft was

successfully performed (Movie 2). The explanted stent-graft showed the broken longitudinal spine wire (Panel D). The patient is alive after 13 months with no further complications. Endoluminal navigation of stent-grafts by postprocessing of high-resolution MDCT data may provide promising information in addition to the regular follow-up procedures after aortic endografting.

Movie 1 Caudo-cranial fly-through confirms kinking of the stent-graft and spine wire fracture (first yellow arrow). The proximal fragment is penetrating the aortic wall (second yellow arrow).

Movie 2 Intraoperative view of conversion performed using anterolateral thoracotomy.