



HAL
open science

Multiple arterial aneurysms in the mediastinum

Drosos Kotelis, Jens-Rainer Allenberg, Götz Richter, Hendrik von Tengg-Kobligk, Nicolas Attigah, Dittmar Böckler

► **To cite this version:**

Drosos Kotelis, Jens-Rainer Allenberg, Götz Richter, Hendrik von Tengg-Kobligk, Nicolas Attigah, et al.. Multiple arterial aneurysms in the mediastinum. *Vascular Medicine*, 2008, 13 (2), pp.173-174. 10.1177/1358863x07086847 . hal-00571401

HAL Id: hal-00571401

<https://hal.science/hal-00571401>

Submitted on 1 Mar 2011

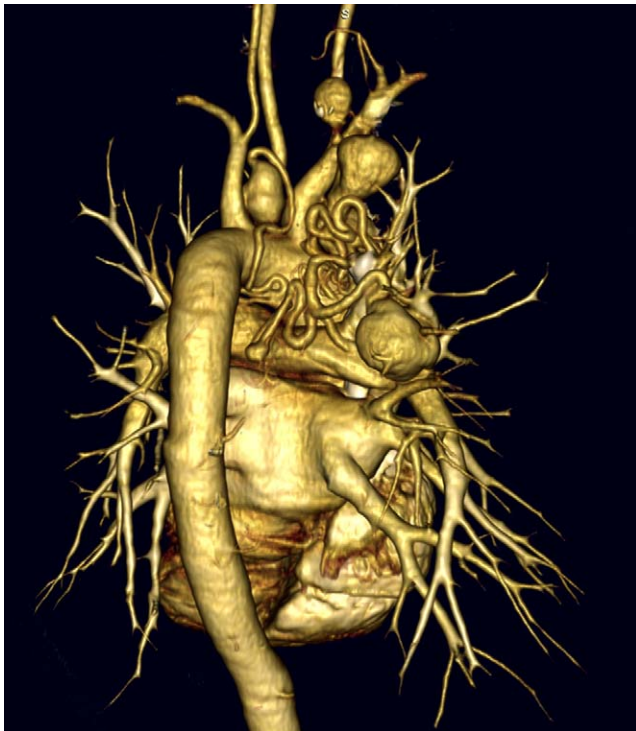
HAL is a multi-disciplinary open access archive for the deposit and dissemination of scientific research documents, whether they are published or not. The documents may come from teaching and research institutions in France or abroad, or from public or private research centers.

L'archive ouverte pluridisciplinaire **HAL**, est destinée au dépôt et à la diffusion de documents scientifiques de niveau recherche, publiés ou non, émanant des établissements d'enseignement et de recherche français ou étrangers, des laboratoires publics ou privés.

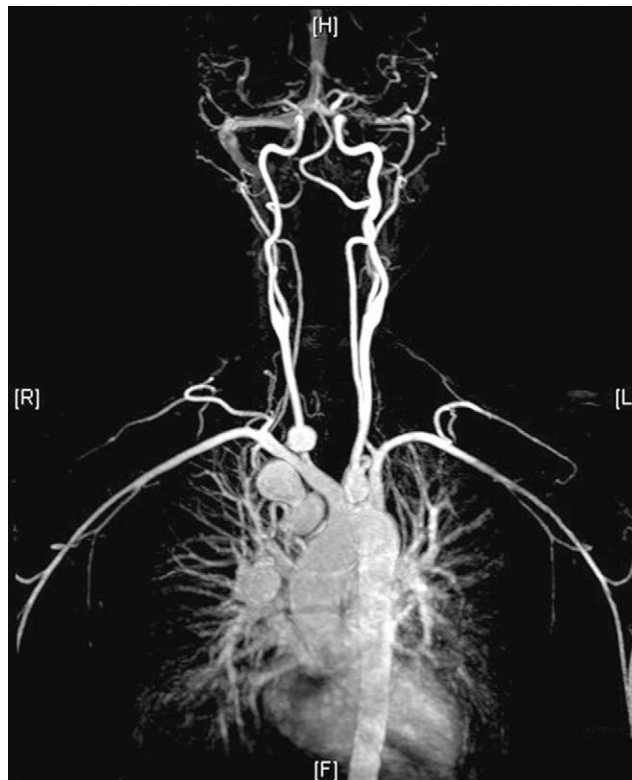Images in vascular medicine

Multiple arterial aneurysms in the mediastinum

Drosos Kotelis¹, Jens-Rainer Allenberg¹, Götz Richter², Hendrik von Tengg-Kobligk³, Nicolas Attigah¹ and Dittmar Böckler¹



Panel A



Panel B

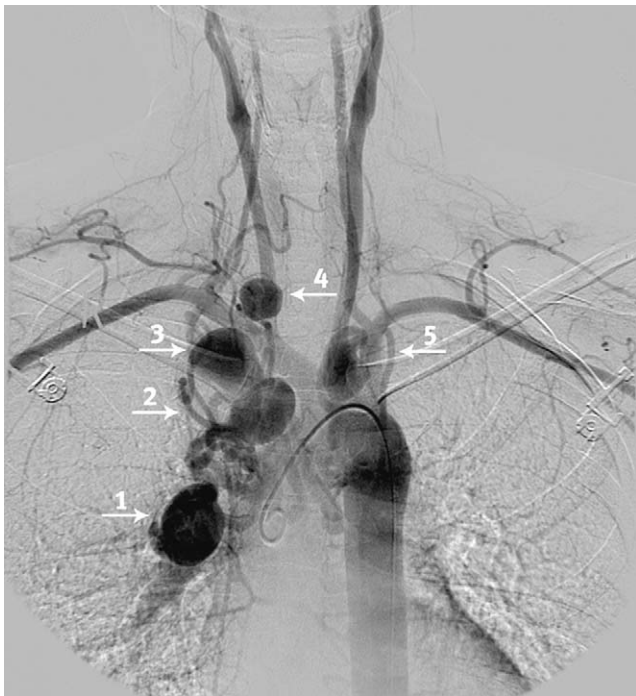A 37-year-old woman presented with a 5-month history of hoarseness. She had no other clinically significant medical history or history of trauma. An ENT doctor diagnosed swelling of the right vocal chord. With the hoarseness being refractory to medical treatment, a chest computed tomography (CT) scan was performed which revealed distinct elongation and kinking of the bronchial

arteries with multiple aneurysms near the right subclavian artery in a location that could cause compression of the recurrent laryngeal nerve (Panel A: posterior view). A contrast-enhanced whole-body magnetic resonance angiography ruled out intracranial, abdominal or acral aneurysm formation (Panel B). Given the uncertain origin of the aneurysms, selective angiography of the thoracic aorta and the supra-aortic vessels showed a total of five aneurysms along the aortic arch (Panel C): aneurysms numbers 1 and 3 were supplied from a bronchial artery and the right internal thoracic artery; aneurysms numbers 4 and 5 were found to originate from the right and the left subclavian artery respectively; aneurysm number 2 originated from the brachiocephalic trunk.

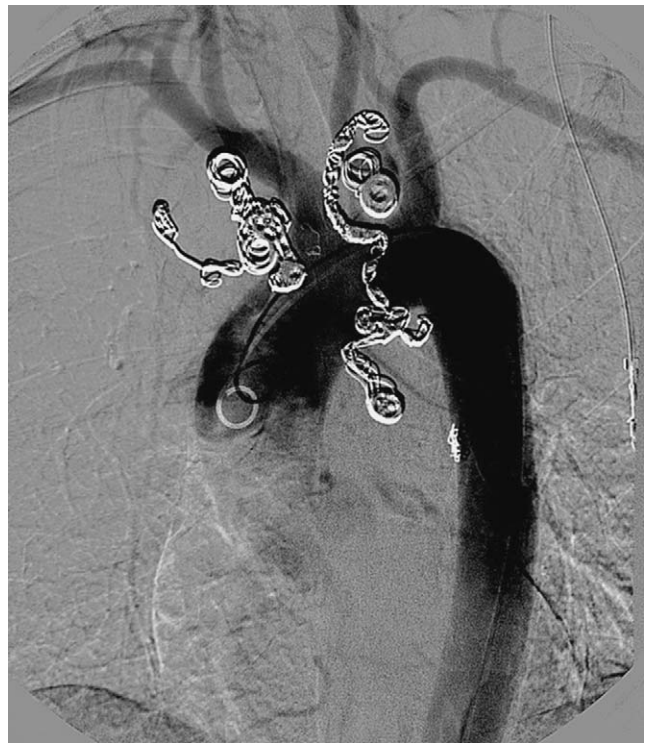¹Department of Vascular and Endovascular Surgery, University of Heidelberg, Heidelberg, Germany; ²Department of Diagnostic Radiology, University of Heidelberg, Heidelberg, Germany; ³Department of Radiology, German Cancer Research Center (DKFZ), Heidelberg, Germany

Correspondence to: Drosos Kotelis, Department of Vascular and Endovascular Surgery, University of Heidelberg, Im Neuenheimer Feld 110, 69120 Heidelberg, Germany.
Email: drosos.kotelis@med.uni-heidelberg.de

Considering the high risk of massive bleeding and neurologic injury with open surgical treatment, we decided to proceed with endovascular embolization. All five aneurysms were selectively embolized in two consecutive sessions using interlocking detachable coils (IDC; Boston Scientific Corporation, Natick, MA, USA) (Panel D).



Panel C



Panel D

At 6 months' follow-up, the CT angiogram showed complete thrombosis of all aneurysms, yet the patient is still suffering from hoarseness and vocal chord swelling.

The etiology of the aneurysm formation in this patient remains unknown, especially since we were not able to gain material for histological examination. Bronchial artery aneurysms are rare and have been associated with atherosclerosis, trauma, inflammatory lung disease, bronchiectasis, tuberculosis, sepsis, and Osler-Weber-Rendu disease.¹ The patient's hoarseness may have been the symptom which led to the diagnosis and may be unrelated to the mediastinal aneurysms. Embolization appears to be a safe and reliable therapeutic option in the management of multiple mediastinal aneurysms.² Long-term follow-up is needed however.

References

- 1 Tanaka, K, Ihaya, A, Horiuchi, T, *et al.* Giant mediastinal bronchial artery aneurysm mimicking benign esophageal tumor: a case report and review of 26 cases from literature. *J Vasc Surg* 2003; **38**: 1125–1129.
- 2 Vernhet, H, Bousquet, C, Jean, B, *et al.* Bronchial aneurysms mimicking aortic aneurysms: endovascular treatment in two patients. *Cardiovasc Interv Radiol* 1999; **22**: 254–257.

'Images in vascular medicine' is a regular feature of *Vascular Medicine*. Readers may submit original, unpublished images related to clinical vascular medicine to: Mark A Creager, Editor in Chief, Vascular Medicine, Brigham and Women's Hospital, 75 Francis Street, Boston, MA 02115, USA.