



HAL
open science

Management of giant cavernous renal arteriovenous malformation

Jagjeeth Naik, Umar Sadat, Jonathan R Boyle

► **To cite this version:**

Jagjeeth Naik, Umar Sadat, Jonathan R Boyle. Management of giant cavernous renal arteriovenous malformation. *Vascular Medicine*, 2008, 13 (2), pp.175-176. 10.1177/1358863x07086128. hal-00571400

HAL Id: hal-00571400

<https://hal.science/hal-00571400>

Submitted on 1 Mar 2011

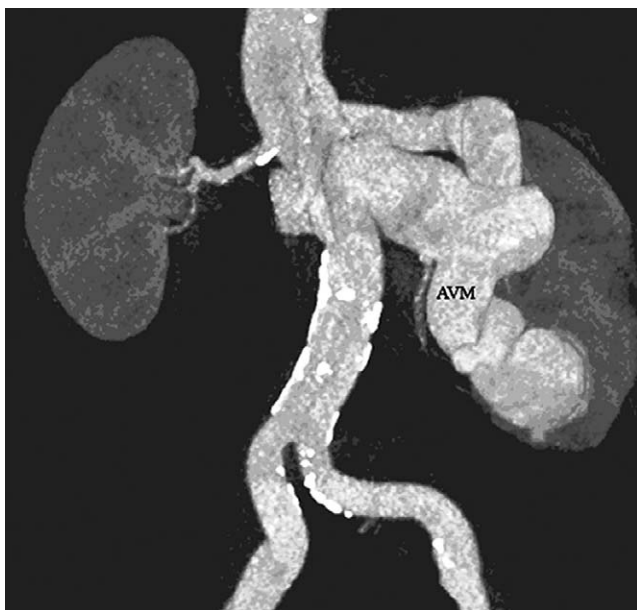HAL is a multi-disciplinary open access archive for the deposit and dissemination of scientific research documents, whether they are published or not. The documents may come from teaching and research institutions in France or abroad, or from public or private research centers.

L'archive ouverte pluridisciplinaire **HAL**, est destinée au dépôt et à la diffusion de documents scientifiques de niveau recherche, publiés ou non, émanant des établissements d'enseignement et de recherche français ou étrangers, des laboratoires publics ou privés.

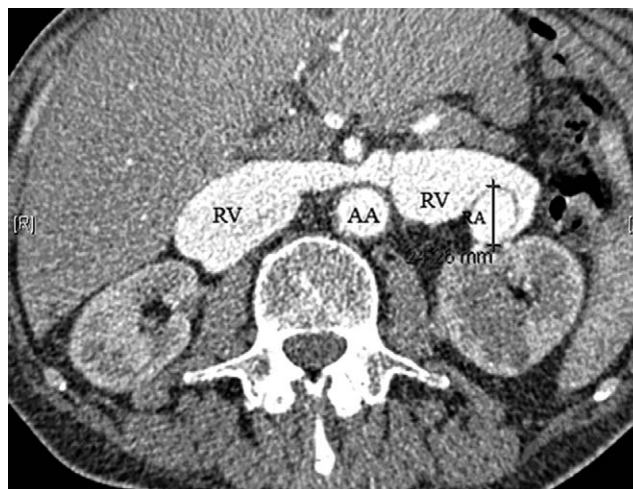
Images in vascular medicine

Management of giant cavernous renal arteriovenous malformation

Jagjeeth Naik, Umar Sadat and Jonathan R Boyle



Panel A



Panel B

A 69-year-old man was referred with weight loss, night sweats, raised inflammatory markers, and an abdominal bruit. He underwent a contrast-enhanced CT scan of the abdomen, which revealed a giant cavernous arteriovenous malformation (AVM) of the left renal artery and vein (Panel A). The left renal artery (RA) was the same size as the adjacent abdominal aorta (AA) and spiralling around a grossly dilated renal vein (Panel B; RV). Aetiology was thought to be congenital, as there was no antecedent history of trauma, biopsy or malignancy. An isotope renal scan showed equivalent function in both kidneys and creatinine levels were normal. Treatment was planned to prevent exacerbation of the existing car-

diomegaly and risk of further high output cardiac failure. Three treatment options are described for this rare condition: endovascular repair, ligation of the fistula and nephrectomy.

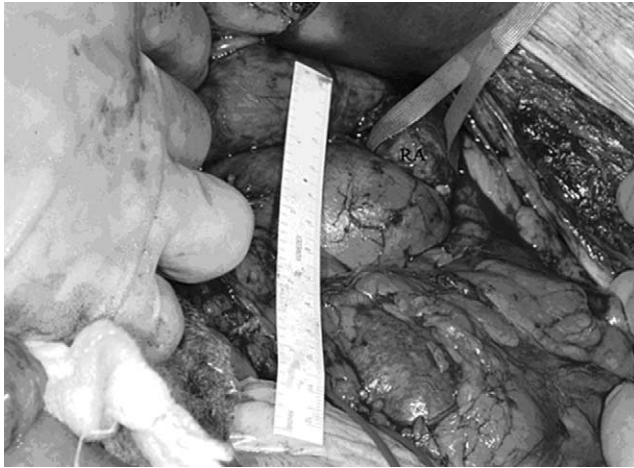Endovascular therapy¹ with coil embolization was felt to be inappropriate in this case due to the vessel calibre and the high-flow fistula (constituting a real danger of coil dislodgement and migration). Open ligation of the AVM is also reported in the literature,² but predominantly for fistulas originating in segmental branches of the renal artery as opposed to the main artery as in this case. Nephrectomy was therefore planned. An abdominal approach was used to control the vessels at the hilum (Panel C; artery slung).

Examination of the excised kidney and opening of the renal vein revealed the site of the AVM, which allowed the passage of a 4-mm catheter (Panel D).

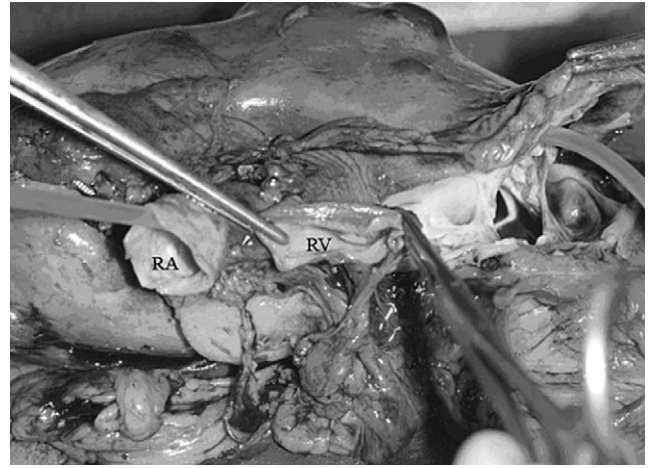
Histology revealed normal endothelium. The patient was discharged on day 6 and at follow-up 6 months later he remains well with stable cardiac status and normal renal function.

Cambridge Vascular Unit, Addenbrooke's Hospital, Cambridge, UK

Correspondence to: Jagjeeth Naik, Department of Vascular Surgery, Box 201, Addenbrooke's Hospital, Hills Road, Cambridge CB2 2QQ, UK. Email: jagnaik@hotmail.com



Panel C



Panel D

References

- 1 Lupattelli, T, Garaci, FG, Manenti, G, Belli, AM, Simonetti, G. Giant high-flow renal arteriovenous fistula treated by percutaneous embolization. *Urology* 2003; **61**: 837.
- 2 Osawa, T, Watarai, Y, Morita, K, Kakizaki, H, Nonomura, K. Surgery for giant high-flow renal arteriovenous fistula: experience in one institution. *BJU Int* 2006; **97**: 794–798.

‘Images in vascular medicine’ is a regular feature of *Vascular Medicine*. Readers may submit original, unpublished images related to clinical vascular medicine to: Mark A Creager, Editor in Chief, Vascular Medicine, Brigham and Women’s Hospital, 75 Francis Street, Boston, MA 02115, USA.