



HAL
open science

Persistent chronic peri-aortitis ('inflammatory aneurysm') after abdominal aortic aneurysm repair: systematic review of the literature

Efh van Bommel, Sj van Der Veer, Tr Hendriksz, Gs Bleumink

► **To cite this version:**

Efh van Bommel, Sj van Der Veer, Tr Hendriksz, Gs Bleumink. Persistent chronic peri-aortitis ('inflammatory aneurysm') after abdominal aortic aneurysm repair: systematic review of the literature. *Vascular Medicine*, 2008, 13 (4), pp.293-303. <10.1177/1358863X08091147>. <hal-00571379>

HAL Id: hal-00571379

<https://hal.science/hal-00571379v1>

Submitted on 1 Mar 2011

HAL is a multi-disciplinary open access archive for the deposit and dissemination of scientific research documents, whether they are published or not. The documents may come from teaching and research institutions in France or abroad, or from public or private research centers.

L'archive ouverte pluridisciplinaire **HAL**, est destinée au dépôt et à la diffusion de documents scientifiques de niveau recherche, publiés ou non, émanant des établissements d'enseignement et de recherche français ou étrangers, des laboratoires publics ou privés.



HAL Authorization

Persistent chronic peri-aortitis ('inflammatory aneurysm') after abdominal aortic aneurysm repair: systematic review of the literature

EFH van Bommel¹, SJ van der Veer², TR Hendriksz² and GS Bleumink¹

Abstract: Data on the outcome of aneurysmal chronic peri-aortitis ('inflammatory aneurysm') after open surgical aneurysm repair are few and contradictory. To what extent this inflammatory process is reversed after endovascular aneurysm repair (EVAR) is even more unclear. The objective of this review was to study the outcome of peri-aortic fibrosis (PAF) and ureteral obstruction in patients with aneurysmal chronic peri-aortitis treated with open surgery or EVAR. Medical literature was searched for pertinent articles on the outcome of PAF and ureteral obstruction after open surgery or EVAR from 1970 through October 2007. Studies were included if specific follow-up data were available on outcomes of interest. A total of 19 studies were included comprising 478 patients (open surgical, $n = 426$; EVAR, $n = 52$). Age, sex and percentage of patients with ureteral obstruction (31% vs 37%) did not differ between groups. Regression of PAF occurred more frequently after open surgery compared to EVAR (86% vs 60%; $p < 0.0001$). Complete regression of PAF was more frequent after open surgery compared to EVAR (52% vs 14%; $p < 0.0001$). After excluding patients in whom concurrent ureterolysis was performed, the frequency of persistent ureteral obstruction remained lower in patients treated surgically compared to patients treated with EVAR, albeit not statistically significant (32% vs 56%; $p = 0.09$). In conclusion, although open surgery is superior to EVAR in achieving regression of chronic peri-aortitis, the frequency of persistent PAF and/or ureteral obstruction is not negligible. Additional medical and/or urological treatment should be considered in selected cases of aneurysmal chronic peri-aortitis.

Key words: aortic aneurysm repair; chronic peri-aortitis; endovascular; inflammatory aneurysm; open surgical; peri-aortic fibrosis; ureteral obstruction

Introduction

The combined findings of abdominal aortic aneurysm (AAA) and peri-aneurysmal fibrosis, usually described as 'inflammatory aneurysm', is considered one of the manifestations of retroperitoneal fibrosis (RPF) and characterized by chronic non-specific inflammation of the retroperitoneum, which can entrap and obstruct retroperitoneal structures, notably the ureters.^{1,2} In idiopathic RPF (i.e. where no causal factor can be identified), an exaggerated inflammatory response to advanced atherosclerosis has been implicated in its pathogenesis.^{3–5}

It is for these reasons that some prefer the term chronic peri-aortitis to encompass idiopathic RPF and peri-aneurysmal fibrosis.^{2–5}

Peri-aneurysmal fibrosis may be suspected pre-operatively in patients with abdominal, back and/or flank pain, weight loss, constipation, and elevated acute-phase reactants and serum creatinine level.^{1,6} Contrast-enhanced computed tomographic (CT) scanning usually confirms the presumed diagnosis and is mandatory for proper planning of aneurysm repair.^{1,2} CT reveals the aneurysm and thickened aortic wall, as well as the often well-delineated peri-aortic soft tissue mass with typical caudad extension to the iliac vessels. The posterior aspect of the aortic wall is usually spared and aortic displacement from the vertebrae is rare.^{1,2} The mass is isodense to psoas muscle and may enhance after contrast injection.^{1,2}

Despite earlier reports suggesting otherwise,^{7–9} it has long been assumed that surgical aneurysm exclusion will suffice in controlling the inflammatory

¹Department of Internal Medicine, Albert Schweitzer Hospital, Dordrecht, The Netherlands; ²Department of Radiology, Albert Schweitzer Hospital, Dordrecht, The Netherlands

Correspondence to: EFH van Bommel, Department of Internal Medicine, Albert Schweitzer Hospital, PO Box 444, NL-3300 AK Dordrecht, The Netherlands.
Email: e.f.h.vanbommel@asz.nl

process. Recently, however, the variable regression of peri-aortic fibrosis after surgical aneurysm exclusion has been noted.^{1,10} Because management differs between centres, little is known about the incidence and postoperative course of ureteral obstruction in these patients and whether or not concomitant ureterolysis should be performed.^{1,10} This is important as associated urological procedures may increase the risk of postoperative complications.^{1,2,10}

Because of a lower risk for morbidity and mortality, endovascular aneurysm repair (EVAR) may be an alternative treatment option for high-risk patients with peri-aneurysmal fibrosis.^{11–15} While it may have equally good results in terms of aneurysm exclusion and aneurysm rupture prevention, persistent or progressive peri-aortic fibrosis has been reported in patients treated with EVAR.^{16–19}

These unclear and controversial issues prompted us to report four cases of persistent chronic peri-aortitis following surgical and endovascular aneurysm exclusion and to review systematically available data on this particular subject.

Materials and methods

Search strategy

The English, German and French language literature indexed in the PubMed and MEDLINE database was thoroughly searched for pertinent articles on open surgical or endovascular repair of inflammatory AAA from 1970 through October 2007. We used the (combined) Medical Subject Headings or text words 'surgical aneurysm repair', 'aortic bypass surgery', 'endovascular aneurysm repair', 'inflammatory aneurysm', 'peri-aortic fibrosis', 'peri-aneurysmal fibrosis', and 'chronic peri-aortitis'. We hand-searched reference lists of all identified studies and of review articles on the general topic of inflammatory aneurysm for further references. The titles and abstracts of all articles identified by the search strategy were screened for appropriateness before retrieval of full articles.

Selection and data extraction

Studies were included in the analysis if the following criteria were fulfilled: (1) inflammatory aneurysm was diagnosed according to accepted criteria;^{1,3,6} (2) open surgical or endovascular aneurysm exclusion was the intended treatment strategy; detailed information was available on at least one of the two primary outcome measures: (3) evolution of peri-aortic fibrosis, including data of repeated (i.e. baseline and follow-up) CT scanning allowing categorization of peri-aortic mass regression; and (4) the evolution of ureteral obstruction. We excluded studies on atherosclerotic (i.e. without inflammation) or mycotic aneurysm repair. Single

case reports or data presented as abstracts only were also excluded from the analysis. Twenty-six retrospective and prospective case-series were identified as potentially relevant and full-text articles were retrieved for evaluation.^{20–45} Of these studies, five were excluded because of lack of data or inability to extract data on outcomes of interest.^{20–24} Two other articles^{25,26} were excluded because data from these case-series were confirmed to be included in more recent articles.^{42,45} Hence, 19 studies were included in our statistical analysis.^{27–45}

The following data were extracted from each article: number of study patients with inflammatory AAA; age (years) and sex of the patients; follow-up duration after the intervention (months); number of patients with uni- or bilateral ureteral obstruction at presentation; type of procedure (open surgical or EVAR); number of patients with concurrent ureterolysis during open surgical aneurysm repair; number of patients with pre-operative CT scanning and at follow-up; number of patients with persistent ureteral obstruction after aneurysm repair; CT-documented evolution of peri-aortic fibrosis (complete, partial or no regression; progression).

If a study reported data related to both atherosclerotic and inflammatory aneurysm repair, we extracted only the data for inflammatory aneurysm repair.^{28,30} Although not a prerequisite for inclusion, follow-up data on clinical signs and symptoms, which were present at baseline (i.e. number of patients with abdominal, back and/or flank pain; number of patients with a raised ESR and/or impaired renal function) were also extracted. If data could not be extracted with confidence, none was entered.

Statistical analysis

Data from most studies were reported as mean and range. In some instances, results were reported as median and range or mean and standard deviation. In cases where individual patient data were available, we chose to calculate the mean and range for continuous variables. Discrete variables are presented as absolute numbers and proportions (%).

To calculate overall data, patient characteristics of studies were pooled if individual patient data were available. When these data were lacking, study estimates were pooled to calculate the means. Differences in findings between study groups (i.e. open surgical versus EVAR) were assessed by the Fisher exact test for categorical variables and the Mann-Whitney test for continuous variables. Values of follow-up variables (i.e. number of patients with pain, raised ESR and impaired renal function) were compared with baseline values using the Fisher exact test. A two-sided *p*-value less than 0.05 was considered statistically significant.

Case reports

Case 1

A 45-year-old man was referred to the outpatient department of internal medicine with malaise, anorexia, weight loss and progressive pain in the abdomen and groin, radiating to the lower back. Physical examination revealed no abnormalities. Laboratory investigation showed elevated erythrocyte sedimentation rate (ESR) (49 mm/h) and C-reactive protein (CRP) (25 mg/l); serum creatinine was 79 $\mu\text{mol/l}$. Abdominal CT scanning showed a retroperitoneal fibrotic mantle enveloping a mildly dilated distal aorta and proximal iliac arteries. Chronic peri-aortitis was suspected and treatment was started with initial high-dose (60 mg/day) prednisone, which led to rapid relief of symptoms. Follow-up CT scanning at 5 months revealed significant regression of the peri-aortic mass. After tapering the prednisone dose to 15 mg, signs and symptoms recurred. Repeat CT scanning confirmed suspected recurrent disease. Combined therapy with azathioprine (150 mg once daily) and prednisone (60 mg once daily) was initiated, which led to rapid improvement in signs and symptoms. Despite combined immunosuppressive treatment for 1 year, he experienced two more recurrences necessitating repeated courses of combined therapy (azathioprine, prednisone, tamoxifen). Fifty-six months after the initial diagnosis, the patient sought a second opinion elsewhere, where surgical intervention was advocated. After gradually stopping medical treatment, the patient underwent resection of the atherosclerotic aorta with insertion of a tube graft prosthesis. Six months after surgery, signs and symptoms of chronic peri-aortitis recurred. Repeat CT scanning showed a large peri-aortic mass; gallium-67 scanning revealed intense pathologic activity.⁴⁶ Treatment was started with prednisone and cyclophosphamide, which led to rapid improvement. At the time of his latest follow-up, a second recurrence after surgical intervention necessitated re-introduction of immunosuppressive treatment.

Case 2

A 64-year-old man was referred to our outpatient department for evaluation of chronic kidney disease. Eleven months prior to presentation he underwent open surgical aortic aneurysm repair for inflammatory AAA. The patient experienced dull flank and lower back pain, constipation and weight loss of 4 kg in the last 4 months. Physical examination showed systolic hypertension (180/80), weak peripheral pulses of the lower extremities and a murmur over the femoral arteries. Relevant laboratory investigation included a normal ESR (17 mm/h) and increased serum creatinine (256 $\mu\text{mol/l}$). An abdominal CT scan showed extensive atherosclerotic dis-

ease of the proximal abdominal aorta, prosthesis in situ, and peri-aortic fibrosis extending towards the aortic bifurcation (Figure 1). There was no hydronephrosis. Gallium scanning was negative.⁴⁶ Recurrent chronic peri-aortitis despite aneurysmectomy was suspected. Chronic kidney disease was thought to be due to chronic hypertension and generalized vascular disease. Treatment was started with tamoxifen 20 mg twice daily, which was well tolerated. Within 2 weeks his complaints improved significantly and pain subsided completely. Follow-up CT scanning at 4 months showed significant regression of the peri-aortic mass (Figure 1B). Tamoxifen treatment was continued for 2 years. At the time of his latest follow-up, 20 months after cessation of tamoxifen, the patient feels well and ESR is within the normal range. His latest CT scan showed stable residual peri-aortic fibrosis.

Case 3

A 76-year-old man was referred to our outpatient department with progressive abdominal and lower

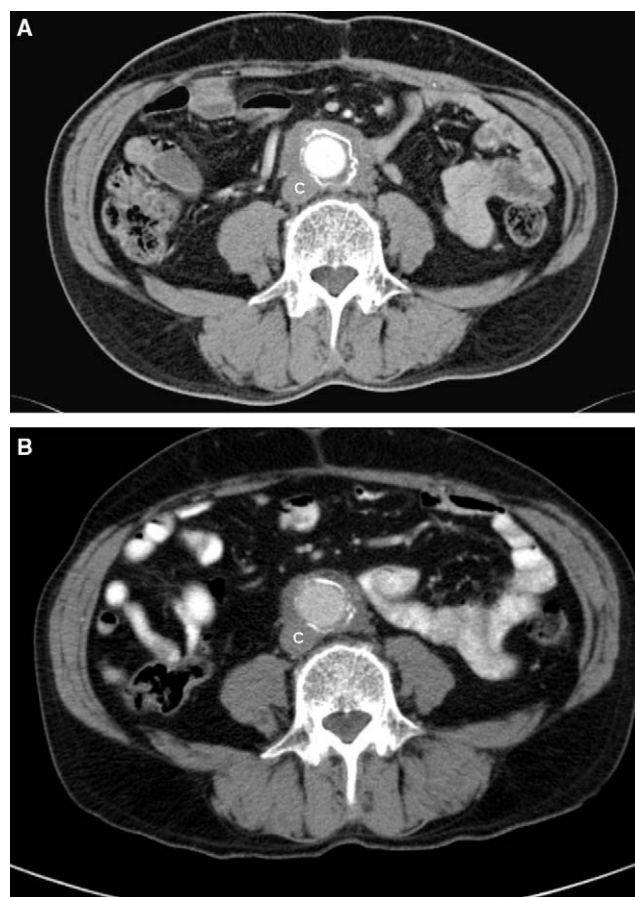


Figure 1 (A) Eleven-month postoperative CT scan in a 64-year-old man shows the aortic bypass graft and a peri-aneurysmal soft tissue mass with limited involvement of inferior caval vein (C). (B) Note that the posterior aortic wall is spared. A follow-up CT scan after 4 months of tamoxifen treatment shows regression of the peri-aortic mass.

back pain, weight loss of 10 kg, pollakisuria and extreme tiredness of 9 months duration. Fourteen months before referral he had received an endovascular stent for treatment of an inflammatory infrarenal aortic aneurysm. Additionally, 2 months before referral endovascular stenting of a thoracic aortic aneurysm has been performed, which was complicated by a proximal type I endoleak. There were no abnormal findings on physical examination. Relevant laboratory investigation included an increased ESR (48 mm/h), CRP (80 mg/l) and serum creatinine 173 $\mu\text{mol/l}$. An abdominal CT scan showed peri-aortic (Figure 2) and peri-iliacal fibrosis with a normal left kidney and an atrophic hydronephrotic right kidney. Hydronephrosis was not seen on a CT scan performed elsewhere prior to the first endovascular procedure. Gallium-67 scanning showed increased pathologic activity at the level of the peri-aortic

mass. Progressive chronic peri-aortitis despite endovascular aneurysmal exclusion was suspected and treatment was started with tamoxifen 20 mg twice daily, which resulted in some improvement of symptoms. Repeated gallium scanning at 3 months showed a decrease in pathologic gallium activity. Laboratory investigation revealed a decrease of the ESR to 15 mm/h and CRP to 11 mg/l, while creatinine remained stable. Follow-up CT scanning at 4 months showed no mass regression. Disease-responsiveness to tamoxifen was considered insufficient, upon which azathioprine 100 mg once daily was added to the treatment regimen. At the time of his latest follow-up, the patient feels well without any complaints. ESR and CRP are within the normal range. CT scanning after 8 months of medical treatment showed moderate regression of the fibrotic mass (Figure 2B).

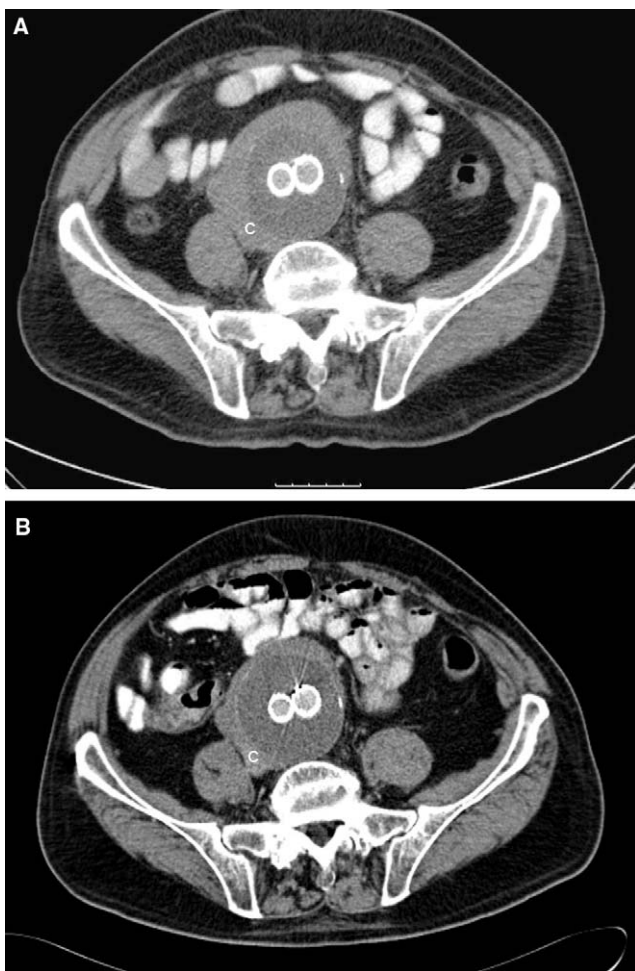


Figure 2 (A) Contrast-enhanced CT scan 14 months post-EVAR in a 76-year-old man shows the two patent limbs of the endovascular graft (Excluder® graft) and a well-delineated peri-aneurysmal soft tissue mass extending to the right psoas muscle. There is some narrowing of the inferior caval vein (C). The posterior aortic wall is spared. (B) A follow-up CT scan after 8 months of treatment with tamoxifen and azathioprine shows regression of the peri-aortic soft tissue mass.

Case 4

This 48-year-old man was referred to our outpatient department with persistent chronic peri-aortitis after aortic bifurcation graft implantation. Five months earlier, the patient was diagnosed in another hospital with peri-aneurysmal fibrosis complicated by bilateral hydronephrosis. He had suffered from fatigue, malaise, back pain, weight loss of 22 kg and fever. Physical examination revealed no abnormalities. The patient was treated with open surgical aneurysm repair combined with bilateral ureteral stenting. Ureteral catheters were removed 2 months later because of local bladder wall irritation. Three months after surgery, symptoms of fatigue and malaise were still very prominent. Lower back pain had diminished to a vague sensation. Fever and weight loss had disappeared. Repeat CT scanning revealed a large peri-aortic mass and hydronephrosis of the left kidney. The patient was then referred to our centre. At presentation, laboratory investigation showed normal ESR (14 mm/h) and CRP (7 mg/l); serum creatinine was 151 $\mu\text{mol/l}$. Gallium scanning was negative. Persistent chronic peri-aortitis was suspected and treatment was started with tamoxifen 20 mg twice daily. Additionally, a percutaneous nephrostomy catheter was inserted. Tamoxifen was well tolerated and led to rapid improvement of symptoms. CT scanning 4 months later showed significant regression of peri-aortic fibrosis. No improvement of renal function was observed, probably because of irreversible obstructive nephropathy.

Results

Characteristics of patients who were treated with open surgical aneurysm repair are depicted in Tables 1 and 2. The mean age of the patients was 67 years (28–92), with a male predominance (82%).

Table 1 Characteristics of study patients treated with open surgical aortic aneurysm repair

Author, year [ref]	Patients, <i>n</i>	Mean age, years (range)	Male sex, <i>n</i> (%)	Ureteral obstruction ^a , <i>n</i> (%)	Mean follow-up months (range)
Plate, 1988 ²⁷	6 ^b	70 (63–78)	4 (80)	4 (50)	7 (6–17) ^c
Nachbur, 1989 ²⁸	8 ^b	62 (50–77)	7 (100)	8 (100)	N/A (4–60)
Stella, 1993 ²⁹	19	65 (38–76)	18 (95)	10 (53)	21 (N/A) ^c
Nitecki, 1996 ³⁰	29	72 (N/A)	24 (83)	9 (31)	13 (3–51)
Bitsch, 1997 ³¹	21	64 (47–78)	19 (90)	7 (33)	36 (4–108)
Lacquet, 1997 ³³	110 ^b	67 (49–84)	101 (92)	23 (21)	54 (6–180)
Koch, 1998 ³²	49	65 (28–92)	46 (94)	N/A	30 (N/A)
Von Fritchen, 1999 ³⁵	42	71 (N/A)	40 (95)	9 (21)	36 (10–91) ^c
Dimakakos, 1999 ³⁴	15	66 (58–78)	15 (100)	3 (20)	N/A (4–120)
Speziale, 2001 ³⁶	14 ^b	66 (58–72)	10 (77)	14 (100)	48 (3–60)
Pistolese, 2002 ³⁷	21	66 (49–76)	19 (90)	5 (24)	10 (4–18)
Arroyo, 2003 ³⁸	52	66 (53–76)	10 (91)	11 (21)	55 (12–96)
Ockert, 2006 ³⁹	40	67 (51–86)	38 (96)	N/A	32 (N/A)
Overall	426	67 (28–92)	351 (82)	103 (31)	35 (3–120)

N/A, not applicable or not available.

^aNo. of patients (percentage) with pre-operative uni- or bilateral ureteral obstruction due to peri-aortic fibrosis.

^bSome patients received additional corticosteroids (Plate, *n* = 1; Nachbur, *n* = 2; Lacquet, *n* = 1; Speziale, *n* = 1).

^cValues are median and range.

Follow-up CT data from patients who were treated with open surgical aneurysm repair (Table 2) showed regression of the peri-aortic mass in 86% of patients. Complete mass regression occurred in 52% of patients. Pre-operative ureteral obstruction was present in 103 of 337 (31%) patients from whom this data were available (Table 1). Overall, ureteral obstruction persisted in 27% at follow-up. To observe the natural evolution of ureteral obstruction after open surgical aneurysm repair *per se*, we excluded patients in whom concurrent ureterolysis was performed during surgery. After exclusion of this factor, persistent ureteral obstruction after open surgical aneurysm repair was present in 32% of patients (Figure 3).

Pooled data from the patients who were treated with the EVAR procedure are depicted in Tables 3

and 4. The mean age of the patients was 67 years (range 56–82), with a male predominance (90%). CT follow-up in patients after the EVAR procedure (Table 4) showed regression of the peri-aortic mass in 60% of patients. Complete regression was observed in 14% of the patients. Pre-operative ureteral obstruction was present in 19 of 52 patients (37%). Ureteral obstruction persisted in 10 of these patients at follow-up (53%).

Comparison of both study groups showed no difference between age and sex (Table 5). Overall, follow-up duration did not differ between groups (*p* = 0.22). The number of patients with ureteral obstruction prior to intervention was also similar in both study groups. More patients treated with EVAR received additional corticosteroids than patients treated with open surgery, but we cannot

Table 2 Evolution of peri-aortic fibrosis after open surgical aortic aneurysm repair in study patients with CT follow-up

Author, year [ref]	Patients with CT follow-up, <i>n</i>	CT findings		
		CR, <i>n</i> (%)	PR, <i>n</i> (%)	NR, <i>n</i> (%)
Plate, 1988 ²⁷	5	5 (100)	0 (0)	0 (0)
Nachbur, 1989 ²⁸	7	4 (57)	3 (43)	0 (0)
Stella, 1993 ²⁹	19	9 (47)	4 (21)	6 (32)
Nitecki, 1996 ³⁰	19	10 (53)	9 (47)	0 (0)
Bitsch, 1997 ³¹	21	6 (29)	12 (57)	3 (14)
Koch, 1998 ³²	49	42 (85)	5 (11)	2 (4)
Von Fritchen, 1999 ³⁵	26	6 (23)	9 (35)	11 (42) ^a
Dimakakos, 1999 ³⁴	10	7 (70)	3 (30)	0 (0)
Speziale, 2001 ³⁶	12	6 (50)	3 (25)	3 (25) ^a
Pistolese, 2002 ³⁷	21	5 (24)	14 (67)	2 (9)
Ockert, 2006 ³⁹	19	9 (47)	8 (42)	2 (11)
Overall	208	109 (52)	70 (34)	29 (14)

CT, computed tomographic; CR, complete regression; PR, partial regression; NR, no regression.

^aProgressive fibrosis was observed in some of these patients (von Fritchen, *n* = 1; Speziale, no. of patients not specified).

Table 3 Characteristics of study patients treated with endovascular aortic aneurysm repair

Author, year [ref]	Patients, <i>n</i>	Mean age, years (range)	Male sex, <i>n</i> (%)	Ureteral obstruction ^a , <i>n</i> (%)	Mean follow-up months (range)
Vallabhaneni, 2001 ⁴⁰	6 ^b	66 (56–76)	5 (83)	2 (33)	19 (6–36)
Hinchliffe, 2002 ⁴¹	11 ^b	69 (60–78)	11 (100)	6 (55)	29 (11–73)
Faizer, 2005 ⁴⁴	6	67 (58–77)	5 (83)	1 (17)	25 (4–56)
Lange, 2005 ⁴⁵	11	66 ± 10.1 (SD)	10 (91)	5 (45)	N/A
Hechelhammer, 2005 ⁴³	10 ^b	64 (57–80)	8 (80)	3 (30)	33 (13–59)
Puchner, 2006 ⁴²	8	69 (55–82)	8 (100)	2 (25)	24 (1–109)
Overall	52	67 (56–82)	47 (90)	19 (37)	26 (1–109)

SD, standard deviation; N/A, not applicable or not available.

^aNo. of patients (percentage) with pre-operative uni- or bilateral ureteral obstruction due to peri-aortic fibrosis.

^bSome patients received additional corticosteroids (Vallabhaneni, *n* = 2; Hinchliffe, *n* = 1; Hechelhammer, *n* = 4).

ascertain if such data were actively searched for by all authors (Tables 1 and 3). Comparison of CT follow-up data shows that regression of the peri-aortic mass not only occurs more frequently after open surgical aneurysm repair compared to EVAR, but also to a greater extent (Table 5). Although rare, progression of the peri-aortic mass is also observed in some patients after both proce-

dures (Table 2 and 4). Overall, the number of patients with persistent ureteral obstruction at follow-up was lower in patients treated surgically compared to patients treated with EVAR (Table 5). After exclusion of patients in whom concurrent ureterolysis was performed during or shortly after intervention (open surgery, *n* = 34; EVAR, *n* = 1), this difference remained, albeit not statistically significant (Table 5).

Few data were available on the evolution of clinical signs and symptoms of chronic peri-aortitis after aneurysm repair. Pooled data from four studies reporting on the short-term evolution of pain after open surgical aneurysm repair^{27,29,30,35} suggest that pain subsides in the majority of patients (patients with abdominal, back and/or flank pain: pre-operative 67/96 [70%] vs postoperative follow-up 6/94 [6%]; *p* < 0.0001). Similarly, pooled data from three studies^{27–29} suggest that the ESR normalizes in the majority of patients after open surgical aneurysm repair (patients with raised ESR: pre-operative 25/33 [75%] vs postoperative follow-up 6/32 [19%]; *p* < 0.001). Pooled data from three studies^{27,30,36} showed persistently impaired renal function in a significant number of patients (pre-operative 34/49 [69%] vs postoperative follow-up 30/44 [68%]; *p* = 1.0). Lack of data on the evolution of clinical signs and symptoms after the EVAR procedure precludes the performance of similar exploration.

Discussion

The present cases illustrate the sometimes recurring or ongoing inflammatory process in patients with chronic peri-aortitis despite aneurysm exclusion. Our systematic review of the literature indicates that in terms of regression of peri-aortic fibrosis, surgical aneurysm repair is superior to EVAR. However, persistent peri-aortic fibrosis occurs in 14% of patients treated with open surgical aneurysm

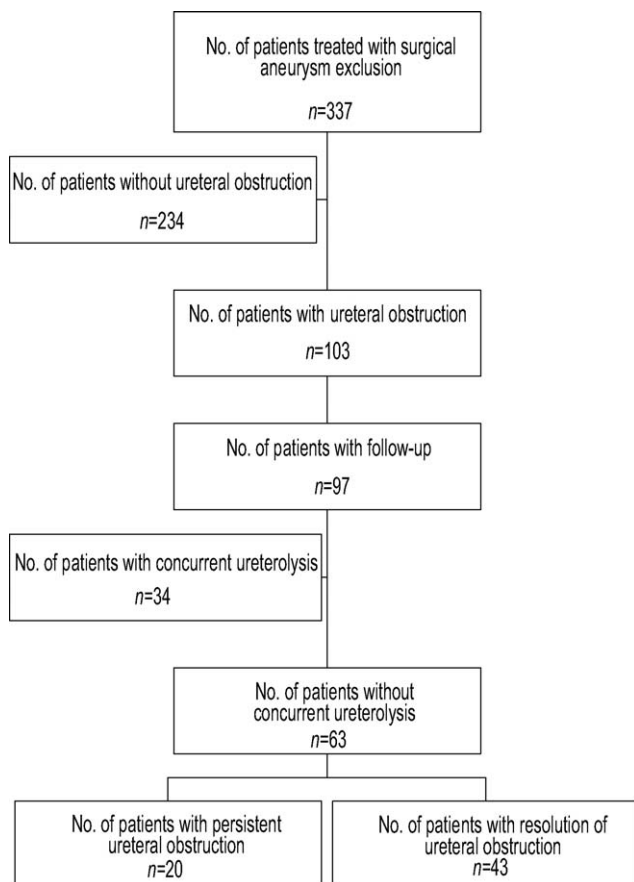


Figure 3 Depiction of the number of patients with pre-operative ureteral obstruction in whom ureteral obstruction did not resolve after open surgical aneurysm exclusion *per se* (i.e. without concurrent ureterolysis). Data from refs 27–31,33–38.

Table 4 Evolution of peri-aortic fibrosis and ureteral obstruction after endovascular aortic aneurysm repair in study patients

Author, year [ref]	CT findings			Persistent ureteral obstruction ^a , n (%)
	CR, n (%)	PR, n (%)	NR, n (%)	
Vallabhaneni, 2001 ⁴⁰	0 (0)	0 (0)	6 (100) ^b	1/2 (50)
Hinchliffe, 2002 ⁴¹	2 (18)	3 (27)	6 (55)	5/6 (83)
Faizer, 2005 ⁴⁴	0 (0)	6 (100)	0 (0)	0/1 (0)
Lange, 2005 ⁴⁵	0 (0)	6 (55)	5 (45) ^b	3/5 (60) ^c
Hechelhammer, 2005 ⁴³	2 (20)	7 (70)	1 (10)	0/3 (0)
Puchner, 2006 ⁴²	3 (38)	2 (24)	3 (38)	1/2 (50)
Overall	7 (14)	24 (46)	21 (40)	10/19 (56)

CT, computed tomographic; CR, complete regression; PR, partial regression; NR, no regression.

^aNo. of patients (percentage) with persistent uni- or bilateral ureteral obstruction at follow-up.

^bProgressive fibrosis was observed in some patients in these series (Vallabhaneni, *n* = 2; Lange, number of patients not specified).

^cUreterolysis was performed in one patient post-EVAR (endovascular aortic aneurysm repair).

repair. After the EVAR procedure, up to 40% of patients will not develop regression of peri-aortic fibrosis. There is a time-dependent regression of peri-aortic fibrosis after aneurysm exclusion, usually requiring at least 4–6 months, and the regression rate may be slow but persistent.^{27,30,31} Better results with open surgery cannot be readily explained by a longer follow-up duration. To what extent the use of additional corticosteroids in some patients contributed to outcomes of interest is unclear. Although rare, *de novo* peri-aortic fibrosis has been observed after EVAR.³⁶ Endovascular grafts provoke a foreign body reaction. Therefore, persistence or *de novo* development may relate to this added stimulus.¹⁷

Although not our primary outcome of interest and based on few data, the present study suggests that in the majority of patients treated with open surgery pain will subside and ESR values will normalize. However, signs and symptoms may recur or gradually worsen and may develop unrecognized, as

illustrated in our cases. It is unknown whether the (sequential) measurement of ESR or CRP is of any value in the diagnosis and follow-up of chronic peri-aortitis. Therefore, additional nuclear imaging with ⁶⁷Ga-scintigraphy or ¹⁸F-fluorodeoxyglucose positron emission tomography (¹⁸F-FDG PET) may not only help in establishing (recurrent) active disease, but may also be the only follow-up parameter in monitoring treatment response.^{46,47} If more widely available and less costly, combined ¹⁸F-FDG PET-CT scanning may become the most appropriate imaging modality in chronic peri-aortitis.

Persistent ureteral obstruction occurred more frequently after EVAR than after open surgical aneurysm exclusion. Although sometimes advocated,^{29,31} performing routine ureterolysis during open surgery seems less obvious as we found that ureteral obstruction subsides in the majority of patients following surgical aneurysm exclusion *per se*. In addition, extensive ureteral dissection has been associated with short and long-term morbidity

Table 5 Comparison of the evolution of peri-aortic fibrosis (PAF) and ureteral obstruction after open surgical or endovascular aortic aneurysm repair in study patients

Variable	Open surgical aneurysm repair	Endovascular aneurysm repair (EVAR)	<i>p</i> -value ^a
Clinical characteristics			
Mean age, years (range)	67 (28–92)	67 (56–80)	0.79
Male sex, n (%)	351/426 (82)	47/52 (90)	0.17
Ureteral obstruction, n (%)	103/337 (31)	19/52 (37)	0.42
Outcome			
Regression of PAF, n (%)	179/208 (86)	31/52 (60)	<0.0001
Complete regression, n (%)	109/208 (52)	7/52 (14)	<0.0001
Persistent ureteral obstruction, n (%)			
All patients with follow-up	25/97 (27)	10/19 (53)	0.02
Patients without ureterolysis ^b	20/63 (32)	10/18 (56)	0.09

^aMann–Whitney test or Fisher exact test, where appropriate.

^bPatients in whom concurrent ureterolysis was performed during or shortly after aneurysm repair were excluded from this analysis (open surgery, *n* = 34; EVAR, *n* = 1).

(e.g. avascular necrosis or fibrosis of the ureter) and mortality.^{29,33,48} Nevertheless, prolonged ureteral obstruction may add to chronic renal failure due to obstructive nephropathy superimposed on often pre-existing ischaemic nephropathy. Indeed, renal atrophy is a frequent finding upon repeated radiologic investigation in patients with RPF complicated by ureteral obstruction.^{30,49} Our observation of persistently impaired renal function in 68% of patients following surgery in the present study substantiates this point. The above findings justify the question of whether (urgent) renal drainage through percutaneous nephrostomy (PNS) and/or ureteral stenting combined with medical treatment should be performed prior to planning the surgical procedure in cases with severe and/or bilateral ureteral obstruction.

Repairing AAAs smaller than 55 mm has not been shown to improve survival.^{1,50} Therefore, primary medical treatment, when needed with renal drainage, is probably the best option in cases with no urgent operation indication. Primary medical treatment may also be preferred in cases of severe inflammation, bilateral ureteral obstruction and/or in the presence of a large peri-aortic mass, thereby achieving symptomatic relief and facilitating otherwise more difficult surgical procedures.^{6,51–57} In other cases, medical treatment should probably be withheld until close follow-up after the intervention shows on-going inflammation, thereby taking into account the time-dependent regression of fibrosis. However, given the risk of irreversible obstructive nephropathy, we suggest earlier consideration of renal drainage in such cases, thereby recognizing the possible early and late complications of PNS or ureteral stenting, notably the increased risk of urinary infection and bacteremia which could lead to prosthesis infection.^{58,59} Although rare, long-term indwelling ureteral stents in patients with an endovascular stent or prosthesis *in situ* have been associated with ureteral leak due to pressure necrosis and uretero-arterial fistula formation.^{60–62} PNS may therefore be the preferred drainage procedure. Irrespective of the urological procedure, close clinical and radiological follow-up is mandatory in these patients.

At least in the short and mid-term, the recently developed EVAR procedure seems to have equally good results as the long-established technique of open surgical aneurysm repair in terms of rupture prevention, which is usually considered the best marker of successful treatment of both inflammatory and non-inflammatory aortic aneurysms.^{1,10,12,63} In atherosclerotic aortic aneurysm, EVAR is associated with lower operative mortality than open surgery.^{1,10,12,63} In a controlled trial, 5-year survival was similar for EVAR compared to open surgery, but with less morbidity despite the need for late

reinterventions.¹¹ Early mortality rate with open surgery in inflammatory aneurysm is slightly higher than in atherosclerotic aneurysm and ranges from 6.8% to 11%.^{20–23,30,33,39} Early mortality rate in inflammatory aneurysm with EVAR appears low and similar to that reported with EVAR in atherosclerotic aneurysm (1.9% vs 1.8%).^{45,64} Although these data need to be confirmed, EVAR seems associated with a lower early mortality than open surgery in inflammatory aneurysm.

However, regression of peri-aortic fibrosis and resolution of ureteral obstruction in patients with inflammatory aortic aneurysms should also be considered important treatment goals. Indeed, postoperative persisting fibrosis with ureteral entrapment and postoperative chronic renal failure were recently shown to be independent risk factors for death.²⁴ Hence, the debate as to whether EVAR should be considered a safer option in (selected) patients with peri-aneurysmal fibrosis as opposed to open surgery should include the less satisfactory results in terms of peri-aortic mass regression and resolution of ureteral obstruction. Therefore, additional medical treatment may need to be considered at an earlier stage with EVAR than with open surgical aneurysm repair, in which a 'wait and see' policy after surgery seems justified in cases without extensive disease.

It has long been recognized that treatment with corticosteroids may facilitate successful resection of an inflammatory aneurysm in patients who were initially considered unfit for surgery.^{2,6,50–57} Despite these early reports, no (controlled) studies exist on the role of steroids and/or other medical therapy in addition to aneurysm exclusion. Steroids act through reduction of inflammation and oedema, inhibition of fibroblastic proliferation, and immunosuppression.^{3,49} Although steroids do not reverse established fibrosis, further fibroblastic proliferation may be slowed and symptomatology reversed. The use of corticosteroids is not without hazard. As a lower rupture rate is reported for inflammatory compared with non-inflammatory aneurysms, some assume that peri-aortic fibrosis actually protects against rupture.^{10,41} In rare cases, actual rupture follows shortly after commencing corticosteroid treatment.^{6,65} Therefore, if corticosteroid therapy is initiated, patients should be carefully followed and if signs of impending rupture such as increasing size or aortic wall thinning are demonstrated, surgical aneurysm repair should be undertaken.^{6,52,65} Another consideration is the increased risk of postoperative morbidity with prolonged corticosteroid use, notably through increased risk of infection and depressed wound healing. In addition, its long-term use is associated with accelerated atherosclerosis and an increased risk of cardiovascular death.⁶⁶

If (additional) medical treatment is considered, we prefer tamoxifen in patients with aneurysmal chronic peri-aortitis.⁶⁷ Contrary to corticosteroids, tamoxifen does not appear to have significant side effects which could complicate surgery and it may even have significant long-term cardioprotective effects.^{68,69} The pathophysiologic pathway by which tamoxifen exerts its effects in chronic peri-aortitis is unknown but is probably hormonal-independent.⁶⁷ Tamoxifen may alter the balance of growth factors such that fibroblast proliferation is inhibited.⁶⁷ The anti-oestrogen tamoxifen may also act as anti-inflammatory/immunosuppressive therapy, which would explain the observed decrease in acute-phase reactants and disappearance of pathologic Ga⁶⁷ activity.^{46,67} Its anti-oxidant and anti-angiogenic properties may also contribute to its efficacy.⁶⁷⁻⁶⁹ Experimentally, tamoxifen has been shown to attenuate development of AAAs.⁷⁰ However, as illustrated in case 1, chronic peri-aortitis may have a chronic-relapsing course and we do not yet have data on the long-term safety and efficacy of tamoxifen.

It should be noted that some use the term 'peri-aneurysmal fibrosis', where others use the term 'inflammatory aneurysm'. It is now clear that it is not aneurysmal formation *per se* but the presence of severe atherosclerosis that is the prerequisite to develop peri-aortic fibrosis in such patients.²⁻⁵ Idiopathic RPF and peri-aneurysmal fibrosis share similar clinical and histopathological features and are both thought to result from an exaggerated inflammatory response to advanced atherosclerosis.³⁻⁵ It is for these reasons that some prefer the term chronic peri-aortitis to encompass idiopathic RPF and peri-aneurysmal fibrosis.²⁻⁵ Perhaps most appropriately, conditions may be referred to as non-aneurysmal chronic peri-aortitis and aneurysmal chronic peri-aortitis. The increased incidence of RPF in men may well be explained by the higher incidence of symptomatic atherosclerotic disease in men. Some even suggest that the future of this disorder lies in the prevention and treatment of atherosclerosis.⁵ Smoking, a major risk factor for atherosclerotic AAA, has been shown to be an even stronger risk factor for the inflammatory variant.^{1,30} Cessation of smoking should therefore be strongly encouraged in all cases of chronic peri-aortitis.^{1,30}

In conclusion, open surgical aneurysm exclusion is superior to EVAR in achieving regression of peri-aortic fibrosis and resolution of ureteral obstruction in patients with aneurysmal chronic peri-aortitis. After excluding patients in whom concurrent ureterolysis was performed, the frequency of persistent ureteral obstruction remained lower in patients treated surgically compared to EVAR but was still relevant. Additional medical treatment, combined with renal drainage when needed, should be considered in selected cases of aneurysmal chronic peri-aortitis,

particularly when severe and/or bilateral ureteral obstruction and/or a large peri-aortic mass is (remains) present. This decision should probably also depend on the type of procedure (i.e. earlier with EVAR than with open surgery).

Acknowledgement

Conflict of interest: none.

References

- Hellman, DB, Grand, DJ, Freischlag, JA. Inflammatory abdominal aortic aneurysm. *JAMA* 2007; **297**: 395-400.
- Van Bommel, EFH. Retroperitoneal fibrosis. *Neth J Med* 2002; **60**: 231-242.
- Mitchinson, MJ. Retroperitoneal fibrosis revisited. *Arch Path Lab Med* 1986; **10**: 784-786.
- Parums, DV. The spectrum of chronic peri-aortitis. *Histopathology* 1990; **16**: 423-431.
- Baker, LRI. Auto-allergic periaortitis (idiopathic retroperitoneal fibrosis). *BJU Int* 2003; **92**: 663-665 (Editorial comment).
- Baskerville, PA, Blakeney, CG, Young, AE, Browse, NL. The diagnosis and treatment of peri-aortic fibrosis ('inflammatory' aneurysms). *Br J Surg* 1983; **70**: 381-385.
- Rastogi, AP, Reid, IS. Bilateral obstruction following aortic bypass surgery. *Clin Nephrol* 1980; **14**: 250-255.
- Vandendris, M, Grégoir, W. Ureteric obstruction secondary to aortic femoral bypass graft. *Eur Urol* 1976; **2**: 136-137.
- Tracy, DA, Eisenberg, RL, Hedgcock, MW. Ureteral obstruction from vascular prosthetic graft surgery. *AJR Am J Roentgenol* 1979; **132**: 415-418.
- Tang, T, Boyle, JR, Dixon, AK, Varty, K. Inflammatory abdominal aortic aneurysms. *Eur J Vasc Endovasc Surg* 2005; **29**: 353-362.
- Peterson, BG, Matsumura, JS, Brewster, DC, Makaroun, MS. Five-year report of a multicenter controlled clinical trial of open versus endovascular treatment of abdominal aortic aneurysms. *J Vasc Surg* 2007; **45**: 885-890.
- Norwood, MG, Lloyd, GM, Brown, MJ, Fishwick, G, London, NJ, Sayers, RD. Endovascular abdominal aortic aneurysm repair. *Postgrad Med J* 2007; **83**: 21-27.
- Teruya, TH, Abou-Zamzam, AM, Ballard, JL. Inflammatory abdominal aortic aneurysm treated by endovascular stent grafting. A case report. *Vasc Surg* 2001; **35**: 391-395.
- Ruppert, V, Verrel, F, Kellner, W, Brandl, T, Reininger, CB, Steckmeier, B. Endovascular repair of inflammatory abdominal aortic aneurysms: a valuable alternative? - case report and review of literature. *Ann Vasc Surg* 2004; **18**: 357-360.
- Rehring, TF, Brewster, DC, Kaufman, JA, Fan, CM, Geller, SC. Regression of perianeurysmal fibrosis and ureteral dilatation following endovascular repair of inflammatory abdominal aortic aneurysm. *Ann Vasc Surg* 2001; **15**: 591-593.
- Nevelsteen, A, Lacroix, H, Stockx, L, Baert, L, Depuydt, P. Inflammatory abdominal aortic aneurysm and bilateral

- complete ureteral obstruction: treatment by endovascular graft and bilateral ureteric stenting. *Ann Vasc Surg* 1999; **13**: 222–224.
- 17 Barrett, JA, Wells, IP, Roobottom, CA, Ashley, S. Progression of peri-aortic fibrosis despite endovascular repair of an inflammatory aneurysm. *Eur J Vasc Endovasc Surg* 2001; **21**: 567–568.
 - 18 Simons, PCG, van Overhagen, H, Bruijninx, CMA, Kropman, RF, Kuijpers, KC. Periaortitis with ureteral obstruction after endovascular repair of an abdominal aortic aneurysm. Case report. *AJR Am J Roentgenol* 2002; **179**: 118–120.
 - 19 Jetty, P, Barber, GG. Aortitis and bilateral ureteral obstruction after endovascular repair of abdominal aortic aneurysm. *J Vasc Surg* 2004; **39**: 1344–1347.
 - 20 Pennell, RC, Hollier, LH, Lie, JT, et al. Inflammatory abdominal aortic aneurysms: a thirty-year review. *J Vasc Surg* 1985; **2**: 859–869.
 - 21 Lindblad, B, Almgren, B, Bergqvist, D, et al. Abdominal aortic aneurysm with perianeurysmal fibrosis: experience from 11 Swedish vascular centers. *J Vasc Surg* 1991; **13**: 231–239.
 - 22 Railo, M, Isoluoma, M, Keto, P, Salo, JA. Surgical treatment of inflammatory abdominal aortic aneurysms: a long-term follow-up of 19 patients. *Ann Vasc Surg* 2005; **19**: 1–6.
 - 23 Yusuf, K, Murat, B, Unal, A, et al. Inflammatory abdominal aortic aneurysm: predictors of long-term outcome in a case-control study. *Surgery* 2007; **141**: 83–89.
 - 24 Todd, GJ, DeRose, JJ. Retroperitoneal approach for repair of inflammatory aortic aneurysms. *Ann Vasc Surg* 1995; **9**: 525–534.
 - 25 Puchner, S, Bucek, RA, Rand, T, et al. Endovascular therapy of inflammatory aortic aneurysms: a meta-analysis. *J Endovasc Ther* 2005; **12**: 560–567.
 - 26 Deleersnijder, R, Daenens, K, Fourneau, I, Maleux, G, Nevelsteen, A. Endovascular repair of inflammatory abdominal aortic aneurysms with special reference to concomitant ureteric obstruction. *Eur J Vasc Endovasc Surg* 2002; **24**: 146–149.
 - 27 Plate, G, Forsby, N, Stigsson, L, Sallstrom, J, Thorne, J. Management of inflammatory abdominal aortic aneurysm. *Acta Chir Scand* 1988; **154**: 19–24.
 - 28 Nachbur, B, Marincek, B, Jakob, R, Ackerman, D. The impact of computed tomography in the diagnosis and postoperative follow-up of ureteric obstruction in aorto-iliac aneurysmal disease. *Eur J Vasc Surg* 1989; **3**: 475–492.
 - 29 Stella, A, Gargiulo, M, Faggioli, GL, et al. Postoperative course of inflammatory abdominal aortic aneurysms. *Ann Vasc Surg* 1993; **7**: 229–238.
 - 30 Nitecki, SS, Hallett, JW, Stanson, AW, et al. Inflammatory abdominal aneurysms: a case-control study. *J Vasc Surg* 1996; **23**: 860–869.
 - 31 Bitsch, M, Norgaard, HH, Roder, O, Schroeder, TV, Lorentzen, JE. Inflammatory aortic aneurysms: regression of fibrosis after aneurysm surgery. *Eur J Vasc Endovasc Surg* 1997; **13**: 371–374.
 - 32 Koch, JA, Poll, L, Klinger, G, Kniemeyer, HW, Mödder, U. Intraoperative findings and postoperative CT-follow-up of inflammatory aortic aneurysms. *Fortschr Röntgenstr* 1998; **169**: 140–145 (German).
 - 33 Lacquet, JP, Lacroix, H, Nevelsteen, A, Suy, R. Inflammatory abdominal aortic aneurysms. A retrospective study of 110 cases. *Acta Chir Belg* 1997; **97**: 286–292.
 - 34 Dimakakos, PB, Kolokotronis, L, Kehagias, D, Katsoros, D. Management of inflammatory abdominal aneurysms – immediate and late results. *Swiss Surg* 1999; **5**: 18–22.
 - 35 Von Fritchen, U, Malzfeld, E, Clasen, A, Kortmann, H. Inflammatory abdominal aortic aneurysm: a postoperative course of retroperitoneal fibrosis. *J Vasc Surg* 1999; **30**: 1090–1098.
 - 36 Speziale, F, Sbarigia, E, Grossi, R, Maraglino, C, Fiorani, P. Inflammatory aneurysms of the abdominal aorta involving the ureters: is combined treatment really necessary. *J Urol* 2001; **165**: 27–31.
 - 37 Pistolese, GR, Ippoliti, A, Mauriello, A, Pistolese, C, Pocek, M, Simonetti, G. Postoperative regression of retroperitoneal fibrosis in patients with inflammatory abdominal aortic aneurysms. Evaluation with spiral computed tomography. *Ann Vasc Surg* 2002; **16**: 201–209.
 - 38 Arroyo, A, Rodriguez, J, Porto, J, Gesto, R. Management and course of hydronephrosis secondary to inflammatory aneurysms of the abdominal aorta. *Ann Vasc Surg* 2003; **17**: 481–485.
 - 39 Ockert, S, Schumacher, H, Böckler, D, Ganten, M, Seelos, R, Allenberg, J. Long-term outcome of operated inflammatory aortic aneurysms. *Vascular* 2006; **14**: 206–211.
 - 40 Vallabhaneni, SR, McWilliams, RG, Anbarasu, A, et al. Perianeurysmal fibrosis: a relative contra-indication to endovascular repair. *Eur J Vasc Endovasc Surg* 2001; **22**: 535–541.
 - 41 Hinchliffe, RJ, Macierewicz, JA, Hopkinson, BR. Endovascular repair of inflammatory abdominal aortic aneurysms. *J Endovasc Ther* 2002; **9**: 277–281.
 - 42 Puchner, S, Bucek, RA, Loewe, C, et al. Endovascular repair of inflammatory aortic aneurysms: long-term results. *AJR Am J Roentgenol* 2006; **186**: 1144–1147.
 - 43 Hechelhammer, L, Wildermuth, S, Lachat, ML, Pfammatter, T. Endovascular repair of inflammatory abdominal aneurysm: a retrospective analysis of CT follow-up. *J Vasc Interv Radiol* 2005; **16**: 737–741.
 - 44 Faizer, R, DeRose, G, Forbes, TL, et al. Midterm follow-up of inflammatory abdominal aortic aneurysms following endovascular repair. *Ann Vasc Surg* 2005; **19**: 636–640.
 - 45 Lange, C, Hobo, R, Leurs, LJ, Daenens, K, Buth, J, Myhre, HO. Results of endovascular repair of inflammatory abdominal aortic aneurysms. A report from the EUROSTAR database. *Eur J Vasc Endovasc Surg* 2005; **29**: 363–370.
 - 46 Van Bommel, EF, Siemes, C, van der Veer, SJ, Han, SH, Huiskes, AW, Hendriksz, TR. Clinical value of gallium-67 SPECT scintigraphy in the diagnostic and therapeutic evaluation of retroperitoneal fibrosis. A prospective study. *J Intern Med* 2007; **262**: 224–234.
 - 47 Nakajo, M, Jinnouchi, S, Tanabe, H, Tateno, R, Nakajo, M. 18F-fluorodeoxyglucose positron emission tomography features of idiopathic retroperitoneal fibrosis. *J Comput Assist Tomogr* 2007; **31**: 539–543.
 - 48 York, JW, Money, SR. Prevention and management of ureteral injuries during aortic surgery. *Semin Vasc Surg* 2001; **14**: 266–274.
 - 49 Van Bommel, EFH, Siemes, C, Hak, AE, van de Veer, SJ, Hendriksz, TR. Long-term renal and patient outcome in idiopathic retroperitoneal fibrosis treated with prednisone. *Am J Kidney Dis* 2007; **49**: 615–625.

- 50 Lederle, FA, Kanee, RL, MacDonald, R, Wilt, TJ. Systematic review: repair of unruptured abdominal aortic aneurysm. *Ann Intern Med* 2007; **146**: 735–741.
- 51 Clyne, CAC, Abercrombie, GF. Perianeurysmal retroperitoneal fibrosis: two cases responding to steroids. *Br J Urol* 1977; **49**: 463–467.
- 52 Hedges, AR, Bentley, PG. Resection of inflammatory aneurysm after steroid therapy. *Br J Surg* 1986; **73**: 374.
- 53 Stotter, AT, Grigg, MJ, Mansfield, K. The response of perianeurysmal – the ‘inflammatory’ aneurysm – to surgery and steroid therapy. *Eur J Vasc Surg* 1990; **4**: 201–205.
- 54 Soury, P, Peillon, C, Melki, J, Riviere, J, Watelet, J, Testart, J. Apropos of an inflammatory aneurysm of the abdominal aorta revealed by anuria. *Ann Chir* 1999; **49**: 327–330 (French).
- 55 Sumino, H, Kanda, T, Nakamura, T, *et al.* Steroid therapy is effective in a young patient with an inflammatory abdominal aortic aneurysm. *J Med* 1999; **20**: 67–74.
- 56 Testart, J, Plissier, P, Peillon, C, Watelet, J. Inflammatory abdominal aortic aneurysm. Role of corticosteroid therapy. *J Mal Vasc* 2000; **25**: 201–207 (French).
- 57 Hoffmeister, AW. Inflammatory aneurysm of the infrarenal aorta. *Chirurg* 1990; **6**: 168–170 (German).
- 58 Hausegger, KA, Portugaller, HR. Percutaneous nephrostomy and antegrade ureteral stenting: technique-indications-complications. *Eur Radiol* 2006; **16**: 2016–2030.
- 59 Lawrentschuk, N, Russell, JM. Ureteric stenting 25 years on: routine or risky. *ANZ J Surg* 2004; **74**: 243–247.
- 60 Sacks, D, Miller, J. Ureteral leak around an aortic bifurcation graft: complication of ureteral stenting. *J Urol* 1988; **140**: 1526–1528.
- 61 Meester, DJ, van Muiswinkel, KW, Ameye, F, *et al.* Endovascular treatment of a ureteroiliac fistula associated with ureteral double J-stenting and an aortic-bifemoral stent graft for an inflammatory abdominal aortic aneurysm. *Ann Vasc Surg* 2006; **20**: 408–410.
- 62 Krambeck, AE, DiMarco, DS, Gettman, MT, Segura, JW. Ureteroiliac fistula: diagnosis and treatment algorithm. *Urology* 2005; **66**: 990–994.
- 63 Eliason, JL, Clouse, WD. Current management of infrarenal abdominal aortic aneurysms. *Surg Clin North Am* 2007; **87**: 1017–1033.
- 64 Brewster, DC, Jones, JE, Chung, TK, *et al.* Long-term outcomes after endovascular abdominal aortic aneurysm repair: the first decade. *Ann Surg* 2006; **244**: 426–438.
- 65 Thompson, JF, Chant, ADB. Non-operative management of perianeurysmal fibrosis. *BMJ* 1988; **297**: 857.
- 66 Wei, L, MacDonald, TM, Walker, BR. Taking glucocorticoids by prescription is associated with subsequent cardiovascular disease. *Ann Intern Med* 2004; **141**: 764–770.
- 67 Van Bommel, EFH, Hendriksz, TR, Huiskes, AWLC, Zeegers, AGM. Tamoxifen therapy for non-malignant retroperitoneal fibrosis. *Ann Intern Med* 2006; **144**: 101–106.
- 68 Grainger, DJ, Schofield, PM. Tamoxifen for the prevention of myocardial infarction in humans: preclinical and early clinical evidence. *Circulation* 2005; **112**: 3018–3024.
- 69 Van Bommel, EFH, Hendriksz, TR. Tamoxifen therapy for non-malignant retroperitoneal fibrosis. *Ann Intern Med* 2006; **144**: 619–620 (Author’s reply).
- 70 Grigoryants, V, Hannawa, KK, Pearce, CG, *et al.* Tamoxifen upregulates catalase production, inhibits vessel wall neutrophil infiltration, and attenuates development of experimental abdominal aortic aneurysms. *J Vasc Surg* 2005; **41**: 1108–1114.