



HAL
open science

Acute lower limb ischemia as the initial symptom of acute myeloid leukemia

Alexandros Kafetzakis, Andreas Foundoulakis, Christos V Ioannou, Emilia Stavroulaki, Anastassios Koutsopoulos, Asterios N Katsamouris

► **To cite this version:**

Alexandros Kafetzakis, Andreas Foundoulakis, Christos V Ioannou, Emilia Stavroulaki, Anastassios Koutsopoulos, et al.. Acute lower limb ischemia as the initial symptom of acute myeloid leukemia. *Vascular Medicine*, 2007, 12 (3), pp.199-202. 10.1177/1358863X07080630 . hal-00571360

HAL Id: hal-00571360

<https://hal.science/hal-00571360>

Submitted on 1 Mar 2011

HAL is a multi-disciplinary open access archive for the deposit and dissemination of scientific research documents, whether they are published or not. The documents may come from teaching and research institutions in France or abroad, or from public or private research centers.

L'archive ouverte pluridisciplinaire **HAL**, est destinée au dépôt et à la diffusion de documents scientifiques de niveau recherche, publiés ou non, émanant des établissements d'enseignement et de recherche français ou étrangers, des laboratoires publics ou privés.

Acute lower limb ischemia as the initial symptom of acute myeloid leukemia

Alexandros Kafetzakis^a, Andreas Foundoulakis^b, Christos V Ioannou^a, Emilia Stavroulaki^b, Anastassios Koutsopoulos^c and Asterios N Katsamouris^a

Abstract: Although coagulatory system disorders are well recognized in patients with acute leukemia, these usually present with either hemorrhagic complications or thrombosis of small vessels. Large vessel thrombosis is a very rare clinical presentation. We present a patient with previously undiagnosed acute myeloid leukemia (M5), who was referred to our hospital with symptoms of acute ischemia of his right lower limb. Occlusion of the right external iliac artery due to a combination of leucostasis and coagulation disorders was noted and successfully treated with urgent leukapheresis, immediate chemotherapy and surgical thromboembolectomy.

Key words: arterial thromboembolic disease; leucostasis; leukapheresis

Introduction

Although disorders of the coagulation system are well recognized in patients with acute leukemia, these usually present with hemorrhagic complications or thrombosis of small vessels. Large vessel thrombosis is a very rare complication. To our knowledge, there are only nine cases reported in the English literature of acute leukemia presenting as acute lower limb ischemia due to large artery occlusion.

This report describes a patient who was admitted to our hospital under this clinical scenario and was discharged with complete remission without amputation at any level.

Case report

A 57-year-old Caucasian ex-smoker (45 pack-years) with a previous history of chronic obstructive pulmonary disease presented in the emergency department with a 6-hour progressive history of coolness, pallor and pain of the right (Rt) lower limb. He had no history of previous claudication. Clinical examination

was unremarkable apart from the findings in the Rt leg. Electrocardiography revealed a regular sinus cardiac rhythm. The Rt leg was cool and pallid with mild sensory loss of the toes, without any motor deficits. The left leg was absolutely normal. Pulses were palpable in all arteries of his left lower limb whereas palpable pulses were found only in the Rt femoral artery. The ankle-brachial pressure index (ABPI) of the left limb was 1.0 (120 mmHg/120 mmHg) and of the right limb was 0.2 (25 mmHg/120 mmHg).

Blood analysis revealed a hematocrit of 33.9% (normal values [NV] 37–47%), platelet count of 50×10^3 (NV: $150\text{--}450 \times 10^3$), white blood cell count (WBC) of 120 300 cells/ μl (95% blasts) (NV: $3.8\text{--}10.5 \times 10^3$ cells/ μl), INR of 1.37 (NV: 0.85–1.15), aPTT of 43.2 s (NV: 28–40 s), D-dimers $>20 \mu\text{g/ml}$ (NV: 0.0–0.5 $\mu\text{g/ml}$) and fibrinogen of 196 mg/dl (NV: 200–400 mg/dl). In view of these results, an emergent arterial angiography was avoided. Duplex ultrasonography revealed normal flow waveforms up to the level of the popliteal artery, occlusion of the tibioperoneal trunk and single-phase flow in the anterior tibial artery. Since the limb was still viable and the coagulation status precluded thrombolysis, the patient was admitted to the hematology–oncology department for heparinization and leukapheresis because of possible leucostasis. After this procedure the WBC fell to 50 000 cells/ μl . Under the provisional morphological diagnosis of acute myeloid leukemia (AML), chemotherapy with AML protocol was initiated (idarubicin $12 \text{ mg/m}^2/24 \text{ h}$ for 3 days followed by cytarabine $200 \text{ mg/m}^2/24 \text{ h}$ for 7 days). The immunophenotypic analysis revealed a unique blast population compatible with AML-M5.

^aVascular Surgery Division, ^bDepartment of Hematology-Oncology and ^cDepartment of Pathology, University of Crete Medical School, Heraklion, Greece

Address for correspondence: Asterios Katsamouris, Vascular Surgery Division, University of Crete Medical School, PO Box 1352, 711 10, Heraklion, Crete, Greece. Tel: +30 2810 392 379 or +30 6932 277 357; Fax: +30 2810 542 063 or +30 2810 392 379; E-mail: asterios@med.uoc.gr

The next day, the lower limb showed clinical deterioration and now had rest pain. The pulses were no longer palpable in the Rt femoral artery and Doppler signals were no longer audible at the femoral level and distally. This clinical deterioration was obviously due to a new thrombotic event. Without having any blood or blood product transfusions, laboratory results were hematocrit: 32%; platelet count: 53×10^3 ; INR: 1.35; aPTT: 38.4 s. Despite any risk of possible hemorrhagic complications, an emergency Rt iliofemoral and femoral-popliteal arterial thromboembolectomy was performed under local anesthesia in an effort to salvage the limb. A white-clot plug was removed from the bifurcation of the Rt common iliac artery (Figure 1A). An improvement of perfusion of the lower limb was noted immediately after the procedure, with restoration of palpable pulses on the dorsalis pedis and posterior tibial arteries as well as restoration of a normal ABPI. Histological examination of the clot revealed cells with similar characteristics with those of AML-M5 cells (Figure 1B).

Complete remission was achieved after the completion of chemotherapy within the next 10 days, without recurrence of further arterial insufficiency, and the patient was discharged after 20 days of hospitalization. At 3 months the patient remains free of symptoms, without any sign of claudication and with complete recovery of initial sensory loss as confirmed after clinical evaluation. Antiplatelet therapy was not prescribed due to an increased risk of hemorrhaging because of a decrease in the platelet count following chemotherapy.

Discussion

Ischemic events in acute leukemia usually involve small vessels of the brain, spleen and lungs. Only nine cases of lower limb ischemia resulting from large arterial occlusion have been presented in the past

(Table 1). In the first case, the affected artery was the aorta¹ and in the second one the external iliac, the profunda femoral and all tibial arteries.² In both cases, leucostasis was the mechanism of ischemia. This is of interest since the most common cause of acute ischemia in acute lymphoblastic leukemia is arterial embolism in patients being actively treated with L-asparaginase or other chemotherapeutic regimens who have associated depression of antithrombin III, plasminogen, fibrinogen and coagulation factor levels. The patients in these case reports had not received any treatment previously and no evidence of coagulopathy was present.

The next three cases involved acute promyelocytic leukemia where the mechanism of ischemia was disseminated intravascular coagulation (DIC).³⁻⁵ In one case with acute promyelocytic leukemia⁶ and in three cases⁷⁻⁹ involving AML, the mechanism of lower limb ischemia was leucostasis and subsequent occlusion of an artery by leukemia cells.

The case reported here is interesting in many respects. First, acute ischemia of the lower limb was the presenting symptom of AML in this patient who had no previous history of fever, weight loss, petechia or other hematologic disorders, which is highly unusual. Moreover, the FAB type of leukemia in our patient was M5. According to the FAB classification, M5 is the monocytic variant of AML. There are two subtypes: M5a (monoblastic variant) and M5b (monocytic variant). This type of leukemia develops leukocytosis in 10–30% of patients as well as a relatively high frequency of DIC. The excessive numbers of leukocytes may seriously affect arterial flow by obstructing microchannels or by forming aggregates and white thrombi. Moreover, leukemic blasts may compete for oxygen in the microcirculation, damaging vessel walls.¹⁰ The above, of course, occur in small and medium size arteries, whereas the exact mechanism of clot/emboli development is poorly understood. One may hypothesize that abnormal accumulation of

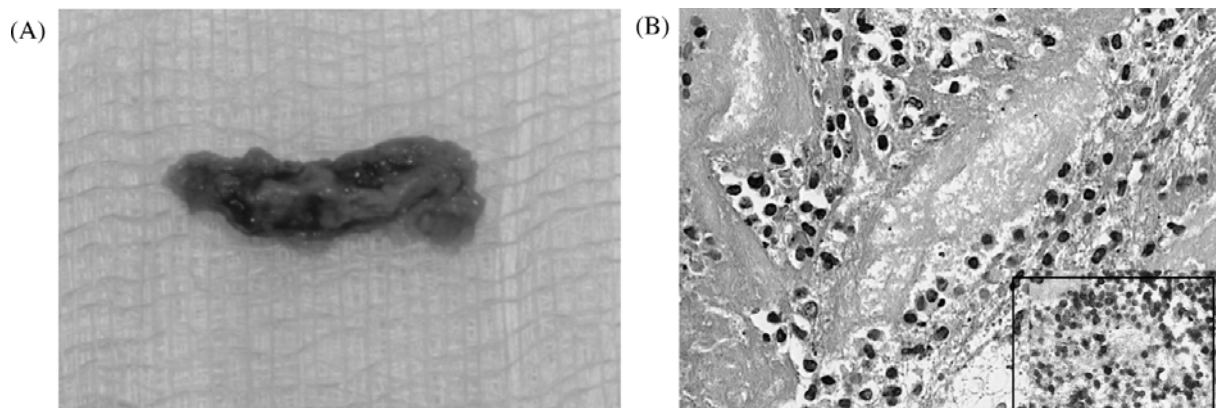


Figure 1 (A) Section of arterial white embolus; (B) showing fibrin material in which isolated or small groups of large monoblastic cells are recognized (hematoxylin & eosin, $\times 400$) that are positive in CD68 monoclonal antibody (KP1 clone $\times 400$) (insert).

Table 1 All reported cases of acute lower limb ischemia due to large artery occlusion: treatment and outcome.

Ref. no.	First author	Age (years) / sex	Type of leukemia	Affected artery	Therapy	Outcome / comments
1	Brinson	36 / M	ALL	Aorta and common iliac artery occlusion	Aortic thrombectomy	Acute renal insufficiency, paraplegia
2	Redmond	28 / M	ALL	Non-occlusive thrombosis of the right external iliac artery Right profunda and tibial artery occlusion	Thrombolysis and intravenous heparin therapy	Below-knee amputation
3	Rolston	16 / M	APL (M3)	Left common iliac occlusion	Iliofemoral arterial thrombectomy	Discharged – no amputation
4	DiGiovanni	16 / M	APL (M3)	Left superficial femoral artery	Femoral thrombo-embolctomy	Discharged – no amputation
5	Kalk	47 / F	APL (M3)	Right popliteal artery obstruction	Conservative	Minor (toe) amputation
6	Fass	10 / M	APL (M3)	Left femoral and iliac arteries	Iliofemoral arterial thrombectomy	Recurrence of ischemia – new transfemoral and transpopliteal thrombectomy
7	Kootte	42 / F	AML (M2)	Aorta and right common iliac occlusion	Aortic thrombectomy	Death
8	Campbell	NR	AML (M2)	Superficial femoral artery obstruction	Conservative	Discharged – no amputation
9	Mataix	42 / –	AML (M2)	Popliteal artery obstruction	Thrombolysis (unsuccessful) Multiple thrombo-embolctomies	Supracondylar amputation
10	Our case	57 / M	AML (M5)	Right common iliac occlusion	Iliofemoral arterial thrombectomy	Discharged – no amputation

M, male; ALL, acute lymphoblastic leukemia; APL, acute promyelocytic leukemia; F, female; AML, acute myelocytic leukemia; NR, not reported.

lymphocytes may initially cause the sedimentation of leukemic cells which may then trigger the accumulation of platelets, thus forming a white clot. This clot may form in any part of the arterial tree, though it is usually seen in the periphery (smaller vessels). If the clot is formed in a larger artery then it will of course flow downstream until it is lodged at an artery of smaller diameter or, as usually seen, at a bifurcation site. In general, the embolic material is composed of a mixture of leukemic cells and thrombus, but the amount contained of the two varies among patients.

Treatment of this patient was challenging since, unlike the previously presented cases, he exhibited both leucostasis and coagulation disorders that precluded the use of thrombolytic therapy and interventional radiology. Despite the above-mentioned difficulties, this patient was successfully treated without recurrence of ischemia or amputation at any level. Treatment was rapidly undertaken with urgent leukapheresis and prompt initiation of chemotherapy in this

patient in an effort to inhibit any further sedimentation. Despite these therapies, the patient required emergency surgery the following day because of limb deterioration and the presentation of limb-threatening ischemia. Though we cannot draw a definite conclusion from just one case, it is our feeling that leukapheresis and chemotherapy may aid in avoiding thromboembolic recurrence. This is in agreement with Fass et al⁶ who attributed the unsuccessful outcome of their patient to delayed initiation of chemotherapy and quoted: 'if remission could have been induced earlier, after initiation of chemotherapy, further propagation of the pathological sedimentation might have been obviated'. To the best of our knowledge there are no articles reporting on the proper approach for treating acute arterial occlusions due to leukemic cells because such embolic occlusions of large arteries are very rare.

Taking into account that thrombolytic therapy is usually not feasible or is unsuccessful and that heparinization is ineffective in these patients, we

believe that combined leukapheresis and chemotherapy is the first therapeutic choice unless the limb is immediately threatened. Despite the possibility of coagulation disorders which often cause difficult to control hemorrhage or recurrent thromboembolic events, prompt surgical thromboembolectomy or revascularization should be attempted in such cases presenting with limb-threatening ischemia.

References

- 1 Brinson R, Garcia G. Acute lymphoblastic leukemia manifested as aortic occlusion. *Am J Med* 1984; **77**: 385–87.
- 2 Redmond EJ, Welch M, Durrans D et al. Acute ischaemia of the lower limb: an unusual presenting feature of acute lymphoblastic leukemia. *Eur J Vasc Surg* 1993; **7**: 750–52.
- 3 Rolston DD, Rubin S, Topolsky D, Styler M, Grilley P. Arterial occlusions as a presenting feature of acute promyelocytic leukemia. *Am J Clin Oncol* 1998; **21**: 436–37.
- 4 DiGiovanni RJ Jr, Crilley P, Kerstein MD. Peripheral arterial occlusion in acute promyelocytic leukemia. *Cardiovasc Surg* 1999; **7**: 258–60.
- 5 Kalk E, Goede A, Rose P. Acute arterial thrombosis in acute promyelocytic leukemia. *Clin Lab Haematol* 2003; **25**: 267–70.
- 6 Fass R, Haddad M, Zaizov R et al. Recurrent peripheral arterial occlusion by leukemic cells sedimentation in acute promyelocytic leukemia. *J Pediatr Surg* 1992; **27**: 665–67.
- 7 Kootte A, Thompson J, Bruijn J. Acute myelocytic leukemia with acute aortic occlusion as presenting symptom. *Acta Haematol* 1986; **75**: 120–21.
- 8 Campbell J, Mitchell C. Acute leg ischaemia as a manifestation of the hyperleukocytosis syndrome in acute myeloid leukemia. *Am J Hematol* 1994; **46**: 167.
- 9 Mataix R, Gomez-Casares MT, Campo C, Malcorra J. Acute leg ischaemia as a presentation of the hyperleukocytosis syndrome in acute myeloid leukemia. *Am J Hematol* 1996; **51**: 250.
- 10 Litchman MA, Rowe JM. Hyperleukocytic leukemias: rheological, clinical, and therapeutic considerations. *Blood* 1982; **60**: 279–83.