



HAL
open science

Images in vascular medicine

Raghu Kolluri, Onsi Kamel

► **To cite this version:**

Raghu Kolluri, Onsi Kamel. Images in vascular medicine. *Vascular Medicine*, 2007, 12 (3), pp.255-256. 10.1177/1358863X07080566 . hal-00571359

HAL Id: hal-00571359

<https://hal.science/hal-00571359>

Submitted on 1 Mar 2011

HAL is a multi-disciplinary open access archive for the deposit and dissemination of scientific research documents, whether they are published or not. The documents may come from teaching and research institutions in France or abroad, or from public or private research centers.

L'archive ouverte pluridisciplinaire **HAL**, est destinée au dépôt et à la diffusion de documents scientifiques de niveau recherche, publiés ou non, émanant des établissements d'enseignement et de recherche français ou étrangers, des laboratoires publics ou privés.

Images in vascular medicine

Unusual etiology of painful leg ulcers

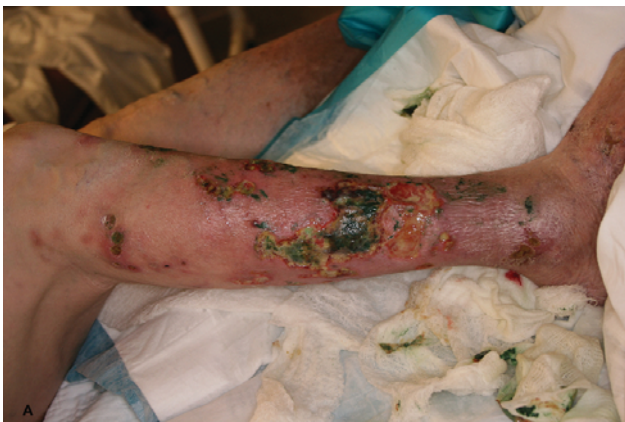Raghu Kolluri^a and Onsi Kamel^b

A 61-year-old Caucasian female with prior history of bilateral femoro-popliteal bypass grafts, chronic venous insufficiency and long-standing rheumatoid arthritis was admitted with painful bilateral lower extremity ulcerations. Presumptive diagnosis of infected venous or vasculitic ulcers was made and vascular medicine consultation was obtained. Anterolateral aspects of bilateral lower extremities were erythematous and revealed several tender ulcers with well-defined edges. The ulcer bases were composed of predominantly pale granulation tissue and serous discharge (Panel A). Ankle-brachial index and toe pressures were normal at rest. Pertinent laboratory results included a rheumatoid factor of 392 IU/ml and a Westergren sedimentation rate of 115 mm/h. The serum cryoglobulins, C-ANCA, P-ANCA and complement levels (C3/C4) were within normal limits. An MRI did not suggest osteomyelitis. A wound biopsy was requested due to the atypical nature

of the ulcers and revealed cutaneous large T-cell lymphoma. Panel B shows the microscopic appearance of the large T-cell lymphoma with angioinvasive features. Beneath an ulcerated epidermis, malignant lymphoid cells infiltrate the deep dermis and subcutis and invade small and medium-sized arterioles in the deep dermis (1: hematoxylin and eosin, $\times 200$). At higher magnification, the cells have a large cell morphology (2: hematoxylin and eosin, $\times 400$). Immunohistochemistry for the T-cell-associated antigen CD3 shows a brown colorimetric reaction decorating the cytoplasmic membranes of the neoplastic cells (3: anti-CD3, $\times 400$).

CHOP chemotherapy was started but she died several months after the diagnosis.

Malignant transformation of chronic ulcers is well documented, although uncommon.¹ Patients with rheumatoid arthritis frequently present with leg ulceration² and are at increased risk for lymphoma.³

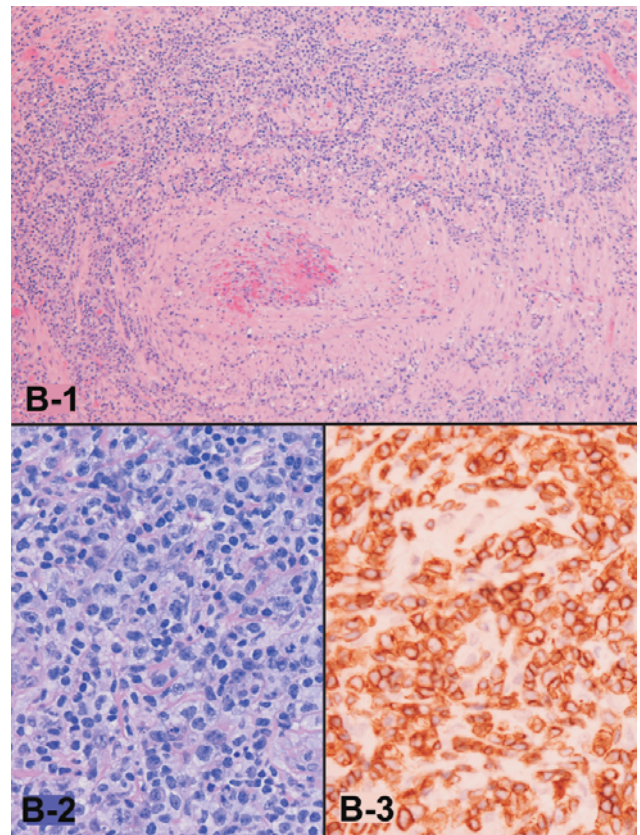


Panel A

'Images in vascular medicine' is a regular feature of *Vascular Medicine*. Readers may submit original, unpublished images related to clinical vascular medicine to: Mark A Creager, Editor in Chief, *Vascular Medicine*, Brigham and Women's Hospital, 75 Francis Street, Boston, MA 02115, USA.

^aPrairie Vascular Institute and ^bDepartment of Pathology, St John's Hospital, Springfield, IL, USA

Address for correspondence: Raghu Kolluri, Prairie Vascular Institute, 401 East Carpenter St, Springfield, IL 62702, USA. Tel: +1 217 788 0706; Fax: +1 217 523 4520; E-mail: rkolluri@prairieheart.com



Panel B

This underscores the importance of tissue biopsy in chronic ulcerations with atypical appearance and in unusual locations.

References

- 1 Mekkes JR, Loots MA, Van Der Wal AC, Bos JD. Causes, investigation and treatment of leg ulceration. *Br J Dermatol* 2003; **148**: 388–401.
- 2 Oien RF, Hakansson A, Hansen BU. Leg ulcers in patients with rheumatoid arthritis – a prospective study of aetiology, wound healing and pain reduction after pinch grafting. *Rheumatology (Oxford)* 2001; **40**: 816–20.
- 3 Askling J, Fored CM, Baecklund E et al. Haematopoietic malignancies in rheumatoid arthritis: lymphoma risk and characteristics after exposure to tumour necrosis factor antagonists. *Ann Rheum Dis* 2005; **64**: 1414–20.