



HAL
open science

Current state of endovascular treatment of femoro-popliteal artery disease

Thomas Zeller

► **To cite this version:**

Thomas Zeller. Current state of endovascular treatment of femoro-popliteal artery disease. *Vascular Medicine*, 2007, 12 (3), pp.223-234. 10.1177/1358863X07079823 . hal-00571358

HAL Id: hal-00571358

<https://hal.science/hal-00571358>

Submitted on 1 Mar 2011

HAL is a multi-disciplinary open access archive for the deposit and dissemination of scientific research documents, whether they are published or not. The documents may come from teaching and research institutions in France or abroad, or from public or private research centers.

L'archive ouverte pluridisciplinaire **HAL**, est destinée au dépôt et à la diffusion de documents scientifiques de niveau recherche, publiés ou non, émanant des établissements d'enseignement et de recherche français ou étrangers, des laboratoires publics ou privés.

Current state of endovascular treatment of femoro-popliteal artery disease

Thomas Zeller

Abstract: Considerable advances have been made over the last decade in percutaneous technology for the treatment of atherosclerotic diseases in the femoro-popliteal arteries. While treatment strategies are well defined in the iliac segment, where angioplasty and stenting perform well in appropriately selected lesions, the search for a durable transcatheter therapy for femoro-popliteal lesions continues. Whereas balloon angioplasty (PTA) is the accepted therapy for short lesions, long diffuse lesions are still recommended for surgical treatment. However, attractive new technologies ranging from transcatheter plaque excision to laser ablation, rotational atherectomy, cryoplasty, brachytherapy, and placement of drug-eluting stents to simple angioplasty with drug-coated balloons may have the potential to replace femoro-popliteal bypass surgery as a treatment of choice for complex lesions. This article reviews the status of percutaneous endovascular techniques for the treatment of femoro-popliteal artery occlusive disease.

Key words: angioplasty; percutaneous intervention; peripheral occlusive disease; popliteal artery; stent; superficial femoral artery

Introduction

Peripheral arterial disease (PAD) is one of the major manifestations of systemic atherosclerosis estimated to be present in 3% of people in the age range 40–59 years and in 20% of people over 70 years.^{1,2} Approximately 5% of the patients with PAD will progress from intermittent claudication to critical limb ischaemia (CLI) in the due course of their disease. The risk factors that lead to this advanced form of PAD are advanced age, tobacco use and diabetes mellitus. Patients on dialysis are also at increased risk of presenting with CLI.^{3–5} CLI is associated with an extremely poor prognosis with a mortality rate of 25.0% at 1 year.^{3,6–8} Significant mortality is due to coexistent cardiovascular and cerebral-vascular diseases.

Anatomically, approximately 30% of the arterial lesions are located in the iliac arteries, 70% in the femoro-popliteal and tibial tract. Isolated lesions below the knee are present in only 15% of the cases. Approximately 30% of the symptomatic PAD patients

have diffuse arterial disease, and the majority of CLI patients, most of whom are diabetic, have distal arterial disease with occlusions in the tibial arteries.

The primary goal of any treatment of patients with PAD will be either limb salvage or relief of significant lifestyle-limiting symptoms. Surgery has long been considered the gold standard treatment when symptoms could not be controlled by risk factor modification, exercise therapy or medication. With the introduction of new interventional techniques and devices, some caused by coronary intervention, acute treatment success and durability of endovascular technology has improved during the last decade. As a result, endovascular intervention has become a first-line therapy to treat PAD and even complex arterial diseases.

Definitions of long-term durability of endovascular procedures

Study reports on the durability of endovascular femoro-popliteal interventions use different terms to describe sustained treatment success. The most important term is 'primary patency', defined as exempt from restenosis of the target lesion during follow-up. 'Primary assisted patency' is defined as patency of the target lesion following endovascular reintervention at the target vessel site in case of symptomatic restenosis. 'Secondary patency' reports patency of the target lesion after treatment of a (re)occlusion of the index lesion. A reintervention at the index lesion site is

Albert-Ludwigs-University Freiburg, Freiburg, Germany and Department of Angiology, Herz-Zentrum Bad Krozingen, Bad Krozingen, Germany

Address for correspondence: Thomas Zeller, Abteilung Angiologie, Herz-Zentrum Bad Krozingen, Südring 15, D-79189 Bad Krozingen, Germany. Tel: +49 7633/4020; Fax: +49 7633/402-8208; E-mail: thomas.zeller@herzzentrum.de

defined as target lesion revascularization (TLR). If another lesion at the target vessel site but not the index lesion itself needs to be treated during follow-up this intervention is defined as target vessel revascularization (TVR).

Superficial femoral artery and popliteal artery disease

The superficial femoral artery (SFA) extending to the proximal popliteal artery segment is the most commonly diseased vasculature. More than 50% of all PAD cases involve the SFA and popliteal artery. Femoro-popliteal disease is often characterized by long, diffuse lesions, long occlusions (as opposed to mild focal stenoses). The unique slow-flow and high-resistance environment in the femoro-popliteal region creates a milieu that seems to increase the prevalence of de novo disease. The same issues that lead to accumulation of plaque within the femoro-popliteal region likely amplify the response to injury and may explain the high incidence of restenosis following traditional angioplasty.⁹ Femoro-popliteal occlusive disease is still the Achilles heel of the vascular specialist.

The durability of femoro-popliteal intervention can be predicted by the pre-procedural angiographic characteristics of the target lesion. The TASC I and the

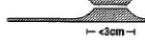
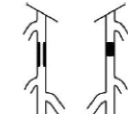
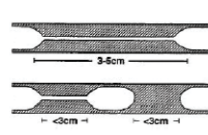
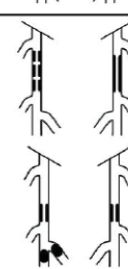
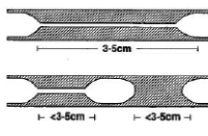
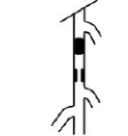

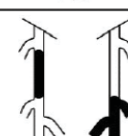
updated TASC II document⁶ divided the femoro-popliteal lesions into four categories (Table 1). TASC A lesions are more suitable for endovascular procedures, whereas surgery is recommended for TASC D lesions. The TASC document clearly states that it takes more evidence to make firm recommendations about the role of angioplasty (PTA) for TASC B and C lesions.

Indications for therapy in femoro-popliteal disease

During the last 2 years, the updated TASC consensus paper⁶ and the ACC/AHA guidelines for the management of patients with PAD⁷ have been published, including literature survey-based recommendations on the treatment of femoro-popliteal artery disease.

Charles Dotter performed the first SFA angioplasty with sequential dilators in 1964.¹⁰ Four decades later, we still continue searching a durable endovascular technology for long complex lesions in the femoro-popliteal segment. With the help of today's available techniques almost all stenoses and at least 90% of occlusions can be reopened. In case of failure to cross a chronic total occlusion with a guidewire, a retrograde popliteal access or the utilization of one of the recently

Table 1 Comparison between TASC I and TASC II recommendations for femoro-popliteal lesions.

TASC 2000: J.Vasc.Surg. 2000;31(1 Pt 2):S104 Fig. 22; Recommendation 34/35; crit issue 14: Morphological stratification and treatment of femoropopliteal lesions		TASC II 2007: Europ J Vasc Endovasc Surg 2007;33(suppl 1): S58-S59 Fig. F2 and Tab. F2; Recommendation 37: TASC classification and treatment of femoral popliteal lesions	
<p>TASC type A lesions: Endovascular treatment of choice</p> <p>1. Single stenosis up to 3 cm in length, not at the origin of the superficial femoral artery or the distal popliteal artery</p>		<p>TASC type A lesions: Endovascular therapy is the treatment of choice</p> <p>1. Single stenosis ≤ 10 cm in length 2. Single occlusion ≤ 5 cm in length</p>	
<p>TASC type B lesions: Currently, endovascular treatment is more often used but insufficient evidence to make recommendation</p> <p>2. Single stenoses or occlusions 3–5 cm long, not involving the distal popliteal artery* 3. Heavily calcified stenoses up to 3 cm in length 4. Multiple lesions, each less than 3 cm (stenoses or occlusions) 5. Single or multiple lesions in the absence of continuous tibial runoff to improve inflow for distal surgical bypass</p>		<p>TASC type B lesions: Endovascular treatment is the preferred treatment.**</p> <p>3. Multiple lesions, each ≤ 5 cm (stenoses or occlusions) 4. Single stenosis or occlusion ≤ 15 cm, not involving the infra geniculate popliteal artery 5. Single or multiple lesions in the absence of continuous tibial vessels to improve inflow for a distal bypass 6. Heavily calcified occlusions ≤ 5 cm in length 7. Single popliteal stenosis</p>	
<p>TASC type C lesions: Currently, surgical treatment is more often used but insufficient evidence to make recommendation</p> <p>6. Single stenosis or occlusion longer than 5 cm* 7. Multiple stenoses or occlusions, each 3–5 cm, with or without heavy calcification</p>		<p>TASC type C lesions: Surgery is the preferred treatment for good-risk patients.**</p> <p>8. Multiple stenoses or occlusions, totalling > 15 cm, with or without heavy calcification 9. Recurrent stenoses or occlusions that need treatment after two endovascular interventions</p>	
<p>TASC type D lesions: Surgical treatment of choice</p> <p>8. Complete common femoral artery or superficial artery occlusions or complete popliteal and proximal trifurcation occlusions.</p>		<p>TASC type D lesions: Surgery is the treatment of choice</p> <p>10. Chronic total occlusion of the CFA or SFA (> 20 cm, involving the popliteal artery) 11. Chronic total occlusion of popliteal artery and proximal trifurcation vessels.</p>	
<p>*CIRSE agrees except for the following changes: Type B femoropopliteal lesions: 2. Single stenoses or occlusions 3–10 cm long, not involving the distal popliteal artery Type C femoropopliteal lesions: 6. Single stenosis or occlusion > 10 cm long</p>		<p>CFA - common femoral artery; SFA - superficial femoral artery</p>	
<p>**For Type B and C lesions: The patient's co-morbidities, fully informed patient preference and the local operator's long-term success rates must be considered when making treatment recommendations for type B and type C lesions</p>			

available devices designed to cross total occlusions or so-called re-entry devices can facilitate recanalization of total femoro-popliteal occlusions. However, cost consideration is associated with these more sophisticated crossing techniques. Both papers indicate exercise therapy and pharmacotherapy as first-line therapy in patients suffering from intermittent claudication.

1. Exercise therapy

1.1. TASC II guidelines, Recommendation 14

“Supervised exercise should be made available as part of the initial treatment for all patients with peripheral arterial disease [A]. The most effective programs employ treadmill or track walking which is of sufficient intensity to bring on claudication, followed by rest, over the course of a 30–60 minute session. Exercise sessions are typically conducted three times a week for 3 months [A].”

1.2. ACC/AHA guidelines

A programme of supervised exercise training is recommended as an initial treatment modality for patients with intermittent claudication. (Class I recommendation, Level of Evidence: A.)

2. Pharmacotherapy

2.1. TASC guidelines, Recommendation 15

“Pharmacotherapy for symptoms of intermittent claudication. A 3- to 6-month course of cilostazol should be first-line pharmacotherapy for the relief of claudication symptoms, as evidence shows both an improvement in treadmill exercise performance and in quality of life [level A recommendation]. Naftidrofuryl can also be considered for treatment of claudication symptoms [A].”

2.2. ACC/AHA guidelines

“A therapeutic trial of cilostazol should be considered in all patients with lifestyle-limiting claudication (in the absence of heart failure). (Class I recommendation, Level of Evidence: A.)” The clinical effectiveness of pentoxifylline as therapy for claudication is marginal and not well established. (Class IIb recommendation, Level of Evidence: C.)

3. Endovascular therapy

3.1. TASC II guidelines

Endovascular treatment of infra-inguinal disease should be limited to patients with failed exercise or pharmacotherapy suffering from intermittent claudication and in every patient with CLI. Endovascular therapy as an established treatment modality is accepted in patients with intermittent claudication. “The low morbidity and mortality of endovascular techniques such as PTA makes it to the preferred choice of treatment in limited disease such as stenoses/occlusions up to 10 cm in length.”

Recommendation 35: “Choosing between techniques with equivalent short- and long-term clinical outcomes: In a situation where endovascular revascularization and open repair/bypass of a specific lesion causing symptoms of peripheral arterial disease give equivalent short-term and long-term symptomatic improvement, endovascular techniques should be used first [B].”

Recommendation 37: “Endovascular therapy is the treatment of choice for type A lesions and surgery is the treatment of choice for type D lesions [C]. Endovascular treatment is the preferred treatment for type B lesions and surgery is the preferred treatment for good-risk patients with type C lesions. The patient’s co-morbidities, fully informed patient preference and the local operator’s long-term success rates must be considered when making treatment recommendations for type B and type C lesions [C].”

3.2. ACC/AHA guidelines

As a class I recommendation “endovascular procedures are indicated for individuals with a vocational or lifestyle-limiting disability due to intermittent claudication when clinical features suggest a reasonable likelihood of symptomatic improvement with endovascular intervention and (a) there has been an inadequate response to exercise or pharmacological therapy and/or (b) there is a very favourable risk-benefit ratio (e.g. focal aorto-iliac occlusive disease). (Level of Evidence: A.)”

As a class IIa recommendation it is stated that “stents (and other adjunctive techniques such as lasers, cutting balloons, atherectomy devices, and thermal devices) can be useful in the femoral, popliteal, and tibial arteries as salvage therapy for a suboptimal or failed result from balloon dilation (e.g. persistent translesional gradient, residual diameter stenosis greater than 50%, or flow-limiting dissection). (Level of Evidence: C.)”

“The effectiveness of stents, atherectomy, cutting balloons, thermal devices, and lasers for the treatment of femoro-popliteal arterial lesions (except to salvage a suboptimal result from balloon dilation) is not well established. (Class IIb recommendation, Level of Evidence: A.) Primary stent placement is not recommended in the femoral, popliteal, or tibial arteries. (Class III recommendation, Level of Evidence: C.)”

In summary, both consensus papers favour conservative therapy as a first-line therapy. Invasive therapy is only indicated if conservative therapy has failed or is not indicated because of co-morbidities or special individual circumstances. Even if reliable data are still rare regarding the effectiveness of advanced techniques compared to plain balloon angioplasty, the new guidelines are more liberal regarding their use than the original TASC I consensus paper.

Post-interventional surveillance programme

Owing to the fact of the probability of restenosis development – still relatively high – and the progressive nature of atherosclerosis, patients undergoing endovascular (and surgical) procedures should be included into a chronic surveillance programme. Usually, follow-up visits are scheduled after 3 and 6 months and every 6 months thereafter. Besides clinical examination, the calculation of the ankle–brachial index (ABI) based on Doppler pressure measurement at the brachial and ankle arteries represents the basic non-invasive examination. In case of recurrent symptoms or a drop of the ABI during follow-up, an additional colour duplex examination for the detection and grading of restenosis or a de novo lesion and a treadmill test for the determination of walking impairment is mandatory. Magnetic resonance tomography angiography and computed tomography angiography are not indicated as routine follow-up examination techniques.

Treatment techniques

Balloon angioplasty

Balloon angioplasty (PTA) remains the simplest technique and may be the first treatment to be proposed for some lesions, but its technical success and durability strongly correlate with lesion morphology.^{11–14} In general, the results obtained after treating longer stenoses and/or occlusions have not been encouraging, even when comparing to the original TASC classification. A 5-year cumulative patency rate of 75% can be expected for short focal stenoses (TASC A) and 6 months cumulative patency rates have been 86.8% for stenoses <7 cm (TASC B) and 23.1% for those >7 cm representing TASC C & D lesions.¹³ PTA of lesions <5 cm is generally more durable than PTA of lesions >10 cm.¹² In the STAR registry¹⁵ the technical success rate for PTA was 95% with a primary patency rate of 87% at 1 year, 80% at 2 years, 69% at 3 years, and 55% at 4 and 5 years. Stratified to TASC categories, the 36-month patency rate was 87% for TASC A lesions, 69% for TASC B lesions and 67% for TASC C lesions, which demonstrated that category C lesions may be treated with results similar to those in category B. Factors affecting long-term patency were the presence of diabetes and renal failure, lesion length, stenosis versus total occlusion, diameter stenosis at baseline and post-PTA, calcification, eccentricity, post-PTA dissection, and serial lesions versus single lesion. The most powerful predictor for reduced vessel patency, however, was a poor tibial vessel run-off compared with an unaffected run-off situation to the foot (primary patency rates 40.6% versus 92%, $p < 0.001$).

Most authors recommend crossing a lesion intraluminally. The technique of subintimal angioplasty as

a primary attempt to cross a total occlusion remains controversial. It seems to give good long-term results for long, not seriously calcified lesions and for patients with CLI. Bell¹⁶ reported more than 1000 procedures with a technical success rate of 86%, a 6-year patency rate of 55% and a 3-year limb salvage of approximately 90% which competes with surgery.

Stent-supported angioplasty

Stent designs have changed over the years. In the early WallstentTM data, SFA reocclusion rates were up to 70% at 3 years.^{17–19} Balloon-expandable stents such as PalmazTM stents (Cordis, Johnson & Johnson, Haan, Germany) and StreckerTM stents (Boston Scientific, Ratingen, Germany) were also implanted at the femoro-popliteal axis and several single-centre series were published showing acceptable results for short lesions.^{19–26} However, three randomized studies^{27–29} comparing PTA alone and PTA and stenting with balloon-expandable stents reported no benefit for stenting and the risk of stent compression. These studies do not support balloon-expandable femoro-popliteal stenting as a primary approach. These stent types may play a limited role in the treatment of highly calcified lesions where self-expanding stent application is limited by its insufficient radial force.

Several non-randomized studies have demonstrated the significant improvement of the new generation of nitinol stents for the SFA. The introduction of the nickel-titanium alloy (nitinol) seemed to change the situation. They offer numerous advantages such as improved deliverability precision, minimal foreshortening, 5 F/6 F sheath compatibility, and longer lengths. Hayerizadeh et al³⁰ retrospectively compared 163 SMARTTM (Cordis) nitinol stents (lesion length: 178 ± 110 mm) with 166 Wallstent stainless steel stents (lesion length: 197 ± 101 mm). The 1-year primary patency rate was 61% with the SMART stent versus 30% with the Wallstent ($p < 0.0001$). Sabeti et al³¹ did a similar retrospective analysis in 175 patients comparing nitinol stents and stainless steel stents. The 2-year patency rate was 69% with nitinol stents and 34% with stainless steel stents ($p = 0.008$). More recently, once again Sabeti et al³² reported a study of 65 patients treated with a SFA lesion length of ≥ 20 cm using nitinol stents and found encouraging results with a 1-year restenosis rate of 7% in non-diabetic and 22% in diabetic patients ($p < 0.01$). Mewissen³³ reported the results of 246 implanted SMART nitinol stents in 137 limbs in the majority of the target lesions, including TASC B and C lesions (mean lesion length 12.6 cm). The patency rates were 92%, 76% and 60% at 6, 12 and 24 months, respectively.

However, from recently published trials we learned that not every nitinol is alike regarding long-term patency and fracture resistance. In parallel with promising long-term patency results coming from the bare stent arm of the SIROCCO II study^{34,35} showing

6-month and 2-year restenosis rates of 7.7% and 25%, respectively, this study raised the question of stent fractures found after 6 months in 17% and 12% for three and two overlapping stents, respectively. The FESTO trial³⁶ suggested a direct correlation between the stent fracture rate and an increased restenosis rate. However, there are several doubts about this theory coming from the latest published or presented randomized trials using the AbsoluteTM stent (Abboth Vascular, Giessen, Germany)³⁷ and the LuminexxTM (CR Bard, Karlsruhe, Germany) stent.³⁸ In the Vienna study,³⁷ the stent fracture rate after 1 year was only 1%; however, the restenosis rate was 25% for SFA lesions with an average length of 101 mm. On the other hand, the FAST (Femoral Artery Stenting Trial) study found stent fractures in 12% of the implanted stents. Binary restenosis rates in the fractured stents versus non-fractured stents were 20% and 28.8%, respectively. Based on these results the stent design and stent surface are more likely to affect stent patency than stent fractures.

One-year patency rates were different in both studies, not only because of significantly differing lesion lengths: the Vienna study³⁷ included SFA lesions with a mean length of 101 mm and 92 mm ($p = 0.11$) in the stent arm and PTA arm, respectively. One-year binary restenosis rates for the 'as-treated' analysis were significantly in favour for the stent group being 25% and 50% ($p = 0.02$), respectively. In contrast, the FAST study including mean lesion lengths of 45 mm and 44 mm for the stent group and PTA group respectively, found no significant difference regarding 1-year restenosis rates for the 'as-treated' analysis being 33% and 38%, respectively. These results may lead to the conclusion that short lesions do quite well with plain PTA, whereas in longer lesions the primary use of stent devices dedicated for femoro-popliteal application should be preferred.

Endografts

Early results with Dacron-covered stents were very disappointing due to the porosity of the graft material allowing restenosis to occur and its association with a significant inflammatory response.³⁹⁻⁴⁴ However, the early and midterm outcomes with the HemobahnTM stent-graft (WL Gore and Associates, Inc., Flagstaff, AZ, USA) seem to be competitive with prosthetic surgical bypass with a reduced inflammatory vessel wall response.⁴⁵⁻⁵³ Recently, the TCT (Trans Catheter Therapeutics) 2006 meeting presented promising single-centre registry data on the 1-year patency of the ViabahnTM (WL Gore and Associates, Inc.) application in long native SFA lesions and on in-stent lesions too being 90% and 65%, respectively.^{54,55} Moreover, Saxon et al⁵⁶ reported a 79% primary patency rate and 93% secondary patency rate at the 4-year follow-up for lesions of an average length >10 cm, using Hemobahn or Viabahn stent grafts. Another potential

indication for the application of this technology might be the treatment of femoro-popliteal aneurysms.⁵⁷ However, reports on the long-term results of the application of this technology are still pending. The impact of occluding all muscular perforating side branches is still uncertain. A comparative study between the endovascular placement of the Hemobahn stent-graft and bare nitinol stenting or, even better, surgical bypass would help provide solid evidence-based support for the use of this technology.

Drug-eluting stents

Recently, hopes that a drug-eluting stent (DES) might prove a useful solution to improve long-term patency in the SFA were dashed by the SIROCCO I and II trials.^{34,58} After promising 6-month intermediate results showing only a trend towards better patency for the DES group due to the much better performance of the bare nitinol SMART stent group as expected when calculating the study size,⁵⁷ after 24 months the outcome was virtually identical for both groups with restenosis rates of 24% and 25% for the DES and the bare stent group, respectively.³⁵ However, even if these trials failed to prove a benefit for a self-expanding stent platform for drug elution, a long-term primary patency rate of about 75% for the bare stents and DES is promising.

Explanations for the failure of a beneficial outcome of DES application to femoro-popliteal arteries are numerous, including wrong (too short) release kinetics and an insufficient peak concentration of the used drug (sirolimus), and a completely different remodelling behaviour of the vessel wall following placement of self-expanding stents compared to balloon-expandable stents as used in the coronaries. Further research has to be awaited to make final conclusions on the potential benefit of DES application in the femoro-popliteal vessel area. Currently, another study is still including patients to investigate the long-term outcome of a polymer-free nitinol stent platform using paclitaxel as a antiproliferative agent (ZILVER study).

Therefore, while stenting remains the preferred interventional therapy for many cases, especially bail out situations, it does not yet appear as the final solution to treat femoro-popliteal lesions. There are many emerging technologies that might revolutionize the way to approach treatment of femoro-popliteal stenotic disease.

Plaque modulation devices

1. Cutting balloon angioplasty

The idea behind this technology is to reduce stretching and overexpansion of the vessel wall by inducing longitudinal cuts into the plaque and the inner layers of the vessel wall. Theoretically this approach should lead to reduced uncontrolled dissection, less elastic recoil, fewer barotraumas and with this a reduced restenosis rate. Cutting balloon (Boston Scientific, Ratingen, Germany) may be indicated in calcified and

rigid lesions, and bifurcation lesions. However, clinical experience with this technology is still limited.⁵⁹

2. Cryoplasty

The objective of cryoplasty (Boston Scientific) is to temporarily freeze the intima and media layers of the vessel wall to a temperature of -10°C at the time of dilation using an automated liquid nitrogen deployment system. Theoretically, this technology is characterized by three major effects leading to a more benign wound-healing process following angioplasty: (i) induce a more controlled and uniform stretching of the vessel wall as a result of a change in plaque microstructure; (ii) a reduction of elastic recoil by freeze-induced alteration of the morphology of collagen and elastic fibres with short-term loss of vessel elasticity; and (iii) apoptosis of vascular smooth muscle cells resulting in a reduced neointima formation.^{60,61} The primary success of this technique seems to be very similar to angioplasty, but controlled data on durability data is still pending. Laird et al⁶² reported a duplex ultrasound-controlled 9-month primary patency rate of 70%. However, the primary success rate of this technology was disappointingly low at 85% and could be improved to 94% by stent placement. Currently, this technology is not justified for general application because of the high device costs compared to plain PTA.

Another approach to avoid stenting with the goal to achieve the same durability is to remove the stenocclusive material using plaque excision devices:

Atherectomy devices

1. Directional atherectomy

In the beginning of the 1990s, there was considerable enthusiasm for directional atherectomy as a means to

increase procedural luminal gain while avoiding barotrauma and vessel recoil. At that time, the Simpson AtheroCath was studied, hoping it would provide a durable solution to femoropopliteal disease.⁶³ Unfortunately, directional atherectomy did not improve the clinical or hemodynamic outcome at this level. Rather, the results suggested that atherectomy might actually be worse than angioplasty.⁶⁴ Based on this early clinical experience, directional atherectomy fell out of favour, but now a new atherectomy device, the SilverHawk™ Atherectomy Catheter (FoxHollow Technologies, Redwood City, CA, USA) specifically designed for the femoro-popliteal segment might change the situation (Figures 1–3). Long, diffuse, even calcified lesions can be treated. The initial outcomes with this device seem promising,^{65,66} and also the first long-term single-centre report could demonstrate satisfying results at least for de novo lesions.^{67,68} Strikingly, restenotic lesions, regardless of whether they were located in-stent or in a native artery vessel segment, did result in much higher reoccurrence rates compared with de novo lesions.

2. Remote endarterectomy

Remote endarterectomy⁶⁹ is a hybrid of minimally invasive surgical and endovascular techniques and offers a safe and effective option for the treatment of long segment SFA diseases with a single small incision in the groin. Extensive debulking can be performed with specifically designed surgical instrumentation combined with standard endovascular equipment (MollRing Cutter; Vascular Architects, Portola Valley, CA, USA). A recent study combined this technique with placement of a distal Aspire™ covered helical stent (Vascular Architects Inc., San Jose, CA, USA). A primary patency rate of 70% at 30 months was recently




Figure 1 (a and b) Detailed drawing of the cutting assembly of the Silverhawk™ atherectomy catheter.




Figure 2 (a and b) Drawing of the complete tip of the Silverhawk atherectomy catheter.

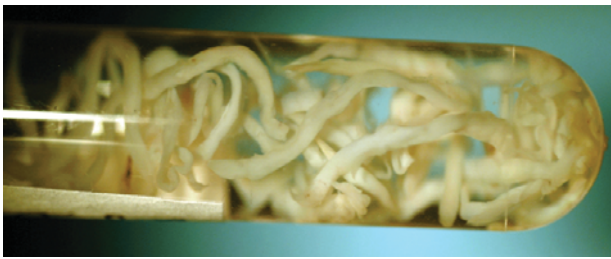


Figure 3 Atherectomized plaque material after Silverhawk atherectomy.

published.⁷⁰ Another study reported a primary patency rate of 69% at 18 months, and a primary-assisted patency rate of 88% at 15 months.⁷¹

3. Excimer laser atherectomy (photoablation)

Debulking the SFA or popliteal artery utilizing laser technology has helped to improve outcomes and durability for femoro-popliteal disease in single-centre reports.^{72–75} Recent advances in catheter design and technique, including saline infusion, have minimized the thermal energy associated with laser therapy and reduced the risk of vessel dissection. The results of the Laser Atherectomy for Critical Ischemia (LACI-2) pilot study are promising for patients with non-healing wounds.⁷⁶ However, the Peripheral Excimer Laser Angioplasty (PELA) study,⁷⁷ a multi-centre, prospective, randomized trial involving 251 patients with claudication (Rutherford category 2–4) for at least 6 months and total SFA occlusions ≥ 10 cm randomized to either excimer laser-assisted angioplasty or balloon dilation was not able to prove any benefit for excimer laser (Spectranetics, Colorado Springs, CO, USA) application. Twelve-month patency rates and functional status were similar in both groups. The only significant difference between both groups was a lower stent rate in the laser-treated cohort. Currently, laser angioplasty does not seem to have a significant role in the treatment of femoro-popliteal diseases.

4. Rotational atherectomy

A still investigational device, the Pathway PVSTTM atherectomy catheter (Pathway Medical, Redwood City, CA, USA), offers an attractive alternative

approach to remove plaque material: scraping flutes that can be extended in diameter by just changing the direction of the rotation of the device at the tip of the catheter atherectomize the plaque from the vessel wall. The debris is continuously aspirated and collected in a collecting reservoir via an inner lumen (Figure 4). Initial short-term experience coming from a European multi-centre registry is promising regarding efficacy and performance of the new device.⁷⁸

Brachytherapy

Böttcher et al⁷⁹ were the first to present data showing that endovascular irradiation is both feasible and safe in humans. In this Frankfurt trial, patients with recurrent lesions after balloon angioplasty with a mean lesion length of 6.7 cm were treated with repeated PTA plus stent implantation and endovascular brachytherapy (BT) for prophylaxis of in-stent restenosis in the SFA. A dose of 12 Gray (Gy) prescribed at a radial distance of 3 mm corresponding to the vessel surface was administered via a non-centring catheter. In the 28 patients available for long-term follow-up, the 5-year primary patency rate was 82%, determined clinically and by ultrasound. Three patients developed restenosis within the treated segment, while two patients presented with acute thrombotic occlusion after 16 and 37 months, respectively.⁸⁰ Furthermore, using magnetic resonance imaging (MRI), the authors observed no evidence of side effects to the vessels, nerves, or soft tissue surrounding the femoral artery. In a randomized study on restenotic SFA lesions, the patients were either randomized to either angioplasty with high-dose gamma BT using a non-centred ¹⁹²Ir source (12 Gy) or repeat angioplasty alone.⁸¹ At 1 year, the restenosis rates were 23% in the BT group versus 42% in the control group ($p = 0.028$) by duplex ultrasound, confirming that BT exerts a beneficial effect in patients with recurrent lesions after prior balloon angioplasty.

Gallino et al⁸² reported results of a 2×2 factorial randomized trial of 335 patients assigned to PTA, PTA plus BT (14 Gy), PTA plus probucol, or PTA plus probucol and BT. No late thrombotic reocclusion occurred after PTA and subsequent BT.⁸³ The 6-month restenosis rates by duplex ultrasound after PTA plus




Figure 4 (a–c) Pathway PVS atherectomy device: view of the distal tip with a 2.1 mm diameter when rotating clockwise (a) and 3.0 mm if rotating counter-clockwise (b). Aspiration ports collect plaque and thrombus. View of the control pod (c).

BT versus balloon angioplasty alone were 17% versus 35%, with a 50% reduction of restenosis by BT compared to plain balloon angioplasty ($p < 0.001$). Probucol did not add to the beneficial effect of BT.

The Peripheral Artery Radiation Investigational Study (PARIS) was approved by the Food and Drug Administration to test feasibility and safety.⁸⁴ The angiographic binary restenosis rate at 6 months was 17.2% and the clinical restenosis rate at 12 months was 13.3%. The authors concluded that intra-arterial high-dose gamma radiation after balloon angioplasty

of SFA lesions was feasible and safe. In the second randomized phase, 203 patients were enrolled in centres in the USA and Europe. In preliminary results (R. Waksman, 2003 American College of Cardiology meeting), disappointingly the angiographic and clinical parameters showed no significant differences between the treatment groups.

The most experience on BT came from the Vienna trials. Based on promising results derived from the feasibility trial (Vienna-01),⁸⁵ the Vienna-02 trial⁸⁶ included patients with a mean lesion length of 17 cm comparing PTA plus non-centred BT and plain PTA. Recurrence rates at 6 and 12 months were 28% and 36% in the PTA + BT group versus 54% and 65% in the plain PTA group ($p < 0.05$), respectively. The significant improvement in patency was also maintained after 3 years. Despite the significant reduction of recurrence in this randomized trial, restenosis was not prevented in about a third of the patients. The Vienna-03 trial⁸⁷ employed a source-centring catheter as used in the PARIS trial. However, opposite to the PARIS protocol, patients with longer lesions (mean lesion length 10 cm) were eligible, and the prescribed dose was 18 Gy compared to 14 Gy in the PARIS trial. One-year restenosis rates in the BT versus placebo groups were 23% versus 53%, confirming a significant benefit for centred BT. To evaluate the interaction of endovascular BT and stenting, a pilot study (Vienna-04 trial⁸⁸) was performed. The mean treated length was 17 cm and a dose of 14 Gy was prescribed. At 6 months recurrence was observed in 10/33 lesions, including seven lesions with sudden late thrombotic occlusion. Prolonged administration of clopidogrel for at least 12 months therefore appeared to be mandatory after stenting and BT. Based on this experience, the Vienna-05 trial⁸⁹ was initiated comparing the 6-month recurrence rates after femoro-popliteal stenting and BT versus stenting alone. The study design and dose prescription were identical to the Vienna 04 trial, except that all patients should receive clopidogrel for at least 1 year. Recurrence rates at 6 months in the BT group compared to the placebo group were 33% versus 35%. A considerable proportion of recurrences were due to early (17%) and late thrombotic (7%) reocclusions in the BT group, all of which occurred after early discontinuation of clopidogrel. Even in the setting of a well-conducted trial, patients stopped taking clopidogrel although it was prescribed by the study investigators. This suggests that in routine clinical application BT represents an unsafe therapy if the antithrombotic regimen is not strictly supervised. This fact and the high logistic requirements prevented a more widespread use of this technology in peripheral interventions such as in the coronaries.

Drug-coated balloon angioplasty

Another approach to suppress overwhelming vessel wall reaction on the angioplasty trauma is the applica-

tion of antiproliferative drugs. Whereas drug-eluting stents have not yet proved a beneficial outcome, Tepe et al recently presented data for the THUNDER trial.⁹⁰ This study creates new hope to surrender the problem of restenosis development. This prospective, double-blinded, multi-centre trial compared plain balloon angioplasty and balloon angioplasty using paclitaxel-enriched dye and balloon angioplasty using a paclitaxel-coated balloon catheter (Paccocath™ BMT, Munich, Germany). Comparable to the beneficial results treating coronary in-stent restenoses,⁹¹ the 6-month binary restenosis rates were significantly lowered in the Paccocath group, being 39%, 56% and 17% ($p < 0.01$) for the three study arms, respectively. The 1-year and 2-year angiographic results must be awaited before the general application of this promising device can be recommended.

Rotational thrombectomy

A rotational thrombectomy device with limited additional atherectomy capabilities available in 6 F and 8 F diameters has been recently proposed by several authors.⁹² The Rotarex™ (Straub Medical, Wangs, Switzerland; Figure 5) system can be applied for thrombotic occlusions in both acute and chronic phases and for long restenosis, especially in in-stent reocclusions with a mixed composition of the occlusive material containing thrombus and neointima. The acute success results are reported in the range 95–100%, with promising long-term results for de novo lesions.^{93,94}

In some situations, it may be impossible to re-enter the true lumen after having passed a chronic total occlusion of the SFA with the wire subintimally. The least expensive technique to solve this problem is using the retrograde transpopliteal approach.⁹⁵ However, not every patient is able to lie in the prone position. Therefore, sophisticated re-entry devices, either IVUS-based (PIONEER™; Medtronic, Menlo

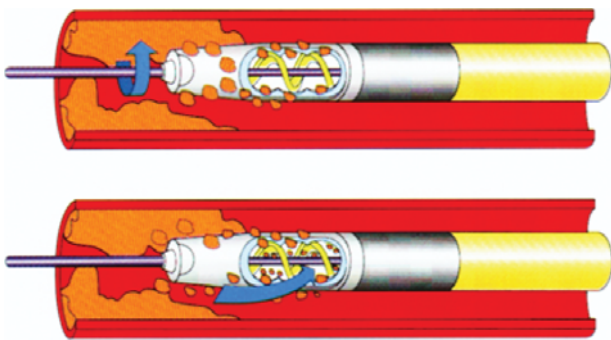


Figure 5 Tip of the Rotarex™ rotational thrombectomy device. The outer part of the cutting head is driven at 40 000 rpm by the internal spiral and removes the occlusive material. The rotation of the spiral produces a permanent vacuum within the catheter which sucks detached thrombotic material into the cutting slits. Here it is chopped up and transported by the spiral through the catheter to the collecting bag. No additional suction device is necessary.

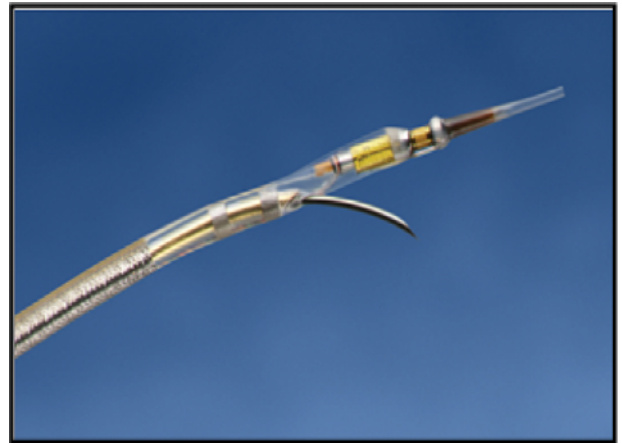


Figure 6 The PIONEER™ re-entry device. A 24 G curved puncture needle allows the puncture of the intima membrane to deliver a second 0.014" guide-wire through the needle into the true lumen. The tip incorporates an integrated 20 MHz IVUS transducer.

Park, CA, USA; Figure 6) or simply orientated with markers (Outback™; Cordis) are introduced to the market. However, no data are yet published about the true value of these expensive technologies.

Summary

All the techniques described above, notwithstanding the treatment of the SFA lesions, are still controversial, although the use of SFA angioplasty with or without stenting is expanding with an increasingly aggressive management strategy for all TASC lesions. It is widely accepted that TASC A and B lesions can be treated with acceptable long-term results using percutaneous minimally invasive techniques. The new techniques may allow us to extend endovascular procedures to TASC C and D lesions. However, despite primary success rates of more than 90%, even in TASC D lesions, the role of endovascular therapy for TASC D lesions remains debated, and many advocate that these patients should be considered for surgical intervention. Surgical bypass remains the gold standard for these more advanced SFA diseases, though surgery is not perfect either. If the distal bypass anastomosis involves the above the knee popliteal artery and the autogenous vein is used as graft material, patency rates are good, and, based on a study involving 3005 limbs, the 5-year primary patency rate is 70% and the secondary patency rate is 81%.⁹⁶ The patency rate is lower if prosthetic grafts are used and if patients are treated for limb salvage. Complications are not infrequent, including wound infections (1.6–3.4%), early graft failures (up to 24%), acute leg ischaemia (rates of 1–2%), surgical reversion (rates of more than 20%) and operative mortality (1.3–6%).⁹⁶

The current challenge of endovascular revascularization still is long-term primary patency. If this limitation can be overcome with acceptable costs, regardless of the technique used, endovascular techniques will also become the first choice treatment of advanced femoro-popliteal disease stages. Therefore, as recently suggested, if the 5-year patency rate of endoluminal interventions exceeds 30%, endoluminal intervention should be the preferred initial invasive strategy.^{97,98}

Percutaneous intervention is on the edge to become the first-line treatment for femoro-popliteal disease regardless its severity. The most promising approach to the treatment of complex femoro-popliteal lesions might be primarily debulking the vessel using atherectomy devices followed by a local drug delivery to suppress overwhelming neointimal and smooth muscle cell growth. The goal should be to avoid the placement of foreign bodies such as stents.

References

- Newman AB, Shemanski L, Manolio TA et al. Ankle-arm index as a predictor of cardiovascular disease and mortality in the Cardiovascular Health Study Group. *Arterioscler Thromb Vasc Biol* 1999; **19**: 538–45.
- Diehm C, Schuster A, Allenberg JA et al. High prevalence of peripheral arterial disease and co-morbidity in 6880 primary care patients: a cross-sectional study. *Atherosclerosis* 2004; **172**: 95–105.
- Weitz JL, Byrne J, Clagett GP et al. Diagnosis and treatment of chronic arterial insufficiency of the lower extremities: a critical review. *Circulation* 1996; **94**: 3026–49.
- Dormandy J, Mahir M, Ascady G et al. Fate of the patient with chronic leg ischemia: a review article. *J Cardiovasc Surg (Torino)* 1989; **30**: 50–57.
- McDaniel MD, Cronenwett JL. Basic data related to the natural history of intermittent claudication. *Ann Vasc Surg* 1989; **3**: 273–77.
- Norgren L, Hiatt WR, Dormandy JA, Nehler MR, Harris KA, Fowkes FGR, et al. Inter-Society Consensus for Management of Peripheral Arterial Disease (TASC II). *Eur J Vasc Endovasc Surg* 2007; **33** (1 suppl): S1–S75.
- Hirsch AT, Haskal ZJ, Hertzner NR et al. ACC/AHA Guidelines for the Management of Patients with Peripheral Arterial Disease 2005 (Lower Extremity, Renal, Mesenteric, and Abdominal Aortic): Executive summary. *J Am Coll Cardiol* 2006; **47**: 1239–312.
- Pentacost MJ, Criqui MH, Dorros G et al. Guidelines for peripheral percutaneous transluminal angioplasty of the abdominal aorta and lower extremity vessels. *Circulation* 1994; **89**: 511–31.
- Shouse HB, Nikanorov A, LaFlash D. Biomechanical forces in the femoropopliteal arterial segment. *Endovascular Today* 2005; **4**: 60–66.
- Dotter CT, Krippaehne WW, Judkins MP. Transluminal recanalization and dilatation in atherosclerotic obstruction of femoral popliteal system. *Am Surg* 1965; **31**: 453–59.
- Becker GJ, Katzen BT, Dake MD. Noncoronary angioplasty. *Radiology* 1989; **170**: 921–40.
- Capek P, McLean GK, Berkowitz HD. Femoropopliteal angioplasty. Factors influencing long-term success. *Circulation* 1991; **83**: I 70–I 80.
- Murray JG, Apthorp LA, Wilkins RA. Long segment (>10 cm) femoropopliteal angioplasty: improved technical success and long term patency. *Radiology* 1995; **195**: 158–62.
- Krepel VM, van Andel GJ, van Erp WF, Breslau PJ. Percutaneous transluminal angioplasty of the femoropopliteal artery: initial and long-term results. *Radiology* 1985; **156**: 325–28.
- Clark TW, Groffsky JL, Soulen MC. Predictors of long term patency after femoropopliteal angioplasty: results from the STAR registry. *J Vasc Interv Radiol* 2001; **12**: 923–33.
- Bell P. Subintimal angioplasty. Presented at the International Congress XVII Endovascular Intervention. 9–12 February 2004. Scottsdale, USA.
- Gordon IL, Conroy RM, Arefi M, Tobis JM, Stemmer EA, Wilson SE. Three-year outcome of endovascular treatment of superficial femoral artery occlusion. *Arch Surg* 2001; **136**: 221–28.
- Damaraju S, Cuasay L, Le D, Strickman N, Krajcer Z. Predictors of primary patency failure in Wallstent self-expanding endovascular prostheses for iliofemoral occlusive disease. *Tex Heart Inst J* 1997; **24**: 173–78.
- Martin EC, Katzen BT, Benenati JF et al. Multicenter trial of the Wallstent in the iliac and femoral arteries. *J Vasc Interv Radiol* 1995; **6**: 843–49.
- Henry M, Amor M, Ethevenot G et al. Palmaz stent placement in iliac and femoropopliteal arteries: primary and secondary patency in 310 patients with 2–4 year follow-up. *Radiology* 1995; **197**: 167–74.
- Strecker EP, Hagen B, Liermann D, Schneider B, Wolf HR, Wambsgans J. Iliac and femoropopliteal vascular occlusive disease treated with flexible tantalum stents. *Cardiovasc Intervent Radiol* 1993; **16**: 158–64.
- Bergeron P, Pinot JJ, Poyen V et al. Long-term results with the Palmaz stent in the superficial femoral artery. *J Endovasc Surg* 1995; **2**: 161–67.
- Vogelzang RL. Long term results of angioplasty. *J Vasc Interv Radiol* 1996; **7** (suppl): 179.
- Henry M, Amor M, Henry I. Femoropopliteal stenting results, indications: choice of the stent. *Radiology* 1999; **213**: 50–59.
- Strecker EP, Boos IB, Gottmann D. Femoropopliteal artery stent placement: evaluation of long-term success. *Radiology* 1997; **205**: 375–83.
- Chatelard P, Guibourt C. Long-term results with a Palmaz stent in the femoropopliteal arteries. *J Cardiovasc Surg* 1996; **37**: 67–72.
- Cejna M, Thurnher S, Illiasch H et al. PTA versus Palmaz stent placement in femoropopliteal artery obstructions: a multicenter prospective randomized study. *J Vasc Interv Radiol* 2001; **12**: 23–31.
- Zdanowsky Z, Albrechtsson U, Lundin A et al. Percutaneous transluminal angioplasty with or without stenting for femoropopliteal occlusions? A randomized controlled study. *Int Angiol* 1999; **18**: 251–55.
- Vroegindewij D, Vos LD, Tielbeek AV, Buth J, vd Bosch HC. Balloon angioplasty combined with primary stenting versus balloon angioplasty alone in femoropopliteal obstructions: a comparative randomized study. *Cardiovasc Intervent Radiol* 1997; **20**: 420–25.
- Hayerizadeh R, Zeller T, Krankenberg H et al. Long-term outcome of superficial femoral artery stenting using nitinol stents

- compared with stainless steel stents. A multicenter study. *Am J Cardiol* 2003; **92** (suppl): S157L.
- 31 Sabeti S, Schillinger M, Amighi J et al. Primary patency of femoropopliteal arteries treated with nitinol versus stainless steel self-expanding stents: propensity score adjusted analysis. *Radiology* 2004; **232**: 516–21.
 - 32 Sabeti S, Mlekusch W, Amighi J, Minar E, Schillinger M. Primary patency of long-segment self-expanding nitinol stents in the femoropopliteal arteries. *J Endovasc Ther* 2005; **12**: 6–12.
 - 33 Mewissen MW. Nitinol stents in the femoropopliteal arterial segment. *Endovascular Today* 2005; **4**: 29–34.
 - 34 Duda SH, Bosiers M, Lammer J et al. Sirolimus-eluting versus bare nitinol stent for obstructive superficial femoral artery disease: the SIROCCO II trial. *J Vasc Interv Radiol* 2005; **16**: 331–38.
 - 35 Duda SH, Bosiers M, Lammer J et al. Drug-eluting and bare nitinol stents for the treatment of atherosclerotic lesions in the superficial femoral artery. *J Endovasc Ther* 2006; **13**: 701–10.
 - 36 Scheinert D, Scheinert S, Sax J et al. Prevalence and clinical impact of stent fractures after femoropopliteal stenting. *J Am Coll Cardiol* 2005; **45**: 312–15.
 - 37 Schillinger M, Sabeti S, Loewe C et al. Balloon angioplasty versus implantation of nitinol stents in the superficial femoral artery. *N Engl J Med* 2006; **354**: 1879–88.
 - 38 Krankenberg H on behalf of the FAST study group. The femoral artery stenting trial (FAST). 12-month final analysis. Presented at Transcatheter Cardiovascular Therapeutics 2006, 22–27 October 2006, Washington, DC, USA.
 - 39 Ahmadi R, Schillinger M, Maca T et al. Femoropopliteal arteries: immediate and long-term results with a Dacron-covered stent-graft. *Radiology* 2002; **223**: 345–50.
 - 40 Henry M, Amor M, Cragg A et al. Occlusive and aneurysmal peripheral arterial disease: assessment of a stent-graft system. *Radiology* 1996; **201**: 717–24.
 - 41 Kessel DO, Wijesinghe LD, Robertson I et al. Endovascular stent-grafts for superficial femoral artery disease: results of 1-year follow-up. *J Vasc Interv Radiol* 1999; **10**: 289–96.
 - 42 Rodriguez-Lopez JA, Soler L, Werner A et al. Long-term follow-up of endoluminal grafting for aneurysmal and occlusive disease in the superficial femoral artery. *J Endovasc Surg* 1999; **6**: 270–77.
 - 43 Spoelstra H, Casselman F, Lesceu O. Balloon-expandable endobypass for femoropopliteal atherosclerotic occlusive disease. *J Vasc Surg* 1996; **24**: 647–54.
 - 44 Bauermeister G. Endovascular stent-grafting in the treatment of superficial femoral artery occlusive disease. *J Endovasc Ther* 2001; **8**: 315–20.
 - 45 Lammer J, Dake MD, Bleyne J et al. Peripheral arterial obstruction: prospective study of treatment with a transluminally placed self-expanding stent-graft. International Trial Study Group. *Radiology* 2000; **217**: 95–104.
 - 46 Bray PJ, Robson WJ, Bray AE. Percutaneous treatment of long superficial femoral artery occlusive disease: efficacy of the Hemobahn stent-graft. *J Endovasc Ther* 2003; **10**: 619–28.
 - 47 Deutschmann HA, Schedlbauer P, Berczi V et al. Placement of Hemobahn stent-grafts in femoropopliteal arteries: early experience and midterm results in 18 patients. *J Vasc Interv Radiol* 2001; **12**: 943–50.
 - 48 Fischer M, Schwabe C, Schulte KL. Value of the Hemobahn/Viabahn endoprosthesis in the treatment of long chronic lesions of the superficial femoral artery: 6 years of experience. *J Endovasc Ther* 2006; **13**: 281–90.
 - 49 Jahnke T, Andresen R, Muller-Hulsbeck S et al. Hemobahn stent-grafts for treatment of femoropopliteal arterial obstructions: midterm results of a prospective trial. *J Vasc Interv Radiol* 2003; **14**: 41–51.
 - 50 Railo M, Roth WD, Edgren J et al. Preliminary results with endoluminal femoropopliteal thrupass. *Ann Chir Gynaecol* 2001; **90**: 15–18.
 - 51 Brodmann M, Stark G, Pabst E et al. Osteomyelitis of the spine and abscess formation in the left thigh after stent-graft implantation in the superficial femoral artery. *J Endovasc Ther* 2000; **7**: 150–54.
 - 52 Tielliu I, Verhoeven E, Prins T et al. Treatment of popliteal artery aneurysms with the Hemobahn stent-graft. *J Endovasc Ther* 2003; **10**: 111–16.
 - 53 Juergens KU, Tombach B, Reimer P et al. Perivascular inflammatory reaction to a Hemobahn stent-graft: diagnosis with 3D MR angiography. *J Endovasc Ther* 2002; **9**: 912–16.
 - 54 Kazemi S, Djelmami-Hani M, Gupta A, Tumuluri R, Shalev Y, Allaqaband S. One year patency rate of the VIABAHN stent-graft for chronic total occlusion or long high-grade stenosis of the superficial femoral artery. *Am J Cardiol* 2006; **98**: 235–36M.
 - 55 Kazemi S, Djelmami-Hani M, Tumuluri R et al. VIABAHN stent-graft for treatment of in-stent restenosis in femoropopliteal vascular occlusive disease, procedural outcome and one-year follow-up. *Am J Cardiol* 2006; **98**: 236M.
 - 56 Saxon AR, Coffman JM, Gooding JM, Ponec DJ. Endograft use in the femoral and popliteal arteries. *Tech Vasc Interv Radiol* 2004; **7**: 6–15.
 - 57 Henry M, Amor M, Cragg A et al. Occlusive and aneurysmal peripheral arterial disease: assessment of a stent-graft system. *Radiology* 1996; **201**: 717–24.
 - 58 Duda SH, Pusich B, Richter G et al. Sirolimus-eluting stents for the treatment of obstructive superficial femoral artery disease: six month results. *Circulation* 2002; **106**: 1505–509.
 - 59 Ansel GM, Sample NS, Botti III CF Jr et al. Cutting balloon angioplasty of the popliteal and infrapopliteal vessels for symptomatic limb ischemia. *Catheter Cardiovasc Interv* 2004; **61**: 1–4.
 - 60 Jordan WD, Taylor SM. SFA stenosis treated with cryoplasty. *Endovascular Today* 2004; **1**: 31–33.
 - 61 Jahnke T. Cryoplasty for the treatment of femoropopliteal artery disease: will freezing solve the problem of cold feet? *J Vasc Interv Radiol* 2005; **16**: 1051–54.
 - 62 Laird JR, Jaff MR, Biamino G et al. Cryoplasty for the treatment of femoro-popliteal arterial disease: results of a prospective multicenter registry. *J Vasc Interv Radiol* 2005; **16**: 1067–73.
 - 63 Dorros G, Iyer S, Lewin R et al. Angiographic follow-up and clinical outcome of 126 patients after percutaneous directional atherectomy (Simpson AtheroCath) for occlusive peripheral vascular disease. *Cathet Cardiovasc Diagn* 1991; **22**: 79–84.
 - 64 Vroegindewij D, Tielbeek AV, Buth J et al. Directional atherectomy versus balloon angioplasty in segmental femoropopliteal artery disease: two-year follow-up with color-flow duplex scanning. *J Vasc Surg* 1995; **21**: 255–69.
 - 65 Zeller T, Krankenberg H, Reimers B et al. Initial clinical experience with a new percutaneous peripheral atherectomy device for the treatment of femoro-popliteal stenoses [in German]. *Rofo* 2004; **176**: 70–75.
 - 66 Zeller T, Rastan A, Schwarzwälder U et al. Percutaneous peripheral atherectomy of femoropopliteal stenoses using a

- new-generation device: six-month results from a single-center experience. *J Endovasc Ther* 2004; **11**: 676–85.
- 67 Zeller T, Rastan A, Schwarzwälder U et al. Long-term results after directional atherectomy of femoro-popliteal lesions. *J Am Coll Cardiol* 2006; **48**: 1573–78.
- 68 Ramaiah V, Gammon R, Kiesz S et al. Midterm outcomes from the TALON registry: treating peripherals with Silverhawk: outcome collection. *J Endovasc Ther* 2006; **13**: 592–602.
- 69 Ho GH, Moll FL, Joosten PP et al. The Moll-ring Cutter remote endarterectomy: preliminary experience with a new endovascular technique for treatment of occlusive superficial femoral artery disease. *J Endovasc Surg* 1995; **2**: 278–87.
- 70 Nelson PR, Powell RJ, Proia RR et al. Results of endovascular superficial femoral endarterectomy. *J Vasc Surg* 2001; **34**: 526–31.
- 71 Rosenthal D, Martin JD, Schubart PJ, Wellons ED, Shuler FW, Levitt AB. Remote superficial femoral artery endarterectomy. *J Vasc Surg* 2004; **40**: 67–72.
- 72 Das TS. Percutaneous peripheral revascularization with excimer laser: equipment, technique and results. *Lasers Med Sci* 2001; **16**: 101–107.
- 73 Scheinert D, Laird JR Jr, Schröder M et al. Excimer laser-assisted recanalization of long, chronic superficial femoral artery occlusions. *J Endovasc Ther* 2001; **8**: 156–66.
- 74 Steinkamp HJ, Rademaker J, Wissgott C et al. Percutaneous transluminal laser angioplasty versus balloon dilation for treatment of popliteal artery occlusions. *J Endovasc Ther* 2002; **9**: 882–88.
- 75 Gray BH, Laird JR, Ansel GM et al. Complex endovascular treatment for critical limb ischemia in poor surgical candidates: a pilot study. *J Endovasc Ther* 2002; **9**: 599–604.
- 76 Laird JR, Zeller T, Gray BH et al for the LACI Investigators. Limb salvage following laser-assisted angioplasty for critical limb ischemia: results of the LACI multicenter trial. *J Endovasc Ther* 2006; **13**: 1–9.
- 77 Laird JR. Peripheral excimer laser angioplasty (PELA) trial results. Presented at the Transcatheter Cardiovascular Therapeutics (TCT) conference, 24–28 September 2005, Washington DC, USA.
- 78 Zeller T, Krankenberg H, Schwarzwälder U et al. Initial clinical experience with the 'Pathway PVTM' atherectomy catheter. *Am J Cardiol* 2006; **98**: 122M.
- 79 Böttcher HD, Schopohl B, Liermann D et al. Endovascular irradiation: a new method to avoid recurrent stenosis after stent implantation in peripheral arteries – technique and preliminary results. *Int J Radiat Oncol Biol Phys* 1994; **29**: 183–86.
- 80 Liermann DD, Bauernsachs R, Schopohl B et al. Intravascular irradiation therapy. In: Waksman R, editor. *Vascular brachytherapy*. 2nd ed. Armonk, NY: Futura Publishing; 1999. p. 395–405.
- 81 Zehnder T, von Briel C, Baumgartner I et al. Endovascular brachytherapy after percutaneous transluminal angioplasty of recurrent femoropopliteal obstructions. *J Endovasc Ther* 2003; **10**: 304–11.
- 82 Gallino A, Do DD, Alerci M et al. Effects of probucol versus aspirin and versus brachytherapy on restenosis after femoropopliteal angioplasty: the PAB randomized multicenter trial. *J Endovasc Ther* 2004; **11**: 595–604.
- 83 Bonvini R, Baumgartner I, Do DD et al. Late thrombotic occlusion after endovascular brachytherapy and stenting of femoropopliteal arteries. *J Am Coll Cardiol* 2003; **41**: 409–12.
- 84 Waksman R, Laird JR, Jurkovitz CT et al. Intravascular radiation therapy after balloon angioplasty of narrowed femoropopliteal arteries to prevent restenosis: results of the PARIS feasibility clinical trial. *J Vasc Interv Radiol* 2001; **12**: 915–21.
- 85 Minar E, Pokrajac B, Ahmadi R et al. Brachytherapy for prophylaxis of restenosis after long-segment femoropopliteal angioplasty: pilot study. *Radiology* 1998; **208**: 173–79.
- 86 Minar E, Pokrajac B, Maca T et al. Endovascular brachytherapy for prophylaxis of restenosis after femoropopliteal angioplasty: results of a prospective randomized study. *Circulation* 2000; **102**: 2694–99.
- 87 Pokrajac B, Schmid R, Pötter R et al. Endovascular brachytherapy prevents restenosis after femoropopliteal angioplasty: results of the Vienna-3 multicenter study [Abstract]. *Int J Radiat Oncol Biol Phys* 2003; **57** (2 suppl): S250.
- 88 Wolfram RM, Pokrajac B, Ahmadi R et al. Endovascular brachytherapy for prophylaxis against restenosis after long-segment femoropopliteal placement of stents: initial results. *Radiology* 2001; **220**: 724–29.
- 89 Wolfram R, Pokrajac B, Budinsky AC et al. Vascular brachytherapy with 192Iridium after femoropopliteal stenting in high risk patients – results from the Vienna-5 trial. *Z Kardiol* 2003; **10** (suppl H): 19.
- 90 Tepe G, Zeller T, Albrecht T, Speck U. Local taxan with short time exposure for reduction of restenosis in distal arteries (THUNDER). Presented at the Transcatheter Cardiovascular Therapeutics (TCT) conference, 22–27 October 2006, Washington DC, USA.
- 91 Scheller B, Hehrlein C, Bocksch W et al. Treatment of coronary in-stent restenosis with a paclitaxel-coated balloon catheter. *N Engl J Med* 2006; **355**: 2113–24.
- 92 Zeller T, Frank U, Bürgelin K et al. Early experience with a rotational thrombectomy device for treatment of acute and subacute infraaortic arterial occlusions. *J Endovasc Ther* 2003; **10**: 322–31.
- 93 Duc SR, Schoch E, Pfyffer M, Jenelten R, Zollikofer CL. Recanalization of acute and subacute femoropopliteal artery occlusions with the Rotarex catheter: one year follow-up. Single center experience. *Cardiovasc Intervent Radiol* 2005; **28**: 603–10.
- 94 Zeller T, Frank U, Bürgelin K et al. [Long-term results after recanalization of acute and subacute thrombotic occlusions of the infra-aortic arteries and bypass grafts using a rotational thrombectomy device.] Article in German. *Rofo* 2002; **174**: 1559–65.
- 95 Scheinert D, Biamino G. Access sites for peripheral interventions. In: Marco J, Serruys P, Biamino G et al, editors. *The Paris Course on Revascularization course book*. Europa Edition: Poitiers, France; 2003. p. 405–10.
- 96 Jaff MR. The nature of SFA disease. *Endovascular Today* 2004; Suppl 3: 5.
- 97 Wolford HY, Surowiec SM, Davies MG. SFA angioplasty versus femoropopliteal bypass. *Endovascular Today* 2005; **4**: 51–53.
- 98 Hunink MG, Wong JB, Donaldson MC, Meyerovitz MF, de Vries J, Harrington DP. Revascularization for femoropopliteal disease: a decision and cost effectiveness analysis. *JAMA* 1995; **274**: 165–71.