



HAL
open science

Bone Augmentation with Bioactive Glass in Three Cases of Dental Implant Placement

Antonietta M. Gatti, Leopoldo A. Simonetti, Emanuela Monari, Stefano Guidi, David Greenspan

► **To cite this version:**

Antonietta M. Gatti, Leopoldo A. Simonetti, Emanuela Monari, Stefano Guidi, David Greenspan. Bone Augmentation with Bioactive Glass in Three Cases of Dental Implant Placement. *Journal of Biomaterials Applications*, 2006, 20 (4), pp.325-339. 10.1177/0885328206054534 . hal-00570766

HAL Id: hal-00570766

<https://hal.science/hal-00570766>

Submitted on 1 Mar 2011

HAL is a multi-disciplinary open access archive for the deposit and dissemination of scientific research documents, whether they are published or not. The documents may come from teaching and research institutions in France or abroad, or from public or private research centers.

L'archive ouverte pluridisciplinaire **HAL**, est destinée au dépôt et à la diffusion de documents scientifiques de niveau recherche, publiés ou non, émanant des établissements d'enseignement et de recherche français ou étrangers, des laboratoires publics ou privés.

Bone Augmentation with Bioactive Glass in Three Cases of Dental Implant Placement

ANTONIETTA M. GATTI,* LEOPOLDO A. SIMONETTI, EMANUELA MONARI,
STEFANO GUIDI AND DAVID GREENSPAN
*The National Institute of Physics of Matter
Laboratory of Biomaterials, Department of Neurosciences
University of Modena and Reggio Emilia
Via del Pozzo 71, 41100 Modena – Italy*

ABSTRACT: This study reports the clinical use of a bioactive bone graft material, PerioGlas[®], in the treatment of dental extraction sites before dental implant placement, to effect bone regeneration and to give early fixation to the implant.

PerioGlas[®], granules, ranging from 90 to 710 μm , are implanted after tooth extraction in three patients; after 6 months bone biopsies were performed in the site of the glass implantation and observed under Electron Scanning Microscopy.

All the granules showed a biodegradation involving precipitation of calcium phosphate that worked as a scaffold for osteoblasts colonization. All cases examined showed the bioactivity of PerioGlas[®] granules resulting in new bone formation and biodegradation of the glass. After a two-year clinical follow-up all the implants were successfully loaded and appeared stable.

KEY WORDS: bioactive materials, implants, dentistry, bone defects.

INTRODUCTION

The use of dental implants to restore function in partially/completely edentulous patients has been highly successful in recent years [1,2]. With the development and improvement in dental

*Author to whom correspondence should be addressed. E-mail: gatti@unimo.it

implant technology, the clinician has more tools to handle complex cases of osseous defects using bone graft materials to augment the sites where the volume of bone would otherwise prohibit the implant placement. There are various materials available for correcting dento-alveolar ridge deformities and augmenting other types of osseous defects. These materials include autogenous bone, demineralized freeze-dried bone allograft (DFDBA), xenografts, alloplasts, and various resorbable and non-resorbable membranes.

Autogenous bone is still considered the gold standard in bone grafting procedures [3–5], notwithstanding its limited availability and the need for a second surgery. The results can be variable, depending on the quality/quantity of the bone used, the preparation of the bone, and the method of placement into the surgical site.

Although there have been reports showing poor results with DFDBA when implanted into extraction sites [4,6], it is widely used for bone grafting. Xenografts have also been a popular choice and are said to stimulate bone formation and to be resorbable as well. Recent reports have shown that these materials remain in the implant site for years before resorbing. The persistence of the material in the site over extended time periods could lead to stress concentration and ultimate bone failure [7–9]. In addition, the presence of proteins of bovine origin in certain xenograft materials, especially in Europe, is still being investigated in relation to the problem of the transmissible spongiform encephalopathy, a disease affecting cattle, but likely transmissible to humans [10].

A number of alloplastic materials have been developed to overcome many of the problems described here. These materials include calcium phosphates, calcium sulfates, and bioactive glasses [11–15]. In general, these materials are said to be osteoconductive, and may or may not be resorbable. Different types of bioactive glass have been used clinically to regenerate bone loss as a result of periodontal disease for over 10 years. The bioactivity of these glasses was also verified for physical parameters, like surface morphology and granule size, and not only their chemical composition. As an example, we quote the work of Ducheyne [16], who synthesized a glass called Biogran[®] that has the same chemical composition of PerioGlas[®], and differs in the granule size range, 300–500 μm instead of 90–710 μm , and it is claimed to have a higher biocompatibility.

There has been a number of clinical studies that have demonstrated consistent results in treating intrabony defects [17]. One study showed that the clinical results of one type of bioactive glass were equivalent to DFDBA in treating two and three wall defects [18]. More recent studies

have shown that when used to regenerate bone in fresh extraction sites or to augment the maxillary sinus, these materials fully resorb over a 6-to-13-month time period [19,20]. The materials have been said to be osteostimulative [21] in that they enhance the bone regeneration of the defect site.

The purpose of this study is to histologically and ultrastructurally evaluate three cases of bone augmentation procedures performed in the mandible, using bioactive glass with a subsequent dental implant placement and to report the resorbability of the bioactive glass and the bone regeneration in the implantation site.

MATERIALS AND METHODS

The cases included in this study and reported in Table 1 are all mandibular teeth that were diagnosed with advanced periodontal disease in need of extraction. All the patients were treated with the following medications: (1) Amoxicillin (1g bid, for 1 day before tooth extraction and continued for 6 days), (2) Metasone retard (1 mg/day for 5 days) and (3) NSAID on demand bid. Probing depth was measured before tooth extraction in each case. The implant sites were prepared by drilling at a speed not exceeding 40 rpm and assuring torque at 32N, without irrigation. This facilitated the harvesting of autogenous bone required to be mixed with bioactive glass (PerioGlas[®], Novabone, USA) (composition: 45% (in weight per cent) SiO₂, 24.5% CaO, 24.5% Na₂O, 4% P₂O₅; size: 90–710 μm) and for a better control of implant alignment. Radiographs were obtained at various times including baseline, immediate post-operative and at 6, 12, 18 (data not shown) and 24 months. At each follow-up, routine hygiene was performed. With prior consent from the patients, biopsies were taken during the six-month follow-up visit.

Case 1 – The patient presented with a periodontal abscess of an endodontically involved molar with 3° furcation lesion having a probing depth of 7 mm, necessitating extraction (Figure 1(a)). The patient was prescribed prophylactic antibiotics for 1 week before extraction of 4.6

Table 1. List of the cases.

Case	Gender	Age	GG health	Smoker	BOP (%)	FMPS (%)
1	M	40	Good	Yes	<20	<20
2	M	60	Good	No	<20	<20
3	F	42	Good	No	>20	>20

GGHealth – Good general health; BOP – Bleeding on probing; FMPS – Full mouth plaque score.

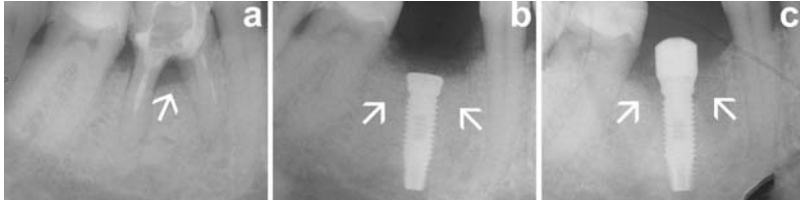


Figure 1. (a) X-ray image of a grade 3 furcation involvement in the lower right first molar (see arrow); (b) implant site and socket filled with the bioglass granules after the implant procedure (see arrows); and (c) fixture and healing abutment 6 months after the implant. Arrows show the biopsy sites.

(lower right first molar). A full thickness flap was raised without vertical releasing incisions, without compromising the flap vascularization and the tooth was extracted, taking care to preserve the bone structure. The socket was then thoroughly cleaned and the implant (Osseotite[®] Standard, 3i Implant Innovation, USA) placed in the interradicular bone. The implant length was chosen to ensure primary stability in the bone. The remaining socket of the extraction site, around the implant, was filled with a mixture of PerioGlas[®] and autogenous bone. The autogenous bone had been harvested from the drilling process during the preparation of the implant site. No additional sites were used to harvest bone (Figure 1(b)). A healing abutment was placed on the implant and the implant was covered for 6 months. At the time of placement of the abutment (6 months from surgery) a biopsy was performed distal to the abutment (Figure 1(c)). An additional small biopsy was taken from the soft tissue around the collar of the implant. The healing abutment was replaced on the implant and the final restoration was made 2 weeks after the biopsy. The abutment was tightened at 32 N with a dynamometric tool controlled by endo-oral radiography (Trophy RGVui Digital Radiography System, Trophy Radiology, France) using Rinn technique and personal bite blocks to ensure consistent alignment.

Case 2 – The patient presented with a high mobility of the cantilever bridge due to root fracture of 3.5 (lower left second premolar) (Figure 2(a)). The bridge was then removed and the tooth extracted and subsequently its socket was filled with a mixture of PerioGlas[®] and autogenous bone (Figure 2(b) and (c)) to maintain proper volume of bone for the esthetics of the final prosthesis. An implant could not be placed in the socket because of the lack of buccal bone, as an implant with dimensions of 4 mm diameter and 10 mm length would compromise the implant primary stability in the alveolar bone. A length more than 10 mm could penetrate the mandibular nerve canal, causing paresthesia.

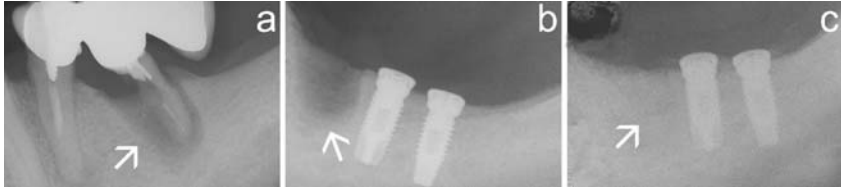


Figure 2. (a) X-ray image of wide bone resorption due to root fracture (see arrow); (b) arrow shows the bone socket before bioactive glass implantation; and (c) bone socket filled with PerioGlas[®] granules plus autogenous bone (see arrows).

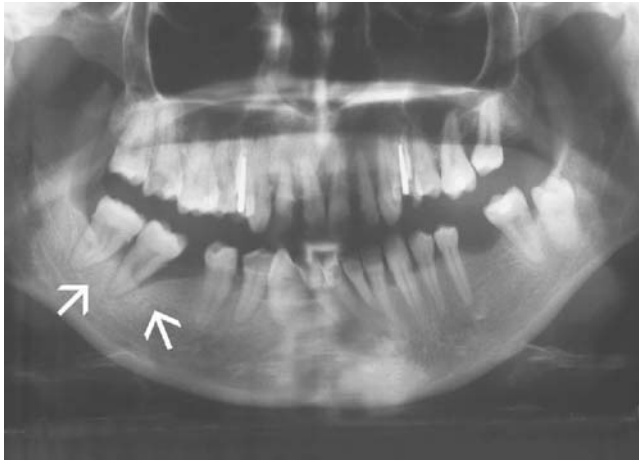

Figure 3. Panoramic X-ray. Arrows indicate the 4.7 area before operation.

Full thickness flap with vertical mesial release incision was performed for a two-stage implant technique distally positioned to the graft-filled socket (Osseotite[®] Standard, 3i Implant Innovation, USA). The periosteum was released before suturing. At 6 months, a biopsy was taken from the filled socket and the implants were loaded. UCLA abutments (3i Implant Innovation, USA) were placed and tightened at 32N using a dynamometric tool controlled by endo-oral radiography (Trophy RGVui Digital Radiography System, Trophy Radiology, France) using Rinn technique and personal bite blocks.

Case 3 – The patient presented with an advanced periodontal lesion as a result of poor oral hygiene and exhibited bleeding on probing (BOP) and full mouth plaque score (FMPS) >20%, and a probing depth of about 12 mm (Figure 3).

In this case, 4.7 (lower right second molar) was extracted and the socket was filled with a mixture of PerioGlas[®] and the patient's blood. The graft site was then covered with a PLA membrane (Atrisorb[®], Atrix Laboratories, USA) for better protection and the mesiovestibular periodontal pocket of 4.8 (lower right third molar) was also grafted as it presented a 7-mm probing depth. The periosteum was dissected to release the flap and to achieve a better primary healing of the wound.

A biopsy was taken after 6 months and two implants (Osseotite[®] Standard, 3i Implant Innovation, USA) were placed with a one-step technique keeping mounting devices in place for a better healing of the soft tissues. The implants were loaded after 6 months and intraoral radiographs (Trophy RGVui Digital Radiography System, Trophy Radiology, France) and orthopantomographs (Cranex Tome CEPH, Soredex, Finland) were taken during the two-year follow-up visit.

The biopsies were fixed in 4% paraformaldehyde and dehydrated in ethanol. After embedding in polymethylmethacrylate, the samples were sectioned with a diamond saw (Accutom, by Struers, Denmark) into a 200- μ m thick and a 20- μ m thick slice, respectively for scanning electron microscopy (SEM) (QUANTA-ESEM by FEI, The Netherlands) and for histological observation (Standard 25, Zeiss, Germany). The thin non-decalcified sections were stained with Stevenel's blue/Van Gieson's picrofuchsin or hematoxylin-eosin, suitable to show calcium deposition and bone morphology. The 200- μ m thick sections were first micro-radiographed and then polished and prepared for SEM observations that were performed both in secondary emitted and backscattered mode (BSE). Elemental analyses and X-ray dot maps were carried out with an energy dispersive system (EDS, by EDAX, USA) to detect the topographic distribution of the elements in the PerioGlas[®] granules after implantation.

RESULTS

The histological and SEM analyses of the biopsy of Case 1 taken from the soft tissue around the implant collar show minimal inflammatory reaction; the cellular reaction around the particles is characterized by normal connective tissue with little infiltrate, demonstrating the compatibility of bioactive glass particles in contact with the soft tissues. The outer layer of the particles shows signs of infiltration and hematoxylin-eosin staining indicates the presence of a calcium-rich layer. The degradation also affects the particle core where cell colonization is observed (Figure 4).

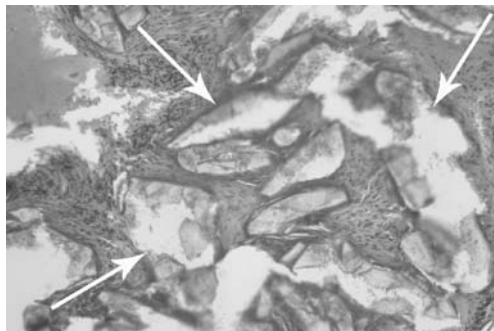


Figure 4. Histologic hematoxylin–eosin stained section of the biopsy in the bone defect (10 \times). Glass granules are still visible after 6 months from implantation (see arrows).

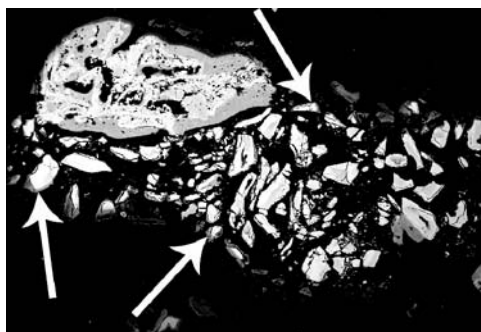


Figure 5. Scanning electron micrograph of the total bone biopsy. Glass granules (whiter) are still visible in bone (see arrows).

At low magnification under the SEM (Figure 5), the biopsy shows bone and granules that are not yet completely resorbed. They appear whiter since they are electronically denser than bone. The grey level contrast in the image clearly delineates older bone (lighter grey) from newly formed bone.

In the apical part of the biopsy, wide zones of mineralization are seen, probably due to autogenous bone pieces that were mixed with PerioGlas[®] during implantation and due to a more intimate contact with the bone walls. Trabecular bone was seen to have grown directly onto the surface of the glass particles away from the bone walls. Some granules appear to have an empty core indicating a resorption of the particles. In addition, new bone can be seen growing within the

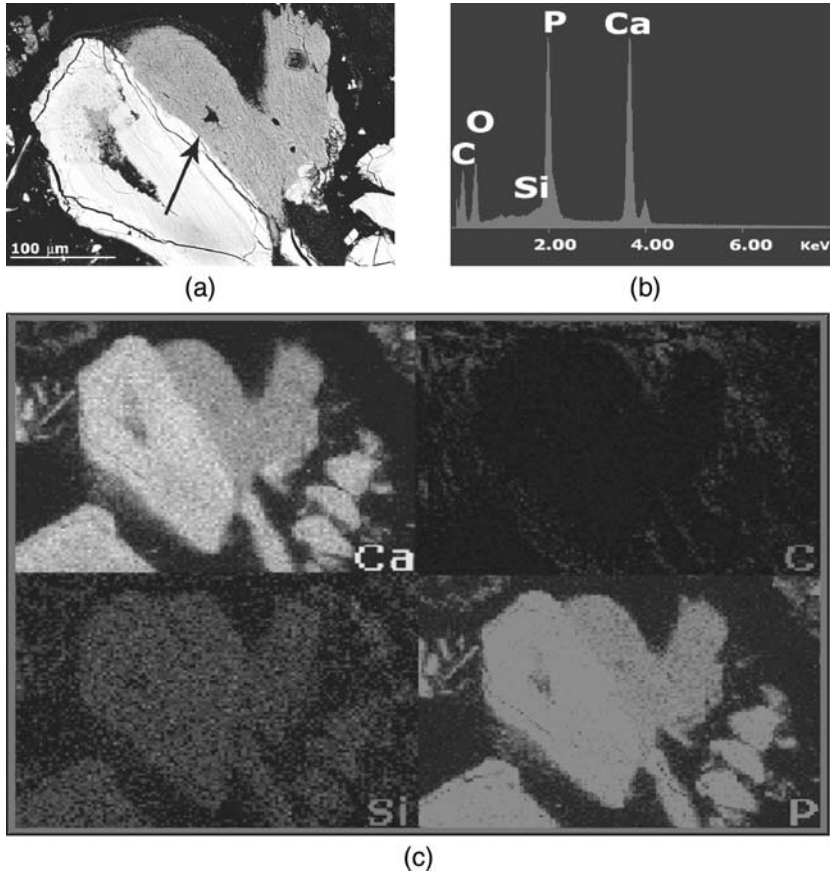


Figure 6. (a) SEM–BSE image of a degraded glass granule (whiter area) surrounded by new bone. Inside the particle there is a pouch where new bone is forming. The cracks cross the outer layer. The arrow indicates the interface of the glass granule–new grown bone. (b) EDS spectrum of the X-ray analyses in the outer layer showing mainly the presence of calcium and phosphorus. (c) X-ray dot maps for calcium (Ca), carbon (C), silicon (Si), and phosphorus (P) indicate the total glass transformation in a calcium phosphate.

excavated pouch of the bioactive glass particle in the SEM image (Figure 6(a)). The appearance of the material adjacent to the newly formed bone is similar to precipitated calcium phosphate (Figure 6(b)).

After 6 months of implantation, the glass underwent a physical-chemical transformation and a significant part had already been transformed into calcium phosphate, as shown by the X-ray dot maps for silicon, calcium, and phosphorus (Figure 6(c)).

The bioglass bioactivity mechanism was already described by many authors [22,23] and it could be divided into different steps: (a) ionic diffusive processes from the glass, (b) its transformation into a hydrated gel, (c) contradiffusion from the extracellular matrix toward the glass surface, and finally (d) precipitation of calcium phosphate in the glass.

Radiographic images of the implant site after 6 (Figure 1(c)) and 24 months (Figure 7) show good maintenance of the bone collar around implant.

Histological observation of the biopsy of Case 2 shows significant bone growth among the bioactive glass particles, which appear degraded: some are intimately connected to the newly formed bone while others are still surrounded by noninflammatory connective tissue. Figure 8 is an undecalcified histologic image (Van Gieson's picrofuchsin) of

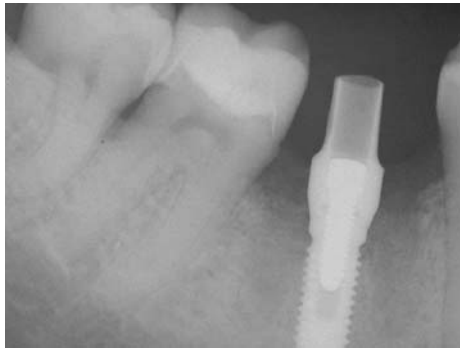


Figure 7. X-ray images of Case 1 implant site after 24-month follow-up.

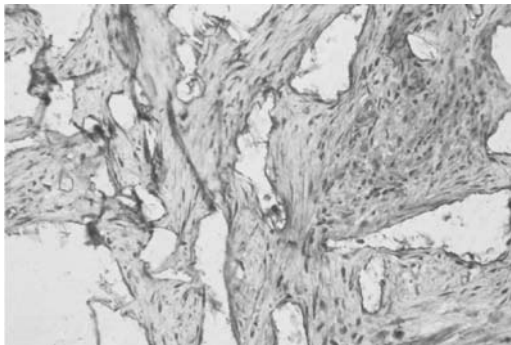


Figure 8. Histological view of a picrofuchsin-stained section. (10 \times) No sign of adverse tissue reactions are visible.

bioactive glass particles inside the pocket. There was no indication of any inflammatory infiltrate.

Scanning electron micrographic investigations show new bone grown both on the particles surface (Figure 9, on the right side) and inside their core (Figure 9, on the left side) indicating an early stage of new bone formation.

Radiographic images show excellent maintenance of the bone collar around implants, even at two-year follow-up (Figure 10). Radiographic density of the regenerated bone appears as normal bone even during the

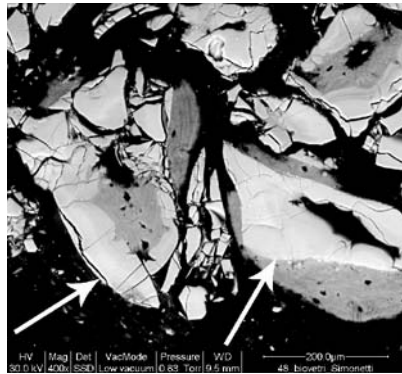


Figure 9. SEM-BSE image: arrows indicate degraded glass granules completely surrounded and invaded by new bone formation.

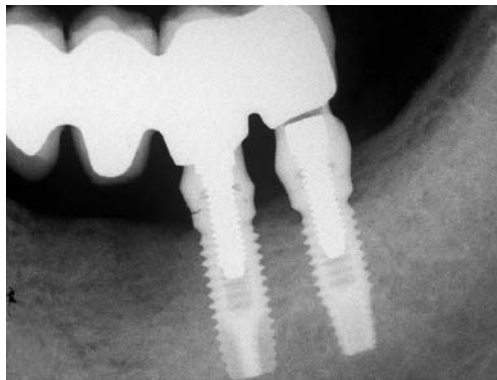


Figure 10. X-ray image of Case 2 implant site after 24-month follow-up.

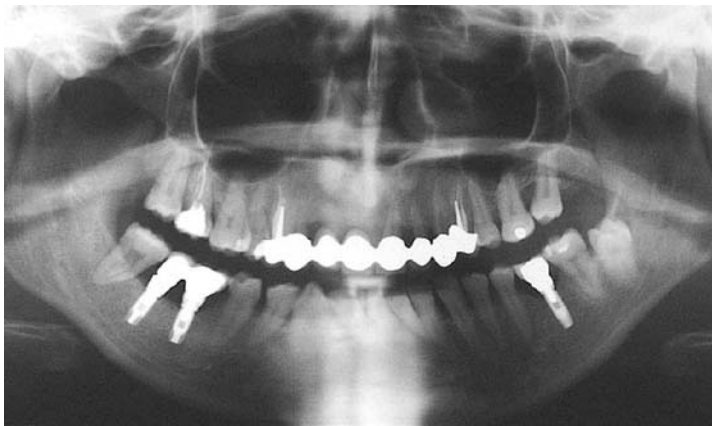

Figure 11. Panoramic X-ray image of Case 3 after 24-month follow-up.

early stages. At the final follow-up of these cases, the bone volume was maintained under loading of the implants when compared with the initial graft volume. In Case 2, where there was no implant placed, the volume was also maintained.

In Case 3, there was less bone formation, although the particle reactivity appeared to be comparable to the other cases. The biopsy in this case was taken from the crestal region and may not be representative of bone formation occurring more apically in the defect. The two-year post-operative clinical results (Figure 11) in this case are similar to the other cases and the implants have been successfully loaded and are stable. Thus, the early evidence of lower bone formation in the biopsy did not appear to have an adverse effect on the clinical result.

In two of the three cases, islands of bone formation were noted in the middle of the defect, far from the bone wall. Bone grows on the glass granule surface that works as a scaffold through the formation of a calcium phosphate-rich layer that induces the colonization of the bone cells.

DISCUSSION

From the results, it is very clear that the use of PerioGlas[®] has significantly influenced the prognosis in all the three cases described here. All the three cases were followed up at the end of two years in a completely loaded state and were all stable and healthy.

PerioGlas[®] is one of the synthetic bone regenerative products belonging to the group of 'glasses and ceramics'. Though hydroxyapatite (HA) has been the most widely used alloplast, its prolonged resorption/remodeling time and its brittleness have led to the development of other alloplasts with improved properties. PerioGlas[®] is made up of bioactive glass particles ranging from 90 to 710 μm , and exhibits properties significantly superior to those of the other alloplasts. Like all synthetic grafts, PerioGlas[®] does not require a second surgery and there is no risk of disease transmission or immunologic response. The three-dimensional scaffold formed *in situ* upon implantation is a critical determinant of the speed of remodeling and regeneration. PerioGlas[®] particulate imparts a greater surface area for the exposure of nutrients, vascularization, and bony ingrowth consequently leading to faster bone regeneration. Unlike most of the other alloplasts that are bioinert, PerioGlas[®] belongs to the class of bioactive regenerative materials. Not only does it act as an osteoconductive scaffold providing an appropriate environment in which bone cells and BMPs can adhere and proliferate, but also interacts with the surrounding tissues and imparts an osteostimulatory effect [24].

The ability of PerioGlas[®] to stimulate bone formation in the presence of osseous tissues but not in soft tissues makes it different from osteoinductive products. PerioGlas[®] is neither osteogenic nor osteoinductive, but a number of *in vivo* studies have demonstrated a more rapid bone formation with Bioglass particles. This has been attributed to the 'osteopromotion' and 'osteoproduction' principles, which are used interchangeably with 'osteostimulation.' Also, the viability and proliferation potential of osteoblasts (MG63) have been shown to be exemplified in the presence of bioglass particles [25]. Because of its ionic release mechanism of action, PerioGlas[®] negates the acidic pH at the wound site, hence reducing the inflammation. *In vitro* tests have also shown that PerioGlas[®] can decrease the clotting time by at least 25%. More tests have proven a significant reduction (3 log) in the bacterial population. There have also been studies revealing an increased osteocalcin and alkaline phosphatase levels [26] at the recipient site in the presence of PerioGlas[®], indicating that all these mechanisms ultimately help in providing a favorable site for osteoblast recruitment and osseous regeneration.

CONCLUSIONS

PerioGlas[®] shows very good handling properties during placement and does not require elaborate mixing techniques or equipment.

The surgical sites showed rapid healing of soft tissue and the material appeared to enhance hemostasis. The material appears to maintain graft volume and shows excellent biocompatibility.

These results show that bioactive glass particles are a viable synthetic graft material for use when grafting is necessary in conjunction with load bearing dental implants as it exhibits reliable and lasting results.

ACKNOWLEDGMENTS

The authors thank Mrs R. Salvatori for the technical help. The research was supported by University of Modena and Reggio Emilia.

REFERENCES

1. Brånemark, P. (1995). Ten-year Survival Rates of Fixed Protheses on Four or Six Implants Ad Modum Branemark in Full Edentulism, *Clin. Oral Implants Res.*, **6**(4): 227–231.
2. Lekholm, U., Gunne, J. and Henry, P. (1999). Survival of the Brånemark Implant in Partially Edentulous Jaws: A 10-year Prospective Multicenter Study, *Int. J. Oral Maxillofac Implants*, **14**(5): 639–645.
3. Goldberg, V.M. and Stevenson, S. (1987). Natural History of Autografts and Allografts, *Clin. Orthop. Related Res.*, **225**: 7–16.
4. Becker, W., Clokie, C., Sennerby, L., Urist, M.R. and Becker, B.E. (1998). Histologic Findings after Implantation and Evaluation of Different Grafting Materials and Titanium Micro Screws into Extraction Sockets: Case Reports, *J. Periodontol.*, **69**: 414–421.
5. Becker, W., Urist, M. and Becker, B. (1996). Clinical and Histologic Observations of Sites Implanted with Intraoral Autogenous Bone Grafts or Allografts, 15 Human Case Reports, *J. Periodontol.*, **67**(10): 1025–1033.
6. Froum, S., Cho, S.C., Rosenberg, E., Rohrer, M. and Tarnow, D. (2002). Histological Comparison of Healing Extraction Sockets Implanted with Bioactive Glass or Demineralized Freeze-dried Bone Allograft: A Pilot Study, *J. Periodontol.*, **73**(1): 94–102.
7. Artzi, Z., Tal, H. and Dayan, D. (2001). Porous Bovine Bone Mineral in Healing of Human Extraction Sockets: 2. Histochemical Observations at 9 months, *J. Periodontol.*, **72**(2): 152–159.
8. Hallman, M., Lundgren, S. and Sennerby, L. (2001). Histologic Analysis of Clinical Biopsies Taken 6 Months and 3 Years after Maxillary Sinus Floor Augmentation with 80% Bovine Hydroxyapatite and 20% Autogenous Bone Mixed with Fibrin Glue, *Clin. Implant Dent. Relat. Res.*, **3**(2): 87–96.
9. Valentini, P., Abensur, D., Densari, D., Graziani, J.N. and Hammerle, C.H.F. (1998). Histological Evaluation of Bio-Oss in a 2-Stage Sinus Floor Elevation and Implantation Procedure, A Human Case Report, *Clin. Oral Impl. Res.*, **9**(1): 59–64.

10. Schwartz, Z., Weesner, T., van Dijk, S., Cochran, D.L., Mellonig, J.T., Lohmann, C.H., Carnes, D.L., Goldstein, M., Dean, D.D. and Boyan, B.D. (2000). Ability of Deproteinized Cancellous Bovine Bone to Induce New Bone Formation, *J. Periodontol.*, **71**(8): 1258–1269.
11. Sailer, H.F. and Weber, F.E. (2000). [Bone Substitutes] Mund Kiefer Gesichtschir, **4**(Suppl. 1): S384–S391.
12. Wetzel, A.C., Stich, H. and Caffesse, R.G. (1995). Bone Apposition onto Oral Implants in the Sinus Area Filled with Different Grafting Materials, A Histological Study in Beagle Dogs, *Clin. Oral Implants Res.*, **6**(3): 155–163.
13. Low, S.B., King, C.J. and Krieger, J. (1997). An Evaluation of Bioactive Ceramic in the Treatment of Periodontal Osseous Defects, *Int. J. Periodontics Restorative Dent.*, **17**(4): 359–367.
14. Zamet, J.S., Darbar, U.R. and Griffiths, G.S. (1997). Particulate Bioglass as a Grafting Material in the Treatment of Periodontal Intrabony Defects, *J. Clin. Periodontol.*, **24**(6): 410–418.
15. Froum, S.J., Weinberg, M.A. and Tarnow, D. (1998). Comparison of Bioactive Glass Synthetic Bone Graft Particles in the Treatment of Human Periodontal Defects, A Clinical Study, *J. Periodontol.*, **69**(6): 698–709.
16. Ducheyne, P. (1999). Effect of Bioactive Glass Particle Size on Osseous Regeneration, *J. Biomed. Mater. Res.*, **46**(2): 301–304.
17. Ong, M.M., Eber, R.M., Korsnes, M.I., MacNeil, R.L., Glickman, G.N., Shyr, Y. and Wang, H.L. (1998). Evaluation of a Bioactive Glass Alloplast in Treating Periodontal Intrabony Defects, *J. Periodontol.*, **69**(12): 1346–1354.
18. Lovelace, T.B., Mellonig, J.T., Meffert, R.M., Jones, A.A., Nummikosk, P.V. and Cochran, D.L. (1998). Clinical Evaluation of Bioactive Glass in the Treatment of Periodontal Defects in Humans, *J. Periodontol.*, **69**(9): 1027–1035.
19. Froum, S., Cho, S.C., Rosenberg, E., Rohrer, M. and Tarnow, D. (2002). Histological Comparison of Healing Extraction Sockets Implanted with Bioactive Glass or Demineralized Freeze-dried Bone Allograft: A Pilot Study, *J. Periodontol.*, **73**(1): 94–102.
20. Tadjoedin, E.S., de Lange, G.L., Bronckers, A.L., Lyaruu, D.M. and Burger, E.H. (2003). Deproteinized Cancellous Bovine Bone (Bio-Oss) as Bone Substitute for Sinus Floor Elevation, A Retrospective, Histomorphometrical Study of Five Cases, *J. Clin. Periodontol.*, **30**(3): 261–270.
21. Loty, C., Sautier, J.M., Tan, M.T., Oboeuf, M., Jallot, E., Boulekbache, H., Greenspan, D. and Forest, N. (2000). Bioactive Glass Stimulates *in vitro* Osteoblast Differentiation and Creates a Favorable Template for Bone Tissue Formation, *J. Bone Min. Res.*, **16**(2): 231–239.
22. Gatti, A., Valdrè, G. and Tombesi, A. (1996). Importance of the Microanalysis in Understanding the Mechanism of Transformation in the Active Glassy Materials, *J. Biomedical Mat. Res.*, **31**(4): 475–480.
23. Gatti, A. and Zaffe, D. (1991). Short Time Behaviour of Active Glass Granules in Bone Defects Repair, *Biomaterials*, **12**(5): 497–504.
24. Gatti, A. and Zaffe, D. (1991). Long Term Behaviour of Active Glasses in Sheep's Mandibular Bone, *Biomaterials*, **12**(3): 345–350.

25. Xynos, I.D., Edgar, A.J., Buttery, L.D., Hench, L.L. and Polak, J.M. (2000). Ionic Products of Bioactive Glass Dissolution Increase Proliferation of Human Osteoblasts and Induce Insulin-like Growth Factor II mRNA Expression and Protein Synthesis, *Biochem. Biophys. Res. Commun.*, **276**(2): 461–465.
26. Price, N., Bendall, S.P., Frondoza, C., Jinnah, R.H. and Hungerford, D.S. (1997). Human Osteoblast-like Cells (MG63) Proliferate on a Bioactive Glass Surface, *J. Biomed. Mater. Res.*, **37**(3): 394–400.