



HAL
open science

Structural brain changes following peripheral vestibulo-cochlear lesion may indicate multisensory compensation

Christoph Helmchen, Jan C. Klinkenstein, Alexandra Krüger, Jan Gliemroth, Christian Mohr, Thurid Sander

► To cite this version:

Christoph Helmchen, Jan C. Klinkenstein, Alexandra Krüger, Jan Gliemroth, Christian Mohr, et al.. Structural brain changes following peripheral vestibulo-cochlear lesion may indicate multisensory compensation. *Journal of Neurology, Neurosurgery and Psychiatry*, 2010, 82 (3), pp.309. 10.1136/jnnp.2010.204925 . hal-00570140

HAL Id: hal-00570140

<https://hal.science/hal-00570140>

Submitted on 27 Feb 2011

HAL is a multi-disciplinary open access archive for the deposit and dissemination of scientific research documents, whether they are published or not. The documents may come from teaching and research institutions in France or abroad, or from public or private research centers.

L'archive ouverte pluridisciplinaire **HAL**, est destinée au dépôt et à la diffusion de documents scientifiques de niveau recherche, publiés ou non, émanant des établissements d'enseignement et de recherche français ou étrangers, des laboratoires publics ou privés.

Structural brain changes following peripheral vestibulo-cochlear lesion may indicate multisensory compensation

Christoph Helmchen^{*}, Jan C. Klinkenstein^{*}, Alexandra Krüger[†],
Christian Mohr[#], Thurid Sander^{*}

NEUROIMAGE NORD, Dept. of Neurology^{*}, Otolaryngology[†], and Institute of
Neuroradiology[#], University of Lübeck

Send correspondence to:

Prof. Dr. Christoph Helmchen, M.D.
NEUROIMAGE NORD &
Department of Neurology
University Hospitals Schleswig-Holstein
Campus Lübeck
Ratzeburger Allee 160
D-23538 Lübeck
Germany
phone: +49-451-500-2927
FAX: +49-451-500-2489
e-mail: christoph.helmchen@neuro.uni-luebeck.de

Figures: 2
Tables: 2
References: 42

Keywords: vestibular lesion, vestibular compensation, voxel-based morphometry

Abbreviations: SI = primary somatosensory cortex, IPL = inferior parietal lobe; STG = superior temporal gyrus; MT = middle temporal area; GMV = grey matter volume, VOR = vestibulo-ocular reflex, CVS = clinical vestibular score, SVV = subjective visual vertical, rCGM = regional cerebral glucose metabolism, BVF = bilateral vestibular failure, AN = acoustic neuroma, VN = vestibular neuritis, VBM = voxel-based morphometry

Licence for Publication: The Corresponding Author has the right to grant on behalf of all authors and does grant on behalf of all authors, an exclusive licence (or non exclusive for government employees) on a worldwide basis to the BMJ Publishing Group Ltd to permit this article (if accepted) to be published in JNNP and any other BMJ PGL products and sublicences such use and exploit all subsidiary rights, as set out in our licence.

ABSTRACT

Background: Do central mechanisms account for the variability of clinical recovery following peripheral vestibulo-cochlear lesions?

Objective: To investigate structural (morphological) plasticity in the human brain following unilateral vestibulo-cochlear lesions which might contribute to central vestibular compensation.

Methods: We compared regional grey matter volume (GMV) changes in patients after surgical removal of unilateral acoustic neuroma with age-matched control subjects. We hypothesized morphometric changes in the vestibular and auditory cortices which may be related to functional disability scores. Patients were examined with a battery of neuro-otological tests and clinical scores to assess vestibular and auditory disability.

Results: Voxel-based morphometry (VBM) was used for categorical comparison between patients and age- and gender- matched controls. GMV increase was found bilaterally in primary somatosensory cortices and motion sensitive areas in the medial temporal gyrus (MT). Simple regression analysis revealed GMV increase (i) in the contralesional superior temporal gyrus / posterior insula to be correlated with decreasing clinically assessed vestibular deficits; (ii) in the contralesional inferior parietal lobe with decreasing functional impairment of daily living activities; and (iii) in the contralesional auditory cortex (Heschl gyrus) with decreasing hearing impairment.

Conclusions: These data **may** suggest structural cortical plasticity in multisensory vestibular cortex areas of patients with unilateral peripheral vestibulo-cochlear lesion after surgical removal of acoustic neuroma. As changes of GMV were related to vestibular function structural brain changes may reflect central mechanisms of **vestibular** compensation.

INTRODUCTION

Central processing of vestibular function is crucially determined by bilateral peripheral input. Vestibular tone imbalance reflects a pathological asymmetry of bilateral vestibular activity in the brain. In the acute stage vestibular tone imbalance causes severe direction-specific oculomotor (spontaneous nystagmus), perceptual (vertigo) and postural deficits (ipsilesional falls). It remains a matter of debate why patients with the *same* persistent peripheral vestibular deficit show quite different vestibular recovery. The peripheral vestibular deficit alone does not seem to determine functional recovery.¹ Despite only partial or incomplete restoration of neural activity in the peripheral vestibular afferents many patients with vestibular neuritis or unilateral surgical vestibular lesions recover probably due to mechanisms of central compensation.^{1, 2} Vestibular rehabilitation may not only involve restoration of peripheral vestibular function but also compensation by central recalibration^{3, 4}, or substitution, i.e. by the somatosensory⁵ or visual system.⁶

While there is some physiological, clinical^{1, 3} and functional imaging⁷ evidence for vestibular compensation following unilateral peripheral vestibular lesions², little is known about *structural* cerebral changes that might also account for the great variability in vestibular recovery. First evidence for structural brain changes following chronic vestibular deafferentation was found in patients with bilateral vestibulopathy.⁸ Based on a very specific *a priori* hypothesis of spatial memory and navigation deficits in patients with peripheral vestibular failure, patients with bilateral⁸ but not unilateral⁹ vestibulopathy showed hippocampal atrophy. In a recent study, we could identify grey matter changes in multisensory vestibular cortex areas of patients with vestibular neuritis which correlated with the clinical vestibular function and vertigo-related disability.¹⁰

Therefore the aim of this study in patients with a unilateral, irreversible peripheral vestibulo-cochlear lesion was to identify structural brain changes which may be related to auditory deficits and / or functional vestibular impairment and disability. We examined patients after unilateral vestibular lesion due to acoustic neuroma (AN) and hypothesized that putative structural brain changes may be related to functional disability possibly indicating vestibular and auditory compensation. We focussed our analysis on cortical structures involved in vestibular and auditory processing: Heschl gyrus, the superior temporal gyrus (STG), the inferior parietal lobule (IPL), posterior insula, anterior cingulate cortex, primary (S1) and secondary somatosensory cortex

(S2), middle temporal area (MT/V5) and hippocampus, and cerebellum, most of which belong to a multisensory vestibular cortical network in man.¹¹ They correspond closely to temporo-insular and temporo-parietal multisensory areas in the monkey¹² responding to vestibular, visual and somatosensory stimuli. These areas have been identified in previous activation studies using PET or fMRI following galvanic^{13, 14}, caloric^{15, 16} or click-evoked¹⁷ vestibular stimulation in healthy subjects as well as in patients with peripheral¹⁸ and central vestibular lesions^{19, 20}.

METHODS

We compared structural magnetic resonance images (T1-weighted three-dimensional gradient echos acquired with a fast low angle shot sequence [FLASH]) of patients following unilateral acoustic neuroma (AN) removal with individually age- and gender-matched healthy control subjects. To relate relative GMV changes of VBM to the clinical disability we used scores of objective and subjective vestibular impairment (see below).

Subjects

We studied 15 right-handed patients (4 male, 11 female) who suffered from a unilateral (left n=10; right n=5) acoustic neuroma (AN). Apart from AN, patients had no history of neurological or neuro-otological disease. All of them had a long-standing history (6.25 +/- 3.9 years) of hearing impairment, tinnitus or dizziness (**Table 1**). Tumors were surgically removed in all of them leaving most of the patients with severe unilateral peripheral vestibular lesions postoperatively. Patients were examined on average 37 ± 26 months (range: 3-81 months) after the operation using a battery of clinical neurological and neuro-otological tests, electrophysiological investigations, clinical disability scores and VBM (T1 GE 3D FLASH). Most patients had pronounced hypacusis or anacusis on the operated side following surgery (**Table 1**). We did not include patients with absent peak I wave in the auditory evoked potentials. Patients showed a variable degree of facial palsy on the operated side (**Table 1**). Functional parameters (i.e. caloric paresis, vestibular disability score) were correlated with changes in grey matter volume. Fifteen age- and gender-matched healthy subjects (4 male, 11 female, all right-handed) served as pair wise controls (individual matching between patient and control with ± 2 years maximal difference). Healthy control subjects were recorded in the same interval and with the same MRI

protocol as the patients. They had no history of neurological or vestibulo-cochlear disease and were normal on neuro-otological clinical examination. The age range of both groups was 35 – 67 years (mean age of AN patients: 56.6 ± 8.9 years; healthy control subjects 55.7 ± 9.1 years). Except for the antivertiginous medication (e.g. dimenhydrinate) in the first four days after surgery, patients did not receive any additional medication. In the hospital, patients had physiotherapy (modified version of Tjernstrom²¹) but they did not have standardized professional physiotherapy after their discharge from the hospital. All subjects gave written informed consent for participation in the study which was conducted in accordance with the declaration of Helsinki and approved by the Ethics committee of the University of Luebeck.

Clinical examinations

All subjects underwent a detailed neurological and neuro-otological examination by two independent, clinically experienced specialists of the University's vertigo unit. Except for partial ipsilesional facial palsy none of the patients had neurological signs beyond those resulting from the AN (hypacusis, signs of peripheral vestibulopathy), particularly there were no clinical signs of brainstem disease.

Neuro-otological signs of vestibular imbalance were assessed in a standardized fashion using a clinical vestibular score (CVS)¹⁰. This score is based on clinical examination covering (1) spontaneous nystagmus, (2) head-shaking nystagmus, (3) gaze-evoked nystagmus, (4) positional nystagmus, (5) head impulse test²², (6) ataxia of stance, (7) lateropulsion (8) lateropulsion during gait without horizontal head movements and (9) ataxia of gait with horizontal head movements, (10) tandem gait ataxia, (11) ataxia on body rotation (180 deg), and (12) the Fukuda stepping test. Each subtest was scored with "0" for absent, "1" for moderate and "2" for severe manifestation of the clinical sign. Accordingly, CVS could range from zero (normal) to 24 (maximum). Values above 3 were taken as pathological (range in healthy control subjects: 0-3).

Self-assessment of vestibular disability was performed using the Cohen and Kimball score (using 28 items consisting of instrumental, ambulation and functional tasks which were evaluated on a 0-10 scale with 0=normal).²³

Recordings of vestibular and hearing function

In addition to the head impulse test (Halmagyi-Curthoys test)²² peripheral vestibular excitability was tested by bithermal caloric irrigation and horizontal (yaw) rotation in the dark using DC electro-oculography. As a measure of unilateral vestibular loss, the mean peak slow-phase velocity during caloric irrigation with water at 30°C and 44°C was measured. Caloric hyporesponsiveness was calculated with the Jongkees's vestibular paresis formula.²⁴ Only patients with at least a 25 % canal paresis were included. Combined semicircular canal and otolithic function in the frontal (roll) plane was assessed by the subjective visual vertical (SVV) as described elsewhere.²⁵ Hearing function was assessed by pure tone audiogram and auditory evoked potentials.²⁵ Hearing impairment at the time of VBM recordings was classified according to the hearing score by Gardner and Robertson²⁶, with "5" indicating deafness, "4" referring to >90 dB threshold in pure tone audiometry, "3" covering 51-90 dB, "2" 31-50 dB, and "1" with 0-30 dB reflecting normal hearing.

MRI scanning and preprocessing

All high-resolution anatomical 3D images were acquired, preprocessed and analysed as described elsewhere¹⁰. T1-weighted three-dimensional gradient echos acquired with a fast low angle shot sequence [FLASH], TR = 15 ms, TE = 5 ms, flip angle 30°, acquisition matrix 256 x 256, isotropic voxel = 1 mm³) were acquired on a 1.5 T scanner (Siemens Symphony, Erlangen, Germany) with a standard head coil to reduce possible inhomogeneities and geometric variations due to magnetic field and gradient differences. Images were then analyzed using the optimized VBM protocol²⁷ with the VBM toolbox for SPM2 (<http://www.fil.ion.ucl.ac.uk/spm>, Wellcome Dept. of Imaging Neuroscience, London, UK), a fully automated technique for computational analysis of relative differences in local grey matter volume. Preprocessing of data involved coregistration, customized study template creation, spatial normalization, segmentation and spatial smoothing.²⁸ First, anatomical images of patients with acoustic neurinoma (AN) on the right side were mirrored on the left side to guarantee a homogenous group. Accordingly, images of corresponding (age- / gender-matched) control subjects for these patients were also mirrored. All data are calculated for left-sided AN, with left-sided GMV changes being ipsilesional due to surgically acquired deficits of vestibular and cochlear function. Images were coregistered to the standard MNI template (Montreal Neurological Institute, Montreal, Canada) of SPM2. All

anatomical images were then used to create a customized grey matter anatomical study template to determine the anatomy and reduce scanner- and population-specific bias. This template was smoothed with a Gaussian kernel of 8 mm full-width-at-half-maximum (FWHM). Spatial normalization of all images to this customized study template was performed using a nonlinear spatial transformation to remove differences in overall size, position, global space and to transfer images to the MNI space, which approximates the Talairach space. This normalization improved the overlap of corresponding anatomical structures.²⁹ Finally, using a modified mixture model cluster analysis, normalized images were corrected for non-uniformities in signal intensity and partitioned in grey (GM), white matter, cerebrospinal fluid (CSF) and background. To remove unconnected non-brain voxels, we applied a series of morphological erosions and dilatations to the segmented images.^{27, 30} No additional modulations were applied. The resulting grey images were smoothed with a Gaussian kernel of 12 mm FWHM. To account for age-related GMV changes, age of all subjects was introduced as a covariate of interest in the analysis.

Statistical analysis and correlation

Data of grey matter was analyzed using voxel-by-voxel multiple regression model (AnCova, VBM with SPM2) in a cross-sectional data analysis revealing differences in relative local GMV changes across the whole brain between AN patients and controls. To account for age-related GMV changes, age of all subjects was introduced as a covariate of interest in the analysis. We excluded all voxels of GMV of < 0.2 (of a maximum value of 1) to obtain fairly homogenous voxels. Because of our strong *a priori* hypothesis we focused our analysis of regional relative grey matter volume (GMV) changes in the regions of interest (ROI): thalamus, hippocampus, primary (S1) and secondary somatosensory cortex (S2), cerebellum, auditory cortex (Heschl gyrus), posterior insula, inferior parietal lobe (IPL), superior temporal gyrus, visual cortex, middle temporal area (MT/V5) most of which belong to a multisensory vestibular cortical network in man¹¹. They correspond closely to temporo-insular and temporo-parietal multisensory areas in the monkey responding to vestibular, visual and somatosensory stimuli. They have been identified in previous activation studies using PET or fMRI following galvanic¹³, caloric^{15, 16} or click-evoked¹⁷ vestibular stimulation in healthy human subjects as well as in patients with peripheral¹⁸ and central vestibular lesions^{19, 20}. Regions of interest (ROI) were created by using the ROI-tool of the WFU-Pick-Atlas in SPM. Regions were defined by appropriate

spheres (r between 15 and 30 mm) centered in the middle of the corresponding brain region. Twenty-three ROIs were used including 21.6 % (47585 / 221379 voxel) of the total brain volume. We generated a mask including those regions to identify relative GMV alterations between AN patients and controls according to our hypothesis.

This mask was applied to the multiple regression model (AnCova) in a second step for a *a priori* ROI based statistical analysis for significant relative GMV differences between AN patients and controls. Absolute GMV changes were not calculated. Statistics inside this ROI analysis were considered significant with $p < 0.005$ (uncorrected) and spatial extent > 200 voxel (ROI-analysis). Reported changes in grey matter volume did not survive a more conservative statistical threshold using corrections for multiple comparisons (FWE or FDR correction) best explained by the small study population ($n = 15$). High voxel threshold was determined to reduce false positive minor clusters³¹. In a third step we performed correlations (simple regression, SPM2) among the grey matter volume data (ROI) of the AN patients with their scores of vestibular and cochlear function (Table 2). Values of scores were mean corrected before entering the correlation analyses. These correlations were analyzed to elucidate the functional significance of the GMV changes. Correlations are considered significant for $p < 0.005$ unless otherwise stated. Thus, due to the limited population size, GMV data were used uncorrected for multiple comparisons, but their significance is underlined by the correlations. The Wake Forest University (WFU)-Pick Atlas³² was used to determine anatomical structures of GMV changes.

RESULTS

Patients

Clinical data of patients following surgical removal of AN are listed in Table 1. All patients had clinical signs of unilateral peripheral vestibular deficit, i.e. all patients showed a pathological head impulse test to the side of the operation. All patients showed severe caloric hyporesponsiveness [91.2 ± 16.27 %; 100 %=no caloric response) and severe hearing impairment (on average 4 ± 1.5 using the tonaudiometry of the Gardner-Score) on the lesion side (operation). Contralateral auditory and vestibular function was normal (Halmagyi-Curthoys test, caloric irrigation). Auditory evoked potentials yielded a normal peak I (amplitude and latency) and delayed or absent peaks II-V on the side of neurectomy while the contralateral side was normal. Subjective visual vertical (SVV) was on average within normal limits

(< 2°)²⁵. The clinical vestibular impairment score (CVS) was on average 8.0 ± 4.9 (0=normal, 24=complete vestibular deficit). Vestibular disability²³ was scored on average 3.0 ± 1.5 . Clinical scores of vestibular deficits and disability (CVS and Cohen Score) did not correlate with caloric hyporesponsiveness. CVS was neither correlated with the duration of symptoms nor the interval (months) since neurectomy.

Imaging data

The categorical comparisons revealed relative GMV-changes in brain regions of patients as compared to age-matched control subjects (**Table 2**). Apart from the inferior parietal and inferior and middle temporal lobe, there were bilateral GMV increases in bilateral primary somatosensory cortex (S1) and visual motion processing areas, i.e. middle temporal area (MT / V5) (**Fig.1**) and the cerebellar vermis (lobule VII). Relative decreases were found in frontal, temporal lobe and in the cerebellum (**Table 2**). There were no significant changes in hippocampus but the absence of a statistically significant effect in a particular region does not prove that the region is unaffected³³. No age-related effects were found (last two bars on the right in **Fig.1** indicate age as a covariate of interest).

Clinical correlations with the clinical assessment (CVS, hearing impairment) or the vestibular disability score were calculated using **linear** regression analyses. **Significant correlations with clinical scores were only found for relative GMV increases but not for decreases.** Details of the morphometric analysis are given in **Table 2**.

There was a contralesional GMV increase in the superior temporal gyrus (STG) and adjacent posterior insula which correlated negatively with CVS (**Fig. 2A**): patients with only subtle signs of vestibular impairment showed the largest relative increase in GMV. Conversely, relative GMV increase was smallest or absent with the largest scores of vestibular impairment resulting from the peripheral vestibular lesions.

Functional disability²³ was negatively correlated with relative GMV increase in the inferior parietal lobe (IPL) (**Fig. 2B**), i.e., GMV increase became smaller with increasing functional disability or, conversely, relative GMV increase was strongest with the least disability.

Relative GMV increases correlating with hearing impairment (Gardner Score) were found in the contralesional auditory cortex (Heschl gyrus) and adjacent posterior insula (**Fig. 2C**). Relative GMV increase was largest with the least hearing impairment and there was no or little GMV increase with hearing loss. This increase

was found on the contralesional side but there was a trend towards bilateral increase which just failed significance on the ipsilesional side. Correlations between relative GMV changes and the SVV were not performed as SVV was within normal limits. With respect to the major effects of relative GMV increases there were no correlations of GMV changes in MT/V5 or somatosensory cortex with clinical or subjective parameters. There were no correlations of GMV changes with the Brackmann Score of facial palsy, the size of the resected tumor or the duration lapsed since the operation.

DISCUSSION

Unilateral vestibulo-cochlear lesion elicited an increase of GMV in visual motion-sensitive areas (MT/V5) and in the primary somatosensory cortex as well as additional increases of GMV in regions of the multisensory vestibular cortex areas which correlated with clinical and electrophysiological parameters of vestibulo-cochlear impairment. This provides some first evidence that peripheral vestibular lesions elicit structural brain changes which might be related to substitution and compensation.

Acute vs. chronic vestibular lesions

Unilateral peripheral vestibular lesions elicit a vestibular tone imbalance not only at the level of the vestibular nuclei but also at the level of the thalamus³⁴ and the “primary” (e.g. posterior insula) and “secondary” (e.g. STG, IPL) vestibular cortex². In the acute stage this tone imbalance can be detected at cortical levels: using positron emission tomography (PET), patients with vestibular neuritis (VN) showed increased regional cerebral glucose metabolism (rCGM) in the contralesional multisensory vestibular cortex.⁷ This activation resembles vestibular stimulation in healthy subjects² which is stronger in the hemisphere ipsilateral to vestibular stimulation.¹⁵ This reflects an inherent physiological dominance of ipsilateral vestibular projections in bilateral cortical representation.¹⁵ Accordingly, ipsilateral vestibular projection is deficient in acute vestibular neuritis giving rise to a vestibular tone imbalance with contralesional rCGM increase due to persisting contralesional vestibular resting discharge.

Clinical signs of vestibular imbalance improve gradually within the first two months probably due to central compensation² and, accordingly, rCGM normalizes after 3 months in vestibular neuritis.⁷ At this time, 3 months after vestibular neuritis, morphological changes of GMV can be identified in the multisensory vestibular cortex of VN patients.¹⁰ The contralesional increase in GMV in retroinsular and posterior insula cortex and STG of VN patients might be the consequence of continuous contralesional increase of rCGM during the acute phase of vestibular neuritis.⁷ The asymmetry of neural activity is probably a driving force for vestibular compensation. Notably, this **may be** functionally significant as VN patients with large GMV increases showed least vestibular impairment. As peripheral regeneration (caloric responsiveness) is a rather poor indicator for vestibular compensation³⁵ GMV changes may be more valuable signs and possibly even contribute to functional recovery.

Here, we demonstrate that AN patients with unilateral peripheral vestibular lesion showed two changes contributing to the morphological substrate of a vestibular imbalance at cortical levels. First, GMV decreases were found in parts of the ipsilesional “secondary” vestibular cortex, e.g. STG and fusiform gyrus. This is also in accord with a deficient dominance of ipsilateral vestibular projections to the cortex.¹⁵ Second, there was a contralesional increase of GMV in the posterior insula. This is in accord with the failure of the ipsilateral dominance of vestibular projections¹⁵ using PET⁷ and VBM recordings¹⁰: the contralesional increase in rCGM is associated with an increase in GMV which **may** contribute to vestibular compensation as the increase was larger the better patients recovered from vestibular tone imbalance. As the vestibular system has a dominant representation in the non-dominant hemisphere¹⁵ **one might suspect this to be the reason for the right-hemispheric GMV changes being correlated with clinical impairment (scores)** in our patients. However, as GMV changes became stronger the less patients were clinically affected, we suspect compensation rather than hemispheric dominance as the responsible mechanism.

Unlike VN patients, our AN patients had substantial reduction of peripheral vestibular function **which may be related to the surgical tumor resection or the preceding tumor growth**. This probably accounts for the lack of GMV changes being correlated with caloric hyporesponsiveness. Additional evidence for vestibular compensation comes from structural changes in the inferior parietal lobe (IPL, BA40) which contains vestibular related neural activity^{17, 36} and showed bilateral, predominantly

contralesional increase in GMV; the larger the increase the less patients were functionally disabled.

Auditory lesions

Ascending projections of the auditory system to the cortex are generally thought to be bilateral. Using fMRI^{17, 37}, unilateral acoustic stimulation elicited bilateral but preferentially contralateral¹⁷ activation of the primary auditory cortex, i.e., the transverse temporal gyrus of Heschl in the depth of the Sylvian fissure. Little is known about the cortical and subcortical auditory tone imbalance following AN surgery. Here we demonstrate GMV increase in the contralesional auditory cortex (medial aspects of the Heschl gyrus) which was larger the less patients had hearing impairments. [At present we cannot conclude whether this is related to an improvement of central hearing processing \(e.g. in the attempt to improve signal detection³⁸\) or reflects the morphological response to an innervation tone imbalance in the auditory system elicited by the unilateral partial deafferentation.](#)

Changes in non-vestibular sensory systems

Somatosensory substitution

GMV increases in motion-sensitive areas (MT/V5) and primary somatosensory cortices may reflect upregulation of sensory interactions since patients with irreversible unilateral peripheral vestibulo-cochlear lesions rely stronger on other sensory afferents.² Upregulation of the sensitivity of other sensory systems, particularly the somatosensory system has been described before³⁹. There is a gradual buildup over weeks of an asymmetrical (ipsilesional) increase in muscle spindle input following unilateral vestibular lesion which demonstrates a unilateral increase in somatosensory weight, which may substitute for the missing vestibular input.⁴⁰ Our AN patients showed bilateral increase of GMV in the primary somatosensory cortex (S1) which might reflect an increase in the somatosensory weight following chronic peripheral vestibular deafferentation as patients have to rely more on somatosensory cues to stabilize balance, i.e. a substitution of the vestibular deficit by other non-vestibular systems.

Visual-vestibular interaction

Reciprocal inhibition between different sensory systems has been proposed as a fundamental working principle of the central nervous system in health and disease² and there is accumulating evidence for multisensory, e.g. visual-auditory, somatosensory-visual and visual-vestibular reciprocal interaction. For example, suppression of visual cortex activity may be important to reduce oscillopsia caused by vestibular nystagmus resulting from acute vestibular tone imbalance.⁴¹

We found a bilateral increase of GMV in middle temporal visual area (MT/V5). MT/V5 is involved in reciprocal visual-vestibular interaction.^{34, 41} Unlike MST and somatosensory cortex, MT does not contain vestibular neurons (Dora Angelaki, personal communication). Accordingly, the increase in GMV in MT may be related to non-vestibular substitution of the peripheral vestibular deficit. It might be a morphological consequence of the altered visual sensitivity and visual motion perception in patients with peripheral vestibular failure.^{6, 42}

Limitations of the study

It was the aim of this first study to investigate putative GMV changes which correlate with parameters of vestibular impairment. We are aware that specificity of compensation is additionally provided by longitudinal studies covering pre- and post-operative investigations at different intervals. Moreover, vestibular afferents were partially preserved in the tumor operation (incomplete [loss of](#) caloric excitability) which could have contributed to compensation, in particular if one takes the fairly large range of intervals between surgery and fMRI recordings into account. However, there was neither a correlation of GMV with caloric responsiveness nor with the duration since the operation. Finally, for ethical reasons, all patients received physiotherapy in the acute postoperative stage but based on our results future studies should investigate the effect of (different forms of) physiotherapy on these GMV changes.

Importantly, all variables listed above could have been confounds if we had *not* found any correlation. However, as we did, our interesting correlations now deserve further investigations.

Acknowledgements

TS was supported by a research grant E04-2009 from the University of Luebeck.

REFERENCES

1. Curthoys IS. Vestibular compensation and substitution. *Curr Opin Neurol* 2000;13(1):27-30.
2. Dieterich M, Brandt T. Functional brain imaging of peripheral and central vestibular disorders. *Brain* 2008;131(Pt 10):2538-2552.
3. Palla A, Straumann D. Recovery of the high-acceleration vestibulo-ocular reflex after vestibular neuritis. *J Assoc Res Otolaryngol* 2004;5(4):427-435.
4. Schmid-Priscoveanu A, Bohmer A, Obzina H, Straumann D. Caloric and search-coil head-impulse testing in patients after vestibular neuritis. *J Assoc Res Otolaryngol* 2001;2(1):72-78.
5. Strupp M, Arbusow V, Maag KP, Gall C, Brandt T. Vestibular exercises improve central vestibulospinal compensation after vestibular neuritis. *Neurology* 1998;51(3):838-844.
6. Dieterich M, Bauermann T, Best C, Stoeter P, Schlindwein P. Evidence for cortical visual substitution of chronic bilateral vestibular failure (an fMRI study). *Brain* 2007;130(Pt 8):2108-2116.
7. Bense S, Bartenstein P, Lochmann M, Schlindwein P, Brandt T, Dieterich M. Metabolic changes in vestibular and visual cortices in acute vestibular neuritis. *Ann Neurol* 2004;56(5):624-630.
8. Brandt T, Schautzer F, Hamilton DA, et al. Vestibular loss causes hippocampal atrophy and impaired spatial memory in humans. *Brain* 2005;128(Pt 11):2732-2741.
9. Hufner K, Hamilton DA, Kalla R, et al. Spatial memory and hippocampal volume in humans with unilateral vestibular deafferentation. *Hippocampus* 2007;17(6):471-485.
10. Helmchen C, Klinckenstein J, Machner B, Rambold H, Mohr C, Sander T. Structural changes in the human brain following vestibular neuritis indicate central vestibular compensation. *Ann NY Acad Sci* 2009;1164:104-115.
11. Dieterich M. Functional brain imaging: a window into the visuo-vestibular systems. *Curr Opin Neurol* 2007;20:12-18.
12. Guldin WO, Grusser OJ. Is there a vestibular cortex? *Trends Neurosci* 1998;21(6):254-259.
13. Stephan T, Deutschlander A, Nolte A, et al. Functional MRI of galvanic vestibular stimulation with alternating currents at different frequencies. *Neuroimage* 2005;26(3):721-732.
14. Bense S, Stephan T, Yousry TA, Brandt T, Dieterich M. Multisensory cortical signal increases and decreases during vestibular galvanic stimulation (fMRI). *J Neurophysiol* 2001;85(2):886-899.
15. Dieterich M, Bense S, Lutz S, et al. Dominance for vestibular cortical function in the non-dominant hemisphere. *Cereb Cortex* 2003;13(9):994-1007.

16. Fasold O, von Brevern M, Kuhberg M, et al. Human vestibular cortex as identified with caloric stimulation in functional magnetic resonance imaging. *Neuroimage* 2002;17(3):1384-1393.
17. Schlindwein P, Mueller M, Bauermann T, Brandt T, Stoeter P, Dieterich M. Cortical representation of saccular vestibular stimulation: VEMPs in fMRI. *Neuroimage* 2008;39(1):19-31.
18. Bense S, Deutschlander A, Stephan T, et al. Preserved visual-vestibular interaction in patients with bilateral vestibular failure. *Neurology* 2004;63(1):122-128.
19. Dieterich M, Bense S, Stephan T, Brandt T, Schwaiger M, Bartenstein P. Medial vestibular nucleus lesions in Wallenberg's syndrome cause decreased activity of the contralateral vestibular cortex. *Ann N Y Acad Sci* 2005;1039:368-383.
20. Dieterich M, Bartenstein P, Spiegel S, Bense S, Schwaiger M, Brandt T. Thalamic infarctions cause side-specific suppression of vestibular cortex activations. *Brain* 2005;128(Pt 9):2052-2067.
21. Tjernstrom F, Fransson PA, Kahlon B, et al. Vestibular PREHAB and gentamicin before schwannoma surgery may improve long-term postural function. *J Neurol Neurosurg Psychiatry* 2009;80(11):1254-1260.
22. Halmagyi GM, Curthoys IS. A clinical sign of canal paresis. *Arch Neurol* 1988;45(7):737-739.
23. Cohen HS, Kimball KT. Development of the vestibular disorders activities of daily living scale. *Arch Otolaryngol Head Neck Surg* 2000;126(7):881-887.
24. Jongkees LB, Maas J, Philipszoon A. Clinical nystagmography: a detailed study of electro-nystagmography in 341 patients with vertigo. *Pract Otorhinolaryngol (Basel)* 1962;24:65-93.
25. Rambold H, Boenki J, Stritzke G, Wisst F, Neppert B, Helmchen C. Differential vestibular dysfunction in sudden unilateral hearing loss. *Neurology* 2005;64(1):148-151.
26. Gardner G, Robertson JH. Hearing preservation in unilateral acoustic neuroma surgery. *Ann Otol Rhinol Laryngol* 1988;97(1):55-66.
27. Good CD, Johnsrude I, Ashburner J, Henson RN, Friston KJ, Frackowiak RS. Cerebral asymmetry and the effects of sex and handedness on brain structure: a voxel-based morphometric analysis of 465 normal adult human brains. *Neuroimage* 2001;14(3):685-700.
28. Ashburner J, Friston KJ. Voxel-based morphometry--the methods. *Neuroimage* 2000;11(6 Pt 1):805-821.
29. Hellier P, Barillot C, Corouge I, et al. Retrospective evaluation of intersubject brain registration. *IEEE Trans Med Imaging* 2003;22(9):1120-1130.
30. Good CD, Johnsrude IS, Ashburner J, Henson RN, Friston KJ, Frackowiak RS. A voxel-based morphometric study of ageing in 465 normal adult human brains. *Neuroimage* 2001;14(1 Pt 1):21-36.
31. Worsley KJ, Andermann M, Koulis T, MacDonald D, Evans AC. Detecting changes in nonisotropic images. *Hum Brain Mapp* 1999;8(2-3):98-101.

32. Maldjian JA, Laurienti PJ, Kraft RA, Burdette JH. An automated method for neuroanatomic and cytoarchitectonic atlas-based interrogation of fMRI data sets. *Neuroimage* 2003;19(3):1233-1239.
33. Ridgway GR, Henley SM, Rohrer JD, Scahill RI, Warren JD, Fox NC. Ten simple rules for reporting voxel-based morphometry studies. *Neuroimage* 2008;40(4):1429-1435.
34. Dieterich M, Bense S, Stephan T, Yousry TA, Brandt T. fMRI signal increases and decreases in cortical areas during small-field optokinetic stimulation and central fixation. *Exp Brain Res* 2003;148(1):117-127.
35. Palla A, Straumann D, Bronstein AM. Vestibular neuritis: Vertigo and the high-acceleration vestibulo-ocular reflex. *J Neurol* 2008.
36. Bremmer F, Schlack A, Duhamel JR, Graf W, Fink GR. Space coding in primate posterior parietal cortex. *Neuroimage* 2001;14(1 Pt 2):S46-51.
37. Overath T, Kumar S, von Kriegstein K, Griffiths TD. Encoding of spectral correlation over time in auditory cortex. *J Neurosci* 2008;28(49):13268-13273.
38. Strelnikov K, Rouger J, Demonet JF, et al. Does Brain Activity at Rest Reflect Adaptive Strategies? Evidence from Speech Processing after Cochlear Implantation. *Cereb Cortex* 2009.
39. Parietti-Winkler C, Gauchard GC, Simon C, Perrin PP. Sensorimotor postural rearrangement after unilateral vestibular deafferentation in patients with acoustic neuroma. *Neurosci Res* 2006;55(2):171-181.
40. Strupp M, Arbusow V, Dieterich M, Sautier W, Brandt T. Perceptual and oculomotor effects of neck muscle vibration in vestibular neuritis. Ipsilateral somatosensory substitution of vestibular function. *Brain* 1998;121 (Pt 4):677-685.
41. Brandt T, Bartenstein P, Janek A, Dieterich M. Reciprocal inhibitory visual-vestibular interaction. Visual motion stimulation deactivates the parieto-insular vestibular cortex. *Brain* 1998;121 (Pt 9):1749-1758.
42. Deutschlander A, Hufner K, Kalla R, et al. Unilateral vestibular failure suppresses cortical visual motion processing. *Brain* 2008;131(Pt 4):1025-1034.

Figures

Fig.1:

Regions of significant changes in relative grey matter volume (GMV) (patients vs. controls) are shown on representative axial, sagittal or coronal slices of the standard Montreal Neurological Institute (MNI) template. The color-bar represents the T statistics for plotted results (A to D). A relative increase in GMV is indicated by the hot-iron color map. The coordinates of the local maxima for each cluster of significant relative GMV-change revealed by categorical comparison of patients vs. controls are given on the ordinate. The barplots (right) illustrate the relative change in GMV of patients compared to controls in arbitrary units \pm standard error of mean (SEM) for patients (first bar), controls (second bar) and corresponding correlation with the age of patients (third bar) and controls (fourth bar) indicating that age does not account for the GMV changes. GMV increase is shown in the ipsi- (A) and contralesional (B) primary somatosensory cortex (S1), (C) bilaterally in motion sensitive areas (MT/V5) and (D) in lobule VII of the cerebellar vermis. Left side in slices is indicated by "L" (ipsilesional), "R" indicates right side (contralesional).

Fig.2:

Significant correlations of grey matter volume (GMV) increase in the superior temporal gyrus (STG) / posterior insula (A) with the clinical vestibular score (CVS), in the inferior parietal lobule (IPL) (B) with the vestibular disability (Cohen and Kimball score), and in the contralesional Heschl gyrus / posterior insula (C) with the hearing loss (Gardner score) are shown on representative axial and coronal slices of the standard Montreal Neurological Institute (MNI) template and indicated by arrows (x-, z-coordinates below the slices). T-scores of the correlation are indicated by the hot-iron color map. On the right side, the linear regressions are plotted. Left side in slices is indicated by "L" (ipsilesional), "R" indicates right side (contralesional). R^2 = coefficient of determination.

Table 1:
Clinical data of patients with unilateral vestibular-cochlear failure following operative removal of acoustic neuroma. F= female; M = male, L = left; R = right; VBM = voxel based morphometry; for scores see Methods (caloric hyporesponsiveness: 0-100%; 100%= no caloric response; vestibular disability score: range 0-10, 10 = most severely affected; CVS=Clinical score of vestibular signs: range 0-24, 24 = most severely affected; House Brackmann Score of facial palsy: range 0-6). Head impulse test (Halmagyi Curthoys test): right or left indicates the pathological side.

Code (pat)	age	sex	Lesion side	Interval (months) since neurectomy	Duration of symptoms before recording (months)	Dizziness / vertigo	Tinnitus	Hearing impairment	Head impulse test	Clinical vestibular score, CVS	Caloric hyporesponsiveness (%)	Vestibular disability (Cohen-Score)	Size of tumor (Koos-Grading)	Hearing-loss (Gardner score)	Facial-Score (House-Brackman)
1	57	F	L	48	55	+	-	+	L	9	85	4	2	3	1
2	64	M	L	15	35	+	-	+	L	6	90	1	4	5	2
4	62	F	R	3	27	+	-	+	R	12	50	5	2	3	1
16	39	F	R	30	39	+	-	+	R	5	100	4	2	2	5
17	38	M	R	55	115	+	+	+	R	4	53	1	2	1	1
21	61	F	L	53	53	+	-	+	L	17	100	4	3	3	2
28	59	M	L	6	15	+	+	+	L	8	100	4	1	5	2
29	54	F	L	64	70	+	+	+	L	4	100	2	3	5	5
31	49	M	R	36	48	-	-	+	R	1	100	1	4	5	5
34	66	F	L	4	184	+	+	+	L	9	90	1	4	2	1
47	67	F	L	3	123	+	-	+	L	9	100	2	3	5	2
49	59	F	L	64	124	+	-	+	L	6	100	3	2	2	2
51	56	F	R	81	116	+	-	+	R	10	100	5	3	5	1
52	65	F	L	31	49	+	-	+	L	18	100	3	2	5	5
61	53	F	L	60	72	+	-	+	L	2	100	1	2	3	1

Table 2: Significant relative grey matter (I) changes are shown for the left (ipsilesional, il) and the right (contralesional, cl) hemisphere. The x ,y ,z coordinates are given in standard Montreal Neurological Institute (MNI) space and the anatomical regions according to the Wake Forest University (WFU) Pick Atlas. Each region is defined by the local maximum within a cluster. **Simple regression analyses** revealed **significant correlations of grey matter volume (GMV) changes** in patients (II) with (a) clinical vestibular score (CVS), (b) vestibular disability (Cohen and Kimball Score), and (c) the hearing loss (Gardner Score).

Lobes	Regions	Left hemisphere					Right hemisphere						
		Coordinates (mm)			T	Z	p	Coordinates (mm)			T	Z	p
		x	y	z				x	y	z			
I. Relative grey matter increases													
Frontal lobe	Superior frontal gyrus							18	34	44	3.51	3.15	.001
	Middle frontal gyrus							33	39	30	3.47	3.11	.001
Temporal lobe	Orbital gyrus	-18	29	-11	4.02	3.51	.000	15	36	-14	3.52	3.15	.001
	Superior temporal gyrus							59	-6	-2	2.94	2.70	.003
	Middle temporal gyrus	-51	-26	0	4.07	3.55	.000	48	-28	0	4.15	3.35	.000
	Middle temporal gyrus	-44	-75	7	2.93	2.70	.003						
Parietal lobe	Inferior temporal gyrus							62	-18	-20	3.72	3.30	.000
	primary somatosensory cortex	-47	-27	52	5.39	4.38	.000	43	-28	64	5.14	4.23	.000
	Inferior parietal lobule							55	-36	47	4.85	4.06	.000
	Inferior parietal lobule	-36	-64	44	5.12	4.22	.000						
	Inferior parietal lobule							50	-33	21	3.41	3.07	.001
Occipital lobe	Precuneus							20	-72	29	5.19	4.26	.000
	Inferior temporal gyrus							49	-70	-2	5.63	4.51	.000
	Inferior occipital gyrus							42	-88	-8	4.28	3.69	.000
	Lingual gyrus							28	-72	-16	4.75	3.99	.000
	Lingual gyrus							17	-98	-12	3.97	3.48	.000
Limbic lobe	Posterior cingulate	-12	-49	7	4.35	3.74	.000						
Cerebellum	cerebellar crus II	-23	-74	-41	4.80	4.02	.000						

	Cerebellar lobule VIIIb (tonsil)	-12	-58	-42	3.85	3.40	.000						
	cerebellar crus II							33	-71	-41	4.06	3.54	.000
	cerebellar vermis (lobule VI)							3	-74	-21	3.23	2.93	.002

II. Relative grey matter decreases

Frontal lobe	Anterolateral prefrontal cortex	-42	49	22	4.49	3.83	.000						
	Orbitofrontal gyrus	-3	32	-16	4.33	3.72	.000						
Temporal lobe	Fusiform gyrus	-53	-70	-19	4.28	3.69	.000						
	Superior temporal gyrus	-55	14	-4	3.11	2.84	.002						
Cerebellum	cerebellar lobule VI							20	-59	-31	3.87	3.41	.000
	cerebellar lobule VIIb	-50	-52	-48	5.63	4.51	.000						
	cerebellar lobule IX							21	-51	-49	3.13	2.85	.002

III. Clinical correlations

a) Clinical Score

Temporal lobe	Superior temporal gyrus / post. insula							51	-3	3	4.80	3.58	.000
---------------	----------------------------------------	--	--	--	--	--	--	----	----	---	------	------	------

b) Cohen Score

Parietal lobe	Inferior parietal lobule							44	-32	24	5.52	3.90	.000
---------------	--------------------------	--	--	--	--	--	--	----	-----	----	------	------	------

c) Gardner Score

Sublobar	Posterior insula / Heschl							42	-21	-1	5.41	3.85	.000
----------	---------------------------	--	--	--	--	--	--	----	-----	----	------	------	------

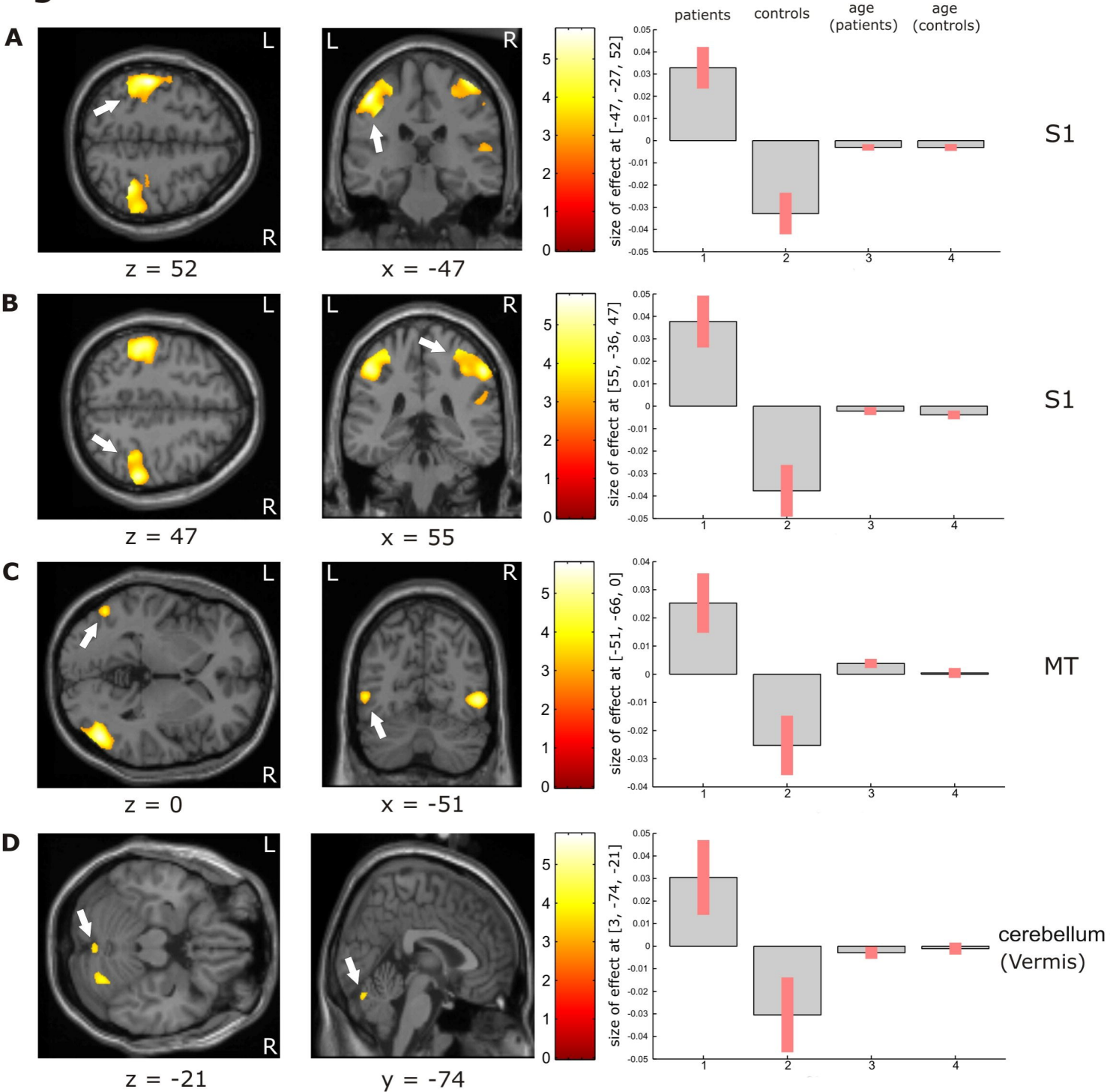
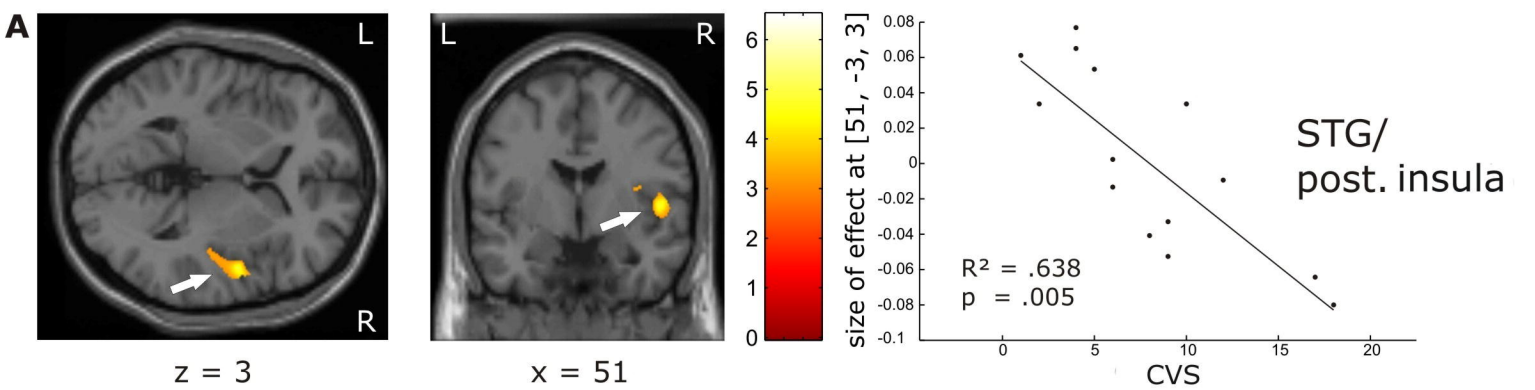
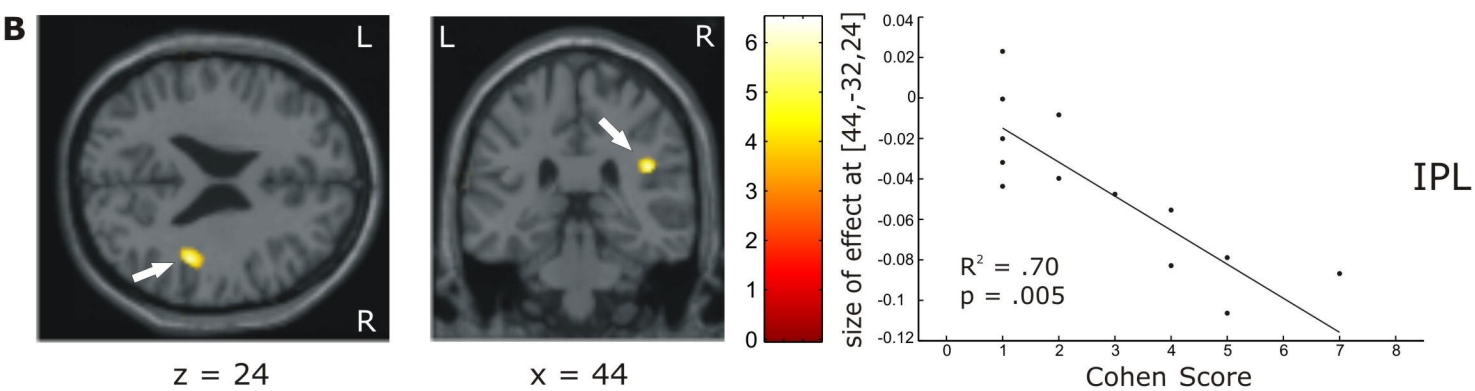
Figure 1

Figure 2

Clinical vestibular score



Cohen Score



Gardner Score

