HAL
open science

SAPHO syndrome in an adult with ulcerative colitis responsive to intravenous pamidronate: a case report and review of the literature

Keith Siau, Catherine J. Laversuch

To cite this version:

Keith Siau, Catherine J. Laversuch. SAPHO syndrome in an adult with ulcerative colitis responsive to intravenous pamidronate: a case report and review of the literature. Rheumatology International, 2009, 30 (8), pp.1085-1088. 10.1007/s00296-009-1021-5 . hal-00568300

HAL Id: hal-00568300

https://hal.science/hal-00568300v1

Submitted on 23 Feb 2011

HAL is a multi-disciplinary open access archive for the deposit and dissemination of scientific research documents, whether they are published or not. The documents may come from teaching and research institutions in France or abroad, or from public or private research centers.

L'archive ouverte pluridisciplinaire **HAL**, est destinée au dépôt et à la diffusion de documents scientifiques de niveau recherche, publiés ou non, émanant des établissements d'enseignement et de recherche français ou étrangers, des laboratoires publics ou privés.

SAPHO syndrome in an Adult with Ulcerative Colitis Responsive to Intravenous Pamidronate: A Case Report and Review of the Literature

Siau K[1]

Address: [1]Department of Rheumatology, Musgrove Park Hospital, Taunton, TA1 5DA, United Kingdom

Tel: 01823 344094

Fax: 01823 342132

Linking powered by eXtyles

Email: keith@siau.org

Keywords: SAPHO, inflammatory bowel disease, CRMO, Ulcerative colitis

Abstract

SAPHO (synovitis, acne, pustulosis, hyperostosis, osteitis) syndrome is a rare group of sterile, inflammatory osteoarticular disorders classically associated with skin lesions. It is occasionally associated with enteropathic disease such as ulcerative colitis. We present a 39 year old patient with chronic ulcerative colitis who developed enteropathic SAPHO and responded well to pamidronate. We discuss the clinicopathological features with particular attention to bone pathology, and perform a literature review of this fascinating syndrome.

Case presentation

A 39 year old female was referred to the rheumatology department with a 6 month history of non-traumatic, relapsing and remitting, right clavicular pain and swelling in 2007. Her past medical history was significant for a 20 year history of histologically confirmed ulcerative pancolitis which required a subtotal colectomy in 2005. 3 months prior to her colectomy, she had presented to the spinal surgery team with an acute episode of lumbar back pain which had last several weeks. Technetium scintigraphy was arranged to investigate the possibility of metastatic disease, showing increased uptake to L4 vertebral body. MRI spine excluded a fracture and revealed high intensity T2 lesions in the affected vertebral body. Subsequent biopsy of L4 vertebral body was unremarkable except for irregular, thick trabeculae with osteoblasts and osteoclasts. As the symptoms had spontaneously resolved without recurrence 6 months later, she was subsequently discharged.

On examination, tenderness of the medial aspect of the right clavicle was elicited. Shoulder movement was normal. There were no dermatological findings. Chest X-ray revealed sclerosis of the affected area, which had initially been normal on clavicular X-ray at presentation. Subsequent MRI revealed low-signal T1 lesion and hyperintense STIR signal affecting the entire right clavicle and surrounding soft tissue (Figure 1), with sparing of the sternum, suggestive of a neoplastic or infective process. Her routine blood results revealed mildly elevated serum alkaline phosphatase (ALP) and C-reactive protein (CRP) concentrations at 75u/L and 17mg/L respectively. Serum white cell count, neutrophils, urea and electrolytes and remaining liver function parameters were all within normal limits. Corrected calcium was normal at 2.4mmol/L. Blood cultures were negative. CT imaging (Figure 2) to exclude Ewing's sarcoma demonstrated medullary sclerosis, irregular cortical erosion and periosteal reaction of the medial right clavicle, consistent with mild indolent osteomyelitis. Biopsy of the area revealed irregular bony trabeculae with increased osteoblastic and osteoclastic activity and associated fibrosis.

In view of the clinical history of coexistent ulcerative colitis with radiological findings of hyperostosis and osteitis, and with the exclusion of an infective or malignant process, the diagnosis of enteropathic SAPHO syndrome was made. In hindsight, SAPHO may have affected the L4 vertebra prior to colectomy, but was only recognised after presenting in her right clavicle 2 years after. Her symptoms abated with low-dose meloxicam. A trial of oral bisphosphonate failed to relieve symptoms, however, an initial infusion of intravenous bisphosphonate (60mg pamidronate) effectively drove the patient into remission. She now receives 3 monthly pamidronate infusions when required for frequent relapses.

Discussion

First coined by Chamot *et al* in 1987,[1] the acronym SAPHO (synovitis, acne, pustulosis, hyperostosis, osteitis) represents all 5 features of their osteoarticular-dermatological syndrome. Over the years, SAPHO has been controversially adapted to encompass a spectrum of disorders sharing clinical and histological features, with more than 50 previously independent entities included under this umbrella term,[2] such as chronic recurrent multifocal osteomyelitis (CRMO), anterior chest wall syndrome and sternocostoclavicular hyperostosis. Despite the acronym, osteitis and hyperostosis constitute the hallmarks of SAPHO syndrome. The diagnosis can be made in the absence of cutaneous signs, which if they present, usually occur within 2 years from the onset of bone symptoms, although the interval may be in excess of 20 years.[3] The currently accepted diagnostic criteria for SAPHO syndrome is based on fulfilling at least one of the following parameters originally determined by Kahn *et al* in 1994:[2]

1) Multifocal osteitis with or without skin manifestations

2) Sterile acute or chronic joint inflammation associated with either pustules from psoriasis (usually palmoplantar) or severe acne (conglobata or fulminans)

3) Sterile osteitis in the presence of any of the above skin manifestations.

SAPHO syndrome is rare with no accurate incidence data. It is of indeterminate aetiology, although some authors believe that an antigenic trigger, related to low grade *Proprionobacterium acnes* infection, may be contributory.[4] Others regard SAPHO to be an additional member of the seronegative spondyloarthropathies,[6,7] in view of common findings such as sacroiliitis and vertebral body involvement which occurs in about 50% of patients,[2,6] the higher prevalence of the HLA-B27 antigen (in 33%),[1,2,7] and the association with extra-articular manifestations such as inflammatory bowel disease,[8-10,13] enthesopathies, uveitis and psoriasis.[2,7-9]

CRMO, which is the commonest presentation of SAPHO syndrome, was found to affect 49% of patients in one cohort consisting of 173 SAPHO patients.[13] CRMO is a clinicopathological diagnosis whereby sterile osteomyelitis (osteitis) is the key feature. The acronym is misleading. It is not necessarily chronic, recurrent nor multifocal in adults, although this is usually the case in children.[13] CRMO is usually chronic with a relapsing and remitting course, although a subacute course before permanent remission may be observed. It typically affects multiple sites in children,[1,2] although unifocal CRMO, especially when affecting the clavicle, is a recognized entity in adults.[13] It is often described in children and young adults, and is rare in adults when the literal terminology is applied. Characteristically, the condition has a predilection for the anterior chest wall in 65-90%, with medial clavicle involvement being the clinical hallmark.[5] The vertebrae are the second most commonly affected site (30%), followed by the diaphyses of long bones, mandible and iliac bones (in 10%).[5] The number of affected areas reduce with increasing age.[13] Technetium scintigraphy is useful for screening affected sites. On X-ray and CT imaging, the affected bone is often enlarged (hyperostosed) and sclerotic due to inflammation. MRI may reveal bone marrow oedema and synovitis. Histologically, a periosteal reaction from leukocyte infiltration, along with increased osteolytic and osteoblastic activity resembling Paget's disease may be observed.[11,12] Absence of bacterial cells is obligatory. With clinical features that vary between children and adult CRMO,[2,12] SAPHO syndrome is regarded by Kahn to be the adult version of CRMO.[2]

The occurrence of SAPHO syndrome in a middle-aged patient with ulcerative colitis, as reported in our case, is very rare. In Germany, where the condition has been well recognized, the incidence of CRMO is estimated at 0.04%,[13] with the enteropathic variant reported to affect 9% of CRMO patients.[9] However, enteropathic SAPHO are typically reported in children and young adults, with the majority of cases occurring in conjunction with Crohn's disease. Only 20-25% of enteropathic variants are associated with ulcerative colitis.[9] The overall picture is of CRMO, usually preceding

gastrointestinal disease for as long as 5 years in children.[8] Skin lesions are present in 40% of cases,[8] with palmoplantar pustulosis being the commonest lesion.[9] Schilling and Marker-Hermann proposed that the pathogenesis of enteropathic SAPHO may be similar to that of enteropathic spondyloarthropathies, and hypothesized that the disorder may be driven by a common antigen inappropriately activating T-cells within lymphoid tissues of the skin-gut-bone axis.[9] However, unlike spondyloarthropathies, most patients with enteropathic SAPHO are HLA-B27 negative. Furthermore, although the role of the synovium in autoimmune disease has been well explored, there is poor understanding why bone should be affected. With regard to our patient, we believe that chronic inflammation within the gut from her 20 year history of colitis may have resulted in abnormal bowel permeability, thereby allowing the abnormal trafficking of lymphocytes from gut mucosa target other tissues. However, no in vitro pathological model exists of enteropathic SAPHO, and its mechanisms remain to be elucidated. Due to the rarity of the condition, the clinical presentation and course of enteropathic SAPHO in adults is also poorly understood.

Currently, no specific treatment exists for SAPHO syndrome. Due to the lack of patient numbers, there have been no randomized placebo-controlled trials. Traditionally, NSAIDs, sulfasalazine and corticosteroids have been tried with varying degrees of success. Azithromycin, which has been beneficial for acne, has been reported to provide rapid osteoarticular relief in over 50% of patients,[14] and are used by some authorities as first line.[13] Infliximab, which has confirmed efficacy in seronegative spondyloarthropathies, may have a role especially in SAPHO associated with Crohn's disease, although its evidence is confined to case reports. Recently, nasal calcitonin has found favour in paediatric patients. However, intravenous pamidronate has now become the cornerstone of treatment for SAPHO syndrome given its safety profile and efficacy. In one series, it has induced complete remission in 60% and partial remission in 30% of patients.[15] Bisphosphonates were initially introduced based on their efficacy in other conditions where bone becomes dysregulated, such as in Paget's disease, which shares histological similarities to CRMO. They act by inducing

osteoclastic apoptosis and exert an anti-inflammatory effect within bone by modulating cytokine concentrations.[15] Better understanding of SAPHO and its enteropathic variant is crucial for the treatment of the condition, which may carry a chronic course with prolonged morbidity.

Conclusion

We present a 39 year old patient with ulcerative colitis with a rare diagnosis of enteropathic SAPHO syndrome predominantly affecting the right clavicle, with good response to pamidronate therapy. Recognition of this condition is important, as the condition is often chronic, and treatment options are available. It can occur, but is often undiagnosed, in the absence of cutaneous manifestations. Knowledge of the condition may help to differentiate it from a malignant process and avoid repeated bone biopsies.

References

1. Chamot AM, et al (1987) Le syndrome acnè pustulose hyperostose ostèite (SAPHO) – Resultats d'une enquète nationale. Rev Rheumat 54:187–196.
2. Kahn MF, Khan MA (1994) The SAPHO-Syndrome. Baillieres Clin Rheumatol 8(2):333–362 Medline. doi:10.1016/S0950-3579(94)80022-7
3. Hayem G, Bouchaud-Chabot A, Benali K, et al (1999) SAPHO syndrome: A long-term follow-up study of 120 cases. Semin Arthritis Rheum 29:159–171 Medline. doi:10.1016/S0049-0172(99)80027-4
4. Kotilainen P, Merilahti-palo R, Lehtonen DP, et al (1996) Propioni-bacterium acnes isolated from sternal osteitis in a patient with SAPHO syndrome. Rheumatol 23:1302–1304.
5. Schilling F, Kessler S (2000) The SAPHO syndrome-Clinical and radiological differentiation and classification on the basis of 86 cases. Rheumatol 59:1–28. doi:10.1007/s003930050001
6. Steinoff Kilursu A, Falasa G, et al (2002) A study of musculoskeletal manifestations in 12 patients with SAPHO Syndrome. J Clin Rheumatol 8:13–22 Medline. doi:10.1097/00124743-200202000-00005
7. Benhamou CL, Chamot AM, Kahn MF (1988) Synovitis-acne-pustulosis-hyperostosis-osteomyelitis syndrome (SAPHO): a new syndrome among the spondyloarthropathies? Clin Exp Rheumatol 6:109–112 Medline.

8. Kahn MF, Bouchon JP, Chamot AM, Palazzo E (1992) Enterocolopathies chroniques et syndrome SAPHO. Rev Rhum Mal Osteoartic 59:91–94 Medline.

9. Schilling F, Marker-Hermann E (2003) Chronic recurrent multifocal osteomyelitis in association with chronic inflammatory bowel disease: entheropathic CRMO. Z Rheumatol 62:527–538 Medline. doi:10.1007/s00393-003-0526-7

10. Bousvaros A, Marcon M, Treem W, et al (▪▪▪) Chronic recurrent multifocal osteomyelitis associated with chronic inflammatory bowel disease in children. Dig Dis Sci 44:2500–2507 Medline. doi:10.1023/A:1026695224019

11. Reith JD, Bauer TW, Schils JP (1996) Osseous manifestations of SAPHO (Synovitis, Acne, Pustulosis, Hyperostosis, Osteitis) syndrome. Am J Surg Pathol 20:1368–1377 Medline. doi:10.1097/00000478-199611000-00008

12. Kahn MF, Chamot AM (1992) SAPHO syndrome. Rheum Dis Clin North Am 18:225–246 Medline.

13. Schilling F SAPHO Syndrome, Orphanet Encyclopedia, October 2004. http://www.orpha.net/data/patho/GB/uk-SAPHO.pdf. Accessed 17 Feb 2009.

14. Schilling F, Wagner AD (2000) Azithromycin: an anti-inflammatory effect in chronic recurrent multifocal osteomyelitis? A preliminary report. Z Rheumatol 59(5):352–353. doi:10.1007/s003930070059

15. Amital H, Applbaum YH, Aamar S, et al (2004) SAPHO syndrome treated with pamidronate: an open-label study of 10 patients. Rheumatology 43(5):658–661 Medline. doi:10.1093/rheumatology/keh149

Linking powered by eXtyles

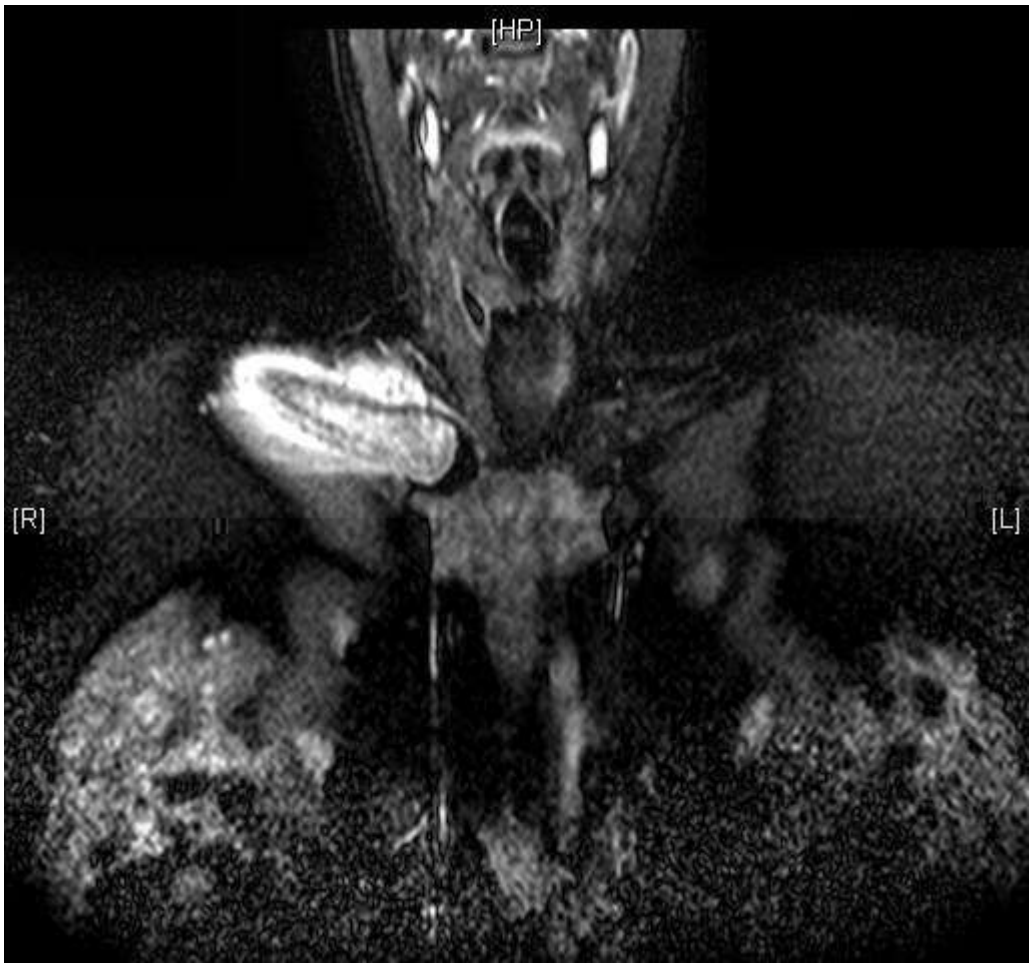

Linking powered by eXtyles

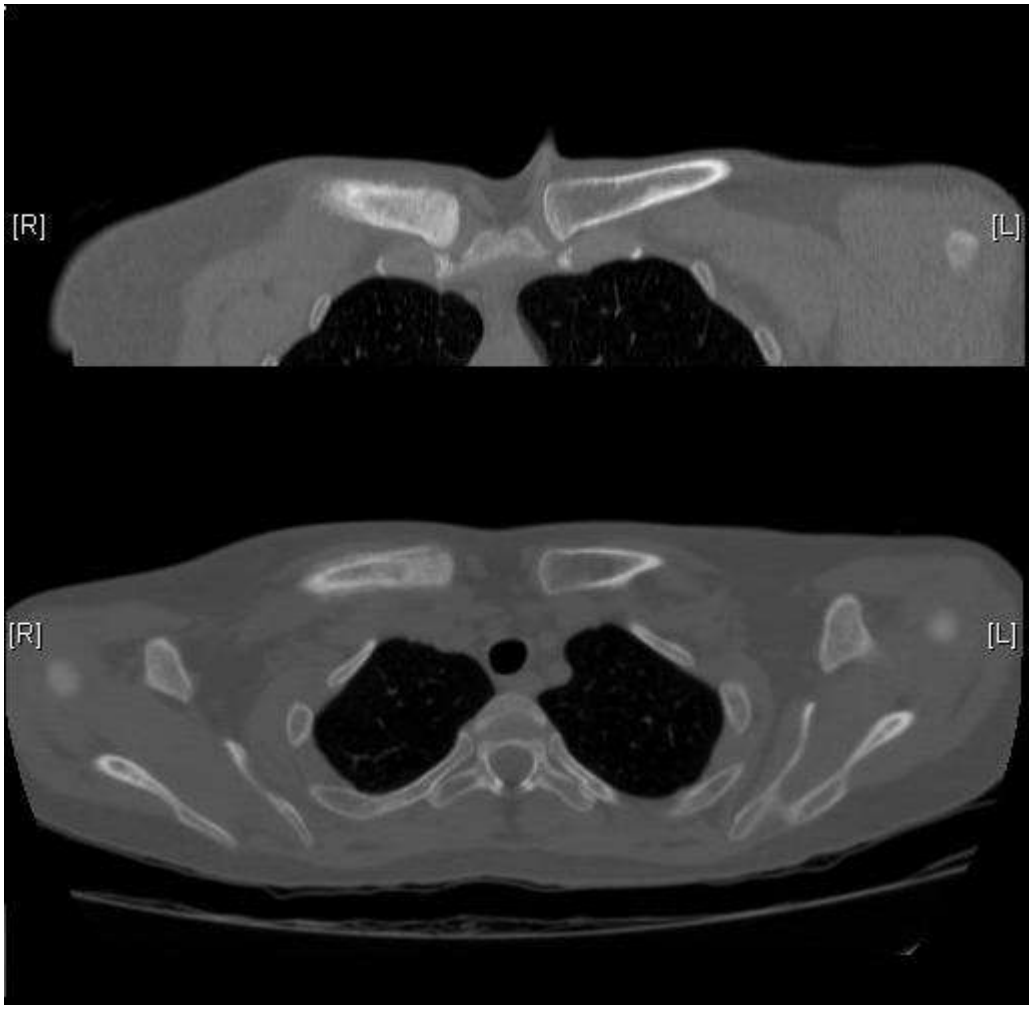
[R]
[L]
[R]
[L]