



HAL
open science

Human Retinal Pigment Epithelium Transplantation: Outcome after Autologous RPE-Choroid Sheet and RPE Cell-Suspension; A Randomized Clinical Study.

Christiane Isolde Falkner-Radler, Ilse Krebs, Carl Glittenberg, Boris Pova ay,
Wolfgang Drexler, Alexandra Graf, Susanne Binder

► **To cite this version:**

Christiane Isolde Falkner-Radler, Ilse Krebs, Carl Glittenberg, Boris Pova ay, Wolfgang Drexler, et al.. Human Retinal Pigment Epithelium Transplantation: Outcome after Autologous RPE-Choroid Sheet and RPE Cell-Suspension; A Randomized Clinical Study.. British Journal of Ophthalmology, 2010, 95 (3), pp.370. 10.1136/bjo.2009.176305 . hal-00567048

HAL Id: hal-00567048

<https://hal.science/hal-00567048>

Submitted on 18 Feb 2011

HAL is a multi-disciplinary open access archive for the deposit and dissemination of scientific research documents, whether they are published or not. The documents may come from teaching and research institutions in France or abroad, or from public or private research centers.

L'archive ouverte pluridisciplinaire **HAL**, est destinée au dépôt et à la diffusion de documents scientifiques de niveau recherche, publiés ou non, émanant des établissements d'enseignement et de recherche français ou étrangers, des laboratoires publics ou privés.

Title Page

Human Retinal Pigment Epithelium Transplantation: Outcome after Autologous RPE-Choroid Sheet and RPE Cell-Suspension; A Randomized Clinical Study.

Christiane I. Falkner-Radler, MD¹, Ilse Krebs, MD¹, Carl Glittenberg, MD¹, Boris Považay, PHD², Wolfgang Drexler, PHD², Alexandra Graf, PHD³, Susanne Binder, MD¹

¹The Ludwig Boltzmann Institute of Retinology and Biomicroscopic Laser surgery, Department of Ophthalmology, Rudolf Foundation Clinic, Vienna, Austria

²Biomedical Imaging Group, Department of Optometry and Vision Sciences, Cardiff University, Wales, UK

³Department of Medical Statistics, Core Unit of Medical Statistics and Informatics, Medical University of Vienna, Vienna, Austria

Clinical Trial Registration: Protocol ID: FR-01-CI-2006, ClinicalTrials.gov ID: NCT00401713

Keywords: autologous retinal transplantation, age-related macular degeneration, retinal pigment epithelium, RPE-sheet, RPE-suspension

Words count: 2414

Corresponding and reprint request author, address:

Christiane I. Falkner-Radler, MD

The Ludwig Boltzmann Institute of Retinology and Biomicroscopic Lasersurgery, Department of Ophthalmology, Rudolf Foundation Clinic, Juchgasse 25, A 1030 Vienna, Austria.

phone: (+43)-1-71165-4607, fax: (+43)-1-71165-4609, e-mail: christiane.falkner-radler@wienkav.at

Abstract

Aims: To evaluate the outcome after two types of retinal pigment epithelium (RPE) transplantation techniques.

Methods: Fourteen consecutive patients with advanced exudative age-related macular degeneration (AMD) were randomly assigned to RPE-choroid sheet transplantation (group 1) or RPE cell-suspension transplantation (group 2). Outcome measurers included best-corrected distance and near visual acuity (BCVA), complication and recurrence rates, autofluorescence (AF), angiography, and time-domain (TD) and spectral-domain optical coherence tomography (SD-OCT).

Results: A three or more lines gain in BCVA at 24 months was found in two patients in group 1 and in one patient in group 2, whereas a three or more lines vision loss occurred in one patient in each group. Revision surgery for proliferative vitreoretinopathy was required in one patient in group 1. Epiretinal membranes developed in two patients in group 1 and in one patient in group 2. No recurrence occurred in this series. AF showed hyperfluorescence coincident with the graft in group 1, and hyper- and hypofluorescence in irregular patterns in group 2. Revascularization of the graft was present in all patients in group 1, and a normal choroidal vasculature in the area of RPE atrophy in all patients in group 2. OCT showed a decrease of retinal thickness in all patients, with an improved visualization of inter- and intralaminar structures in the SD-OCT.

Conclusion: The anatomic and functional outcome after both RPE transplantation techniques was comparable. Intrastructural irregularities of the sheet assessed using SD-OCT might explain the rather limited visual gain in otherwise successful sheet transplants.

Introduction

Despite the introduction of anti-vascular endothelial growth factor (anti-VEGF) treatment resulting in significant improvement of vision in patients with neovascular age-related macular degeneration (AMD), the treatment for advanced AMD, geographic atrophy and/or non-responders is still controversial. Maculoplasty, may be an alternative surgical approach in these patients with the potential of restoring the retinal anatomy and achieving stable long-term results.[1]

Transplantation of retinal pigment epithelium (RPE) has been introduced more than two decades ago, and considerable progress has been made regarding surgical technique and outcome.[2-4]

In the clinical situation drawbacks as well as successes have been reported.[5-9] Today, autologous RPE is used in clinical studies because homologous transplants make long term combined immunosuppressive therapies necessary, which are difficult to tolerate by elderly patients.[10] Besides cell condition, basal lamina changes and cell survival, refinement of surgical technique is an important factor for improvement of anatomic and functional outcome.

Two different transplantation techniques are currently used in clinical studies, the RPE-suspension technique and the RPE-choroid-sheet technique.[11,12] The RPE-cell suspension, providing limited amounts of cells on a partially defect basal lamina can easily be delivered subretinally through small retinotomies, which can be sealed with a gas bubble. The translocation of a full thickness RPE-choroidal sheet, providing a regular cell sheet of polarized RPE on its own basal lamina carries a high risk for intra- and postoperative complications. Thus, a silicone oil tamponade is mandatory necessitating a second vitreoretinal surgery for silicone oil removal.

This randomized clinical cohort study, is the first study evaluating these two autologous RPE-transplantation techniques in advanced neovascular age-related macular degenerartion (AMD).

Materials and Methods

Consecutive patients with foveal choroidal neovascularization (CNV) related to AMD were included in the study if they fulfilled all the following criteria: 1. age over 50 years; 2. progression of the disease combined with progressive visual loss over the past 3 to 6 months; 3. not suitable for laser therapy and/or photodynamic therapy (PDT) (large lesions, lesions containing more than 50% pigment epithelium detachment [PED] or hemorrhage), and 4. “non-responders” to the aforementioned therapies and to at least three, monthly performed, intravitreal anti-vascular endothelial growth factor (anti-VEGF) treatments. Non responders were defined as patients presenting at least two of the following criteria: increase of lesion size (fluorescein angiography), increase of retinal thickness (RT), decrease of best-corrected visual acuity (BCVA). The study was approved by the ethics committee of the city of Vienna and complied with the Declaration of Helsinki. Patients were recruited from our outpatient department and signed informed consent for the study.

Patients were randomly assigned to receive either a full RPE-choroid sheet transplantation and silicone oil tamponade (group 1) or transplantation of a RPE-cell suspension combined with a gas tamponade (group 2). All surgical procedures were performed by one surgeon (SB). The principles of the surgical technique for the RPE-choroid graft were similar to the technique described by van Meurs et al.[7,13] After 20 gauge pars plana vitrectomy and/or simultaneous cataract surgery, the membrane removal was performed. Then perfluorocarbon (PFC) was injected, and a retinal quadrangle was surrounded with diathermy and/or intensive laser treatment before tissue preparation in the superior mid peripheral region of the retina. For this maneuver a switch from the non-contact wide-angle system (B.I.O.M. II; OCULUS Germany) to corneal lenses was performed, and a chandelier light was used. The PFC was removed, and a little amount of fluid was injected subretinally to provide delivery of the transplant with minimal trauma. The graft was gently grasped on its choroidal side and cut free. Then the retina on the flap was removed, and the RPE-choroid sheet was translocated subfoveally. After correct graft

positioning, PFC was injected again, followed by a silicone–PFC fluid exchange as last surgical step. Three to 6 months later, silicone oil removal was planned. Our technique of RPE-cell suspension has been described in detail previously.[8,14]

Patients were examined before surgery and at one week, one month, and at 3, 9, 12 and 24 months after surgery. Clinical examinations included BCVA (early treatment diabetic retinopathy study charts, ETDRS) and Radner reading charts (logarithm of reading acuity determination, logRAD), biomicroscopy, autofluorescence, fluorescein and indocyanine green angiography (Heidelberg Engineering GmbH, Heidelberg, Germany), and time-domain and spectral-domain optical coherence tomography (TD- and SD-OCT) scans. Additionally, all patients underwent microperimetry at the 24 months follow-up using the MP-1 microperimeter (Nidek Technologies, Vigonza, Italy) with a Goldmann III and a 4-2 threshold algorithm. Two ophthalmologists uninvolved in the selection of the patients and surgery performed the examinations.

A masked statistical analysis was performed using SAS Software Version 9.1 (SAS Institute Inc., Cary, North Carolina, USA) including univariate and stepwise regression analyses to find differences between both treatment groups and to determine the association between main outcome variables (best-corrected distance and near visual acuity [BCVA] and retinal thickness [RT]) at 24 months, baseline demographics and complication rates. Analyses of variance (ANOVA) were used to determine the association between baseline demographics and time course of BCVA and RT. A 2-sided p-value less than .05 was considered statistically significant.

Results

Fourteen patients who underwent surgery between November 2004 and October 2006 were included in this study. The surgery was uneventful in all patients. Simultaneous cataract surgery was performed in 10 patients; the other 4 patients were pseudophakic before surgery. No significant difference between the treatment groups and baseline demographics was found ($p>.05$).

	RPE-choroid sheet TX (group 1)	RPE cell-suspension TX (group 2)	P value
Patients included	n=7	n=7	
Mean age (range, years)	77 (72 and 82)	79 (71 and 84)	p=.35
Gender	5 female, 2 male	4 female, 3 male	p=1.0
Lesion size (range, mm)	7.8 (3.5 and 10)	6.1 (4.9 and 9.2)	p=1.0
Diagnosis			p=.59
Classic CNV with hemorrhage	n=5	n=3	
Occult CNV, Occult and Classic CNV	n=2	n=4	
Non responder to previous therapy	n=5	n=2	p=.29
Distance BCVA (mean \pm SD, ETDRS)	0.25 \pm 0.22	0.28 \pm 0.23	p=.75
Range	LP (n=2) and 0.55	0.04 and 0.53	
Near BCVA (mean \pm SD, logRAD)	1.3 \pm 0.7	1.3 \pm 0.7	p=.79
Range	NRA (n=2) and 0.6	NRA (n=2) and 0.4	
Mean RT (range, μ m)	565 (398 and 750)	482 (464 and 498)	p=.54
Mean follow-up (range, months)	27 (24 and 36)	32 (24 and 42)	

In group 1, a proliferative vitreoretinopathy (PVR) retinal detachment developed at 6 weeks after surgery in one patient. Revision surgery consisted of silicone oil removal, re-vitreotomy, membrane peeling, laser treatment, and silicone oil tamponade because of a residual retinal

detachment nasally superior. Due to massive membrane formation, silicone oil removal was not possible in this patient. All other patients underwent silicone oil removal, and in two patients a simultaneous removal of preretinal membranes was performed. In group 2, a preretinal membrane developed in one patient but was not surgically removed because of the patient's low vision. No significant difference for the complication rates was found between both treatment groups ($p=.56$). No recurrence was encountered in this case series.

In group 1, two patients showed a 3 or more lines gain in distance BCVA at 24 months. Another patient showed a 3 or more lines vision loss at 24 months, and 4 patients showed stable vision within 2 lines. The two patients with significant improvement in distance acuity regained reading ability during follow-up. Two other patients, one presented with a PVR retinal detachment and a significant loss of distance BCVA, lost reading ability during follow-up. Another patient did not recover reading vision after surgery. In group 2, one patient showed a 3 or more lines gain in distance BCVA at 24 months, and another patient had a 3 or more lines vision loss after surgery. The other 5 patients presented with stable vision within 2 lines. One patient in this group, regained reading ability during follow-up, another patient lost reading vision after surgery, and two other patients did not recover any reading ability at 24 months. No significant difference for distance and near BCVA was found between both treatment groups ($p>.75$). Additionally, baseline demographics were not significantly associated with the visual outcome in both groups ($p>.05$). Details on BCVA are presented in table 2

	RPE-choroid sheet TX (group 1)	RPE cell-suspension TX (group 2)
Patients included	n=7	n=7
Distance BCVA (mean \pm SD, ETDRS)		

1 month	0.11 ± 0.15	0.07 ± 0.10
3 months	0.11 ± 0.12	0.07 ± 0.08
9 months	0.10 ± 0.13	0.12 ± 0.15
12 months	0.13 ± 0.20	0.16 ± 0.15
24 months	0.20 ± 0.16	0.26 ± 0.17
Near BCVA (mean \pm SD, logRAD)		
1 month	1.8 ± 0.3	1.8 ± 0.3
3 months	1.6 ± 0.4	1.7 ± 0.3
9 months	1.6 ± 0.5	1.7 ± 0.3
12 months	1.5 ± 0.4	1.7 ± 0.3
24 months	1.5 ± 0.4	1.6 ± 0.3

, and in figure 1 and 2.

In group 1, autofluorescence showed hyperfluorescent areas of different intensity corresponding to the RPE- choroid sheet in all cases. These findings showed some decrease in size and loss of intensity up to normal fluorescence during follow-up (figure 3c,d). In group 2, autofluorescence showed areas of hypo and hyperfluorescence in irregular patterns and well demarked areas of RPE atrophy with absent autofluorescence, remaining similar in size and shape during follow-up (figure 4f). Two cases showed small areas of normal autofluorescence within the area of RPE atrophy. In group 1, revascularisation of the graft was visible on fluorescein and indocyanine green angiography in all cases, but was not corresponding to AF of the RPE (figure 3e,f,g,h). In group 2, hyperfluorescence (window defect) was present on fluorescein (figure 4g) and a normal choroidal vasculature in indocyanine green angiography (figure 4h) in the area of RPE atrophy in all cases. Additionally, visual acuity did not correlate with intensity of AF.

OCT measurements showed a decrease in RT after surgery in all patients in this case series. In group 1, mean RT at baseline was 565 μ m and decreased to 415 μ m at 24 months. In group 2,

mean RT at baseline was 482 μ m and decreased to 322 μ m at 24 months. With TD-OCT the RPE-choroid sheet appeared well placed and flat in the subretinal area, while with SD-OCT intralaminar and intrastructural abnormalities were visible within the graft. In the area of atrophy surrounding the graft an enhanced permeability into the choroid was present. This increased permeability was absent in the area of the graft. In patients after RPE cell-suspension localized increased permeability into the tissue in areas of RPE-atrophy was more clearly visualized in SD-OCT compared with TD-OCT. In both groups, SD-OCT showed abnormal overlying retina with a missing clear outer retinal zone. Details are presented in figure 5.

Microperimetry at 24 months demonstrated retinal fixation over the graft in 6 patients in group 1, and in 2 patients in group 2. Fixation was graded relatively unstable in two patients in group 1, and unstable in 4 patients in group1 and in 2 patients in group 2.

Discussion

This randomized study evaluated outcomes of two RPE transplantation techniques in patients with advanced neovascular AMD, who were unsuitable for/or non-responders to other forms of treatment. Transplantation of RPE-choroid sheet and RPE-cell suspension were able to maintain distance BCVA or in the best cases to restore foveal function. However, reading ability could rarely be restored or improved.

Baseline demographics were comparable between both groups in our series ($p > .05$). Contrary to other reports [15,16] the size of the lesion/hemorrhage and the type of the CNV were not significantly related to the visual outcome in both groups in our study ($p > .05$).

The postoperative complication rates were comparable between both treatment groups ($p = .56$). In literature higher surgery related complication rates were reported after RPE-choroid sheet transplantation. [7,8,13-15,17-19] No recurrence of the CNV was detected angiographically in any of our patients. This is in accordance with two studies on RPE-choroid sheet cases in geographic atrophy and neovascular AMD.[17,18] One comparative study on neovascular AMD reported no recurrence in the graft group, but in the macular translocation group (4 out of 12 patients)[16], and another study found recurrence of CNV in 11 out of 84 RPE-choroid sheet cases.[15]

The functional outcome was comparable between both groups in our series and quite similar to literature. [15,17-19] Duration of vision loss has been reported to be a significant predictor for the functional outcome after RPE-choroid sheet transplantation and macular translocation.[15-17]

Half of the patients included in our study were non-responders to previous treatment, and 5 patients out of these 7 non-responders underwent RPE-choroid sheet transplantation. This longstanding vision loss with an already impaired function of the photoreceptors and the neurosensory retina may be another reason for the less favorable visual results in group 1. As our study started in 2004, we were not able to include microperimetry, which would have provided additional information on retinal function in our baseline and early postoperative follow-

up. However, 8 patients had retinal fixation over the graft at 24 months, but fixation was graded relatively unstable in 2 patients after RPE-choroid sheet transplantation and unstable in 6 patients after both RPE transplantation techniques. Other studies reported better results on fixation stability after RPE-choroid sheet transplantation.[15,19]

Transplantation of RPE-choroid sheet provides an organized cell layer over its own basal lamina, whereas transplantation of RPE-cell suspension has the disadvantage that a limited amount of cells is distributed over a damaged basal lamina with an uncertain fate.[20,21] This implicates that uneventful transplantation of RPE-choroid sheet, being a better cell source compared to RPE-cell suspension, may offer higher chances to regain normal retinal structures and thus visual function. Additionally, our previously published studies on RPE cell-suspension have shown that patients with smaller membranes had a greater chance to regain vision compared to patients with large pathologies.[8,14] Nevertheless, the RPE-choroid sheet group consisting of patients with large pathologies having uneventful transplantation did not show significantly better outcome. Further evaluation offered two explanations for this limited visual outcome: (1) The RPE-choroid sheets that reached the edge of normal RPE on one side started building RPE-bridges from this side. These grafts showed better maintenance in color and autofluorescence over time. Although two patients presented with regain in vision after surgery, only one of these patients showed a continuous visual recovery over more than 18 months. Five of our RPE-choroid sheet patients presented with grafts not close enough to the normal RPE to create these bridges. Additionally, they showed a decrease of the size of the graft, which were surrounded by fibrotic tissue. (2) The RPE-choroid sheets looked regular and well organized on TD-OCT. However, on SD-OCT irregularities in the cell layers within the graft were visualized. These irregularities suspicious of scar formation or increased gliosis may also explain the inadequate visual recovery. Additionally, we found an absent clear outer nuclear and photoreceptor layer as previously described by Mac Laren et al., which they interpreted as photoreceptor loss over the graft.[20]

Our study has some limitations. Although, there has been no report evaluating the outcome after transplantation of RPE-choroid sheet and RPE-cell suspension, the sample size in the present study is relatively small. This may have limited the power in detecting outcome differences and may lead to insufficiency of statistical analysis. The 24 months follow-up seems to be appropriate for evaluating these different transplantation techniques, although anatomic as well as visual outcomes may still change 3 to 6 years after surgery.[20]

In conclusion, transplantation of RPE offers an alternative approach in advanced AMD, also suitable for geographic AMD and other degenerative retinal diseases. However, the functional results with RPE transplantation techniques do not approach the levels of outcome seen with anti-VEGF treatment. Although complication rates after transplantation of RPE seem to be higher, long-term effects of repeated intravitreal application are still unknown.[23,24] Refinement of surgical technique to allow for an adequate graft size, improvement of the quality of RPE and Bruch's membrane (rejuvenation, gene therapy, prosthetic Bruch's membrane, stem cells) and combination therapies might be future options to improve outcome after transplantation of RPE. Refined indications for treatment (for example patients with fresh RPE-rips involving the fovea or "non-responders" at an earlier time) should be evaluated in multicenter trials.

Acknowledgments/Disclosure:

Licence for Publication: The Corresponding Author has the right to grant on behalf of all authors and does grant on behalf of all authors, an exclusive licence (or non exclusive for government employees) on a worldwide basis to the BMJ Publishing Group Ltd and its Licensees to permit this article (if accepted) to be published in BJO editions and any other BMJPGJ products to exploit all subsidiary rights, as set out in our licence (<http://group.bmj.com/products/journals/instructions-for-authors/licence-forms/>).

Competing Interest: None declared

Funding/ Support: None declared

Financial Disclosures: None declared

Contributions to Authors: Design of the study (C.I.F.-R., S.B.), Conduct of the study (C.I.F.-R., I.K., C.G., B.P., W.D., A.G, S.B.), Collection and Management (C.I.F.-R.), Analysis (C.I.F.-R., I.K., A. G.), Interpretation (C.I.F.-R., I.K., A G., S.B.), Preparation (C.I.F.-R., I.K., A G., S.B), Review and final approval (C.I.F.-R., I.K., A G., S.B)

Other Acknowledgments: None

References

1. Del Priore LV, Tezel TH, Kaplan HJ. Maculoplasty for age-related macular degeneration: reengineering Burch's membrane and the human macula. *Prog Retin Eye Res* 2006;25:539-62.
2. Flood MT, Gouras P, Kjeldbye H. Growth characteristics and ultrastructure of human retinal pigment epithelium in vitro. *Invest Ophthalmol Vis Sci* 1980;19:1309-20.
3. Lopez R, Gouras P, Brittis M, et al. Transplantation of cultured rabbit retinal epithelium to rabbit retina using a closed-eye method. *Invest Ophthalmol Vis Sci* 1987;19:1131-7.
4. Gouras P, Algvere P. Retinal cell transplantation in the macula: new techniques. *Vision Res* 1996;36:4121-5.
5. Aisenbrey S, Lafaut BA, Szurman P, et al. Iris pigment epithelial translocation in the treatment of exsudative macular degeneration: a 3-year follow-up. *Arch Ophthalmol* 2006;124:183-8.
6. Chai H, Shin MC, Tezel TH, et al. Use of iris pigment epithelium to replace retinal pigment epithelium in age-related macular degeneration: a gene expression analysis. *Arch Ophthalmol* 2006;124:1276-85.
7. van Meurs JC, ter Averst E, Hofland LJ, et al. Autologous peripheral retinal pigment epithelium translocation in patients with subfoveal neovascular membranes. *Br J Ophthalmol* 2004;88:110-3.
8. Binder S, Krebs I, Hilgers RD, et al. Outcome of transplantation of autologous retinal pigment epithelium in age-related macular degeneration: a prospective trial. *Invest Ophthalmol Vis Sci* 2004;45:4151-60.
9. Stanga PE, Kychenthal A, Fitzke FW, et al. Retinal pigment epithelium translocation after choroidal neovascular membrane removal in age-related macular-degeneration. *Ophthalmology* 2002;109:1492-8.

10. Tezel TH, Del Priore LV, Berger AS, et al. Adult retinal pigment epithelial transplantation in exsudative age-related macular degeneration. *Am J Ophthalmol* 2007;143:584-95.
11. Binder S, Stanzel BV, Krebs I, et al. Transplantation of RPE in AMD. *Prog Retin Eye Res* 2007;26:516-54.
12. da Cruz L, Chen FK, Ahmado A, et al. RPE transplantation and its role in retinal disease. *Prog Retin Eye Res*. 2007 Nov;26(6):598-635.
13. van Meurs JC, Van den Biesen PR. Autologous retinal pigment epithelium and choroids translocation in patients with exsudative age-related macular degeneration: short term follow-up. *Am J Ophthalmol* 2003;1136:688-95.
14. Binder S, Stolba U, Krebs I, et al. Transplantation of autologous retinal pigment epithelium in eyes with foveal neovascularization resulting from age-related macular degeneration: a pilot study. *Am J Ophthalmol* 2002;133:215-25.
15. Maaijwee K, Heimann H, Missotten T, et al. Retinal pigment epithelium and choroids translocation in patients with exsudative age-related macular-degeneration: long term results. *Graefes Arch Clin Exp Ophthalmol* 2007;245:1681-9.
16. Chen FK, Patel PJ, Uppal GS, et al. A comparison of macular translocation with patch graft in neovascular age-related macular degeneration. *Invest Ophthalmol Vis Sci* 2009;50:1848-55.
17. Jousen AM, Joeres S, Fawzy N, et al. Autologous translocation of the choroids and retinal pigment epithelium in patients with geographic atrophy. *Ophthalmology* 2007;114:551-60.
18. MacLaren RE, Uppal GS, Balaggan KS, et al. Autologous transplantation of the retinal pigment epithelium and choroids in the treatment of neovascular age-related macular degeneration. *Ophthalmology* 2007;114:561-570.

19. Treumer F, Bunse A, Klatt C, et al. Autologous retinal pigment epithelium-choroid sheet transplantation in age related macular degeneration: morphological and functional results. *Br J Ophthalmol* 2007;91:349-53.
20. Tsukahara I, Ninomiya S, Castellarin A, et al. Early attachment of uncultured retinal pigment epithelium from aged donors onto Bruch's membrane explants. *Exp Eye Res* 2002;74:255-66.
21. Zarbin MA. Analysis of retinal pigment epithelium integrin expression and adhesion to aged submacular human Bruch's membrane. *Trans Am Ophthalmol Soc* 2003;101:499-520.
22. MacLaren RE, Bird AC, Sathia PJ, et al. Long-term results of submacular surgery combined with macular translocation of the retinal pigment epithelium in neovascular age-related macular degeneration. *Ophthalmology* 2005;112:2081-7.
23. Ciulla TA, Rosenfeld PJ. Antivascular endothelial growth factor therapy for neovascular age-related macular degeneration. *Curr Opin Ophthalmol* 2009;20:158-65.
24. Jeganathan VS, Verma N. Safety and efficacy of intravitreal anti-VEGF injections for age-related macular degeneration. *Curr Opin Ophthalmol* 2009;20:223-5.

Legends:

TABLE 1: Patients` Demographic Data Undergoing Two Different Autologous Retinal Pigment Epithelium (RPE) Transplantation Techniques.

RPE=retinal pigment epithelium, TX=transplantation, p=p value, p<.05=statistically significant, n=number of patients, CNV=choroidal neovascularization, BCVA=best corrected distance and near visual acuity, ETDRS= early treatment diabetic retinopathy study charts, logRAD=logarithm of reading acuity determination, RT=retinal thickness, n=number of patients, mean=mean value, SD=standard deviation, LP=light perception., NRA= no reading ability.

TABLE 2: Functional Outcome after Retinal Pigment Epithelium (RPE) Transplantation.

RPE=retinal pigment epithelium, TX=transplantation, BCVA=best corrected distance and near visual acuity, ETDRS= early treatment diabetic retinopathy study charts, logRAD=logarithm of reading acuity determination, mean=mean value, SD=standard deviation.

FIGURE 1. Mean values (points) and standard deviations (vertical lines) of distance best-corrected visual acuity (BCVA) measurements using ETDRS charts (early treatment diabetic retinopathy study charts,) charts over time are shown for treatment group 1 (RPE-choroid sheet transplantation, solid line) and treatment group 2 (RPE-cell suspension transplantation, dashed line).

FIGURE 2. Mean values (points) and standard deviations (vertical lines) of the near best-corrected visual acuity (BCVA) measurements using Radner reading charts (logarithm of reading acuity determination, logRAD) over time (baseline, at 1,3,9,12, and 24 months) are presented for treatment group 1 (RPE-choroid sheet transplantation, solid line) and treatment group 2 (RPE-cell suspension transplantation dashed line).

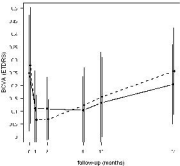
FIGURE 3. Twelve months (a,c,e,g) and 24 months (b,d,f,h) images of a 72 years old woman, who underwent RPE-choroid sheet transplanation on her left eye for a large subretinal hemorrhage not responding to PDT treatment. Twenty-four months after surgery, she presented with a significant improvement in distance BCVA and a regain in reading vision. The graft is

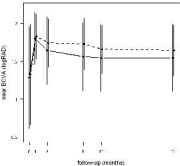
clearly visible as a dark area surrounded by the bright atrophy in red-free photographs (a,b), and as a hyperfluorescent area within the hypofluorescent atrophy in autofluorescence (c,d).

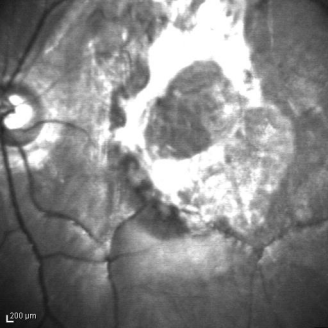Revascularisation of the graft is shown in fluorescein (e,f) and indocyanine green angiography (g,h). These findings remained stable during follow-up.

FIGURE 4. Red-free photographs (RF), autofluorescence (AF), fluorescein and indocyanine green angiography (FAG, ICG) images of a 74 years old man with a diagnosis of CNV and pigment epithelium detachment in his left eye. Twenty-four months after RPE cell-suspension transplantation, his distance BCVA remained stable, but he did not recover any reading vision. Baseline images show a partially fibrotic lesion with retinal folds, surrounded by hemorrhage (corresponding to blockage in FAG) (RF,a), inhomogeneous hypofluorescence in the area of the lesion (AF,b), blocked fluorescein in the area of subretinal hemorrhage, hyperfluorescence and leakage corresponding to the CNV (FAG,c), and dilated vessels and choriocapillaris defects within the lesion (ICG,d). Images at 24 months show areas of hyperpigmentation (dark) and atrophy (bright) (RF,e), hypofluorescence with isles of hyperfluorescence (AF,f), blocked fluorescein in the area of hyperpigmentation and hyperfluorescence in the area of the RPE atrophy (FAG,g) and choriocapillaris defects in a normal choroidal vasculature (ICG,h).

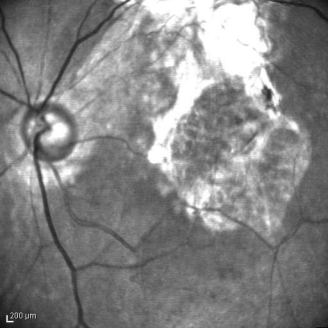
FIGURE 5. Time-domain (TD) and spectral domain (SD) optical coherence tomography (OCT) images at 24 months after RPE-choroid sheet transplantation (a,b) and RPE cell-suspension transplantation (c,d). In both treatment groups, an increased permeability of light into the tissue is visible in areas of RPE-atrophy. This increased permeability is absent in the area of the graft. No signs of fluid leakage are visible in both groups. The retinal thickness (RT) anterior to the graft seems normal (except for a small area) compared to subnormal in the area of the cell-suspension. The outer retinal zone was absent in an abnormal retina overlying the transplant in both groups. These cell irregularities and the retinal and subretinal layers are more clearly shown in the SD OCT scans.



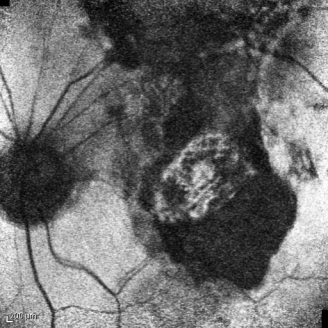




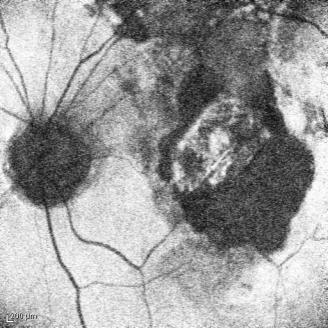200 μm



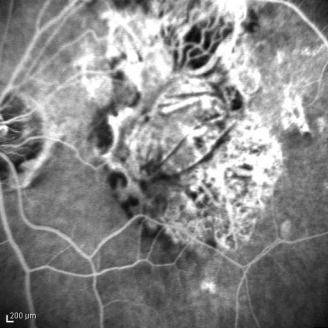
200 μ m



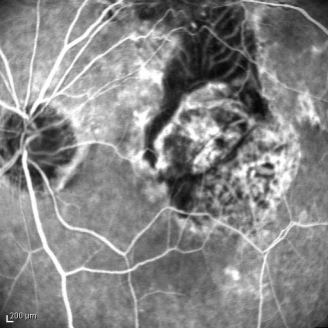
200 μm



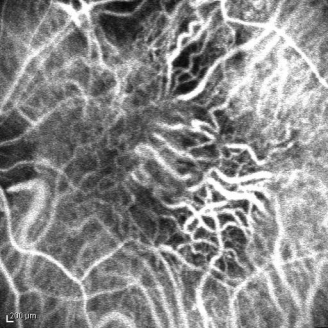
200 μm



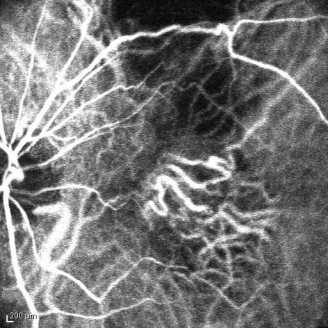
200 μm



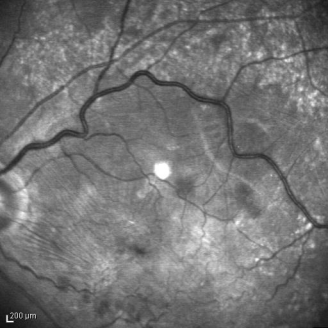200 μm



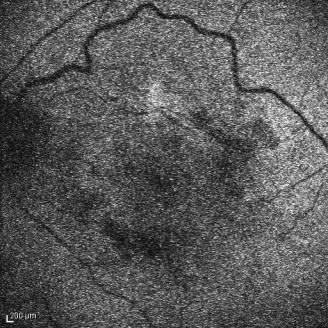
200 μm



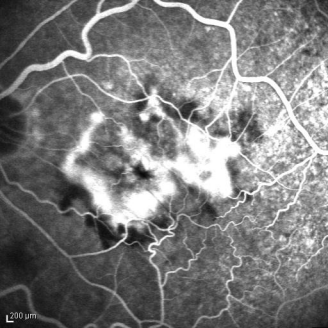
200 μ m



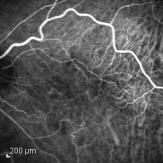
200 μm



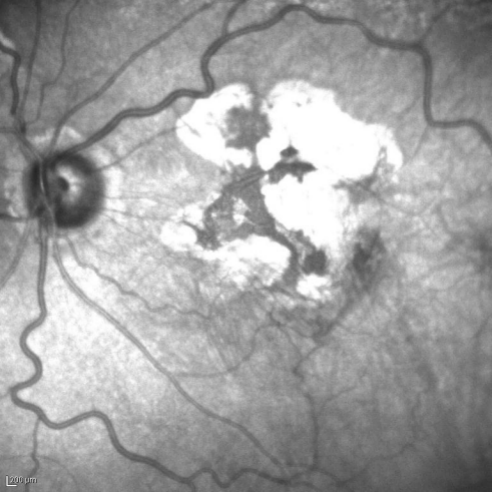200 μm



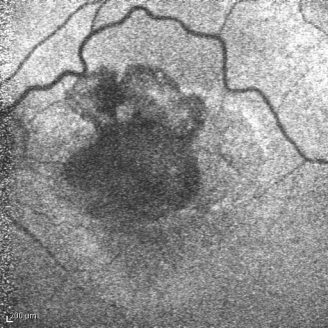
200 μm



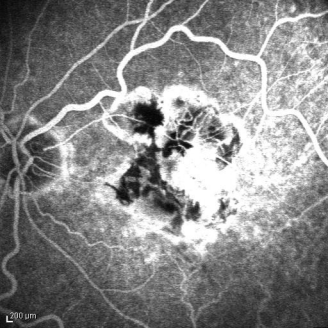
200 μm



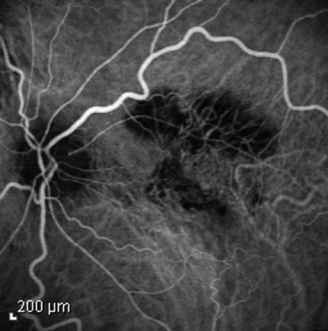
200 μm



200 μm



200 μm



200 μm

