



Small Incision Corneal Refractive Surgery using the SMILE procedure for the Correction of Myopia and Myopic Astigmatism: Results of a 6 months prospective study

Walter Sekundo, Kathleen Kunert, Marcus Blum

► To cite this version:

Walter Sekundo, Kathleen Kunert, Marcus Blum. Small Incision Corneal Refractive Surgery using the SMILE procedure for the Correction of Myopia and Myopic Astigmatism: Results of a 6 months prospective study. British Journal of Ophthalmology, 2010, 95 (3), pp.335. 10.1136/bjo.2009.174284 . hal-00567046

HAL Id: hal-00567046

<https://hal.science/hal-00567046>

Submitted on 18 Feb 2011

HAL is a multi-disciplinary open access archive for the deposit and dissemination of scientific research documents, whether they are published or not. The documents may come from teaching and research institutions in France or abroad, or from public or private research centers.

L'archive ouverte pluridisciplinaire **HAL**, est destinée au dépôt et à la diffusion de documents scientifiques de niveau recherche, publiés ou non, émanant des établissements d'enseignement et de recherche français ou étrangers, des laboratoires publics ou privés.

Small Incision Corneal Refractive Surgery using the SMILE[®] procedure for the Correction of Myopia and Myopic Astigmatism: Results of a 6 months prospective study

Walter Sekundo, MD¹, Kathleen S. Kunert², Marcus Blum, MD²

¹ Department of Ophthalmology, Phillips University of Marburg, Germany

² Department of Ophthalmology, Helios Hospital Erfurt, Erfurt, Germany

Corresponding author: Professor Dr. med. Walter Sekundo

Department of Ophthalmology
Philipps University of Marburg
Robert-Koch-Strasse 4
35037 Marburg /Germany

Phone: + 49 (6421) 586-6275

Fax: + 49 (6421) 586-5678

E-mail: sekundo@med.uni-marburg.de

This study has been supported by Carl Zeiss Meditec, Germany.

The authors do not have any financial interests in any product mentioned.

Competing Interest: None declared

Licence for Publication:

The Corresponding Author has the right to grant on behalf of all authors and does grant on behalf of all authors, an exclusive licence (or non exclusive for government employees) on a worldwide basis to the BMJ Publishing Group Ltd to permit this article (if accepted) to be published in PMJ and any other BMJPGL products and sublicences such use and exploit all subsidiary rights, as set out in our licence.

Abstract

Purpose: This 6 months prospective multi-center study evaluated the feasibility of performing myopic Femtosecond Lenticule Extraction (FLEx) through a small incision using the SMILE[®] procedure.

Design: Prospective, non randomized clinical trial.

Participants: 91 eyes of 48 patients with myopia with and without astigmatism completed the final 6 month follow-up. The patients' mean age was 35.3 years. Their preoperative mean spherical equivalent (SE) was -4.75 D (\pm 1.56 D).

Methods: A refractive lenticule of intrastromal corneal tissue was cut utilizing a prototype of the Carl Zeiss Meditec AG (CZM) VisuMax[®] femtosecond laser system. Simultaneously two opposite small "pocket" incisions were created by the laser system. Thereafter, the lenticule was manually dissected with a spatula and removed through one of incisions using a modified McPherson forceps.

Main outcome measures: UCVA and BSCVA after 6 months, objective and manifest refraction as well as slit-lamp examination, side effects and a questionnaire.

Results: 6 months post-operatively, the mean SE was -0.01 D \pm 0.49 D. 95,6 % of eyes treated were within \pm 1.0 D, and 80,2% of eyes within \pm 0.5 D of intended correction. 83.5% of eyes treated had an UCVA of 1.0 (20/20) or better. 53% of eyes remained unchanged, 32.3% gained one line and 3.3% two lines of BSCVA. 8.8% lost one line and 1.1% lost \geq 2 lines of BSCVA. When answering a standardized questionnaire, 93.3% of patients were satisfied with the obtained results and would undergo the procedure again.

Conclusion: SMILE[®] is a new promising flapless minimally invasive refractive procedure to correct myopia.

Introduction

Lamellar refractive surgery developed from the concepts and work of Jose Barraquer. In the original keratomileusis procedure for myopia a disc approximately 300µm thick was dissected from the anterior cornea in a freehand fashion and reshaped using a cryolathe. In the late 1980s Ruiz developed an automated microkeratome, that controlled the speed as it passed across the cornea leading to more consistent results. This procedure has become known as automated lamellar keratoplasty or ALK. In the 1990s the combination of a microkeratome and an excimer laser (for the refractive cut) was developed by Pallikaris, Burrato and others further increasing the predictability of the refractive procedure. This procedure, known as laser assisted in situ keratomileusis or LASIK has gained a wide acceptance worldwide¹. The limits of this procedure have been already proven in a long-term six and ten years follow-up studies related to the induction of aberrations and regression^{2,3}

Femtosecond lenticule extraction (FLEx) is a new procedure, which does not require a microkeratome or an excimer laser. In FLEx both the flap and the refractive lenticule are created in a one-step procedure using a femtosecond laser. Meanwhile the first peer reviewed publications^{4,5} as well as the first reports by other investigators (Shah R. Changing paradigm in refractive surgery. Advanced FLEx results.

Presented at the Annual Symposium of the ASCRS, San Francisco, 2nd of April 2009) awoke an interest in this new technology and procedure. Despite the fact that FLEx does not utilize an excimer laser, this procedure requires a flap which is smaller, but similar to the one for the femtosecond laser-assisted laser in situ keratomileusis (FemtoLasik) operation. A substantial part of complications, e.g. dry eyes and disturbance of corneal biomechanics, caused by or after LASIK surgery is believed to

be linked to the fact of flap creation regardless of the type of flap cutting. FLEx has a potential to work without lifting the flap. Thus, this prospective study was set-up to investigate the possibility of a FLEx procedure through a smaller incision avoiding creation of a flap. This modification was named Small Incision Lenticule Extraction (SMILE). To the best of our knowledge this is the first prospective study on this topic

Participants and Methods

This prospective study was approved by the Ethics Committee of the Chamber of Physicians of Thuringia, Germany, as well as by the Ethics Committee of the Chamber of Physicians of Rhineland-Palatinate, Germany. An informed consent was obtained from each patient. The inclusion criteria were spherical myopia up to – 10 Diopters (D) and myopic astigmatism up to -5 D cyl. Other inclusion criteria were a minimum age of 21 years, BSCVA \geq 0.8 (20/25) and no other ocular conditions except myopia. Moreover, the central corneal thickness as measured by AC-Master[®] (Carl Zeiss Meditec AG, Jena, Germany) had to be more than 500 μ m and the calculated residual stromal bed after treatment > 250 μ m. A regular topographic pattern was verified by Atlas[™] topography. Absence of asymmetric corneal thickness was confirmed by a pachymetry map of the Visante[™]-OCT (Carl Zeiss Meditec AG, Jena/Germany). The follow-up appointments were 1d, 1 week, 1 month, 3 and 6 months postoperatively. In the first 5 patients the fellow eye treatment was carried out not earlier than 1 week after the treatment of the first eye. All remaining patients had a bilateral simultaneous procedure. Patients' average age at the time of surgery was 35.3 years. The mean preoperative spherical equivalent was -4.75 D (\pm 1.56 D). The mean preoperative myopic astigmatism of -0.78 D \pm 0.79 D cyl (from 0 to -4.5 D

cyl) was recorded. The mean scotopic pupil diameter was measured 5.7 ± 1.0 mm and the mean preoperative pachymetry $538.4 \pm 22.6 \mu\text{m}$.

The main outcome measures were the predictability, efficacy, stability and safety of the refractive results obtained with the novel procedure described below.

The SMILE[®] procedure

SMILE[®] is performed under topical anaesthesia using 3 drops of preservative free oxybuprocaine tetrachloride (Conjucain EDO[™], Bausch & Lomb, Berlin, Germany) applied 2-3 minutes prior to surgery. After standard sterile draping and insertion of the aspirating speculum, the patient's eye is positioned under the VisuMax[®] integrated surgical microscope. Afterwards, the table moves to the laser treatment position under an illuminated and curved suction contact glass (so-called treatment pack). While the patient fixates an internal target light for centration, the cornea is partly applanated by moving the table upward toward the curved contact glass. The surgeon observes this motion through the operating microscope and controls the movement with a joystick. Once an appropriate centration has been achieved the surgeon initiates the automatic suction. The patient continues to observe the blinking target light even when the suction is being applied. The VisuMax[®] femtosecond laser produces ultra short pulses of light at a repetition rate of 200 kHz with a typical pulse energy $\leq 300\text{nJ}$ which are focused at a precise depth in the corneal tissue. A plasma state develops with optical breakdown, and a small gas bubble is formed from the vaporization of tissue. A series of bubbles are created in a spiral fashion with typical spot distance of 3-5 μm resulting in cleaving of tissue planes.

A schematic drawing of the procedure is show in Figure 1. Four subsequent femtosecond incisions are performed: the posterior surface of the refractive lenticule,

the lenticule border and the anterior surface of the refractive lenticule. The latter extends centripetally as for 0.5 mm. The side cuts for the access to the lenticule are positioned 180° apart and have an extension of 80° of cord length. One half of the eyes treated had the opening incisions in the 12 and 6 o'clock position (surgeon W.S.) (Fig.2) and the other half at the 3 and 9 o'clock position (surgeon M.B.). After the suction has been released, the patient is moved toward the observation position under the VisuMax® integrated surgical microscope. A thin spatula is inserted through the side cut over the roof of the refractive lenticule dissecting this plane followed by the bottom of the lenticule. The lenticule is subsequently grasped with modified serrated McPherson forceps (Geuder, GmbH, Germany, design M. Blum) and removed. After the removal of the lenticule the intrastromal space is flushed assuring an adequate flow from one incision to the opposite incision using a standard Lasik irrigating cannula.

Intended thickness of the upper arcade of tissue (equivalent of "flap thickness" in standard FLEx) varied between 110 µm and 130 µm, its diameter was chosen between 7.0 and 7.5 mm (mean 7.3 ± 0.2 mm), always at least 0.5 mm larger than the diameter of the refractive lenticule. The lenticule diameter varied between 6.0 and 7.0 mm with a mean of 6.5 ± 0.3 mm according to patient's scotopic pupil. The same equation as for FLEx¹ was used to calculate the geometry and the thickness of the refractive lenticule. The postoperative regimen consisted of preservative free ofloxacin (Floxal EDO™, Bausch & Lomb, Berlin, Germany) dexamethasone (Dexa EDO™, Bausch & Lomb, Berlin, Germany) and hyaluronic acid lubricating drops (VisLube™, Chemedica, Switzerland) 4 times per day each for one week. After this, only lubricating drops were used up to 3 months as needed. Follow-up intervals were 1 day, 1 week, 1, 3 and 6 months.

The following parameters were obtained at each visit:

- Best spectacle corrected (BSCVA) and uncorrected visual acuity (UCVA) using different ETDRS charts at each visit
- Objective and manifest refraction
- Corneal topography (Atlas[®], Carl Zeiss Meditec)
- Wave front measurements (WASCA[®], Carl Zeiss Meditec)
- Pachymetry and pachymetry map (AC Master[®] and Visante-OCT[®], Carl Zeiss Meditec)
- Goldmann's applanation tonometry (not on day 1 and week 1)
- Side effects were recorded
- Patients had to answer a standardized questionnaire consisting of 16 items such as glare, night driving problems, dryness, pain etc.

All measured data was collected on standardized study spread sheets and entered into Datagraph 3.5b software (Datagraph, Pieger GmbH, Germany) for analysis.

Further statistical analysis was performed using Excel 2003 (Microsoft Inc.,USA) and WINSTAT for Excel 2005.1 (R. Fitch Software Inc.,USA) The Wilcoxon signed rank test was used to compare mean outcomes.

Results

Safety

As shown in Figure 3, 49 eyes (53%)kept an unchanged best spectacle corrected visual acuity (BSCVA), 29 eyes (32.3%) gained one line and 3 eyes (3.3%) two lines. Eight eyes (8.8%) treated lost one line. One eye (1.1%) lost 2 lines and another eye (1.1%) lost >2 lines of BSCVA.

Predictability of spherical equivalent (SE) and Efficacy

At the 6 month follow-up 80.2% of eyes treated were within ± 0.5 D and 95.6% within ± 1.0 D of the intended refractive target (Figure 4). Six months post-operatively the mean SE was measured to be -0.01 D ± 0.49 D. The UCVA of 0.5 (20/40) or better was obtained in 97.6% and the UCVA of 1.0 (20/20) or better in 83.5% of eyes treated (Figure 5). Of the latter 28.2% had an UCVA of 1.2 and 10.6% of eyes treated an UCVA of 1.6 (20/12.5)

Stability

On the first few postoperative days the eyes were nearby plano with typical surface dependent fluctuation in vision as known from the LASIK procedure. The refraction stabilized at the 1-week follow-up interval. No further significant change in spherical equivalent (SE) was observed at one month (0.05 D), three (0.14 D) and 6 months (0.10 D). (Figure 6).

Side effects

No cases of transient sensitivity light syndrome or diffuse lamellar keratitis were observed. In one eye, a paracentral perforation of the upper arcade of corneal tissue by the dissecting spatula occurred due to stronger adhesion between the roof of the refractive lenticule and the undersurface of the upper corneal layers. This eye (1.1%) lost 3 lines of BSCVA at 6 months follow-up, but fortunately recovered to only 1 lost line at 1 year additional follow-up. There was one case of non-progressive epithelial ingrowth at the edge of the superior incision. Three cases of a small tear at the

incision edge as well as 3 cases of a localized epithelial defect nearby the edge were recorded. In one eye the laser incision opening was incomplete. Thus, the incision was opened to a desirable extent using diamond knife and the lenticule extracted. There were 10.0% of visually insignificant microstriae, one case of superficial punctate corneal staining (1.1%), but no subjective complains of dry eye syndrome recorded at 1week follow-up.

Questionnaire

On the scale of 0 to 100 (0=very poor; 100= best ever known vision) the mean quality of vision was graded 92.3. All patients reported full independence from spectacle correction. The questionnaire was asked in relation to each individual eye treated. 25 (28.4%) reported a marked improvement of their vision, 60 (68.2%) reported an extreme improvement of their vision. The remaining eyes had “some improvement”. None was complaining of worsening. In general, the question “would you have the surgery again” was answered by 93.3% with “yes”, 6.7% of the cases answered “not sure”, there were no “no” answers. However, when asked precisely 5.5% had some troubles with night vision and 6.6% with driving a car at night. There were no cases of glare, but 7 cases (7.7%) felt to perceive the feeling of dryness requiring lubrication as compared to 2 cases (2.2%) preoperatively. The questionnaire used in this study has been derived and modified from the questionnaires used in MEL 80 FDA approval study and has been validated in previous FLEx studies ^{4,5} Further details are displayed in the appendix.

Higher Order Aberrations

The mean total induction of HOA was $0.04 \pm 0.07 \mu\text{m}$. For the spherical aberration $Z_{4,0}$ the mean induction valued $0.008 \pm 0.07 \mu\text{m}$ and for the coma $Z_{3,+1}$ $-0.04 \pm 0.12 \mu\text{m}$ and $Z_{3,-1}$ -0.09 ± 0.13 respectively.

Discussion

In a recent prospective clinical study on 108 eyes with myopia and myopic astigmatism treated by the Femtosecond Lenticule Extraction (FLEx) Blum and Sekundo reported 98.1% of eyes treated being within ± 1.0 D, and 74.8% of eyes within ± 0.5 D of intended correction⁵. They could also show that 97.1% of patients were satisfied with the obtained results and would undergo the FLEx procedure again⁵. However, they also reported peripheral visually insignificant microstriae in 15.7%, superficial punctate keratitis in 13.9% and subjective dry eye syndrome in 8.3% at 1 week follow-up (unpublished data on file). Microstriae, flap displacement and dry eye syndrome are believed to be a result of flap creation regardless of the type of procedure, whether it is microkeratome LASIK, Femto-LASIK or FLEx^{6,7}.

When FLEx became a feasible option for corneal refractive correction a question arose, if this procedure can be executed through a smaller incision avoiding a flap creation

This very first study on SMILE[®] answers this question. First, a successful refractive correction using two incisions of 80° arc lengths is not only possible, but also provided 83% of eyes treated with an UCVA of 20/20 or better: a result getting close to outcomes known from Femto-LASIK⁸. However, it was our experience that the surgical manoeuvres in the SMILE[®] procedure are far more challenging than in FLEx, as it is of an utmost importance to find the first dissection plane over the roof of the lenticule first. When the spatula undermines the lenticule first getting to its bottom, the surgery becomes difficult, as the thin lenticule “sticks” to the superior corneal layers and becomes almost invisible. This problem does not exist with FLEx, where – in a similar case- the flap can be lifted and the lenticule stripped off from the back of the flap. Nevertheless, as we succeeded in all cases performed with this

prototype of the 200 kHz VisuMax Laser, one can imagine, that the second generation 500kHz machine might provide an even better dissection plane making the removal of the lenticule easier and the incision width smaller. With regard to the microstriae, we observed a marked reduction of microstriae in comparison to FLEx⁵. However, some microstriae can still be observed after myopic SMILE[®] due to the compression effect within the superior corneal layers after the removal of the underlying lenticule. Another noteworthy fact was the reduction of superficial punctate corneal staining and subjective dry eye syndrome ($p < 0.001$, Fishers exact test), when compared with FLEx. These findings support the hypothesis that SMILE[®] reduces the amount of dissected nerve fibers.

Another important finding was the fact that a 110 to 130µm deep vertical corneal incision does not induce detectable irregular corneal topographic astigmatism in an arcuate keratotomy (AK) like fashion. We attribute this to a very low depth of cut as compared to the true AK¹. The concept of two opposite, paired incisions proved successful, as we could assure an adequate flow when flushing the interface.

Nevertheless, in 8.8 % of cases intrastromal debris were recorded in our series.

Despite the more challenging dissection technique of SMILE[®] in comparison to FLEx performed with the same prototype of VisuMax[®] laser, the current study showed slightly better refractive results with regard to the SE and the stability of the achieved refractive change. We assume, that this finding reflects the higher internal structural stability in flapless SMILE[®] treated corneas. Further improvement might be possible, when special SMILE[®] nomograms will be used instead of the original FLEx equation¹. So far no enhancement was required for any of the eyes treated.

However, we are aware that a possible current drawback of the SMILE[®] procedure is an inability for in-situ enhancement. Currently, SMILE[®] treated eyes would either

require an add-on surface ablation or a surgical opening (with femtosecond laser or manually) of the side cut incisions, thus creating a flap, for enhancement purposes. Moreover, the early work of Ruiz et al.⁹ on femtosecond laser intrastromal correction for low degree of refractive error might eliminate this theoretical problem in the future. In summary, this multicenter prospective study showed for the first time that Femtosecond Lenticule Extraction can be achieved through a small incision. This novel flapless approach, named SMILE[®], achieved refractive correction slightly better than FLE_x and very close to the latest generation excimer laser technology, while the structural integrity of the cornea and corneal nerve fibres after SMILE[®] appears to be superior to that of the flap procedures.

These first results should encourage further research in order to obtain optimized nomograms and easier surgical manipulation. We also believe that 500 kHz technology may contribute to a further reduction of the opening side cut incisions.

Legends

Fig.1: A schematic drawing of the SMILE[®] procedure. The VisuMax[®] femtosecond laser system cuts the back of the refractive lenticule followed by its front surface incision. In the 3rd step two vertical opposite incisions 80°arc length are carried out. When the patient has returned to the observation position the final 4th step is performed manually, with the lenticule being dissected through the side cut opening incision and removed manually using forceps.

Fig. 2 A six month postoperative view of the cornea with two fine scars corresponding to the opening incisions at the 12 and 6 o'clock position. The dilated pupil (for fundus examination) underlines the perfect arcuate shape of the opening incisions.

Fig. 3: Safety, shown as a loss/gain in Snellen lines of the BSCVA .

Fig. 4: Predictability of spherical equivalent at 6 months follow-up. 80.2% of eyes are within ± 0.5 D and 95.6% within ± 1.0 D.

Fig. 5: The distribution of UCVA at 6 month follow-up.

Fig. 6: Stability of refractive outcome over the 6-month follow-up period.

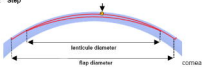
Appendix: A detailed questionnaire used in this study with respective results

References

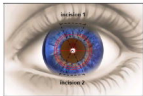
1. Sekundo W. Refraktive Chirurgie. In Augustin AJ (Ed.) „Augenheilkunde“, Springer, Heidelberg New York Tokio; 2007: 823-845
1. Alió JL, Muftuoglu O, Ortiz D, Pérez-Santonja JJ, Artola A, Ayala MJ, Garcia MJ, de Luna GC Ten- year follow-up of laser in situ keratomileusis for high myopia. Am J Ophthalmol 2008; 145:55-64
2. Sekundo W, Bönike K, Mattausch P, Wiegand W. Six-year follow-up of laser in situ keratomileusis for moderate and extreme myopia using a first-generation excimer laser and microkeratome. J Cataract Refract Surg. (2003) 29:1152-1158
3. Sekundo W, Kunert K, Russmann Ch, Gille A, Bissmann W, Strobrawa G, Stickler M, Bischoff M, Blum M. First efficacy and safety study of femtosecond lenticule extraction for the correction of myopia. J Cataract Refract Surg 2008; 34:1513.

-
4. Blum M, Kunert K, Schroeder M, Sekundo W. Femtosecond Lenticule Extraction (FLEX) for the correction of myopia preliminary: 6 month results. Graefes Arch Clin Exp Ophthalmol. 2010 Feb 4. [Epub ahead of print]
 5. Sekundo W. Komplikationen der laserrefraktiven Hornhautchirurgie. Klin Monatsblatt Augenheilk 2008 ;225:R73-82.
 6. Potgieter FJ, Roberts C, Cox IG, Mahmoud AM, Herderick EE, Roetz M, Steenkamp W.J Prediction of flap response. J Cataract Refract Surg. 2005 ;31:106-14.
 7. Blum M, Kunert K, Gille A, Sekundo W LASIK for Myopia using the ZeissVisuMax Femtosecond Laser and MEL 80 Excimer Laser. J Refract Surg 2009; 25:350-356
 8. Ruiz LA, Cepeda LM, Fuentes VC. Intrastromal correction of presbyopia using a femtosecond laser system. J Refract Surg. 2009 25:847-54..

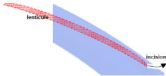
1st & 2nd Step

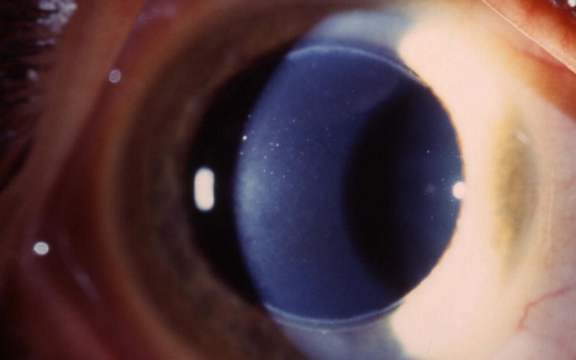


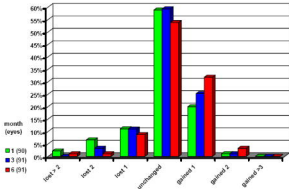
3rd step

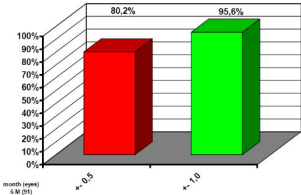


4th step

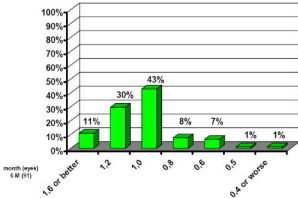








Refractive outcome - Percentage within | Attempted |



UCVA - Percentage 'EFFICACY'

