



HAL
open science

Using A Heating Cable Within The Abdomen To Make Hyperthermic Intraperitoneal Chemotherapy Easier: Feasibility And Safety Study In The Swine

P. Ortega-Deballon, O. Facy, G. Magnin, F. Piard, B. Chauffert, P. Rat

► **To cite this version:**

P. Ortega-Deballon, O. Facy, G. Magnin, F. Piard, B. Chauffert, et al.. Using A Heating Cable Within The Abdomen To Make Hyperthermic Intraperitoneal Chemotherapy Easier: Feasibility And Safety Study In The Swine. *EJSO - European Journal of Surgical Oncology*, 2010, 36 (3), pp.324. 10.1016/j.ejso.2009.11.010 . hal-00566749

HAL Id: hal-00566749

<https://hal.science/hal-00566749>

Submitted on 17 Feb 2011


HAL is a multi-disciplinary open access archive for the deposit and dissemination of scientific research documents, whether they are published or not. The documents may come from teaching and research institutions in France or abroad, or from public or private research centers.

L'archive ouverte pluridisciplinaire **HAL**, est destinée au dépôt et à la diffusion de documents scientifiques de niveau recherche, publiés ou non, émanant des établissements d'enseignement et de recherche français ou étrangers, des laboratoires publics ou privés.

Accepted Manuscript

Title: Using A Heating Cable Within The Abdomen To Make Hyperthermic Intraperitoneal Chemotherapy Easier: Feasibility And Safety Study In The Swine

Authors: P. Ortega-Deballon, O. Facy, G. Magnin, F. Piard, B. Chauffert, P. Rat



PII: S0748-7983(09)00518-6

DOI: [10.1016/j.ejso.2009.11.010](https://doi.org/10.1016/j.ejso.2009.11.010)

Reference: YEJSO 2921

To appear in: *European Journal of Surgical Oncology*

Received Date: 15 September 2009

Accepted Date: 16 November 2009

Please cite this article as: Ortega-Deballon P, Facy O, Magnin G, Piard F, Chauffert B, Rat P. Using A Heating Cable Within The Abdomen To Make Hyperthermic Intraperitoneal Chemotherapy Easier: Feasibility And Safety Study In The Swine, *European Journal of Surgical Oncology* (2009), doi: 10.1016/j.ejso.2009.11.010

This is a PDF file of an unedited manuscript that has been accepted for publication. As a service to our customers we are providing this early version of the manuscript. The manuscript will undergo copyediting, typesetting, and review of the resulting proof before it is published in its final form. Please note that during the production process errors may be discovered which could affect the content, and all legal disclaimers that apply to the journal pertain.

**USING A HEATING CABLE WITHIN THE ABDOMEN TO MAKE
HYPERTHERMIC INTRAPERITONEAL CHEMOTHERAPY EASIER:
FEASIBILITY AND SAFETY STUDY IN THE SWINE**

P Ortega-Deballon^{1,2}, O Facy², G Magnin³, F Piard⁴, B Chauffert^{1,5}, P Rat^{1,2}.

¹ INSERM UMR 866, Equipe Avenir. University of Burgundy, France.

² Department of Digestive and Thoracic Surgical Oncology, University Hospital, Dijon, France

³ Department of Anesthesiology, University Hospital, Dijon, France

⁴ Department of Pathology, University Hospital, Dijon, France

⁵ Department of Medical Oncology, GF Leclerc Regional Anticancer Centre, Dijon, France

Corresponding author and reprints:

Dr Pablo Ortega Deballon

Service de Chirurgie Digestive, Thoracique et Cancérologique

Centre Hospitalier Universitaire du Bocage

1, Bd. Jeanne d'Arc

21079 DIJON Cedex, France

e-mail: pablo.ortega-deballon@chu-dijon.fr

Tel. +33 380 29 37 47

Fax. +33 380 29 35 91

A film showing this procedure was presented at the 6th International Workshop on Peritoneal Surface Malignancies held in Lyon, France, in November 16-19, 2008.

This work was supported by a grant from the University Hospital of Dijon and the Regional Council of Burgundy.

Running title: A heating cable is safe for HIPEC

ABSTRACT

Background. Hyperthermic intraperitoneal chemotherapy (HIPEC) is a complex, expensive and time-consuming procedure. Despite its good results in the treatment of peritoneal carcinomatosis, these factors have precluded the wider use of this procedure around the world. We hypothesized that HIPEC could be performed by heating the liquid within the abdomen and thus avoiding the need for an external heating circuit and a pump. The aim of this study was to assess the feasibility and safety of an internal heating device for hyperthermic intraperitoneal chemotherapy in an experimental model.

Methods. Four large-white pigs underwent one-hour open intraperitoneal hyperthermia with closed abdomen using this new device. Constant stirring of the liquid around the viscera was performed in the first three animals, but not in the fourth one. At the end of the procedure, all of the viscera were carefully examined to look for thermal injury. Any lesion or doubtful area was removed and sent to pathologic examination.

Results. No adverse events occurred during surgery in any of the animals. A temperature of 42°C was reached in an average time of 14 minutes and maintained homogeneously between 42°C and 43°C for one hour. No visceral injury was detected in the first three animals. Three foci of thermal injury to the mucosa were detected in the absence of stirring (fourth animal).

Conclusion. Heating the solution within the abdomen during hyperthermic intraperitoneal chemotherapy is feasible, safe and achieves perfect thermal homogeneity. This device provides a time-saving inexpensive way to perform intraperitoneal hyperthermic chemotherapy.

INTRODUCTION

Hyperthermic intraperitoneal chemotherapy (HIPEC) is an increasingly recognized and used technique in patients with peritoneal carcinomatosis¹⁻⁴. Despite its good results, some drawbacks of HIPEC have probably hindered its wider use around the world. It is a complex, time-consuming operation that requires expensive, sophisticated equipment⁵⁻⁷.

There are two types of HIPEC: one in which the abdomen is left open during chemotherapy (open-abdomen HIPEC) and another one in which the abdomen is closed (closed-abdomen HIPEC). We chose to perform open abdomen HIPEC after improving the security of the procedure with the use of an abdominal cavity expander (a modification of Sugarbaker's "coliseum technique")⁷⁻⁹ and a water-tight cover transforming the abdomen into a sort of glove box¹⁰. This technique has been called "semi-open" (or "semi-closed")¹¹; it provides a safe way to obtain optimal exposure of the viscera during HIPEC (as it is an open procedure) while avoiding exposure of the personnel (as in closed HIPEC).

We hypothesized that (*using the "semi-open" technique*) the heating source could be placed within the abdomen. This would avoid the need for the current complex and expensive perfusion machine and the extracorporeal circuit (heating device, reservoir, pumps), which can become blocked or leak chemotherapy liquid and requires the watchful surveillance of one member of the team. Such a system would also save time, as preparing the circuit is a time-consuming step in HIPEC. We designed a novel HIPEC technique which involves heating the liquid inside the abdomen. The safety and efficacy of this device were assessed in an animal model.

ANIMALS AND METHODS

Description of the prototype

The device consists of a 17 m long electric heating cable covered with silicon rubber insulation. This cable was connected to a 24-volt transformer which was itself connected to a 220-volt electric outlet (figure 1 a and b).

Animals

Four 3-month-old large white female pigs were used, weighing 50-60 kg. All of the pigs were allowed to acclimatize to the laboratory environment for 7 days with free access to standard food and water. They were then operated on and sacrificed at the end of the procedure with an intravenous injection of pentobarbital (Dolethal[®], Vétquinol, France). This project was approved by the Animal Ethics Committee of the University of Burgundy, France.

Anaesthesia

Anesthesia was induced by intramuscular injection of 1 g ketamine + 1 mg atropine, and then completed by intravenous ketamine and sufentanil until endotracheal intubation. The animals were maintained under anaesthesia by isoflurane (1.5%), intravenous sufentanil and cisatracurium. Heart rate, electrocardiogram, esophageal temperature and oxygen blood saturation were measured using the NICO system (Novamatrix Medical Systems Inc., Wallingford, CT). Fluid resuscitation was achieved with isotonic saline and Ringer lactate with a mean volume of 2 litres per pig.

Surgical technique

We used A large midline laparotomy to access the abdomen. Our usual device for closed HIPEC with open abdomen was installed. This procedure has already been described in detail elsewhere¹⁰. Briefly, it consists of a latex abdominal cavity expander stapled to the cutaneous edges and suspended on a metallic frame held by a Thompson retractor (Landanger, France). Two temperature probes (one fixed with a stitch to the diaphragm and one into the pelvis)

were passed through the latex sheet and connected to an integrated system of temperature control (Bodytherm 8180, version 1.2.0, EFS électronique, France). The abdominal cavity was filled in with 3 litres of physiologic serum at 37°C. Two prototypes were used for every animal, one in the supramesocolic and one in the inframesocolic area. The loops of the heating cable passed through the abdominal cavity expander and were uniformly distributed within the abdominal cavity, between bowel loops, in the infradiaphragmatic and infrahepatic areas, in the lesser sac, in both paracolic gutters and in the pelvis. A transparent metacrylate cover with a Gelpport in its centre (Landanger, France) was placed over the metallic frame and the latex piece hermetically closing the abdominal cavity in our usual way to perform HIPEC. We switched on both devices and the temperature progressively increased until 42°C was reached. A temperature between 42°C and 43°C was maintained for one hour. In the first three animals, thermal homogeneity was ensured by constant stirring of the liquid by the surgeon's hand with sequential opening of the different abdominal spaces, thus avoiding a permanent contact within a segment of cable and a part of a viscus. We switched off the device for some minutes when the temperature rose above 43°C in the concerned area. In the fourth animal, stirring was not performed and the cable loops remained in the same position throughout the procedure in order to check if the close contact between the cable and the viscera for one hour induced any thermal injury. After one hour, the liquid was sucked out and the cable loops removed, as were the temperature probes. The skin was incised a few millimetres outside its junction with the expander and both were removed en bloc. All of the viscera were then carefully examined to look for thermal injury. We removed and sent any lesion or doubtful area for pathologic examination.

Statistical data. Time is presented as mean value \pm standard deviation.

RESULTS

Feasibility

The distribution of both loop-wires (one in the supramesocolic and one in the inframesocolic area) took 15 minutes in every animal. After filling the cavity with 3 liters of physiologic serum at 37°C and switching on the prototypes, the temperature progressively increased to reach 42°C in 14 ± 3 minutes. The temperature was uniformly maintained between 42°C and 43°C for one hour. An almost perfect thermal homogeneity was achieved (figure 2). No adverse events occurred during the procedure.

Safety

At the end of the procedure, we did not find any thermal injury in the first three animals despite a thorough search for lesions along the gastrointestinal tube, the vessels, the liver, the biliary tree, the spleen, the urinary bladder and the retroperitoneum. In the fourth animal (in which the liquid was not stirred at all during the 1-hour heating period allowing permanent close contact along the cable and the viscera), three lesions were found in the small bowel with thermal injuries involving only the mucosa (figure 3), as confirmed by the microscopic analysis. There were also disseminated evanescent whitish marks along the bowel serosa which resolved within some minutes. The three injured bowel segments were removed and sent to pathologic examination, which confirmed pre-necrotic ulcerated bowel mucosa without involvement of the muscular layer or the serosa in any case.

DISCUSSION

Set up procedure

With this new device, homogeneous intraperitoneal hyperthermia was achieved. The installation of the prototype was quick and easy. Problems of circuits or tubes becoming blocked were obviously avoided. We think it is important to use two different wires for the supramesocolic and the inframesocolic area as they often behave differently with regard to temperature: temperature in the former is usually lower (probably due to the cooling effect of the ventilation in the lungs). This would allow independent thermal management to achieve homogeneity in both areas (one device can be switched off for some minutes if the temperature rises in that area). Constant stirring also helps to maintain thermal homogeneity. The duration chosen for HIPEC was 1 hour. This is an intermediate point between the 30-minute HIPEC performed by most teams with oxaliplatin for peritoneal carcinomatosis of colorectal origin¹⁴ and the 60-minute or 90-minute HIPEC used for peritoneal pseudomyxoma, mesothelioma or ovarian cancer¹⁵⁻¹⁸.

Logistic drawbacks of HIPEC

Cytoreduction prior to HIPEC is the most time-consuming step of the operation, but the installation of the circuit is also a time-consuming part of the operation. The external heating circuit can become blocked by the suction of viscera or by lumps of fatty tissue, meaning that one person has to watch it almost full time throughout the procedure. The required equipment is expensive, which may hinder the wider use of HIPEC around the world^{12,13}. There is also a fear of exposure of the personnel to chemotherapy drugs. All these problems need to be overcome.

Originality and interest of this device

Placing the heating source in the abdomen avoids the need for a circuit and a pump, saving time and money. It also makes HIPEC safer, as there is no external circuit with its risk of

leaks of chemotherapy drugs. If this device is used in the context of our previously described closed abdominal cavity expander¹⁰, it provides a safe and less expensive way to perform open HIPEC. This simplification of the traditional technique could make HIPEC available for more surgical teams.

To our knowledge, no authors have performed HIPEC without an external circuit and a pump. Cho et al. evaluated two annular-phased-array applicators in order to perform external regional hyperthermia associated with systemic standard chemotherapy for peritoneal carcinomatosis, but there was no HIPEC¹⁹. Mochiki et al. performed gastrectomy with postoperative intraperitoneal hyperthermo-chemotherapy (PIHC) using Thermotron RF-8 (a heating device that can raise temperatures in both superficial and deep-seated tumours using radiofrequency electromagnetic waves as a source of heat)²⁰. However, the concept of heating the liquid inside the abdomen during surgery in HIPEC is totally new.

Risk of thermal injury

The main concern with this new concept is the risk of thermal injury. Stirring within the abdominal cavity was done in the first three animals due to the fear of thermal injuries in case of a close and permanent contact between a segment of the heating cable and the viscera. In the absence of stirring during the one-hour hyperthermia (fourth animal), three sites of thermal injury were found in the bowel. Even though the external layers of the bowel were not involved (probably due to the fact that the mucosa is the most sensitive layer of the bowel), we must emphasize the need for constant stirring in order to obtain a totally safe procedure. It could be argued that thermal injuries are not always immediately apparent and that a survival of the animals with a follow-up was necessary. However, if the three lesions that were apparent after an extensive search in the fourth animal involved only the mucosa, we think this is a supplementary argument to think that there were no full-thickness injuries at all.

We can conclude that heating the liquid inside the abdomen during HIPEC is feasible, safe and achieves optimal thermal homogeneity. A phase I clinical study in which this cable is used to heat the liquid within the abdomen during open HIPEC with closed abdomen is warranted.

ACCEPTED MANUSCRIPT

ACKNOWLEDGMENTS

We thank Philip Bastable for revising the manuscript, Jean-Luc Beltramo for his advice regarding the effects of the potential magnetic field generated by the prototype, and the ENESAD staff (Véronique Julliand, Vet.D., and Céline Faubladièr) for their kind welcome and their care for animals.

Conflict of interest

Patrick Rat, M.D. owns the copyright for this new concept and for the prototype (patent number: FR08.00683, 2008, February). He has received lecture fees from Landanger, France, regarding other technical developments in HIPEC, but not concerning the present device. No other conflict of interest regarding this work declared.

REFERENCES

1. Verwaal VJ, van Ruth S, Witkamp A et al. Long-term survival of peritoneal carcinomatosis of colorectal origin. *Ann Surg Oncol* 2005; 12: 65-71.
2. Yan T, Morris DL. Cytoreductive surgery and perioperative intraperitoneal chemotherapy for isolated colorectal peritoneal carcinomatosis: experimental therapy or standard of care? *Ann Surg* 2008; 248: 829–835.
3. Esquivel J, Sticca R, Sugarbaker P et al. Cytoreductive surgery and hyperthermic intraperitoneal chemotherapy in the management of peritoneal surface malignancies of colonic origin: a consensus statement. *Ann Surg Oncol* 2007; 14: 128–33.
4. Verwaal VJ, Bruin S, Boot H et al. 8-Year follow-up of randomized trial: cytoreduction and hyperthermic intraperitoneal chemotherapy versus systemic chemotherapy in patients with peritoneal carcinomatosis of colorectal cancer. *Ann Surg Oncol* 2008; 15: 2426–32.
5. Bonastre J, Jan P, Pouvourville G et al. Coûts et financement de la chimiohyperthermie intrapéritonéale (CHIP) associée à une chirurgie d'exérèse. *Ann Chir* 2005; 130: 553-61.
6. Stewart JH, Shen P, Levine E. Intraperitoneal hyperthermic chemotherapy for peritoneal surface malignancy: current status and future directions. *Ann Surg Oncol* 2005; 12: 765-77.
7. Sugarbaker PH, Clarke L. The approval process for hyperthermic intraoperative intraperitoneal chemotherapy. *Eur J Surg Oncol* 2006; 32:637–43.
8. Elias D, Antoun B, Raynard JM et al. Traitement des carcinoses péritonéales par exérèse complète et chimiohyperthermie intrapéritonéale. Etude de phase I-II permettant de définir la meilleure procédure technique. *Chirurgie* 1999; 124: 380-9.

9. Rat P, Benoit L, Cheynel N et al. La chimiothérapie intrapéritonéale à ventre ouvert et avec « débordement ». *Ann Chir* 2001; 126: 669-71.
10. Benoit L, Cheynel N, Ortega-Deballon P et al. Closed hyperthermic intraperitoneal chemotherapy with open abdomen: a novel technique to reduce exposure of the surgical team to chemotherapy drugs. *Ann Surg Oncol* 2008; 15: 542-6.
11. Glehen O, Cotte E, Kusamura S et al. Hyperthermic intraperitoneal chemotherapy: nomenclature and modalities of perfusion. *J Surg Oncol* 2008; 98: 242-6.
12. Bonastre J, Jan P, de Pourvoirville G et al. Coûts et financement de la chimiohyperthermie intrapéritonéale (CHIP) associée à une chirurgie d'exérèse. *Ann Chir* 2005; 130: 553-61.
13. Elias D, Bonnay M, Puizillou JM et al. Heated intraoperative intraperitoneal oxaliplatin after complete resection of peritoneal carcinomatosis : pharmacokinetic and tissue distribution. *Ann Oncol* 2002; 13: 267-72.
14. Elias D, Lefevre JH, Chevalier J et al. Complete cytoreductive surgery plus intraperitoneal chemohyperthermia with oxaliplatin for peritoneal carcinomatosis of colorectal origin. *J Clin Oncol* 2009; 27: 681-5.
15. Elias D, Honoré C, Ciuchendea R et al. Peritoneal pseudomyxoma: results of a systematic policy of complete cytoreductive surgery and hyperthermic intraperitoneal chemotherapy. *Br J Surg* 2008; 95: 1164-71.
16. Gesson-Paute A, Ferron G, Thomas F, Cohen de Lara E, Chatelut E, Querleu D. Pharmacokinetics of oxaliplatin during open versus laparoscopically assisted heated intraoperative intraperitoneal chemotherapy (HIPEC): an experimental study. *Ann Surg Oncol* 2008;15: 339-44.

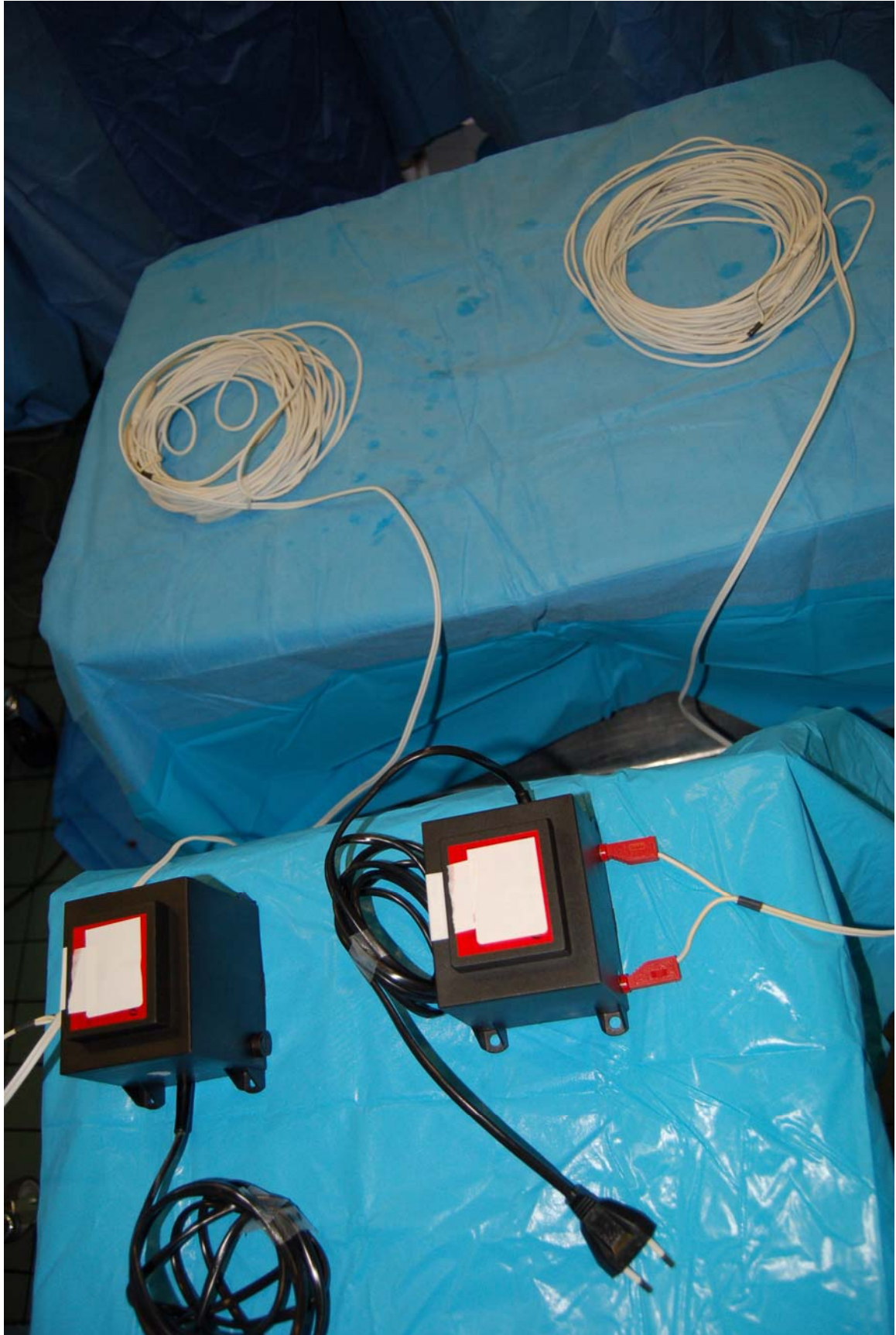
17. Brigand C, Monneuse O, Mohamed F et al. Peritoneal mesothelioma treated by cytoreductive surgery and intraperitoneal hyperthermic chemotherapy: results of a prospective study. *Ann Surg Oncol* 2006; 13: 405-12.
18. Cotte E, Glehen E, Mohamed F et al. Cytoreductive surgery and intraperitoneal chemohyperthermia for chemoresistant and recurrent advanced epithelial ovarian cancer: prospective study of 81 patients. *World J Surg* 2007; 31: 1813-20.
19. Cho CH, Wust P, Hildebrandt B et al. Regional hyperthermia of the abdomen in conjunction with chemotherapy for peritoneal carcinomatosis: evaluation of two annular-phased-array applicators. *Int J Hyperthermia* 2008; 24: 399-408.
20. Mochiki E, Shioya M, Sakurai H et al. Feasibility study of postoperative intraperitoneal hyperthermochemotherapy by radiofrequency capacitive heating system for advanced gastric cancer with peritoneal seeding. *Int J Hyperthermia* 2007; 23: 493-500.

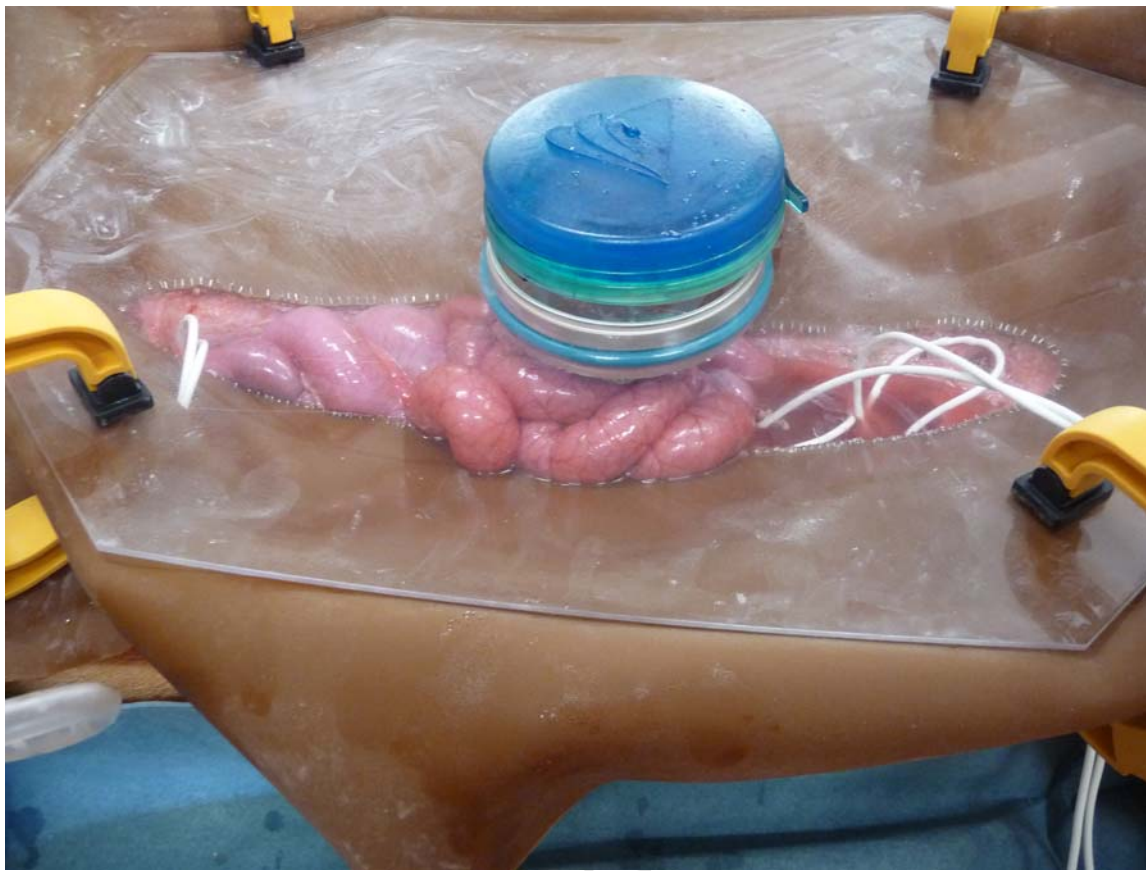FIGURE LEGENDS

Figure 1. The prototype consists of a low-voltage insulated electric resistance cable connected to a 24 volts transformer (a). The two heating cables used for every HIPEC passed through the abdominal cavity expander and were distributed within the abdomen (b).

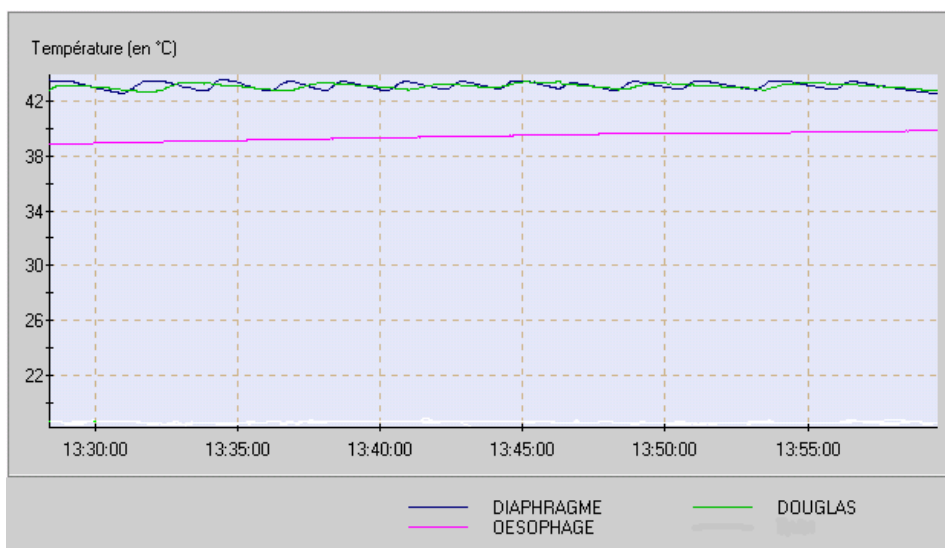
Figure 2. Temperature curves (in °C) in both probes (“Diaphragme”: diaphragm and “Douglas”: pelvis) during the procedure showing thermal homogeneity. Central temperature (“Oesophage” denotes the thermal probe in the oesophagus) was never above 39.5 °C.

Figure 3. Three thermal injuries were encountered in the small bowel in animal number 4 (no stirring during the 1-hour procedure). Only the mucosa was involved..

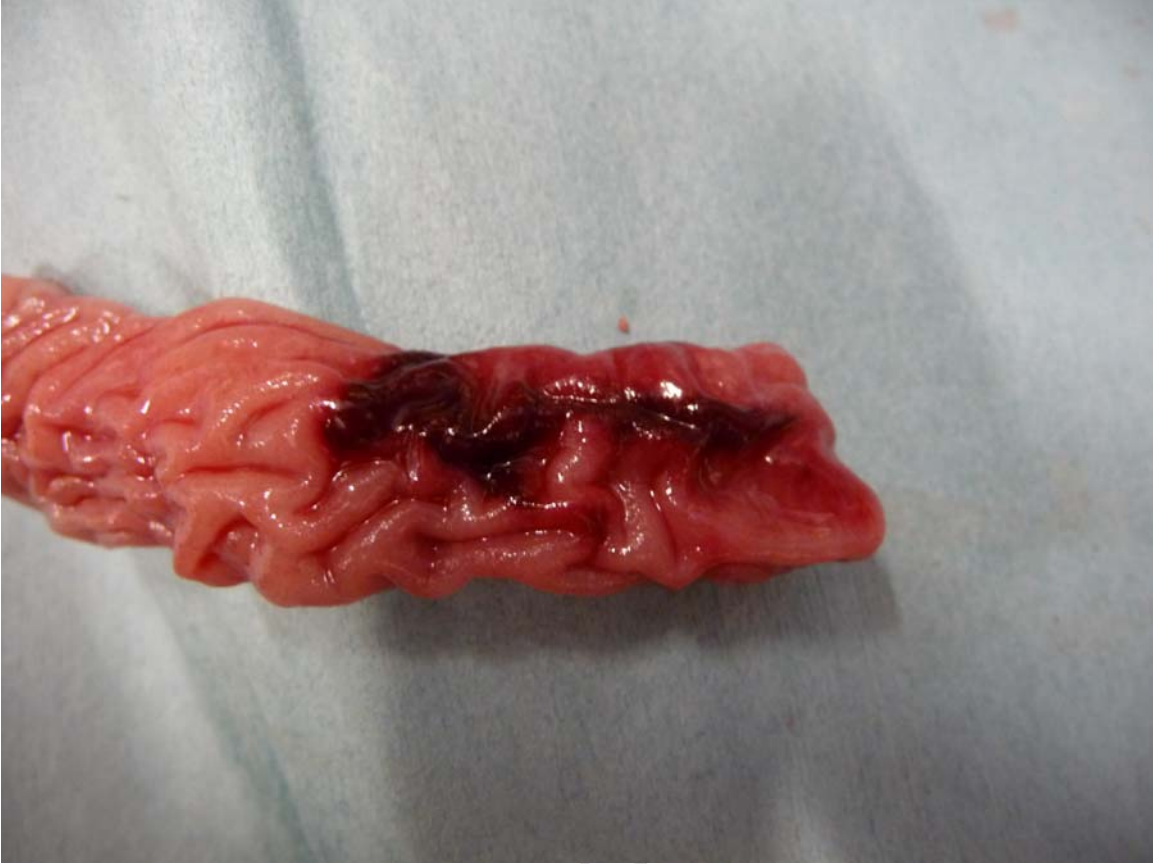



ACCEPTED I



ACCEPTED MA



ACCEPTED I