



HAL
open science

Results of liver resection in combination with radiofrequency ablation for hepatic malignancies

R.M. Eisele, J. Zhukowa, S. Chopra, S.C. Schmidt, U. Neumann, J. Pratschke,
G. Schumacher

► **To cite this version:**

R.M. Eisele, J. Zhukowa, S. Chopra, S.C. Schmidt, U. Neumann, et al.. Results of liver resection in combination with radiofrequency ablation for hepatic malignancies. *EJSO - European Journal of Surgical Oncology*, 2010, 36 (3), pp.269. 10.1016/j.ejso.2009.07.188 . hal-00566740

HAL Id: hal-00566740

<https://hal.science/hal-00566740>

Submitted on 17 Feb 2011

HAL is a multi-disciplinary open access archive for the deposit and dissemination of scientific research documents, whether they are published or not. The documents may come from teaching and research institutions in France or abroad, or from public or private research centers.

L'archive ouverte pluridisciplinaire **HAL**, est destinée au dépôt et à la diffusion de documents scientifiques de niveau recherche, publiés ou non, émanant des établissements d'enseignement et de recherche français ou étrangers, des laboratoires publics ou privés.

Accepted Manuscript

Title: Results of liver resection in combination with radiofrequency ablation for hepatic malignancies

Authors: R.M. Eisele, J. Zhukowa, S. Chopra, S.C. Schmidt, U. Neumann, J. Pratschke, G. Schumacher



PII: S0748-7983(09)00406-5

DOI: [10.1016/j.ejso.2009.07.188](https://doi.org/10.1016/j.ejso.2009.07.188)

Reference: YEJSO 2870

To appear in: *European Journal of Surgical Oncology*

Received Date: 23 March 2009

Revised Date: 12 July 2009

Accepted Date: 23 July 2009

Please cite this article as: Eisele RM, Zhukowa J, Chopra S, Schmidt SC, Neumann U, Pratschke J, Schumacher G. Results of liver resection in combination with radiofrequency ablation for hepatic malignancies, *European Journal of Surgical Oncology* (2009), doi: 10.1016/j.ejso.2009.07.188

This is a PDF file of an unedited manuscript that has been accepted for publication. As a service to our customers we are providing this early version of the manuscript. The manuscript will undergo copyediting, typesetting, and review of the resulting proof before it is published in its final form. Please note that during the production process errors may be discovered which could affect the content, and all legal disclaimers that apply to the journal pertain.

**Results of liver resection in combination with radiofrequency ablation for
hepatic malignancies**

R.M. Eisele, J. Zhukowa, S. Chopra, S.C. Schmidt, U. Neumann, J. Pratschke, G.
Schumacher

Department of General-, Visceral-, and Transplantation Surgery, Charité Campus
Virchow Klinikum, Berlin, Germany

Corresponding author:

Robert M. Eisele MD

Department of General-, Visceral-, and Transplantation Surgery

Universitätsmedizin Berlin

Charité Campus Virchow Klinikum

Augustenburger Platz 1

13353 Berlin

Germany

Tel: +49-30-450-652483

Fax: +49-30-450-552900

e-mail: robert_m.eisele@charite.de

Abstract

Introduction: Liver tumors should be surgically treated whenever possible. In case of bilobar disease or coexisting liver cirrhosis, surgical options are limited. Radiofrequency ablation (RFA) has been successfully used for irresectable liver tumors. The combination of hepatic resection and RFA extends the feasibility of open surgical procedures in patients with liver metastases and hepatocellular carcinoma (HCC).

Patients and methods: RFA was performed with two different monopolar devices using ultrasound guidance. Intraoperative use of RFA for the treatment of liver metastases or HCC was limited to otherwise irresectable tumors during open surgical procedures including hepatic resections. Irresectability was considered if bilobar disease was treated, the functional hepatic reserve was impaired or appraised marginal for allowing further resection.

Results: Ten patients with both liver metastases and HCC, and two patients with cholangiocellular carcinoma were treated. Complete initial tumor clearance was achieved in all patients. Two patients of the metastases group and five patients of the HCC group suffered from local recurrence after a median of 12 months (1-26) (local recurrence rate 32%). Five patients of the metastases group and six patients of the HCC group developed recurrent tumors in different areas of the ablation site after a median time of 4 months (2-18) (distant intrahepatic recurrence in 55%). Survival at 31 months was 36%.

Conclusion: RFA extends the scope of surgery in some candidates with intraoperatively found irresectability.

Introduction

Radiofrequency ablation (RFA) of liver tumors has been established for the treatment of irresectable liver tumors with limited size [1-3]. The approach of RFA may be percutaneous, laparoscopic, or via laparotomy. The decision for a specific approach is based among others on tumor site, number of nodules and general health condition. The percutaneous and laparoscopic approaches are minimally invasive and are used successfully under certain conditions. [4-7]. RFA via laparotomy offers many advantages compared to the percutaneous and laparoscopic approach. The placement of the RFA electrode is more accurate and safer than using percutaneous or laparoscopic approaches, which may be the reason for improved tumor control in case of open surgical approach [8]. Intraoperative staging is made possible by the use of intraoperative ultrasound. Furthermore, RFA may extend the feasibility of surgery in case of multiple tumors [9,10]. With a multimodal approach including hepatic resection, RFA and chemotherapy, a median survival of 36 months could be achieved in technically unresectable patients with colorectal liver metastases [11]. These results double the survival rate compared to other treatment modalities in this group of patients. In patients with bilobar metastases or advanced cirrhosis, major liver resections are impossible because of the postoperative liver failure. We show here an extension of resectability of otherwise irresectable tumors using the combination of liver resection and RFA.

Patients and Methods

Indication for liver resection, RFA and the combination of both, was made individually. Criteria for the decision were extent of tumor, number of tumor nodules, presence and degree of cirrhosis, and expected loss of functional liver parenchyma. RFA was performed instead of resection to prevent loss of functional liver parenchyma, which could lead to fatal liver failure. Whether to treat an individual tumor nodule by resection or RFA was usually not determined until the procedure; the decision was only made intraoperatively. In cirrhotic livers, RFA of technically resectable HCC nodules was occasionally preferred rather than loss of large parenchymal masses due to anatomic resection, e.g. in case of advanced cirrhotic impairment of functional capabilities, whereas in metastatic disease, RFA was performed in case of bilobar disease after resection of one liver lobe and residual tumor deep in the parenchyma of the remaining; superficial lesions were rather resected.

Technical features

Pretherapeutic diagnostic work-up included cross-sectional imaging as well as blood values reflecting liver function. All ablations were performed under intraoperative ultrasound guidance. Cool-tip single needles and a 200 W generator (Radionics, Burlington, MA) were used in 12 procedures, and the RITA medical device Starburst XL 15 cm and the model 1500 generator (RITA medical Ltd., Mountain View, CA) in 10. In general, it was intended to treat one tumor with a single ablation. Overlapping ablation areas were considered in tumor sizes exceeding 4.0 cm (n=2). Immediate postoperative cross-sectional imaging was performed only in selected cases (n=3), if intraoperative ultrasound was not conclusive in confirming complete ablation of the tumor. Indication for a surgical treatment was confirmed by a multi-disciplinary tumor board. Informed consent was obtained prior to RFA in all procedures.

Follow-up

Follow-up was performed every three months during the first year, every six months during the second year and thereafter annually. As is usual in oncological practice, the screening method of choice was transabdominal ultrasound supplemented in case of suspicious ultrasound findings by computed tomograms or magnetic resonance imaging, usually enhanced by contrast media, besides basic clinical

examinations and assessment of laboratory parameters (e.g. tumor markers). If suspicious findings remained, the patients received further treatment; histopathological confirmation of tumor recurrence was not compulsory.

Presentation of the data

Continuous data were expressed as median with ranges or mean +/- standard deviation and compared using the Mann–Whitney U test after exclusion of a Gaussian distribution by Kolmogorov-Smirnov testing. Categorical data were compared using the Chi square test or Fisher's exact test where appropriate. The statistical analyses were performed using commercially available SPSS 14.0 statistical software (SPSS Company, Chicago, Illinois, U.S.A.). Differences were considered to be statistically significant if the p value was less than 0.05. Survival data were counted regardless of the censored cases; cumulative analysis of overall and disease-free survivals for different groups were however calculated by the Kaplan-Meier method, and statistical comparisons were based on the log-rank test.

Results

Indications

From 2001 to 2005, 22 liver resections, combined with RFA, were performed. None of the procedures were combined with extrahepatic surgery. Age of the patients was 61 +/- 12 years. 15 patients were male, seven female. The patients suffered from hepatocellular carcinoma (HCC) (n=10), cholangiocellular carcinoma (CCC) (n=2), or metastases (n=10), which derived from colorectal cancer (n=8), malignant melanoma (n=1) or neuroendocrine disorders (n=1). All patients presented with bifocal (n=6) or multilocular tumor disease (n=16). While patients with metastases and CCC had no liver cirrhosis, seven out of ten patients with HCC suffered from Child A (n=5) or Child B (n=2) cirrhosis. Three patients with HCC had no cirrhosis. Four patients had received chemotherapy prior to the combined surgical procedure.

Procedures

The largest resection was a hemihepatectomy in eight patients. No extended resection was performed in combination with RFA. Other resections included left lateral bisegmentectomies (n=6) or atypical resections (n=18, sum beyond 22 due to procedures including various types of resections [n=5]). RFA was performed to ablate one (n=18) or two (n=4) nodules. Tumor size of ablated nodules ranged from 1.0 to 4.2 cm in diameter. Seven RF-ablated tumors had a diameter of 3 cm or were larger.

Complications

According to the classification of Clavien, the majority of the complications were classified as grade I. Four patients underwent endoscopic treatment of biliary leakage as a grade III complication with uneventful further clinical course. Two grade IV complications occurred: One patient needed temporary hemodialysis for acute renal failure due to formation of ascites, and the other spent 142 days in the hospital, among them 81 in the intensive care unit, for septic complications. No grade V complication, i.e. death of the patient, occurred. Patients were dismissed after an average hospital stay of 23 days. Patients with liver cirrhosis did not stay significantly longer than the average; in contrary, their hospital stay tended towards a shorter duration (15 days, p=0.581 [Mann-Whitney-U-test]).

Survival and outcome

Outcome and survival is shown on a patient-by-patient basis in table 1. Tumor recurrence was observed in 20 patients. Truly local recurrence after RFA was seen in seven patients (32% on a per-patient-, 27% on a per-tumor-basis). Tumor recurrence with new tumor nodules in other parts of the liver was present in 12 patients. After a follow up of 31 months, eight patients are still alive, two without tumor burden and six with tumor recurrence. Four of the latter patients received further treatment comprising of a liver transplantation in one case and repeated resection in the other three patients. Seven patients were treated with chemotherapy due to systemic tumor progression. An explicit analysis of the success rates was not performed for the heterogeneity of the patient population and the different chemotherapeutic regimens applied. Kaplan-Meier estimations of survival and disease free survival are displayed separately for metastases and primary liver tumors in figure 1. No statistically significant difference in survival was found in the log-rank comparison of the results of both entities ($p=0.815$ and $p=0.841$ for overall and disease free survival, respectively).

Discussion

The presented series shows a successful extension of the feasibility of surgical treatment of liver tumors using the combination of liver resection and RFA. These findings resemble some results reported in the literature [11-23] on the feasibility of this treatment approach with limited complications and increased survival. Table 2 provides an overview of reports on such a combined treatment. The total population encompassed accounts for 631 patients. Approximately one third of the publications consist of case reports; only two reports on larger series (> 100 patients) are available. The patient population in ten of the 15 reports included patients with predominantly metastatic, mostly colorectal liver disease with an assumed normal liver function. In contrary, our patient groups included not only metastatic liver tumors with normal liver function, but also primary liver tumors (HCC and CCC). Seven out of a total of ten patients with HCC presented with liver cirrhosis. Two of these patients had an advanced liver disease (stage B according to the Child-Pugh-classification). Only limited resections were performed in this group of patients. However, in two of the five patients with Child A cirrhosis, a left sided hemihepatectomy was performed in combination with RFA for a tumor in the remaining right liver lobe. Resection of tumors in cirrhotic livers is an established approach [26]. RFA in cirrhotic livers has also been described by several authors [27]. The combination of both resection and RFA for HCC in cirrhotic livers may have an increased risk of postoperative liver failure. However, there was no such postoperative deterioration of liver function in the presented series. In contrary, even the postoperative hospital stay seems to be shorter or at least comparable to non-cirrhotic patients in this subgroup of patients. A present report on a single center experience with simultaneous resection and RFA for HCC by Kim et al. [24] confirms data provided by Choi et al. [22], who found a 3 and 5 year-survival of 73% and 47%, respectively, compared to a similar rate of complications and a slightly better survival (80% for 3 years and 55% for 5 years) [24]. In contrast, Raut et al. [19] report on inferior survival rates (45% for 3 and 5 years) and more complications compared to the Korean experience [22]. Our own data approach those figures (survival 50% after 3 years for HCC patients only, see fig. 1). However, liver transplantation (LTX) for HCC reveals a better long-term survival of up to 71% after 5 years [28], if appropriate selection criteria are adopted. CCC is generally not a good indication for LTX, however, there is a highly selective group in which LTX may be superior to other therapies [29]. In conclusion, after

thorough patient selection and correct preoperative staging, an individual decision for this approach may lead to the indication for a combined treatment.

Complications

Similar to reports in the literature [11-17,19,20,22,24], a considerable rate of complications ranging from 10 to 33% was observed in our experience. However, no postoperative liver failure was observed. Notably, neither heat injury of adjacent organs nor intrahepatic abscess formation, or biliary duct damage, occurred in the presented series, which indicates, that intraoperative RFA can be performed safely and without adding intolerable risk to the patient. Frequent complications were biliary leakages inherent in hepatic resection. Most of them could be managed by endoscopic interventions, and were eventually treated successfully. No death occurred.

Liver metastases

Liver resection for colorectal metastases seems to provide a five-year survival of 25 to 40%. Neoadjuvant chemotherapy may even improve resectability. Thirteen to sixteen percent of unresectable patients could be rendered resectable. The most important factor is to achieve a tumor-free status after resection. Liver resection of metastases from other primary tumors such as breast, stomach, pancreas, melanoma, or others has to be decided individually, if extrahepatic tumor is disclosed. The effectiveness of RFA versus liver resection for colorectal liver metastases has been previously shown already [17]. Compared to RFA, liver resection appears to lead to prolonged overall survival. Thus, open surgery and subsequent liver resection should be performed whenever possible, which can then be combined with RFA during the same procedure if necessary. In such a setting RFA can be performed safely and efficiently without loss of large parts of functional liver parenchyma. Moreover, RFA during laparotomy causes significantly better long-term tumor control than laparoscopic or percutaneous RFA, because of a more precise placement of the RFA electrode [30]. The result is an expected better local tumor control [30]. The comparably high local recurrence rate of 27% on a per-tumor basis in the presented series is partly explained by the presence of large nodules (≥ 3 cm, $n = 7$ [approximately one third of all RF-ablated nodules]) treated with RFA. Tumor size exceeding 3 cm is known to be a significant risk factor for increased local

recurrence rates [8]. Furthermore, propensity score methods applied by Gleisner et al. demonstrated, that a poor survival following combined resection and RFA may be the result of different tumor biologic profiles rather than inappropriate treatment strategies including RFA [25]. With a multimodal approach including (major and minor) hepatic resection, RFA and chemotherapy, a median survival of 36 months could be achieved in technically irresectable patients with colorectal liver metastases [11]. This figure doubles the survival of any other treatment modality in this group of patients. Our results confirm these data regarding the low rate of complications; median overall survival was slightly inferior with 26 months in a mixed population with various indications. However, in selected cases, intraoperatively found irresectability can be converted into an operable condition using RFA additionally to hepatic resections.

ACCEPTED MANUSCRIPT

References

1. Curley S A. Radiofrequency ablation of malignant liver tumors. *Ann Surg Oncol* 2003;10:338-47.
2. Sutherland L M, Williams J A, Padbury R T, Gotley D C, Stokes B, Maddern G J. Radiofrequency ablation of liver tumors: a systematic review. *Arch Surg* 2006;141:181-90.
3. Lam C M, Ng K K, Poon R T, Ai V, Yuen J, Fan S T. Impact of radiofrequency ablation on the management of patients with hepatocellular carcinoma in a specialized centre. *Br J Surg* 2004;91:334-8.
4. Kettenbach J, Blum M, Kilanowicz E, Schwaighofer S M, Lammer J. [Percutaneous radiofrequency ablation of liver cell carcinoma: a current overview]. *Radiologe* 2004;44:330-8.
5. Yokoyama T, Egami K, Miyamoto M, et al. Percutaneous and laparoscopic approaches of radiofrequency ablation treatment for liver cancer. *J Hepatobiliary Pancreat Surg* 2003;10:425-7.
6. Lencioni R, Crocetti L, Cioni D, Della Pina C, Bartolozzi C. Percutaneous radiofrequency ablation of hepatic colorectal metastases: technique, indications, results, and new promises. *Invest Radiol* 2004;39:689-97.
7. Lencioni R, Cioni D, Crocetti L, Bartolozzi C. Percutaneous ablation of hepatocellular carcinoma: state-of-the-art. *Liver Transpl* 2004;10:S91-7.
8. Kuvshinov B W, Ota D M. Radiofrequency ablation of liver tumors: influence of technique and tumor size. *Surgery* 2002;132:605-11; discussion 611-2.
9. Hanna N N. Radiofrequency ablation of primary and metastatic hepatic malignancies. *Clin Colorectal Cancer* 2004;4:92-100.
10. Poon R T. Recent advances in techniques of liver resection. *Surg Technol Int* 2004;13:71-7.
11. Elias D, Baton O, Sideris L, et al. Hepatectomy plus intraoperative radiofrequency ablation and chemotherapy to treat technically unresectable multiple colorectal liver metastases. *J Surg Oncol* 2005;90:36-42.
12. Elias D, Goharin A, elOtmayn A, et al. Usefulness of intraoperative radiofrequency thermoablation of liver tumours associated or not with hepatectomy. *EJSO* 2000;26:763-9.
13. Oshowo A, Gillams AR, Lees WR, Taylor I. Radiofrequency ablation extends the scope of surgery in colorectal liver metastases. *EJSO* 2003;29:244-7.
14. Pawlik TM, Izzo F, Cohen DS, Morris JS, Curley SA. Combined resection and radiofrequency ablation for advanced hepatic malignancies: results in 172 patients. *Ann Surg Oncol* 2003;10(9):1059-69.
15. Evrard S, Becouarn Y, Fonck M, Brunet R, Mathoulin-Pelissier S, Picot V. Surgical treatment of liver metastases by radiofrequency ablation, resection, or in combination. *EJSO* 2004;30:399-406
16. Tepel J, Hinz S, Klomp HJ, Kapischke M, Kremer B. Intraoperative radiofrequency ablation (RFA) for irresectable liver malignancies. *EJSO* 2004;30:551-5.
17. Abdalla E, Vauthey JN, Ellis LM, et al. Recurrence and outcomes following hepatic resection, radiofrequency ablation, and combined resection/ablation for colorectal liver metastases. *Ann Surg* 2004;239:818-27.
18. Mateo R, Singh G, Jabbour N, Palmer S, Genyk Y, Roman L. Optimal cytoreduction after combined resection and radiofrequency ablation of hepatic metastases from recurrent malignant ovarian tumors. *Gynecol Oncol* 2005;97:266-70.
19. Raut CP, Izzo F, Marra P, et al. Significant long-term survival after radiofrequency ablation of unresectable hepatocellular carcinoma in patients with cirrhosis. *Ann Surg Oncol* 2005;12(8):616-28.
20. Fiiole B, Jansen MC, vanDuijnhoven FH, vanHillegersberg R, vanGulik TM, Borel Rinkes IHM. Combining partial liver resection and local ablation of liver tumours: a preliminary Dutch experience. *W J Surg Oncol* 2006;4:46.
21. Hildebrand P, Kleemann M, Roblick UJ, et al. Radiofrequency-ablation of unresectable primary and secondary liver tumors: results in 88 patients. *Langenbecks Arch Surg* 2006;391:118-23.
22. Choi D, Lim HK, Joh JW, et al. Combined hepatectomy and radiofrequency ablation for multifocal hepatocellular carcinomas: long-term follow-up results and prognostic factors. *Ann Surg Oncol* 2007;14(12):3510-8.
23. Kornprat P, Jarnagin WR, deMatteo RP, Fong Y, Blumgart LH, d'Angelica M. Role of intraoperative thermoablation combined with resection in the treatment of hepatic metastasis from colorectal cancer. *Arch Surg* 2007;142(11):1087-92.
24. Kim YS, Rhim H, Lim HK, et al. Intraoperative radiofrequency ablation for hepatocellular carcinoma: long-term results in a large series. *Ann Surg Oncol* 2008;15(7):1862-70.
25. Gleisner AL, Choti MA, Assumpcao L, Nathan H, Schulick RD, Pawlik TM. Colorectal liver metastases – recurrence and survival following hepatic resection, radiofrequency ablation, and combined resection-radiofrequency ablation. *Arch Surg* 2008;143(12):1204-12.
26. Yanaga K. Current status of hepatic resection for hepatocellular carcinoma. *J Gastroenterol* 2004;39:919-26.
27. Santambrogio R, Bianchi P, Palmisano A, Donadon M, Moroni E, Montorsi M. Radiofrequency of hepatocellular carcinoma in patients with liver cirrhosis: a critical appraisal of the laparoscopic approach. *J Exp Clin Cancer Res* 2003;22:251-5.
28. Jonas S, Bechstein WO, Steinmuller T, et al. Vascular invasion and histopathologic grading determine outcome after liver transplantation for hepatocellular carcinoma in cirrhosis. *Hepatology*. 2001 May;33(5):1080-6.
29. Pascher A, Jonas S, Neuhaus P. Intrahepatic cholangiocarcinoma: indication for transplantation. *J Hepatobiliary Pancreat Surg*. 2003;10(4):282-7.
30. Eisele RM, Neumann U, Neuhaus P, Schumacher G. Open surgical is superior to percutaneous access for radiofrequency ablation of hepatic metastases, *W J Surg* 2009;33(4):804-11

Conflict of interest statement

There are no conflicts of interest. None of the authors have any conflict of interest in the submitted manuscript EXTENDED INDICATION FOR LIVER RESECTION IN COMBINATION WITH RADIOFREQUENCY ABLATION.

Robert M. Eisele on behalf of the authors

ACCEPTED MANUSCRIPT

	Tumor number		Segments involved			Survival		Recurrence		
	total	treated by RFA	total	resected	RFA	overall	disease-free	local	distant intrahep.	systemic
Met. 1	3	2	2,4,7	2	4,7	34	26	no	yes	yes
Met. 2	4	1	2/3,4,6/7	2/3,4,6/7	4	42	2	no	yes	yes
Met. 3	3	2	2/3,4,6	2/3	4,6	17	14	no	no	yes
Met. 4	3	1	4/2,4,7	4/2,7	4	20	6	yes	yes	yes
Met. 5	3	2	2/3,7,8	2/3	7,8	3	2	no	yes	yes
Met. 6	8	1	1,2/3,3,4	1,2/3,4	3	5	5	no	no	no
Met. 7	4	2	2,4,5,6	2/3,6	4,5	16	5	no	no	yes
Met. 8	2	1	2/3,6	2/3	6	51	2	no	yes	no
Met. 9	3	1	4,6/7,8	2-4,8	6/7	48	6	yes	no	yes
Met. 10	2	1	4,8	2-4	8	48	48	no	no	no
HCC 1	3	1	2,5/6,7/8	2,7/8	5/6	12	5	no	no	no
HCC 2	3	1	2,3,7/8	2,5-8	3	18	4	yes	yes	no
HCC 3	2	1	7,8	7	8	26	8	no	yes	no
HCC 4	5	1	2,4,6	4,6	2	65	29	yes	no	no
HCC 5	3	1	2,3,8	2-4	8	63	1	yes	yes	yes
HCC 6	3	1	2/3,4,5/6	2-4	5/6	59	18	no	yes	no
HCC 7	2	1	1,5/6	5/6	1	2	2	no	no	yes
HCC 8	3	1	3 (2x),5	3,5-8	3	41	15	yes	no	no
HCC 9	2	1	4 (2x)	4	4	8	4	no	yes	yes
HCC 10	2	1	6,8	6	8	49	49	yes	yes	no
CCC 1	4	1	2,3,8	2-4	8	9	9	no	no	yes
CCC 2	4	1	2,3,4,6	3,4,5-8	2	17	1	no	yes	yes

Table 1: Results including procedure specific data as well as survival, local, distant intrahepatic (distant intrahep.) and systemic recurrence for patients with metastases (met), hepatocellular carcinoma (HCC) and cholangiocellular carcinoma (CCC) following combined treatment of resection and radiofrequency ablation (RFA)

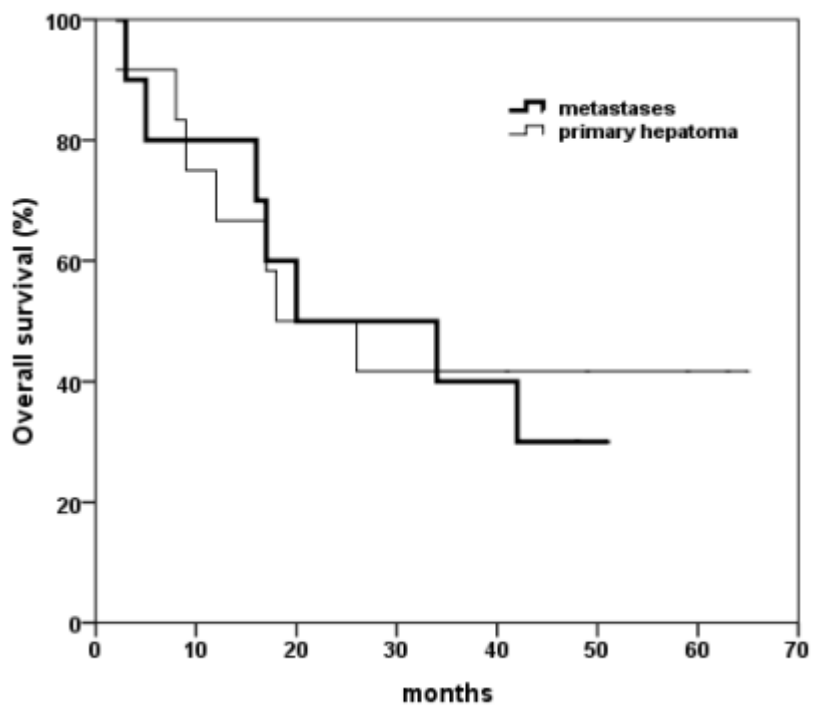
	n	Entity	Resection type	Survival
[12]	17	metastases	10 major, 7 minor	2 y: 95 %
[13]	3	metastases	not specified	2 y: 69 % *
[14]	172	mets (+5 HCC)	86 major, 86 minor	2 y: 80 %, 5 y: 30 %
[15]	12	metastases	4 major, 8 minor	1 y: 80%
[16]	11	mets + HCC	6 major, 5 minor	1 y: 79 %
[17]	101	metastases	56 major, 45 minor	3 y: 43 %, 4 y: 36 %
[11]	63	metastases	44 major, 19 minor	1 y: 92 %, 2 y: 67 %, 3 y: 47 %
[18]	3	metastases	1 major, 2 minor	1 y: 67 %
[19]	22	HCC	2 major, 20 minor	1 y: 43 %, 3 y: 7 %, 4 y: 7 %
[20]	35	mets (+2 HCC)	7 major, 28 minor	1 y: 84 %, 2 y: 70 %, 3 y: 43 %
[21]	36	mets + HCC	26 major, 10 minor	1 y: 90 %, 2 y: 65 %, 3 y: 40 %
[22]	53	HCC	9 major, 44 minor	1 y: 87 %, 2 y: 83 %, 3 y: 80 %, 4 y: 68 %, 5 y: 55 %
[23]	19	metastases	9 major, 10 minor	3 y: 47 %
[24]	29	HCC	2 major, 27 minor	1 y: 92 %, 2 y: 80 %, 3 y: 73 %, 4 y: 61 %, 5 y: 47 % *
[25]	55	metastases	8 major, 47 minor	1 y: 80 %, 3 y: 45 %
Berlin experience	22	mets + HCC	8 major, 14 minor	1 y: 77 %, 2 y: 50 %, 3 y: 41%

Table 4: Summary of publications including procedures combining RFA and resection (y years, * whole series). Numbering: see reference list

Legend to the figure:

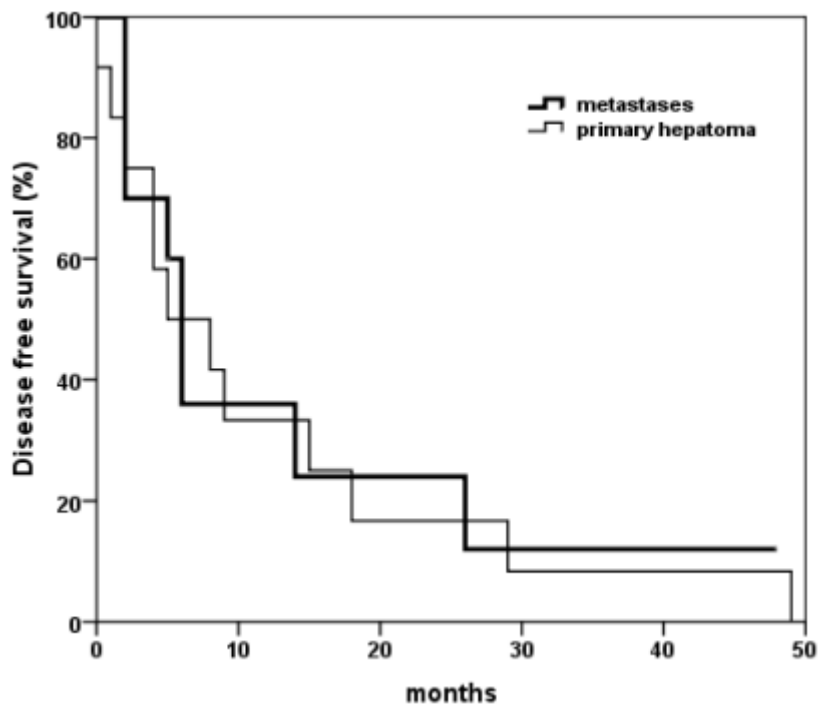
Figure 1: Kaplan Meier estimations of overall survival (fig. 1a) and disease free survival (fig. 1b), separately displayed for patients with primary liver tumors and metastases (log-rank test: $p=0.815$ [fig. 1a], $p=0.841$ [fig. 1b])

ACCEPTED MANUSCRIPT



ACCEPTED MANUSCRIPT

ACCEPTED MANUSCRIPT



ACCEPTED MANUSCRIPT

ACCEPTED MANUSCRIPT