



HAL
open science

Current Strategies for Knee Cartilage Repair

Nick Kalson, Panagiotis Gikas, Timothy Briggs

► **To cite this version:**

Nick Kalson, Panagiotis Gikas, Timothy Briggs. Current Strategies for Knee Cartilage Repair. International Journal of Clinical Practice, 2010, 64 (10), pp.1444. 10.1111/j.1742-1241.2010.02420.x . hal-00566327

HAL Id: hal-00566327

<https://hal.science/hal-00566327>

Submitted on 16 Feb 2011

HAL is a multi-disciplinary open access archive for the deposit and dissemination of scientific research documents, whether they are published or not. The documents may come from teaching and research institutions in France or abroad, or from public or private research centers.

L'archive ouverte pluridisciplinaire **HAL**, est destinée au dépôt et à la diffusion de documents scientifiques de niveau recherche, publiés ou non, émanant des établissements d'enseignement et de recherche français ou étrangers, des laboratoires publics ou privés.



Current Strategies for Knee Cartilage Repair

Journal:	<i>International Journal of Clinical Practice</i>
Manuscript ID:	IJCP-01-10-0050.R1
Manuscript Type:	Non-Systematic Review
Date Submitted by the Author:	08-Mar-2010
Complete List of Authors:	Kalson, Nick; Royal National Orthopaedic Hospital Gikas, Panagiotis; Royal National Orthopaedic Hospital, Bone Tumour Service Briggs, Timothy; Royal National Orthopaedic Hospital, Bone Tumour Service
Specialty area:	



Current Strategies for Knee Cartilage Repair

Nicholas S. Kalson, Panagiotis D. Gikas*, Timothy W. R. Briggs

Bone Tumour Service, Royal National Orthopaedic Hospital, Brockley Hill,
Stanmore, Middlesex, UK. HA7 4LP.

* Author for correspondence. Email, pdgikas@doctors.org, Telephone +44
7958342989

Key words: Knee, cartilage, injury, microfracture, autologous chondrocyte
implantation, mosaicplasty

Abstract

Defects in knee articular cartilage can cause pain and disability and present the clinician with an extremely challenging clinical situation. This article describes the most up-to-date surgical techniques that aim to repair and/or regenerate symptomatic focal defects in articular cartilage, which include arthroscopic debridement, microfracture bone marrow stimulation and autologous osteochondral allografting, with an emphasis on autologous chondrocyte implantation (ACI). In the future, refinement of tissue engineering approaches promises to further improve outcome for these patients.

Introduction

Knee articular cartilage (AC) defects have long presented a challenge to physicians. In 1743 the famous English anatomist William Hunter wrote 'an ulcerated cartilage is a trouble-some problem... that, once destroyed, it is not recovered' [1]. Today, more than 250 years later, cartilage damage is still an issue for physicians and patients and there is still no universally accepted and successful treatment approach for damaged AC. However, the result of research into novel surgical therapies developed over the last two decades, described in this article, have the potential to consign this statement to history.

Importance of knee cartilage defects

Articular cartilage lesions are common. In patients undergoing arthroscopic investigation for knee symptoms the incidence of cartilage defects has been found to be 61% [2] and 63% [3] and the prevalence of work- or sport-related articular lesions has been reported at 22% and 50% [4, 5]. Furthermore, in patients with anterior cruciate laxity the incidence of articular pathology is as high as 54% [6]. Although more common with age, these injuries are also frequent in patients less than 55 years old [3, 7], in whom a prosthetic joint replacement, with a limited lifespan, is not recommended. Therefore alternative treatments are required. Focal AC defects are most often traumatic in origin, resulting from a high-load impact or repetitive shear and torsional loads on the superficial zone of articular cartilage [8]. A small proportion of lesions are caused by osteochondritis dessicans (less than 5%)[9]. Focal AC defects are separate from osteoarthritis, a chronic degenerative disease, which has distinct clinical, radiological and arthroscopic findings.

Natural history of knee cartilage defects

1
2
3
4
5
6
7
8
9
10
11
12
13
14
15
16
17
18
19
20
21
22
23
24
25
26
27
28
29
30
31
32
33
34
35
36
37
38
39
40
41
42
43
44
45
46
47
48
49
50
51
52
53
54
55
56
57
58
59
60

Hyaline AC is predominantly composed of a unique extra-cellular matrix (ECM), formed from embryonic mesenchyme in a complex and incompletely understood developmental process [10]. The two principal components of AC are proteoglycans, negatively charged glycosaminoglycan chains that swell and hydrate AC, and collagen type II, a fibrillar collagen that traps the proteoglycans and provides tensile strength. This ECM is specialised to cope with its singular biomechanical environment; to regain a functional joint, cartilage defects would ideally be replaced by tissue of this precise composition.

Injury to some musculoskeletal tissues, such as bone, result in recapitulation of embryonic development processes and regeneration of fully functional tissue identical to the pre-injured tissue. However, there are several barriers to intrinsic articular cartilage repair: 1) It is avascular, meaning that the nutrients required for energetic repair processes and the removal of metabolic waste products are limited by diffusion to/from surrounding tissues. 2) It is relatively acellular, therefore few cells are available to effect repair. These obstacles conspire to limit repair of defects to a fibro-cartilaginous substitute tissue with different molecular composition (more type I collagen, less proteoglycan) and biomechanical behaviour (less proteoglycan and collagen type II, more collagen type I), compared to the original hyaline tissue [11, 12].

Despite this clear pathological response to injury the natural history of untreated AC lesions is not fully understood [13]. Shelbourne et al. (2003) reported a series of patients identified with AC defects discovered at the time of arthroscopic cruciate ligament reconstruction. Patients left with untreated AC lesions had similar subjective patient scores at an average follow up of nine years than control subjects with no AC defects. Interestingly, the authors also noted that a number of patients with significant AC defects have no/mild clinical symptoms [5]. In another treatment intervention trial patients treated only with debridement and no surgical repair procedure showed spontaneous improvement [14]. Therefore, although some lesions will be asymptomatic, AC defects have the potential to manifest as continued joint pain, impaired movement and functional disability, that will need treating in a

1
2
3 carefully selected group of patients. Additionally, it is known that AC defects
4 increase the risk of osteoarthritis, which may require knee replacement [15].
5
6 Therefore, it is desirable to intervene not only to reduce current morbidity but also
7
8 in order to reduce the likelihood of future joint disorder.
9

10 11 12 13 14 15 ***Patient selection and indication for surgery*** 16

17
18 A wide-range of non-specific symptoms may lead clinicians to consider that an AC
19 defect is the source of a patient's pain, including locking, pain at rest, swelling, pain
20 with activity, instability and retropatellar crepitus [16, 17]. Approximately two thirds
21 of patients with chondral defects have associated ligamentous or meniscal pathology
22 and AC damage has been reported in association with 23% of ACL injuries and 54%
23 of knees with chronic anterior cruciate ligament laxity or instability [6]. Focal AC
24 defects are distinct from osteoarthritis, which often involves more widespread
25 cartilage damage and prominent subchondral bony changes, is predominantly a
26 disease of old age, and has a chronic, gradually worsening course.
27
28
29
30
31
32
33
34
35

36
37 Cartilage lesions are graded I-IV according the International Cartilage Repair Society
38 scale [18]. Grade I lesions are nearly normal with only superficial fissures, grade II
39 lesions extend less than 50% of cartilage depth, grade III are severely abnormal
40 lesions extending more than 50% of cartilage depth, but not into the subchondral
41 bone, and grade IV lesions include the subchondral bone.
42
43
44
45
46
47
48

49 Clinical examination is supported by arthroscopic assessment, the gold standard
50 investigation for chondral defects, which allows direct visualisation of the chondral
51 surface. In addition, magnetic resonance imaging (MRI) has a high sensitivity and
52 specificity to detect chondral defects (greater than 95% for grade III lesions [19]).
53 High resolution MRI can provide sufficient information for operative planning, and
54 might in future obviate the need for diagnostic arthroscopy. Most importantly, the
55 commonly occurring asymptomatic AC defect makes it essential that care is taken
56 during clinical examination and investigations to determine that findings correlate
57
58
59
60

1
2
3 with clinical symptoms, therefore ensuring that treatment is not misdirected [5].
4
5 Patient selection and indications for surgery vary according to the treatment type,
6
7 and are considered further below.
8
9

10 11 12 **Current treatment options**

13
14
15
16 Orthopaedic surgeons have developed a wide arsenal of treatment options for
17
18 treating focal knee AC defects [20]. Those most commonly employed today include,
19
20 but are not limited to: 1) arthroscopic debridement, in which loose cartilage is
21
22 trimmed, 2) microfracture, in which bone marrow based repair is stimulated, 3)
23
24 autologous osteochondral grafting, in which bone-cartilage plugs are harvested from
25
26 non-weight bearing joint sites and implanted directly into the defect, and 4)
27
28 autologous chondrocyte implantation, a two-stage procedure involving harvest of
29
30 chondrocytes, growth *in vitro*, then re-implantation.
31
32

33
34 Which treatment is chosen depends on several factors, including size of lesion,
35
36 availability of particular treatments and the age and requirements of the patient.
37
38 Small lesions may be conservatively managed with arthroscopic debridement and
39
40 careful monitoring [14, 21], whereas more extensive lesions require greater
41
42 intervention. The first choice treatment for lesions less than 2.5 cm² is bone marrow
43
44 stimulation by microfracture [8, 22-24]. Larger lesions may be treated by
45
46 mosaicplasty[17], this technique is limited by the availability of donor tissue, or by
47
48 autologous chondrocyte transplantation, which is becoming more widely available
49
50 [8]. Other treatments, such as abrasion chondroplasty and the use of carbon fibre
51
52 pads, are either less widely practised, or have been superseded, and are therefore
53
54 not discussed.
55
56
57

58 **Arthroscopic debridement**

59
60

1
2
3 Small defects in which there are loose, overhanging flaps of cartilage may initially be
4 treated by arthroscopic debridement [14, 21]. These lesions often present with
5 locking. However, larger, more complex defects, perhaps with no obvious loose
6 body, require more complex procedures, which either stimulate repair tissue
7 (microfracture) or replace damaged cartilage (osteochondral transplantation or
8 autologous chondrocyte implantation).
9
10
11
12
13
14

Bone marrow stimulation by microfracture

15
16
17
18
19
20 Bone marrow stimulation by microfracture is widely considered the first choice
21 treatment for small lesions (less than 2.5 cm²) [8, 22-24] (Figure 3). Bone marrow
22 stimulation techniques aim to induce bleeding for the subchondral bone followed by
23 the formation of a fibrin clot, migration and recruitment of bone marrow derived
24 stem cells and the formation of a fibrocartilaginous repair tissue that covers full-
25 thickness chondral lesions. Bony drilling into the defect, first described by Pridie in
26 1959 [25], was prevalent until the advent of microfracture in the 1990s [26]. Pridie
27 drilling uses a hand-driven or motorised drill to penetrate the subchondral plate. This
28 is thought to cause heat-related tissue damage, whereas microfracture uses a
29 gentler arthroscopic awl, which does not generate significant heat [27, 28].
30 Microfracture is now more popular than other bone marrow stimulation techniques
31 (drilling and arthroscopic abrasion arthroplasty [29]).
32
33
34
35
36
37
38
39
40
41
42
43
44

45 Microfracture has demonstrated good or excellent results in 60-80% of patients [27,
46 30, 31]. There is some evidence that MF works best in patients under 40 years old
47 that might have intrinsically superior healing responses to those in older patients
48 [32]. It benefits from the low-morbidity of an arthroscopic procedure with a
49 relatively quick recovery period and low complication rate [30, 33].
50
51
52
53
54
55

56 Treatable lesions are 1-2.5 cm² large, and well shouldered with protected edges [8].
57 Microfracture involves debridement of unstable cartilage to bone level to form a
58 stable rim of healthy cartilage around the defect. Specially designed awls are then
59 used to make multiple holes 2-4 mm deep and 3-4 mm apart in the subchondral
60

1
2
3 bone [34]. Rehabilitation includes continuous passive motion and partial weight
4 bearing for 6-8 weeks. Interestingly, non-human primate models of microfracture
5 show repair tissue to be immature after six weeks, suggesting a longer rehabilitation
6 period might be necessary [35].
7
8
9

10
11
12 The procedure may be less-well suited to the patello-femoral joint or the tibia, which
13 in one study showed deterioration after 18 months following microfracture [24], or
14 to lesions larger than 4 cm², which have been reported to fair better after treatment
15 with autologous chondrocyte transplantation [22, 23]. Complications include
16 degenerative changes in the subchondral area, such as cysts, osseous overgrowth
17 and intra-lesional osteophytes in approximately 33% of cases [24, 27]. The
18 significance of these findings has not been proven, but changes to the subchondral
19 plate likely underlie failed MF treatment [33].
20
21
22
23
24
25
26
27
28
29

30 Microfracture is not a curative treatment, but it can provide relief for a number of
31 years. However, doubts remain over the durability of the repair tissue produced,
32 which is fibrocartilagenous and has inferior biomechanical properties compared to
33 hyaline tissue. Mithoefer et al. (2009) conducted a systematic review examining the
34 clinical efficacy of MF for knee AD defects. They identified six randomised control
35 trails, which all showed improved knee function during the first 24 months post-
36 operation, but the longevity of the initial improvement was not consistent between
37 studies [36]. Furthermore, a recent report of microfracture used to treat
38 professional athletes concluded that 'from a strict scientific stand point an untreated
39 control group would be valuable to demonstrate that microfracture does not just
40 mirror the natural course of healing' [37]. There are currently no published studies
41 comparing MF (or any other intervention) to an untreated control group. This should
42 be an important future research goal.
43
44
45
46
47
48
49
50
51
52
53
54
55

56 ***Autologous osteochondral grafting / mosaicplasty***

57
58
59

60 Autologous osteochondral allografting, also known as mosaicplasty, most commonly
involves transplantation of small (less than 1cm²) cylindrical cartilage plugs

1
2
3 harvested from non-weight bearing areas such as the lateral femoral condyle or the
4 trochlea, directly into the defect in a one-stage procedure [17] (Figure 2). The use of
5 different size plugs allows defect filling of more than 90%, and the graft needs to be
6 perpendicular and flush to the surface to prevent catching with knee motion [17].
7 This technique has the advantage of directly implanting hyaline cartilage onto the
8 defect. The procedure may be done open or arthroscopically, and is not
9 recommended in individuals over 50 years old [17]. Good to excellent results have
10 been reported in 85-95% of treated defects of the femoral condyles, tibial surfaces
11 and patellar/trochlear lesions [38-43].
12
13
14
15
16
17
18
19
20
21

22 It is important to note that repair using autologous tissue technique is most suited to
23 small (less than 4 cm²) lesions, being limited by the availability of donor tissue and by
24 potential donor-site morbidity [17, 44]. Larger defects may be filled with allogeneous
25 cartilage tissue from a cadaveric donor, although this risks immunologic rejection
26 and disease transmission from donor to recipient. Therefore osteochondral
27 allografts are generally reserved for uncontained (not well-defined) lesions greater
28 than 4 cm² where there is significant osseous damage [8].
29
30
31
32
33
34
35
36
37
38

39 ***Autologous chondrocyte implantation***

40
41 By 2003 more than 15,000 patients have undergone ACI worldwide [45] and it is now
42 widely considered the frontline treatment for defects larger than 2 cm² [8] (Figure
43 4). The procedure is recommended for ICRS grade III/IV lesions of the femoral
44 condyle or trochlear region, but more recently has been used with success for
45 patellar lesions. The optimum candidate is a highly motivated patient, less than 50-
46 55 years old, with a high functional demand and high potential for compliance with
47 the long-term rehabilitation required (reviewed in [8]).
48
49
50
51
52
53
54
55

56 **Indications**

57
58 The size of a lesion best suited to ACI is still debated. Conventional thinking is that
59 lesions less than 2-2.5 cm² may be treated initially with microfracture, and that ACI
60 may be used in patients that continue to have pain after microfracture. However,

1
2
3 although microfracture was considered a 'non bridge-burning procedure' [33], a
4 recent study suggests that previous microfracture reduces the chances of successful
5 ACI by 30% [33]. Bone involvement is not a contraindication, but when bone
6 involvement is deeper than 6 – 8 mm autologous bone grafting should be
7 undertaken (Petersen 2003). Reciprocal (kissing) lesions are generally a
8 contraindication.
9
10
11
12
13
14

15 16 17 **Pre-operative assessment**

18 In pre-operative planning weight loss is central, and a BMI less than 30 kg/m² is
19 recommended. Weight loss has been associated with improved activities of daily
20 living scores and SF-36 Physical Component Summary Scores following cartilage
21 repair procedures [27]. Clinical assessment should include knee alignment and
22 associated injuries. Malalignment should be corrected by osteotomy, and knee
23 ligaments reconstructed. Meniscal lesions require repair or resection at initial
24 arthroscopy. Radiographic assessment includes postero-anterior weight bearing
25 views to assess for medial/lateral compartment narrowing, bilateral Merchant views
26 to assess patellar facet wear, subluxation and tilt, and bilateral long-limb standing
27 radiographs to examine the leg axis and potential sites of increased load to the
28 repair site. Magnetic resonance imaging has a high sensitivity and specificity (over
29 90%) for detecting AC defects, but only lesions that correlate with clinical symptoms
30 should be treated.
31
32
33
34
35
36
37
38
39
40
41
42
43
44

45 **Surgical technique**

46 Two separate procedures are required for ACI. First, arthroscopic assessment is
47 performed after physical examination and radiographic studies. If areas of ICRS
48 grade III/IV are found, the lesions are measured. If the reciprocal surface is not
49 severely damaged and the patient is an appropriate candidate for chondrocyte
50 implantation a biopsy is taken. Harvest is from a non-weight bearing area of articular
51 cartilage, such as the medial edge of the trochlear groove. Approximately 200-300
52 mg of tissue are taken, which corresponds to approximately 300,000 cells. It is
53 important to remove tissue from a healthy area in order that 'normal' chondrocytes
54 are collected. Chondrocytes are cultured for 4-6 weeks in a laboratory compliant
55
56
57
58
59
60

1
2
3
4
5
6
7
8
9
10
11
12
13
14
15
16
17
18
19
20
21
22
23
24
25
26
27
28
29
30
31
32
33
34
35
36
37
38
39
40
41
42
43
44
45
46
47
48
49
50
51
52
53
54
55
56
57
58
59
60

with Good Manufacturing Practice guidelines. It is important that chondrocytes are not cultured longer than this, or phenotypic changes emerge. Either a chondrocyte suspension, or chondrocytes seeded on a collagen-based scaffold (matrix assisted autologous chondrocyte implantation – MACI) is then implanted in a second procedure. The defect is prepared by debriding the edges to normal articular cartilage. Damage to the underlying chondral bone is avoided to prevent bleeding into the defect. In ACI, a periosteal graft, which may be harvested from the proximal tibia, is used to cover the implanted cells [46], or chondrocytes can be implanted beneath a collagen membrane (ACI-C). In the MACI technique, cells are seeded on a collagen type I/III scaffold at a precise concentration (1 million cells per cm²). The membrane is placed directly into the defect and secured with fibrin glue, eliminating the need for suturing to surrounding cartilage and use of a cover, which can damage surrounding healthy cartilage.

Rehabilitation

Rehabilitation protocols vary widely, but always involve a long and cautious process, requiring high motivation and patient compliance. When planning rehabilitation it is important to remember that a biological healing process is occurring, which involves cell proliferation (0-6 weeks), matrix production (first 6 months), and matrix remodeling (6 months onward). Most protocols require reduced weight bearing for 10 weeks, aiming to avoid impact loading and twisting or shearing forces which might damage the repair tissue. One protocol uses a plaster of Paris for week one, then toe-touch weight bearing with flexion-extension exercises at weeks two-six [47]. From six weeks partial weight bearing is used, and from ten weeks full weight bearing is allowed. Other regimes use passive movement from day one onwards, which aims to stimulate implanted cells via mechanical signals as early as possible [48]. It ought to be noted that the ideal mobilization protocol aims to optimize the repair process, and it is tailored to the individual case. Well-contained lesions are protected by surrounding cartilage and may begin weight bearing at 4 weeks, whereas large poorly contained lesions should not bear weight fully until 8-12 weeks post-surgery [8].

Post-operative assessment

Arthroscopy remains the gold standard for post-operative evaluation, often carried out at one year post-operation, and allows visualisation of the repair and biopsy for histological assessment. Probe indentation stiffness can also be measured, and has demonstrated up to 80% stiffness compared with native articular cartilage [49]. Gikas et al. (2009) demonstrated progressive development from fibrocartilage to hyaline cartilage with increasing time from operation in patients having undergone ACI/MACI. The appearances of the repair tissue can also be investigated with MRI [50]. In one series ACI provided better defect filling than microfracture [51]. More sophisticated MRI techniques use intravenously administered gadolinium, which can penetrate cartilage, and T1 imaging can estimate glycosaminoglycan content, and T2 mapping allows evaluation of collagen content (for review see [52]).

Clinical results of ACI

Clinical results for ACI have been encouraging. Numerous case-series report positive effectiveness of ACI for treatment of knee AC defects, with follow-up now available more than 10 years post-procedure [53-56]. Furthermore, there are randomised trials (RCT) comparing ACI to microfracture [20, 23, 57] and to mosaicplasty [58], and these RCTs have been reviewed in an attempt to determine an optimum treatment for focal AC defects.

A Cochrane Collaboration meta-analysis identified four randomised control trials comparing ACI with microfracture or mosaicplasty that met their eligibility criteria [23, 58-61]. One of these trials reported superior outcome for ACI versus mosaicplasty [58], whilst the other trials did not find a superior treatment. In one study one year after treatment ACI was associated with a tissue regenerate that was superior to that of microfracture [23]. Overall, they could not find evidence to support ACI over microfracture or mosaicplasty, and concluded that further randomised trials are required.

Since publication of the Cochrane review (2006) [61], further RCTs have been published. Knutsen et al. (2007) reported no difference in clinical or radiographic

1
2
3 outcome measures at 5-year follow up of patients treated with either microfracture
4 or ACI [20]. Saris et al. (2008) report similar short-term clinical outcome was for ACI
5 and microfracture groups [62]. Similarly, Van Assche et al. (2008) reported on 67
6 patients randomised to microfracture or ACI. Follow-up at two years did not show
7 differences in functional outcome [63].
8
9

10
11
12
13
14 Recently, Magnussen et al. (2008) reviewed five randomised control trials comparing
15 ACI/MACI, osteochondral autograft transfer and microfracture. All treatments
16 improved clinical outcome measures compared to pre-operative assessment, but no
17 technique consistently had superior results, and no study used non-operative control
18 groups [64]. The authors' recommendation is that a large prospective trial be
19 conducted and that non-operated controls be included.
20
21
22
23
24
25
26
27

28 These trials are consistent in reporting clinical improvement following ACI.
29 Furthermore, economic analysis has demonstrated cost effectiveness of ACI [65].
30 There is emerging evidence that the repair tissue produced in ACI is more
31 hyaline-like and more durable than that following microfracture. [20, 62]. However,
32 there is currently no firm evidence that ACI provides improved patient outcomes
33 compared to either microfracture or mosaicplasty. Furthermore, the quality of trial
34 methodology investigating knee AC defects could be improved by adequately
35 describing randomisation procedures, including untreated control groups, use of
36 validated outcome measures and the use of an independent investigator or outcome
37 assessment [61, 66].
38
39
40
41
42
43
44
45
46
47
48

49 **Matrix-assisted/induced autologous chondrocyte implantation**

50 Autologous chondrocyte implantation is considered to be the first widely available
51 and commercially successful cell-based therapeutic intervention. Undoubtedly, in
52 the future more cellular therapies will become available to treat a wide variety of
53 disorders. The pioneering position of ACI at the forefront of medical technology has
54 understandably led to close scrutiny from medical regulatory authorities. Wood et al.
55 (2006) reported that the rate of adverse reactions in patients treated with Carticel,
56 an autologous chondrocyte implant system, was 3.8% (497/7500). Adverse reactions
57
58
59
60

1
2
3 included graft failure (25%), delamination (22%) and tissue hypertrophy (18%) [67]
4
5 and most often occurs within 6 months after surgery in approximately 25% cases and
6
7 can require surgery [54].
8
9

10
11 It is thought that tissue hypertrophy is related to the use of a periosteal graft to
12
13 cover the implanted chondrocytes, which in addition is technically difficult to harvest
14
15 and can cause joint stiffness and arthrofibrosis. The technical advantages of scaffold-
16
17 based techniques (e.g. MACI), which remove the need for an arthrotomy and the risk
18
19 of periosteal hypertrophy, have led to some surgeons preferring scaffold techniques
20
21 [54]. Therefore, there has been evolution towards implants in which cells are seeded
22
23 in a 3D matrix that does not require periosteal cover. Since the late 1990s, when the
24
25 European Drug Agency licensed the use of collagen and hyaluronan based scaffolds
26
27 for implantation with cultured autologous chondrocytes, several different matrix
28
29 based implants have been devised, including Matrix induced autologous
30
31 chondrocyte implantation (MACI, Verigen Transplantation Service, Copenhagen,
32
33 Denmark), Hyalograft C (Fidia Advanced Biopolymers Laboratories, Padova, Italy),
34
35 and CaReS (Ars Arthro, Esslingen, Germany). Mid-long term follow-up is now
36
37 becoming available [68], and suggests that MACI gives similar or slightly improved
38
39 clinical outcome compared to ACI [47] or microfracture [56]. Biopsy results have also
40
41 been encouraging, showing the production of hyaline cartilage [47, 50].
42
43 Nevertheless, randomised trials are required to investigate these new procedures
44
45 [69].
46

47
48 Histological analysis of repair tissue following ACI/MACI reveals that approximately
49
50 50% of patients have hyaline-like or mixed hyaline and fibrocartilage tissue [20, 50].
51
52 Although this is certainly improved compared to microfracture [62], why some
53
54 chondrocyte implants produce hyaline tissue and others fibro cartilaginous tissue is
55
56 not known. This may be due to specific patient, cell-culture or knee injury factors,
57
58 and investigation into predicting which patients respond best will be important in
59
60 the future. Saris et al. (2008) have begun to investigate manipulation of histological
outcome by characterising and selecting chondrocytes for implantation by gene
expression profile analysis for a number of cartilage marker genes, such as collagen

1
2
3 type II. They found that superior structural tissue was formed in the ACI group,
4 which used characterised chondrocytes, compared with microfracture. This is a
5 promising approach, but further study comparing un-characterised cultured
6 chondrocytes is required to determine whether cell-selection results in improved
7 histological outcome [62].
8
9
10
11
12

13 14 15 16 17 ***Future perspectives***

18
19
20 Treatment for articular cartilage lesions has pioneered tissue-engineering
21 techniques, illuminating a path that other therapeutic interventions will undoubtedly
22 tread. Improvement in clinical outcome has been demonstrated following ACI
23 treatment, and there are clear routes forward which involve the development of
24 matrix-based implants. Currently, minimally invasive procedures such as
25 microfracture are probably best for small defects (less than 2.5 cm²), and ACI for
26 larger lesions. However, it has been said that no treatment has demonstrated long-
27 term efficacy [16, 67]. The evidence for ACI providing superior outcomes compared
28 with treatment by microfracture bone-marrow stimulation is not yet well established
29 [61, 66] and improvement in the quality of randomised control trials that are
30 undertaken is required [61, 66].
31
32
33
34
35
36
37
38
39
40
41

42
43 Chondrocyte implantation holds great promise for future development. The
44 refinement of tissue engineering techniques will include evaluation of different cell-
45 scaffold combinations, genetic manipulation of implanted cells, and use of
46 alternative cell sources such as mesenchymal stem cells. In the future, therapies
47 might incorporate mechanical stimulation of the tissue *ex vivo* prior to implantation
48 (NeoCart), the use of allogenic chondrocyte transplantation (DeNovo ET), use
49 hydrogel or hyaluronic acid-based scaffolds [70]. There is also a push to develop
50 single-stage arthroscopic cell-based treatments that use allogeneous cells, or
51 autologous cells of non-cartilage origin (e.g. mesenchymal stem cells) cultured and
52 differentiated *in vitro* prior to implantation. Although none of these procedures yet
53
54
55
56
57
58
59
60

1
2
3 have regulatory approval, the scope for future development of chondrocyte
4
5 implantation techniques will, hopefully, result in superior treatments.
6
7
8
9

10 **Key points**

11 Articular cartilage defects are a common injury, particularly in the young and active

12 They still present a challenging problem with no universally accepted treatment

13 Whether to treat must be directed primarily by clinical information, not solely by the
14 presence of a lesion

15 Microfracture is a successful temporary repair procedure, recommended for small
16 lesions, which produces fibrous tissue and can provide relief for several years

17 Autologous chondrocyte implantation offers the possibility of regeneration with a
18 hyaline tissue, and is the recommended front-line treatment for larger defects

19 Future research will refine tissue engineering techniques to improve outcome with
20 cell-scaffold treatments
21
22
23
24
25
26
27
28
29
30
31
32
33
34
35
36
37
38

39 **Review criteria**

40 Articles published in English were identified by searching PubMed in December 2009
41 using the following search terms: 'cartilage and repair', 'cartilage and regeneration',
42 'cartilage and articular chondrocyte implantation', 'cartilage and osteochondral
43 autograft', 'cartilage and microfracture', and 'cartilage and periosteal
44 transplantation'.
45
46
47
48
49
50
51
52
53
54
55
56
57
58
59
60

Figure Legend

Figure 1. Schematic of a focal knee cartilage defect. (A) A fibrillated cartilage lesion. (B) Debridement of the defect to healthy cartilage with smooth vertical borders. Reproduced with permission from [71].

Figure 2. Arthroscopy mosaicplasty. (A) Miniarthrotomy mosaicplasty on the medial femoral condyle for the treatment of a chondral defect. Three osteochondral plugs can be seen implanted in the defect. (B) Mosaicplasty on the medial talar dome to treat an osteochondritis dessicans defect. Images kindly provided by Laszlo Hangody.

Figure 3. Bone marrow stimulation by microfracture. (A) Small holes 3-4 mm apart are created in the bone of the defect. Bleeding is induced, which results in healing by production of fibrocartilagenous tissue. (B) Femoral condyle defect that has been filled with newly formed fibrocartilagenous tissue. Reproduced with permission from Lutzner et al. (2009) [72].

Figure 4. Autologous chondrocyte implantation. (A) A focal cartilage defect that has been debrided to healthy cartilage. (B) Autologous cultured chondrocytes have been implanted into the defect, over which a periosteal flap will be sutured. Reproduced with permission from Gikas et al. (2009) [47].

References

1. Hunter W. On the structure and diseases of articulating cartilage. *Phil Trans Royal Soc.* 1743;42B:514-21.
2. Hjelle K, Solheim E, Strand T et al. Articular cartilage defects in 1,000 knee arthroscopies. *Arthroscopy : the journal of arthroscopic & related surgery : official publication of the Arthroscopy Association of North America and the International Arthroscopy Association.* 2002 Sep 1;18(7):730-4.
3. Curl WW, Krome J, Gordon ES et al. Cartilage injuries: a review of 31,516 knee arthroscopies. *Arthroscopy : the journal of arthroscopic & related surgery : official publication of the Arthroscopy Association of North America and the International Arthroscopy Association.* 1997 Aug 1;13(4):456-60.
4. Piasecki DP, Spindler KP, Warren TA et al. Intraarticular injuries associated with anterior cruciate ligament tear: findings at ligament reconstruction in high school and recreational athletes. An analysis of sex-based differences. *Am J Sports Med.* 2003 Jul-Aug;31(4):601-5.
5. Shelbourne KD, Jari S, Gray T. Outcome of untreated traumatic articular cartilage defects of the knee: a natural history study. *The Journal of bone and joint surgery American volume.* 2003 Jan 1;85-A Suppl 2:8-16.
6. Indelicato PA, Bittar ES. A perspective of lesions associated with ACL insufficiency of the knee. A review of 100 cases. *Clin Orthop Relat Res.* 1985 Sep 1(198):77-80.
7. Noyes FR, Bassett RW, Grood ES, Butler DL. Arthroscopy in acute traumatic hemarthrosis of the knee. Incidence of anterior cruciate tears and other injuries. *The Journal of bone and joint surgery American volume.* 1980 Jul 1;62(5):687-95, 757.
8. Jones DG, Peterson L. Autologous chondrocyte implantation. *The Journal of bone and joint surgery American volume.* 2006 Nov 1;88(11):2502-20.
9. Widuchowski W, Widuchowski J, Trzaska T. Articular cartilage defects: study of 25,124 knee arthroscopies. *Knee.* 2007 Jun 1;14(3):177-82.
10. Morrison EH, Ferguson MW, Bayliss MT, Archer CW. The development of articular cartilage: I. The spatial and temporal patterns of collagen types. *J Anat.* 1996 Aug;189 (Pt 1):9-22.
11. Furukawa T, Eyre DR, Koide S, Glimcher MJ. Biochemical studies on repair cartilage resurfacing experimental defects in the rabbit knee. *J Bone Joint Surg Am.* 1980 Jan;62(1):79-89.
12. Cheung HS, Lynch KL, Johnson RP, Brewer BJ. In vitro synthesis of tissue-specific type II collagen by healing cartilage. I. Short-term repair of cartilage by mature rabbits. *Arthritis Rheum.* 1980 Feb;23(2):211-9.
13. Widuchowski W, Lukasik P, Kwiatkowski G et al. Isolated full thickness chondral injuries. Prevalance and outcome of treatment. A retrospective study of 5233 knee arthroscopies. *Acta chirurgiae orthopaedicae et traumatologiae Cechoslovaca.* 2008 Oct 1;75(5):382-6.

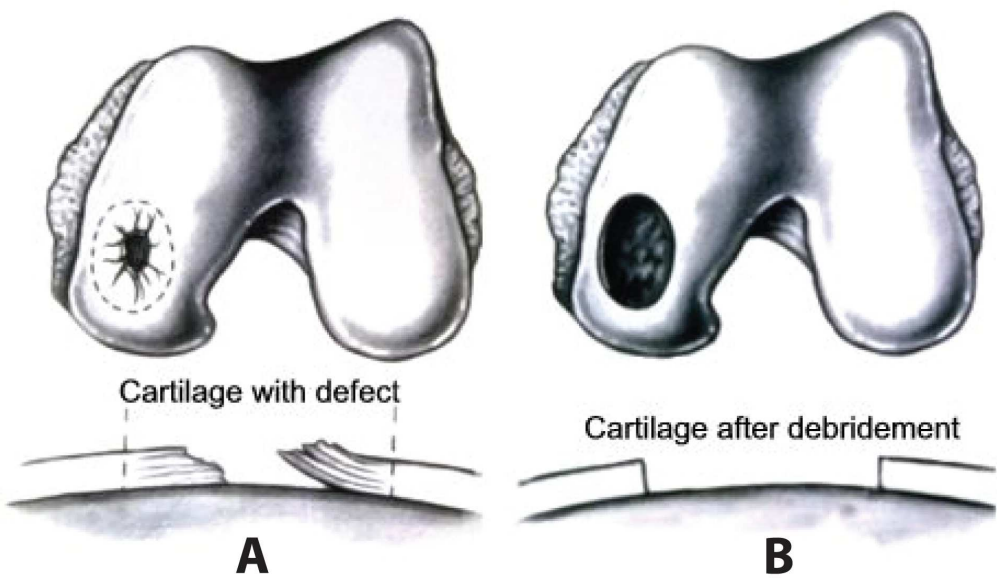
- 1
 - 2
 - 3
 - 4
 - 5
 - 6
 - 7
 - 8
 - 9
 - 10
 - 11
 - 12
 - 13
 - 14
 - 15
 - 16
 - 17
 - 18
 - 19
 - 20
 - 21
 - 22
 - 23
 - 24
 - 25
 - 26
 - 27
 - 28
 - 29
 - 30
 - 31
 - 32
 - 33
 - 34
 - 35
 - 36
 - 37
 - 38
 - 39
 - 40
 - 41
 - 42
 - 43
 - 44
 - 45
 - 46
 - 47
 - 48
 - 49
 - 50
 - 51
 - 52
 - 53
 - 54
 - 55
 - 56
 - 57
 - 58
 - 59
 - 60
14. Dozin B, Malpeli M, Cancedda R et al. Comparative evaluation of autologous chondrocyte implantation and mosaicplasty: a multicentered randomized clinical trial. *Clin J Sport Med*. 2005 Jul;15(4):220-6.
15. Gelber AC, Hochberg MC, Mead LA et al. Joint injury in young adults and risk for subsequent knee and hip osteoarthritis. *Ann Intern Med*. 2000 Sep 5;133(5):321-8.
16. Ochi M, Adachi N, Nobuto H et al. Articular cartilage repair using tissue engineering technique--novel approach with minimally invasive procedure. *Artif Organs*. 2004 Jan;28(1):28-32.
17. Hangody L, Rathonyi GK, Duska Z et al. Autologous osteochondral mosaicplasty. Surgical technique. *J Bone Joint Surg Am*. 2004 Mar;86-A Suppl 1:65-72.
18. International Cartilage Repair Society. Cartilage Injury Evaluation Package. 2000. Accessed 01 Jan 2010. Available from: www.cartilage.org/_files/contentmanagement/ICRS_evaluation.pdf
19. Palosaari K, Ojala R, Blanco-Sequeiros R, Tervonen O. Fat suppression gradient-echo magnetic resonance imaging of experimental articular cartilage lesions: comparison between phase-contrast method at 0.23T and chemical shift selective method at 1.5T. *J Magn Reson Imaging*. 2003 Aug;18(2):225-31.
20. Knutsen G, Drogset JO, Engebretsen L et al. A randomized trial comparing autologous chondrocyte implantation with microfracture. Findings at five years. *J Bone Joint Surg Am*. 2007 Oct;89(10):2105-12.
21. Levy AS, Lohnes J, Sculley S et al. Chondral delamination of the knee in soccer players. *Am J Sports Med*. 1996 Sep-Oct;24(5):634-9.
22. Bekkers JE, Inklaar M, Saris DB. Treatment selection in articular cartilage lesions of the knee: a systematic review. *Am J Sports Med*. 2009 Nov;37 Suppl 1:148S-55S.
23. Knutsen G, Engebretsen L, Ludvigsen TC et al. Autologous chondrocyte implantation compared with microfracture in the knee. A randomized trial. *J Bone Joint Surg Am*. 2004 Mar;86-A(3):455-64.
24. Kreuz PC, Steinwachs MR, Erggelet C et al. Results after microfracture of full-thickness chondral defects in different compartments in the knee. *Osteoarthritis Cartilage*. 2006 Nov;14(11):1119-25.
25. Pridie K. A method of resurfacing osteoarthritic knee joints. *J Bone Joint Surg Am*. 1958;41:2.
26. Blevins FT, Steadman JR, Rodrigo JJ, Silliman J. Treatment of articular cartilage defects in athletes: an analysis of functional outcome and lesion appearance. *Orthopedics*. 1998 Jul;21(7):761-7; discussion 7-8.
27. Mithoefer K, Williams RJ, 3rd, Warren RF et al. The microfracture technique for the treatment of articular cartilage lesions in the knee. A prospective cohort study. *J Bone Joint Surg Am*. 2005 Sep;87(9):1911-20.
28. Gill TJ, Asnis PD, Berkson EM. The treatment of articular cartilage defects using the microfracture technique. *J Orthop Sports Phys Ther*. 2006 Oct;36(10):728-38.
29. Johnson LL. Arthroscopic abrasion arthroplasty: a review. *Clin Orthop Relat Res*. 2001 Oct(391 Suppl):S306-17.

- 1
 - 2
 - 3
 - 4
 - 5
 - 6
 - 7
 - 8
 - 9
 - 10
 - 11
 - 12
 - 13
 - 14
 - 15
 - 16
 - 17
 - 18
 - 19
 - 20
 - 21
 - 22
 - 23
 - 24
 - 25
 - 26
 - 27
 - 28
 - 29
 - 30
 - 31
 - 32
 - 33
 - 34
 - 35
 - 36
 - 37
 - 38
 - 39
 - 40
 - 41
 - 42
 - 43
 - 44
 - 45
 - 46
 - 47
 - 48
 - 49
 - 50
 - 51
 - 52
 - 53
 - 54
 - 55
 - 56
 - 57
 - 58
 - 59
 - 60
30. Steadman JR, Briggs KK, Rodrigo JJ et al. Outcomes of microfracture for traumatic chondral defects of the knee: average 11-year follow-up. *Arthroscopy : the journal of arthroscopic & related surgery : official publication of the Arthroscopy Association of North America and the International Arthroscopy Association*. 2003 Jan 1;19(5):477-84.
31. Asik M, Ciftci F, Sen C et al. The microfracture technique for the treatment of full-thickness articular cartilage lesions of the knee: midterm results. *Arthroscopy*. 2008 Nov;24(11):1214-20.
32. Kreuz PC, Erggelet C, Steinwachs MR et al. Is microfracture of chondral defects in the knee associated with different results in patients aged 40 years or younger? *Arthroscopy*. 2006 Nov;22(11):1180-6.
33. Minas T, Gomoll AH, Rosenberger R et al. Increased failure rate of autologous chondrocyte implantation after previous treatment with marrow stimulation techniques. *Am J Sports Med*. 2009 May;37(5):902-8.
34. Steadman JR, Rodkey WG, Rodrigo JJ. Microfracture: surgical technique and rehabilitation to treat chondral defects. *Clin Orthop Relat Res*. 2001 Oct(391 Suppl):S362-9.
35. Gill TJ, McCulloch PC, Glasson SS et al. Chondral defect repair after the microfracture procedure: a nonhuman primate model. *Am J Sports Med*. 2005 May;33(5):680-5.
36. Mithoefer K, McAdams T, Williams RJ et al. Clinical efficacy of the microfracture technique for articular cartilage repair in the knee: an evidence-based systematic analysis. *Am J Sports Med*. 2009 Oct;37(10):2053-63.
37. Riyami M, Rolf C. Evaluation of microfracture of traumatic chondral injuries to the knee in professional football and rugby players. *J Orthop Surg Res*. 2009;4:13.
38. Ghazavi MT, Pritzker KP, Davis AM, Gross AE. Fresh osteochondral allografts for post-traumatic osteochondral defects of the knee. *J Bone Joint Surg Br*. 1997 Nov;79(6):1008-13.
39. Szerb I, Hangody L, Duska Z, Kaposi NP. Mosaicplasty: long-term follow-up. *Bull Hosp Jt Dis*. 2005;63(1-2):54-62.
40. Emmerson BC, Gortz S, Jamali AA et al. Fresh osteochondral allografting in the treatment of osteochondritis dissecans of the femoral condyle. *Am J Sports Med*. 2007 Jun;35(6):907-14.
41. Marcacci M, Kon E, Delcogliano M et al. Arthroscopic autologous osteochondral grafting for cartilage defects of the knee: prospective study results at a minimum 7-year follow-up. *Am J Sports Med*. 2007 Dec;35(12):2014-21.
42. Tetta C, Busacca M, Moio A et al. Knee Osteochondral Autologous Transplantation: Long-term MR findings and clinical correlations. *Eur J Radiol*. 2009 Jun 11.
43. Solheim E, Hegna J, Oyen J et al. Osteochondral autografting (mosaicplasty) in articular cartilage defects in the knee: results at 5 to 9 years. *Knee*. 2010 Jan;17(1):84-7.

- 1
- 2
- 3
- 4 44. Choi YS, Potter HG, Chun TJ. MR imaging of cartilage repair in the knee and
- 5 ankle. *Radiographics* : a review publication of the Radiological Society of
- 6 North America, Inc. 2008 Jan 1;28(4):1043-59.
- 7 45. Minas T. Autologous chondrocyte implantation in the arthritic knee.
- 8 *Orthopedics*. 2003 Sep;26(9):945-7.
- 9 46. Brittberg M, Lindahl A, Nilsson A et al. Treatment of deep cartilage defects in
- 10 the knee with autologous chondrocyte transplantation. *N Engl J Med*. 1994
- 11 Oct 6;331(14):889-95.
- 12 47. Gikas PD, Bayliss L, Bentley G, Briggs TWR. An overview of autologous
- 13 chondrocyte implantation. *The Journal of bone and joint surgery British*
- 14 *volume*. 2009 Aug 1;91(8):997-1006.
- 15 48. ACTIVE Trial. Accessed 03 Jan 2010. Available from:
- 16 http://www.activetrial.org.uk/ACTIVESite/Active%20protocol3.6_Apr08.pdf
- 17 49. Vasara AI, Nieminen MT, Jurvelin JS et al. Indentation stiffness of repair tissue
- 18 after autologous chondrocyte transplantation. *Clin Orthop Relat Res*. 2005
- 19 Apr(433):233-42.
- 20 50. Gikas PD, Morris T, Carrington R et al. A correlation between the timing of
- 21 biopsy after autologous chondrocyte implantation and the histological
- 22 appearance. *The Journal of bone and joint surgery British volume*. 2009 Sep
- 23 1;91(9):1172-7.
- 24 51. Brown WE, Potter HG, Marx RG et al. Magnetic resonance imaging
- 25 appearance of cartilage repair in the knee. *Clin Orthop Relat Res*. 2004
- 26 May(422):214-23.
- 27 52. Trattinig S, Domayer S, Welsch GW et al. MR imaging of cartilage and its
- 28 repair in the knee--a review. *European radiology*. 2009 Jul 1;19(7):1582-94.
- 29 53. Peterson L, Brittberg M, Kiviranta I et al. Autologous chondrocyte
- 30 transplantation. Biomechanics and long-term durability. *Am J Sports Med*.
- 31 2002 Jan-Feb;30(1):2-12.
- 32 54. Kon E, Delcogliano M, Filardo G et al. Second generation issues in cartilage
- 33 repair. *Sports medicine and arthroscopy review*. 2008 Dec 1;16(4):221-9.
- 34 55. Mandelbaum B, Browne JE, Fu F et al. Treatment outcomes of autologous
- 35 chondrocyte implantation for full-thickness articular cartilage defects of the
- 36 trochlea. *Am J Sports Med*. 2007 Jun;35(6):915-21.
- 37 56. Kon E, Gobbi A, Filardo G et al. Arthroscopic second-generation autologous
- 38 chondrocyte implantation compared with microfracture for chondral lesions
- 39 of the knee: prospective nonrandomized study at 5 years. *Am J Sports Med*.
- 40 2009 Jan;37(1):33-41.
- 41 57. Cole BJ. A randomized trial comparing autologous chondrocyte implantation
- 42 with microfracture. *J Bone Joint Surg Am*. 2008 May;90(5):1165; author reply
- 43 -6.
- 44 58. Bentley G, Biant LC, Carrington RW et al. A prospective, randomised
- 45 comparison of autologous chondrocyte implantation versus mosaicplasty for
- 46 osteochondral defects in the knee. *J Bone Joint Surg Br*. 2003 Mar;85(2):223-
- 47 30.
- 48 59. Horas U, Pelinkovic D, Herr G et al. Autologous chondrocyte implantation and
- 49 osteochondral cylinder transplantation in cartilage repair of the knee joint. A
- 50
- 51
- 52
- 53
- 54
- 55
- 56
- 57
- 58
- 59
- 60

- 1
2
3
4
5
6
7
8
9
10
11
12
13
14
15
16
17
18
19
20
21
22
23
24
25
26
27
28
29
30
31
32
33
34
35
36
37
38
39
40
41
42
43
44
45
46
47
48
49
50
51
52
53
54
55
56
57
58
59
60
- prospective, comparative trial. *J Bone Joint Surg Am*. 2003 Feb;85-A(2):185-92.
60. Basad E. Treatment of chondral defects with MACI or microfracture. First results of a comparative clinical study. *Orthopädische Praxis*. 2004;40:5.
61. Wasiak J, Clar C, Villanueva E. Autologous cartilage implantation for full thickness articular cartilage defects of the knee. *Cochrane database of systematic reviews (Online)*. 2006 Jan 1;3:CD003323.
62. Saris DB, Vanlauwe J, Victor J et al. Characterized chondrocyte implantation results in better structural repair when treating symptomatic cartilage defects of the knee in a randomized controlled trial versus microfracture. *Am J Sports Med*. 2008 Feb;36(2):235-46.
63. Van Assche D, Staes F, Van Caspel D et al. Autologous chondrocyte implantation versus microfracture for knee cartilage injury: a prospective randomized trial, with 2-year follow-up. *Knee Surg Sports Traumatol Arthrosc*. 2009 Oct 10.
64. Magnussen RA, Dunn WR, Carey JL, Spindler KP. Treatment of focal articular cartilage defects in the knee: a systematic review. *Clin Orthop Relat Res*. 2008 Apr;466(4):952-62.
65. Minas T. Chondrocyte implantation in the repair of chondral lesions of the knee: economics and quality of life. *Am J Orthop*. 1998 Nov;27(11):739-44.
66. Jakobsen RB, Engebretsen L, Slauterbeck JR. An analysis of the quality of cartilage repair studies. *J Bone Joint Surg Am*. 2005 Oct;87(10):2232-9.
67. Wood JJ, Malek MA, Frassica FJ et al. Autologous cultured chondrocytes: adverse events reported to the United States Food and Drug Administration. *The Journal of bone and joint surgery American volume*. 2006 Mar 1;88(3):503-7.
68. Behrens P, Bitter T, Kurz B, Russlies M. Matrix-associated autologous chondrocyte transplantation/implantation (MACT/MACI)--5-year follow-up. *Knee*. 2006 Jun;13(3):194-202.
69. Zeifang F, Oberle D, Nierhoff C et al. Autologous Chondrocyte Implantation Using the Original Periosteum-Cover Technique Versus Matrix-Associated Autologous Chondrocyte Implantation: A Randomized Clinical Trial. *Am J Sports Med*. 2009 Dec 4.
70. Hettrich CM, Crawford D, Rodeo SA. Cartilage repair: third-generation cell-based technologies--basic science, surgical techniques, clinical outcomes. *Sports medicine and arthroscopy review*. 2008 Dec 1;16(4):230-5.
71. Image available from:
<http://tc.engr.wisc.edu/UER/uer01/author1/>. Accessed 05 Jan 2010.
72. Lutzner J, Kasten P, Gunther KP, Kirschner S. Surgical options for patients with osteoarthritis of the knee. *Nat Rev Rheumatol*. 2009 Jun;5(6):309-16.

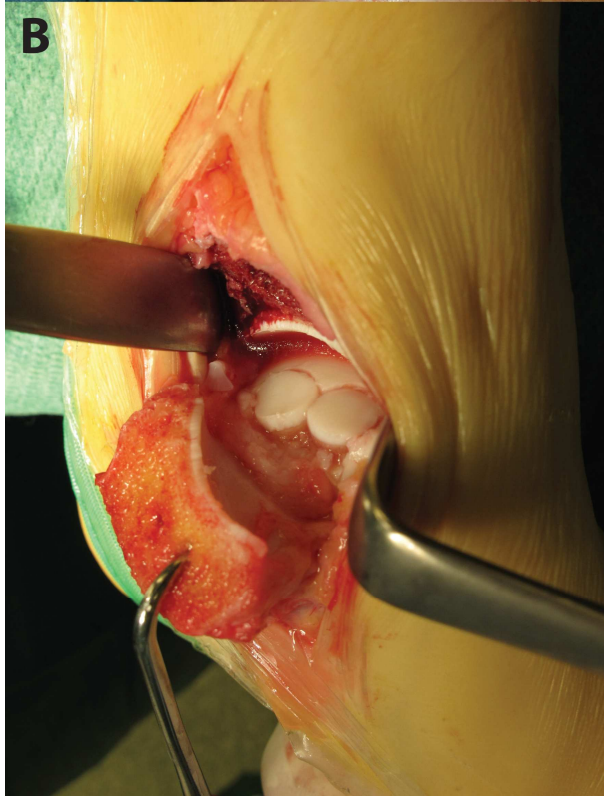
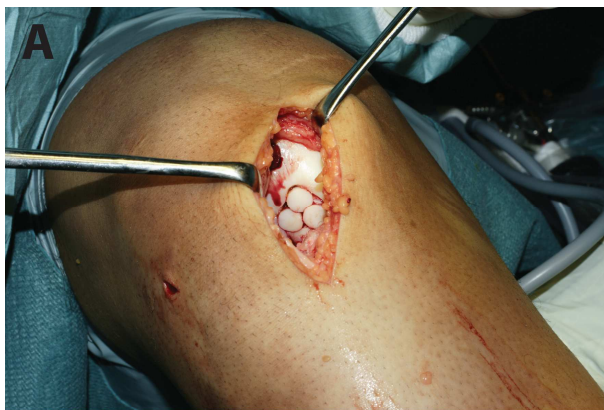
1
2
3
4
5
6
7
8
9
10
11
12
13
14
15
16
17
18
19
20
21
22
23
24
25
26
27
28
29
30
31
32
33
34
35
36
37
38
39
40
41
42
43
44
45
46
47
48
49
50
51
52
53
54
55
56
57
58
59
60



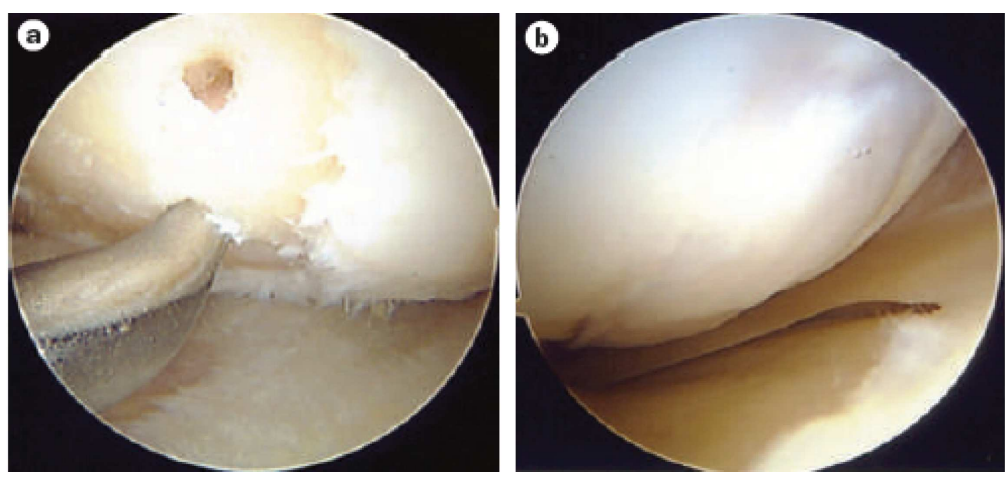
161x97mm (300 x 300 DPI)

Review Only

1
2
3
4
5
6
7
8
9
10
11
12
13
14
15
16
17
18
19
20
21
22
23
24
25
26
27
28
29
30
31
32
33
34
35
36
37
38
39
40
41
42
43
44
45
46
47
48
49
50
51
52
53
54
55
56
57
58
59
60



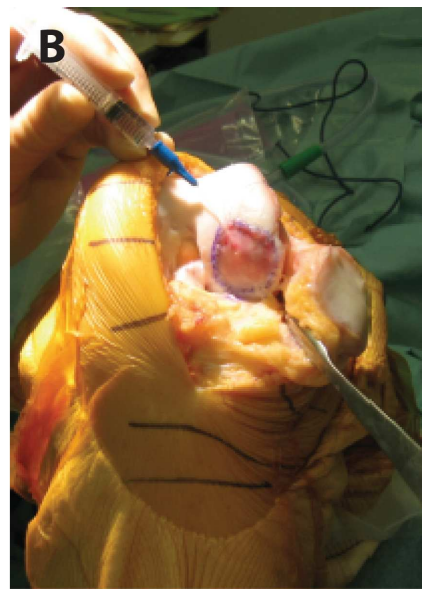
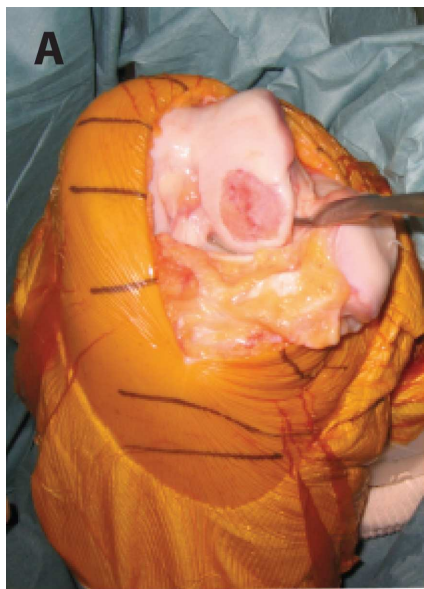
1
2
3
4
5
6
7
8
9
10
11
12
13
14
15
16
17
18
19
20
21
22
23
24
25
26
27
28
29
30
31
32
33
34
35
36
37
38
39
40
41
42
43
44
45
46
47
48
49
50
51
52
53
54
55
56
57
58
59
60



194x89mm (300 x 300 DPI)

Review Only

1
2
3
4
5
6
7
8
9
10
11
12
13
14
15
16
17
18
19
20
21
22
23
24
25
26
27
28
29
30
31
32
33
34
35
36
37
38
39
40
41
42
43
44
45
46
47
48
49
50
51
52
53
54
55
56
57
58
59
60



175x103mm (300 x 300 DPI)

Review Only