



HAL
open science

METHOTREXATE IN PEDIATRIC ULCERATIVE COLITIS: A RETROSPECTIVE SURVEY AT A SINGLE TERTIARY REFERRAL CENTER

Marina Aloi, Giovanni Di Nardo, Francesca Conte, Luigi Mazzeo, Nelson Cavallari, Federica Nuti, Salvatore Cucchiara, Laura Stronati

► **To cite this version:**

Marina Aloi, Giovanni Di Nardo, Francesca Conte, Luigi Mazzeo, Nelson Cavallari, et al.. METHOTREXATE IN PEDIATRIC ULCERATIVE COLITIS: A RETROSPECTIVE SURVEY AT A SINGLE TERTIARY REFERRAL CENTER. *Alimentary Pharmacology and Therapeutics*, 2010, 32 (8), pp.1017. 10.1111/j.1365-2036.2010.04433.x . hal-00566326

HAL Id: hal-00566326

<https://hal.science/hal-00566326>

Submitted on 16 Feb 2011

HAL is a multi-disciplinary open access archive for the deposit and dissemination of scientific research documents, whether they are published or not. The documents may come from teaching and research institutions in France or abroad, or from public or private research centers.

L'archive ouverte pluridisciplinaire **HAL**, est destinée au dépôt et à la diffusion de documents scientifiques de niveau recherche, publiés ou non, émanant des établissements d'enseignement et de recherche français ou étrangers, des laboratoires publics ou privés.

**METHOTREXATE IN PEDIATRIC ULCERATIVE COLITIS: A
RETROSPECTIVE SURVEY AT A SINGLE TERTIARY REFERRAL
CENTER**

Journal:	<i>Alimentary Pharmacology & Therapeutics</i>
Manuscript ID:	APT-0301-2010.R2
Wiley - Manuscript type:	Original Scientific Paper
Date Submitted by the Author:	22-Jul-2010
Complete List of Authors:	Aloi, Marina; Sapienza University of Rome, Pediatric Gastroenterology and Liver Unit Di Nardo, Giovanni; Sapienza University of Rome, Pediatric Gastroenterology and Liver Unit Conte, Francesca; Sapienza University of Rome, Pediatric Gastroenterology and Liver Unit Mazzeo, Luigi; Sapienza University of Rome, Pediatrics Cavallari, Nelson; Sapienza University of Rome, Pediatric Gastroenterology and Liver Unit Nutti, Federica; Sapienza University of Rome, Pediatric Gastroenterology and Liver Unit Cucchiara, Salvatore; University of Rome, Pediatric Gastroenterology Stronati, Laura; ENEA, Section of Toxicology and Biomedical Sciences
Keywords:	Inflammatory bowel disease < Disease-based, Ulcerative colitis < Disease-based, Paediatric gastroenterology < Topics, Immunosuppression < Topics

1
2
3 **METHOTREXATE IN PEDIATRIC ULCERATIVE COLITIS: A RETROSPECTIVE**
4
5 **SURVEY AT A TERTIARY REFERRAL CENTER**
6
7
8
9

10
11
12 Marina Aloï, Giovanni Di Nardo, Francesca Conte, Luigi Mazzeo, Nelson Cavallari,
13
14 Federica Nuti, Salvatore Cucchiara and *Laura Stronati.
15
16

17
18
19
20
21
22 Sapienza University of Rome, Department of Pediatrics, Pediatric Gastroenterology and
23
24 Liver Unit and ENEA Section of Toxicology and biomedical Sciences, Rome Italy
25
26

27
28
29
30
31 **Running title: Methotrexate in pediatric ulcerative colitis**
32
33

34
35
36
37
38
39
40
41
42
43
44
45
46
47
48
49
50 **Corresponding author:**

51
52 Salvatore Cucchiara, MD
53 Department of Pediatrics, Head
54 Pediatric Gastroenterology and Liver Unit, Director
55 Sapienza University of Rome
56 Viale Regina Elena 324, 00161 Rome
57 Tel +390649979324 Fax +390662277415
58 e-mail: salvatore.cucchiara@uniroma1.it
59
60

ABSTRACT

BACKGROUND. Patients with ulcerative colitis (UC) often receive thiopurines as immunomodulators (IMs) to maintain remission and avoid corticosteroids (CS). If unresponsive or intolerant to these agents they are treated with methotrexate (MTX), an antimetabolite never assessed in pediatric UC.

AIM. To describe the experience with MTX in UC children

METHODS. Thirty-two patients (median age 13.9 years) received MTX. Pediatric Ulcerative Colitis Activity Index (PUCAI) and use of CS were the main outcomes evaluated baseline and at 3, 6 and 12 months.

RESULTS. Indications to MTX were azathioprine (AZA) unresponsiveness in 18, AZA intolerance/toxicity in 10 and spondyloarthritis in 4. Response or remission were achieved in 72%, 63% and 50% of patients at 3, 6 and 12 months, respectively. Mean PUCAI was 49.5 ± 23.3 at baseline and 32.9 ± 21.9 , 29.5 ± 21.8 and 29.4 ± 19.9 at 3, 6 and 12 months, respectively ($p: 0.03$). At the beginning of MTX 16 patients (50%) received CS, that were discontinued in 13 of them (81%) by 6 months. At the end of the study 11 patients (33%) needed short courses of CS for disease relapse.

CONCLUSIONS. MTX may be useful in treating children with UC, although large, controlled trials are warranted to better define its effectiveness in pediatric UC.

INTRODUCTION

Inflammatory bowel diseases (IBD), i.e. ulcerative colitis (UC) and Crohn's disease (CD), are chronic inflammatory disorders of the gut characterized by recurrent exacerbations intermingled with phases of quiescence (1,2). Most patients with active UC respond to aminosalicylates (5-ASA) or CS. The latter are highly effective in inducing remission, however, a considerable group of patients relapse when steroids are withdrawn (3). Moreover, children on long term CS exhibit serious adverse effects, among which linear growth delay, osteopenia, and infections are the most cumbersome (3,4). CS sparing while maintaining remission is a tricky therapeutic strategy in the management of IBD: for this purpose IMs have successfully been introduced into the therapeutic armamentarium of this disorder (5,6). The most commonly used IMs for IBD are thiopurine analogs such as azathioprine (AZA) and 6-mercaptopurine (6-MP) (7): however, serious adverse events may lead to cessation of therapy in up to 25% of patients, while unresponsiveness occurs in 15-20% of them (8,9). Thiopurine intolerant or unresponsive patients are usually treated with alternative IMs or biological therapy. Recently, there has been a great concern due to a reported increase in the risk of lymphoma in IBD patients chronically treated with AZA (10). The chronic use of thiopurine analogs has been also challenged following publication of cases of hepato-splenic T cell lymphoma in young adults receiving them in association with biologics (11). Thus, pediatric gastroenterologists not uncommonly consider alternative IMs.

Methotrexate (MTX), a potent folic acid antagonist, causes a decrease in purine production at the cellular level (12,13). A direct antiinflammatory effect of MTX (i.e. inhibition of cellular proliferation, decrease in the formation of antibodies and in the production of inflammatory mediators, induction of apoptosis) has also been demonstrated (13) leading to its use in several inflammatory disorders, such as psoriasis and rheumatoid arthritis (14,15). However, the role of MTX in IBD remains somewhat unclear, although it has been

1
2
3 shown to be effective both for induction and maintenance of remission in adults with CD
4 (16-18). While very few reports have shown the effectiveness and safety of MTX in
5
6 (16-18). While very few reports have shown the effectiveness and safety of MTX in
7
8 children with CD (19,20), reports in UC are lacking and confined to adult patients
9
10 (21,23,24). Thus, the aim of this study was to report the experience of a tertiary referral
11
12 Center for Pediatric Gastroenterology in the use of MTX in children with UC.
13
14
15
16

17 **PATIENTS AND METHODS**

18
19 This is a retrospective longitudinal study conducted at a single tertiary referral Center for
20
21 Pediatric Gastroenterology. The Department database was screened for all children
22
23 diagnosed with UC by 2004, and those treated with MTX were identified. Diagnosis of UC
24
25 was based on widely agreed endoscopic and histological criteria (25), after excluding
26
27 infectious and systemic disease, food allergies and malabsorption syndromes. All patients
28
29 underwent ileocolonoscopy with a pediatric videocolonoscope (Olympus, PCF Q 180 I)
30
31 following conscious sedation with i.v. pethidine (1-2 mg/Kg) and midazolam (0.1 mg/Kg) or
32
33 under general anesthesia. Endoscopic criteria for UC were diffuse continuous
34
35 inflammation extending from the rectum proximally and characterized by granularity,
36
37 friability, small diffuse superficial ulcers superimposed on a background of loss of vascular
38
39 mucosal pattern and normal appearing distal ileal mucosa. Histological features for UC
40
41 were a continuous intense mixed acute and chronic inflammatory infiltrate of the lamina
42
43 propria, distortion of crypt architecture and/or crypt atrophy, basal plasmacytosis, cryptitis
44
45 and crypt abscesses, Paneth cell metaplasia distal to the ascending colon. The behavior of
46
47 disease activity, measured through PUCAI (26) and the use of corticosteroids (evaluated
48
49 baseline and at 3, 6,12 months post-MTX) were the main outcomes. PUCAI is a validated,
50
51 noninvasive, multi-item measure of disease activity with established cut-off values for
52
53 remission (<10 points), mild (10–34 points), moderate (35–64 points), and severe disease
54
55 (65–85 points), developed in 2007 (26,27,28). Clinical remission was defined as a PUCAI
56
57
58
59
60

1
2
3 score < 10 and clinical response as a decrease in the PUCAI of at least 20 points as
4 compared to baseline (26). Medical records of patients evaluated before 2007 were
5 retrospectively reviewed by an experienced physician unaware of medical therapy and
6 PUCAI sub-domain scores were attributed. The use of CS, adverse effects and surgical
7 procedures during the study period were the secondary outcomes recorded. Thiopurine
8 intolerance was defined as a requirement to discontinue thiopurine because of side
9 effects. Thiopurine refractoriness was defined as no clinical improvement to a trial of at
10 least 12 weeks therapy. MTX was given weekly by intramuscular injection at the dose of
11 15 mg/m² body surface area. All children received 5 mg of intramuscular folic acid weekly,
12 6 hours after MTX. To detect potential hepatic, renal or haematological side effects of MTX
13 therapy, patients were monitored every 2 weeks during the first 2 months and every 8 to
14 12 weeks thereafter (29). Laboratory tests included full blood count, inflammatory, renal
15 and liver function parameters, serum albumin, electrolytes, lipase and amylase. Liver
16 ultrasound was performed if liver function tests were abnormal, while chest x-ray was
17 performed in all patients before starting MTX to rule out pulmonary fibrosis.

18
19
20
21
22
23
24
25
26
27
28
29
30
31
32
33
34
35
36
37
38
39 Statistical analysis for the comparison of the qualitative variables was carried out by χ^2
40 test or Fisher's exact test (where appropriate). Continuous variables were compared using
41 the Mann-Whitney nonparametric *U* test. A p value less than or equal to 0.05 was
42 considered as significant. Data were given as median (and ranges) and as mean \pm SD.

43 44 45 46 47 48 49 50 **RESULTS**

51
52
53 Of the 38 children with active UC treated by MTX with a follow-up of at least 12 months, 32
54 (16 males) provided complete data on all items of the PUCAI with a valid total score
55 (median age: 14.0 years; range: 8.3–19.8; IQR 12.5). The mean age at diagnosis of UC
56 was 10 \pm 4.3 years, and MTX was commenced 23.4 \pm 12.3 months after diagnosis. The
57
58
59
60 Table summarizes baseline clinical characteristics of the patients. At the introduction of

1
2
3 MTX, an extensive colitis (pancolitis) was present in 24 (75%), a left-sided colitis in 5
4 (16%), and a proctitis in 3 (8%). AZA had been introduced in all but 4 patients as first-line
5 IM agent. Thiopurine therapy was discontinued because of primary nonresponse or
6 relapse in 18 patients (56%), and intolerance/toxicity in 10 (31%). In 4 patients MTX had
7 been introduced as the first-line IM because of coexisting joint disease
8 (spondyloarthropathy). MTX was administered parenterally in all patients with a mean
9 dose of MTX for patient of 13.7 ± 3.6 mg/m²/week. All patients were on chronic treatment
10 with mesalazine (75-100 mg/Kg/day) that was maintained in addition to MTX during all the
11 observation period.
12
13
14
15
16
17
18
19
20
21
22
23

24 Of the 32 children on MTX a clinical improvement (response or remission) was seen in
25 72%, 63%, and 50% at 3, 6, and 12 months respectively (Figure): this included 6 of 10 with
26 AZA intolerance or toxicity, and 14 of 18 with AZA refractoriness. Remission was observed
27 in 10 patients at 3 months, and in 9 at both 6 and 12 months; response was observed in
28 13, 11 and 7 patients at 3, 6, and 12 months, respectively. Mean PUCAI 6 months before
29 the introduction of MTX was 40.5 ± 23.6 (moderate disease), 49.5 ± 23.3 at the introduction
30 of MTX, and 32.9 ± 21.9 , 29.5 ± 22.8 , 29.4 ± 25.9 (mild disease) at 3, 6 and 12 months post-
31 MTX, respectively (p: 0.03). At the beginning of MTX 16 patients were receiving oral
32 prednisolone with a mean dose of 1.24 mg/Kg/day (range 0.2-3.2 mg): tapering of CS was
33 possible in 14 (87.5%), with complete discontinuation in 11 (68.7%) within the first 3
34 months, and in other 2 patients after 6 months of MTX. At 12 months, 8 children were
35 receiving short courses of CS because of disease relapse. At the end of the study period 8
36 patients had a sustained steroid-free clinical remission.
37
38
39
40
41
42
43
44
45
46
47
48
49
50
51
52
53

54 No surgery was performed during the observation period. There were adverse reactions in
55 8 patients within the first 3 months of therapy: asymptomatic elevation of alanine
56 aminotransferase (ALT 3 to 4 times the upper limit of normal) in 4, with normalization in all
57 after dose reduction of MTX, whereas 4 needed to discontinue the drug because of
58
59
60

1
2
3 intractable nausea. No haematological or infectious complications were observed in this
4
5 case series.
6
7
8
9

10 **DISCUSSION**

11
12 The natural history of UC is characterized by phases of remission intermingled with
13 recurrent flare-ups, that occur in an unpredictable fashion and impair the quality of life of
14 the patients. The main goals in the management of pediatric UC are to control disease
15 exacerbations and avoid prolonged use of CS (1). The classical medical armamentarium
16 for UC includes anti-inflammatory drugs, CS and IMs. While CS have a short-term clinical
17 efficacy, they do not change the disease natural history and cause a number of
18 troublesome side effects. The IMs are considered as steroid sparing agents, when a long-
19 term remission is attainable (30). Although thiopurines are the most commonly used IMs,
20 some patients exhibit unresponsiveness or intolerance to them and MTX has been
21 proposed as an alternative immunomodulatory therapy (1,2). Whereas there are few
22 retrospective reports on MTX in patients with CD, there are no data on the effectiveness
23 and safety of MTX in pediatric UC. Our study shows that children with UC may benefit
24 from MTX, both to induce and to maintain remission, as well as in reducing CS exposure.
25
26 Of the 32 treated patients, we observed an overall clinical improvement in 23, 20 and 16 at
27 3, 6 and 12 months, respectively. Comparable high response rates are reported in adult
28 studies. A recent retrospective study in 32 adults nonresponsive or intolerant to thiopurines
29 reported a clinical response of 68% using either oral or parenteral MTX at an induction
30 dose of 25 mg/week (31). Previously, a response rate of 72% and a remission rate of 42%
31 had been reported in adults with active UC formerly treated with thiopurines (24). The
32 evidence for using MTX in UC is restricted to observational studies, while the only
33 randomized, placebo-controlled trial in adults found no efficacy, however it was
34 underpowered and a low oral dose of MTX (12.5 mg weekly) was used (21). In our study
35
36
37
38
39
40
41
42
43
44
45
46
47
48
49
50
51
52
53
54
55
56
57
58
59
60

1
2
3 the majority of patients started MTX during a flare-up of the disease, thus it is conceivable
4 that a “regression to the mean phenomenon” might contributed to the clinical response to
5 the therapy, leading to a lower disease activity just by chance. However, as shown by
6 longitudinal assessment of disease activity, our patients had highly active disease already
7 six months before starting MTX (i.e. medium PUCAI 40.5 ± 23.6), thus reducing the likely
8 impact of this phenomenon.
9

10 We gave MTX intramuscularly since it has previous shown that this way of administration
11 may be more useful due to the variable oral bioavailability of the drug (22). Subcutaneous
12 injection is as an alternative method of parenteral administration: as compared to
13 intramuscular injection it produces similar pharmacokinetics, and leads to greater patient
14 comfort by reducing local complication rate at the injection site (23). The majority of our
15 patients improving on MTX achieved clinical remission within 10-12 weeks (range, 6–12),
16 this indicating that MTX is clinically efficacious earlier than thiopurines, which have a
17 delayed onset of action, usually 2 or 3 months after commencement of administration (30).
18 The anti-inflammatory effect of MTX at low-doses has not clearly been defined. Whereas
19 MTX at high doses has an antiproliferative and cytotoxic effect, by inhibiting the enzyme
20 dihydrofolate reductase and leading to defective DNA synthesis and cell death (12), at low-
21 doses it acts mainly as an IM (32). The immunomodulatory effect of MTX is poorly
22 understood but it involves increased concentrations of adenosine (33), inhibition of cellular
23 proliferation and induction of apoptosis (34), and decreased production of inflammatory
24 mediators, such as interleukins and eicosanoids (13).
25
26
27
28
29
30
31
32
33
34
35
36
37
38
39
40
41
42
43
44
45
46
47
48
49
50
51

52 The safety of MTX has been extensively studied in patients with chronic inflammatory
53 diseases such as rheumatoid arthritis and psoriasis. In the short term, the most common
54 side effects are of gastrointestinal type, in particular nausea, vomiting and diarrhea, and
55 asymptomatic elevation of transaminases. Longer-term safety concerns include bone
56 marrow suppression, opportunistic infection due to immune suppression, pneumonitis,
57
58
59
60

1
2
3 teratogenicity, and cirrhosis (30). The supplementation of folates during MTX therapy
4
5 seems to reduce the risk of cytopenia and the severity of gastrointestinal symptoms
6
7 without reduction in efficacy and bioavailability of the drug (35). The majority of our
8
9 patients preferred folic acid intramuscularly despite the latter is widely know to be very
10
11 effective by oral route (36).
12
13

14
15 In our study MTX was well tolerated and safe. Four children needed to discontinue the
16
17 drug due to intractable nausea unresponsive to folic acid and antiemetics; in 4 patients
18
19 there was a transient abnormality in liver function tests, that resolved with MTX dose
20
21 reduction. Due to the rarity of severe chronic liver disease related to MTX therapy and
22
23 according to recent recommendations (37,38) a conservative approach was done and no
24
25 patient underwent liver biopsy.
26
27

28
29 It is still unsettled whether MTX may be considered as a first-line IM agent in the treatment
30
31 of UC. Indeed, there are no head-to-head studies comparing MTX and AZA in IBD and no
32
33 data are available on MTX as first-line therapy while its is commonly reported in patients
34
35 unresponsive or intolerant to thiopurines. In our study only 4 patients with UC and
36
37 spondyloarthopathy received MTX as first-line IM agent: they improved both in intestinal
38
39 and articular symptoms without adverse reactions.
40
41
42

43 Although this study has some limitations such as the small sample size, the lack of
44
45 controls and the retrospective nature, however it suggests that MTX can be a useful agent
46
47 for the management of pediatric UC patients, unresponsive or intolerant to thiopurines.
48
49 Large, controlled prospective trials are warranted to better define the role and the place of
50
51 MTX in the treatment of pediatric UC.
52
53
54
55
56
57
58
59
60

Table. Clinical characteristics of 32 pts with UC treated with methotrexate

Age (yrs)	Median	14.0
	Range	8.3 – 19.8
Sex		12M,12F
Age at diagnosis (yrs)	Mean±SD	10±4,3
Disease location	Proctitis	3 (8%)
	Left-sided colitis	5 (16%)
	Pancolitis	24 (75%)
Previous therapy with AZA		28 (87%)
Indication to MTX therapy	AZA intolerance/toxicity	10 (31%)
	Nonresponse/ relapse on AZA	18 (56%)
	Spondyloarthropathy	4 (12%)
CS at the introduction of MTX		16 (50%)

For Peer Review

REFERENCES

1. Grossman AB, Baldassano RN. Specific considerations in the treatment of pediatric inflammatory bowel disease. *Expert Rev Gastroenterol Hepatol* 2008;2:105-24.
2. Sauer CG, Kugathasan S. Pediatric inflammatory bowel disease: highlighting pediatric differences in IBD. *Med Clin North Am.* 2010;94:35-52.
3. Hyams J, Markowitz J, Lerer T et al. The natural history of corticosteroid therapy for ulcerative colitis in children. *Clin Gastroenterol Hepatol* 2006;4:1118-23.
4. Leonard MB. Glucocorticoid-induced osteoporosis in children: impact of the underlying disease. *Pediatrics* 2007;119:S166-72.
5. Rufo PA, Bousvaros A. Current therapy of inflammatory bowel disease in children. *Paediatr Drugs* 2006;8:279-302.
6. Punati J, Markowitz J, Leret T, et al. Effect of early immunomodulator use in moderate to severe pediatric Crohn's disease. *Inflamm Bowel Dis* 2008;14:949-54.
7. Braus NA, Elliott DE. Advances in the pathogenesis and treatment of IBD. *Clin Immunol* 2009; 132:1-9.
8. Homan M, Baldassano RN, Mamula P. Managing complicated Crohn's disease in children and adolescents. *Nat Clin Pract Gastroenterol Hepatol* 2005;2:572-9.
9. Akoberg AK. Crohn's disease: current treatment options. *Arch Dis Child* 2008;93:787-792.
10. Kandiel A, Fraser AG, Korelitz BI, Brensinger C, Lewis JD. Increased risk of lymphoma among inflammatory bowel disease patients treated with azathioprine and 6-mercaptopurine. *Gut* 2005;54:1121-5.
11. Cucchiara S, Escher J, Hildebrand H, Amil-Dias J, Stronati L, Ruemmele FM. Pediatric inflammatory bowel disease and risk of lymphoma: should we revise our treatment strategies? *J Pediatr Gastroenterol Nutr* 2009;48:257-67.
12. Jolivet J, Cowan KH, Curt GA, Clendeninn NJ, Chabner BA. The pharmacology and clinical use of methotrexate. *N Engl J Med* 1983;309:1094-1104.
13. Cronstein BN. The mechanism of action of methotrexate. *Rheumat Dis Clin North AM* 1997;23:739-755.
14. Feely MG, Erickson A, O'Dell JR. Therapeutic options for rheumatoid arthritis. *Expert Opin Pharmacother* 2009;10:2095-106.

15. Kalb RE, Strober B, Weinstein G, Lebowitz M. Methotrexate and psoriasis: 2009 National Psoriasis Foundation Consensus Conference. *J Am Acad Dermatol*. 2009;60:824-37.
16. Kozarek RA, Patterson DJ, Gelfand MD, Botoman VA, Ball TJ, Wilske KR. Methotrexate induces clinical and histologic remission in patients with refractory inflammatory bowel disease. *Ann Intern Med* 1989;110: 353–6.
17. Feagan BG, Rochon J, Fedorak RN, et al. Methotrexate in the treatment of Crohn's disease. *N Engl J Med* 1995; 332:292–7.
18. El-Matary W, Vandermeer B, Griffiths AM. Methotrexate for maintenance of remission in ulcerative colitis. *Cochrane Database Syst Rev* 2009.
19. Uhlen S, Belbouad R, Nareski K, Goulet O, et al. Efficacy of Methotrexate in pediatric Crohn's disease: a french multicenter study. *Inflamm Bowel Dis* 2006;12:1053-1057.
20. Weiss R, Lerner A, Shapiro R, et al. Methotrexate treatment in pediatric Crohn's disease patients intolerant or resistant to purine analogues. *J Pediatr Gastroenterol Nutr* 2009;48:526-30.
21. Oren R, Arber N, Odes S, et al. Methotrexate in chronic ulcerative colitis: a double blind, randomised, Israeli multicentre trial. *Gastroenterol* 1996;110:1416-21.
22. Cummings JRF, Herrlinger KR, Travis SPL, et al. Oral methotrexate in ulcerative colitis. *Aliment Pharmacol Ther* 2005;21:285-9.
23. Patel V, Macdonald JK, McDonald JW, Chande N. Methotrexate for maintenance of remission in Crohn's disease. *Cochrane Database Syst Rev* 2009.
24. Paoluzi OA, Pica R, Marcheggiano A, et al. Azathioprine or methotrexate in the treatment of patients with steroid dependent or steroid resistant ulcerative colitis: results of an open-label study on efficacy and tolerability in inducing and maintaining remission. *Aliment Pharmacol Ther* 2002;16:1751-9.
25. Justinich CJ, Hyams JS. Inflammatory bowel disease in children and adolescence. *Gastrointest Endosc Clin N Am*, 1994;4:39-54.
26. Turner D et al. Development, validation and evaluation of a Pediatric Ulcerative Colitis Activity Index: a Prospective Multicenter Study. *Gastroenterol* 2007;133:423-432.
27. Turner D, Seow CH, Greenberg GR, et al. A systematic prospective comparison of noninvasive disease activity indices in ulcerative colitis. *Clin Gastroenterol Hepatol*. 2009;7:1081-8.

- 1
- 2
- 3 28. Turner D, Hyams J, Markowitz J, et al. Appraisal of the pediatric ulcerative colitis
- 4 activity index (PUCAI). *Inflamm Bowel Dis*. 2009;15:1218-23.
- 5
- 6 29. Kremer JM, Alarcón GS, Lightfoot RW, et al. Methotrexate for rheumatoid arthritis:
- 7 suggested guidelines for monitoring liver toxicity. *American College of*
- 8 *Rheumatology*. *Arthritis Rheum* 1994;37: 316-28.
- 9
- 10 30. Markowitz J, Grancher K, Kohn N, Daum F. Immunomodulatory therapy for pediatric
- 11 inflammatory bowel disease: changing patterns of use, 1990-2000. *Am J*
- 12 *Gastroenterol*. 2002;97:928-32.
- 13
- 14 31. Wahed M, Louis-Auguste JR, Baxter LM, et al. Efficacy of methotrexate in Crohn's
- 15 disease and ulcerative colitis patients unresponsive or intolerant to
- 16 azathioprine/mercaptopurine. *Aliment Pharmacol Ther* 2009; 30:614-20.
- 17
- 18 32. Ravikumara M, Hinsberger A, Spray CH. Role of methotrexate in the management
- 19 of Crohn's disease. *J Pediatr Gastroenterol Nutr* 2007;44:427-30.
- 20
- 21 33. Morabito L, Montesinos MC, Schreiber DM, et al. Methotrexate and sulfasalazine
- 22 promote adenosine release by a mechanism that requires ecto-5'-nucleotidase-
- 23 mediated conversion of adenine nucleotides. *J Clin Invest* 1998;101:295-300.
- 24
- 25 34. Genestier L, Paillot R, Fournel S, et al. Immunosuppressive properties of
- 26 methotrexate: apoptosis and clonal deletion of activated peripheral T cells. *J Clin*
- 27 *Invest* 1998;102:322-8.
- 28
- 29 35. Nathan DM, Iser JH, Gibson PR. A single center experience of methotrexate in the
- 30 treatment of Crohn's disease and ulcerative colitis: a case for subcutaneous
- 31 administration. *J Gastroenterol Hepatol* 2008;23:954-8.
- 32
- 33 36. Pavy S, Constantin A, Pham T, Gossec L, Maillefert JF, et al. Methotrexate therapy
- 34 for rheumatoid arthritis: clinical practice guidelines based on published evidence and
- 35 expert opinion. *Joint Bone Spine*. 2006;73:388-95.
- 36
- 37 37. Aberra FN, Lichtenstein GR. Monitoring of inflammatory bowel disease. *Aliment*
- 38 *Pharmacol Ther* 2005;21:307-19.
- 39
- 40 38. Siegel CA, Sands BE. Review article: practical management of inflammatory bowel
- 41 disease patients taking immunomodulators. *Aliment Pharmacol Ther* 2005;22:1-16.
- 42
- 43
- 44
- 45
- 46
- 47
- 48
- 49
- 50
- 51
- 52
- 53
- 54
- 55
- 56
- 57
- 58
- 59
- 60

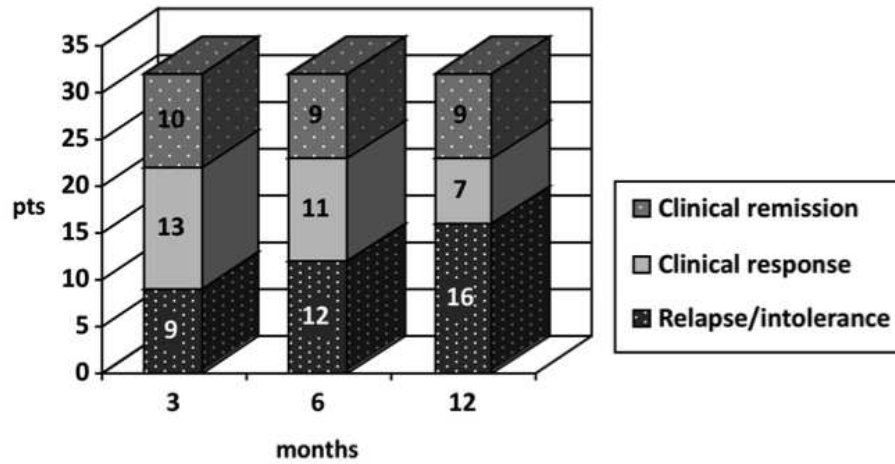


Figure. Rate of clinical remission/response and relapse/intolerance to MTX in pts with UC over the 1-year study period
254x190mm (72 x 72 DPI)