



HAL
open science

VCP Disease associated with myopathy, Paget Disease of Bone and Frontotemporal Dementia: Review of a unique disorder

Virginia E. Kimonis, Erin Fulchiero, Jouni Vesa, Giles Watts

► To cite this version:

Virginia E. Kimonis, Erin Fulchiero, Jouni Vesa, Giles Watts. VCP Disease associated with myopathy, Paget Disease of Bone and Frontotemporal Dementia: Review of a unique disorder. *Biochimica et Biophysica Acta - Molecular Basis of Disease*, 2008, 1782 (12), pp.744. 10.1016/j.bbadis.2008.09.003 . hal-00562856

HAL Id: hal-00562856

<https://hal.science/hal-00562856v1>

Submitted on 4 Feb 2011

HAL is a multi-disciplinary open access archive for the deposit and dissemination of scientific research documents, whether they are published or not. The documents may come from teaching and research institutions in France or abroad, or from public or private research centers.

L'archive ouverte pluridisciplinaire **HAL**, est destinée au dépôt et à la diffusion de documents scientifiques de niveau recherche, publiés ou non, émanant des établissements d'enseignement et de recherche français ou étrangers, des laboratoires publics ou privés.

Accepted Manuscript


VCP Disease associated with myopathy, Paget Disease of Bone and Frontotemporal Dementia: Review of a unique disorder

Virginia E. Kimonis, Erin Fulchiero, Jouni Vesa, Giles Watts

PII: S0925-4439(08)00166-X
DOI: doi: [10.1016/j.bbadis.2008.09.003](https://doi.org/10.1016/j.bbadis.2008.09.003)
Reference: BBADIS 62849

To appear in: *BBA - Molecular Basis of Disease*

Received date: 25 June 2008
Revised date: 28 August 2008
Accepted date: 3 September 2008



Please cite this article as: Virginia E. Kimonis, Erin Fulchiero, Jouni Vesa, Giles Watts, VCP Disease associated with myopathy, Paget Disease of Bone and Frontotemporal Dementia: Review of a unique disorder, *BBA - Molecular Basis of Disease* (2008), doi: [10.1016/j.bbadis.2008.09.003](https://doi.org/10.1016/j.bbadis.2008.09.003)

This is a PDF file of an unedited manuscript that has been accepted for publication. As a service to our customers we are providing this early version of the manuscript. The manuscript will undergo copyediting, typesetting, and review of the resulting proof before it is published in its final form. Please note that during the production process errors may be discovered which could affect the content, and all legal disclaimers that apply to the journal pertain.

**VCP Disease associated with myopathy, Paget Disease of Bone and Frontotemporal Dementia:
Review of a unique disorder**

Virginia E. Kimonis^{1*}, Erin Fulchiero^{2,3}, Jouni Vesa¹, and Giles Watts^{3,4}.

¹Division of Genetics and Metabolism, Department of Pediatrics, University of California, Irvine,

²Division of Genetics and Metabolism, Children's Hospital, ³Harvard Medical School, Boston, MA
Department of Orthopedic Surgery, Children's Hospital Boston, Boston, MA

Keywords:

Inclusion body, vacuolar myopathy, ALS, FSH, Alzheimer, TDP43, ubiquitin, AAA protein

*Correspondence to:

Virginia Kimonis, M.D, MRCP,

Division of Genetics & Metabolism,

Department of Pediatrics,

University of California, Irvine

101 The City Drive, ZOT 4482

Orange, CA 92868

Tel: (714) 456-2942

Fax: (714) 456-5610

Email: vkimonis@uci.edu

ABSTRACT

Inclusion body myopathy (IBM) associated with Paget disease of the bone (PDB) and frontotemporal dementia (FTD) (now called IBMPFD), is a progressive autosomal dominant disorder that was recently identified as being caused by mutations in the VCP (p97 or CDC48) gene which plays a key role in the ubiquitin-proteasome dependent degradation of cytosolic proteins and in the retro translocation of misfolded proteins from the endoplasmic reticulum into the cytoplasm. Approximately 90% of the affected persons in the study have myopathy or muscle weakness particularly of the shoulder and hip girdles, which can lead to loss of walking ability and even death by complications of respiratory and cardiac failure. About half of affected study participants have Paget disease of bone characterized by abnormal rates of bone growth that can result in bone pain, enlargement and fractures. Findings of premature FTD affecting behavior and personality are seen in a third of affected individuals. Within 20 IBMPFD families whose data was analyzed for this study, ten missense mutations have been identified, the majority of which are located in the N-terminal ubiquitin binding domain. Inclusions seen in the muscle, brain and heart in VCP disease contain ubiquitin, beta amyloid and TDP 43, also seen in other neurodegenerative disorders thus implicating common pathways in their pathogenesis.

INTRODUCTION

The inclusion body myopathies encompass a heterogeneous group of autosomal recessive and autosomal dominant disorders which include sporadic inclusion body myositis (s-IBM) and hereditary inclusion body myopathies (h-IBM). Both autosomal dominant (IBM1) and autosomal recessive hereditary inclusion body myopathies have been previously studied. The autosomal recessive form, IBM2, was first identified in a Persian Jewish family as affecting the leg muscles but sparing the quadriceps. Subsequent studies mapped this form of HIBM to 9p13-12 and identified mutations in the UDP-N-acetylglucosamine-2-epimerase/N-acetylmannosamine kinase (GNE) gene as causal [1]. Nonaka myopathy or distal myopathy with rimmed vacuoles (OMIM 605820) is allelic to IBM2 [2]. Autosomal dominant type of IBM—type 3 associated with congenital joint contractures, external ophthalmoplegia, and proximal muscle weakness maps to chromosome region 17p13.1 and is associated with mutations in myosin heavy chain MYHC2A, the major isoform in type 2A fibers. Inclusion body myopathy with Paget disease of bone and frontotemporal dementia (IBMPFD, OMIM 167320) is a highly penetrant, autosomal dominant progressive disorder that maps to chromosome 9p21-p12 [3]. Although the concurrent presentation of Paget's disease, neuronal degeneration, and myopathy has been documented previously [4-6], this combination was recognized as a genetically distinct clinical syndrome only in 2000 [7]. A diagnosis of IBMPFD should be considered if an individual who has two or more of the following features: progressive myopathy, Paget disease of bone, and Frontotemporal dementia. *Tau* mutations were first identified in several families with autosomal dominant hereditary frontotemporal dementia (FTD) and Parkinsonism linked to chromosome 17 (FTDP-17) [8]. The majority of FTD families however have no demonstrable *tau* mutations [9], however recently have been identified with mutations in the progranulin gene [10, 11]. IBMPFD was subsequently attributed to being caused by mutations in the gene encoding Valosin-Containing Protein (VCP), a member of the AAA-ATPase superfamily and an essential component of the ubiquitin-proteasome pathway-mediated Endoplasmic Reticulum-Associated Degradation (ERAD) [12]. Our study has expanded to include patients from the original 13 North American families reported by Watts et. al (2004) [12], families

reported from Germany [13], France [14], Austria [15] and additional families studied by our group [16], altogether harboring ten VCP missense mutations, approximately half of which represent mutation hot spots.

CLINICAL DIAGNOSIS AND PHENOTYPIC DESCRIPTION

Myopathy

Among these unrelated families, 122 individuals presented clinically with a combination of components of the familial disease: 107 (87.7%) had myopathic weakness at a mean age of 42.9 (Range 3-66 y). The myopathy is characterized by adult-onset, slowly progressive distal and proximal muscle weakness with initial involvement of the hip girdle and shoulder girdle muscle groups. Patients exhibit abnormal, waddling gait; inability to raise the arms; difficulty in climbing stairs; and mild weakness of the hands. Clinical features include a generalized reduction or absence of tendon reflexes, normal nerve conduction, and myopathic electromyogram (EMG). The serum creatine phosphokinase (CPK) levels are typically normal to slightly elevated (mean 195 U/L, range 40-1145 U/L; normal range 20-222 U/L) with the highest levels having been identified in the early stages of the disease. Light microscopy of muscle biopsy reveals nonspecific changes: variability in fiber size, type I fiber predominance, and atrophic and hypertrophic fibers. Fibers may contain single or multiple rimmed vacuoles and cytoplasmic VCP- and ubiquitin-positive inclusions visible in some fibers are characteristic of inclusion body myopathy. The inclusions appear with time and can be observed at a later stage of the disease in some individuals. In advanced cases, severe degenerative muscle changes and fatty replacement of muscle fibers may be noted. Unlike sIBM inflammatory cells are notably absent. Affected patients lose ambulation, become bedridden, and develop quadriparesis, with respiratory and cardiac failure eventually leading to death between the ages of 40s-60s. Historically, patients suffering from the debilitating effects of this ultimately lethal disease have been misdiagnosed with a range of diseases including Limb-Girdle Muscular Dystrophy (LGMD), Amyotrophic Lateral Sclerosis (ALS), muscular dystrophy,

facioscapulohumeral muscular dystrophy (FSH), scapuloperoneal muscular dystrophy, and myotonic dystrophy [7] .

Immunohistochemical analysis with a polyclonal antibody to VCP indicates the localization of VCP to rounded aggregates present sporadically in both normal and aberrant muscle fibers [12]. Atrophic and vacuolated muscle fibers containing abundant cytoplasmic-paired helical filaments with epitopes of phosphorylated tau, congophilia, abnormal accumulation of beta amyloid precursor protein (APP) epitopes, and accumulation of apolipoprotein E (ApoE) were observed in one family [17]. Weihl et al (2008) [18] evaluated the immunolocalization of FTD-U associated proteins, VCP and TDP-43 in muscle because of the findings of TDP43 positive inclusions in the brains of affected individuals by Neumann et al. 2007 [19]. Both proteins are normally present in myonuclei and accumulate as sarcoplasmic inclusions, which in some cases co-localize with ubiquitin in sIBM and IBMPFD.

Paget's disease of bone

Paget's disease of the bone (PDB) was identified in 56 (45.9%) at a mean age of 41.7 years (Range 23-65 y) versus > 50 years. in the general population. The typical distribution of Paget's disease includes the spine, pelvis, scapulae and skull. PDB is often asymptomatic; however, patients may exhibit spine or hip pain, skeletal deformity and localized enlargement. Additionally the skin may feel warm to the touch because of increased vascularity. A clinical diagnosis of Paget's disease should be confirmed through radiology, radionuclide bone scanning, and biochemical testing of bone resorption or formation parameters. Radiologic surveys reveal coarse trabeculation, cortical thickening, transverse lucent areas, and spotty sclerosis; however, radionuclide scans provide the most sensitive detection of abnormal bone metabolism [20]. Additional disease manifestations include reduced height, pathologic fractures, long bone or cranial bone deformity, or hearing loss due to eighth nerve compression by calvarial bony overgrowth. PDB is characterized by the overactivity of abnormally large,

multinucleated osteoclasts which histologically reveal nuclear filamentous inclusions of 15 to 18 nm paired helical filaments similar to that seen in IBM.

Serum alkaline phosphatase (ALP) concentrations were elevated in all affected individuals with PDB (mean 359 U/L, range 58-1724 U/L; normal range 30-130); urine pyridinoline (PYD) (mean 153, normal 31.1 IU/I); and deoxypyridinoline (DPD) concentration was increased (mean 40 IU/L, normal 6.8 IU/L) in all affected individuals.

Frontotemporal dementia

Frontotemporal dementia (FTD) was seen only in 14 of 20 families including 46 (37.7%) patients with a mean age of diagnosis of 55.1 (Range 39- 60) years (Figure 1).

Early-onset frontotemporal dementia impairs executive or other frontal lobe functions, dominated by behavioral changes. Diagnosis is based upon drastic personality alteration including changes in affect, decline in social interpersonal conduct, perseveration, aphasia and emotional blunting detected by comprehensive neuropsychological assessment. In families studied thus far, approximately 30% of affected individuals had frontotemporal dementia with a mean age of diagnosis of 55 years (range: 42-62 years). Several individuals were in advanced stages of dementia when diagnosed with IBMPFD. The relative sparing of visuospatial abilities and memory are discriminators between FTD, Alzheimer's, and other dementias. FTD is further distinguished by cerebral atrophy in the frontal and anterior temporal lobes of the brain rather than the hippocampal, posterior temporal and parietal effects of Alzheimer's disease. Neurofibrillary tangles, senile plaques and Lewy bodies associated with various dementias are also absent. Diagnosis is complicated by the inconclusive results of structural and functional neuroimaging, including the differential presence of focal prefrontal or anterior temporal atrophy on magnetic resonance imaging (MRI) or computed tomography (CT).

Modifier genes were evaluated because of the variable phenotype in IBMPFD. From a database of 231 members of 15 original families, 174 had *APOE* genotype available for regression analysis. Data analysis suggested a potential link between *APOE* 4 genotype and the frontotemporal dementia found in IBMPFD but no association was found with

the myopathy and PDB. We also observed no association between frontotemporal dementia and microtubule associated protein tau (*MAPT*) H2 haplotype ($p=0.5$) [21]. Because of limited information on the neuropathology in IBMPFD, we performed a systematic analysis of the brain neuropathologic changes in eight patients with VCP mutations. A novel pattern of ubiquitin pathology was identified, characterized by ubiquitin-positive neuronal intranuclear inclusions and dystrophic neurites. The ubiquitin pathology was abundant in the neocortex, less robust in limbic and subcortical nuclei, and absent in the dentate gyrus. Only rare inclusions were detected with antibodies to VCP and there was no biochemical alteration in the VCP protein [22]. We studied the pathological consequences of several heterozygous VCP mutations on human striated muscle. IBMPFD skeletal muscle pathology is characterized by degenerative changes and filamentous VCP- and ubiquitin-positive cytoplasmic and nuclear protein aggregates [7], [23]. The CNS pathology is characterized by a novel pattern of ubiquitin pathology distinct from without VCP mutations. TAR DNA binding protein 43 (TDP-43) was recently identified as a major disease protein in the ubiquitin-positive inclusions of sporadic and familial frontotemporal lobar degeneration with ubiquitin-positive inclusions (FTLD-U). Accumulations of TDP-43 co localized with ubiquitin pathology in IBMPFD, including both intranuclear inclusions and dystrophic neurites [19]. These studies further support the hypothesis that the pathogenesis of IBM and neurodegenerative disorders, especially FTD-U are similar.

VALOSIN-CONTAINING PROTEIN

Valosin containing protein (VCP) or p97 is a member of the AAA protein superfamily (ATPases Associated with a variety of cellular Activities). Typical of type II family members, VCP is characterized by the presence of two conserved energy-generating ATPase domains (D1 and D2), as well as a cofactor and polyubiquitin binding CDC48 N-domain, a flexible N-D1 linker, D1-D2 linker, and C-terminal domains. VCP forms a hexameric barrel of six-fold symmetry, wherein the D1 and D2 domains of each subunit are joined in a head to tail fashion [24] while the N-domain juts out from the apex of the D1 and D2 domains at 30° [25]. The N-terminal CDC48 domain in which the majority of

observed mutations are found is involved in ubiquitin binding. Exons 3, 5, and 6 encode regions of the CDC48, Linker 1, and D1 AAA-ATPase domains, wherein all but one of the identified IBMPFD mutations have been located (Table 1).

Protein degradation in eukaryotes usually requires multiubiquitylation and subsequent delivery of the tagged substrates to the proteasome [26]. Recent studies suggest the involvement of the AAA ATPase CDC48, its cofactors, and other ubiquitin binding factors in protein degradation, but how these proteins work together is unclear although it has been shown that these factors cooperate sequentially through protein-protein interactions and thereby escort ubiquitin-protein conjugates to the proteasome. Central to this pathway is the chaperone CDC48/p97, which coordinates substrate recruitment, E4-catalyzed multiubiquitin chain assembly, and proteasomal targeting [27], [28].

Concomitantly, CDC48 prevents the formation of excessive multiubiquitin chain sizes that are surplus to requirements for degradation. In yeast, this escort pathway guides a transcription factor from its activation in the cytosol to its final degradation and also mediates proteolysis at the endoplasmic reticulum by the ERAD pathway.

Numerous seemingly unrelated functions have been attributed to this ubiquitous protein constituting 1% of the cytosol in yeast, including ubiquitin/proteasome-dependent proteolysis through association with cofactor Ufd1-Npl4, cell cycle control, membrane fusion, nuclear envelope reformation, suppression of apoptosis, regulation of the NF- κ B pathway and DNA damage response [29, 30]. Studies implicating VCP in endoplasmic reticulum-associated degradation have shown that its malfunction results in vacuole and inclusion body formation [29]. A recent study of VCP's specific functionality within this pathway highlights the retention of normal ATPase activity and hexameric structure despite the presence of the common R155H mutation in the enzyme's N-domain [31]. Size exclusion analysis and electron microscopy of the mutant protein proved identical to hexameric wild-type VCP [32]. However, transfection of C2C12 cells with R155H and R95G mutants increased the presence of ubiquitin-conjugated proteins relative to cells both transfected with the wild-type protein and untransfected cells. More significantly, impairment of the degradation of Δ F508 mutant cystic fibrosis transmembrane regulator

(Δ F508-CFTR), a known ERAD substrate, directly implicates perturbation of the ERAD pathway. IBMPFD thereby joins familial forms of Alzheimer's disease, Parkinson's disease, Marinesco-Sjögren Syndrome, and other neurodegenerative diseases in which intracellular protein accumulation results from perturbation of ER chaperone function. Each of these disorders affects genes (VCP, UBB+1, parkin, and SYL1, respectively), which are essential in the ubiquitin-proteasome and ER-associated degradation (ERAD) pathways. It has also been proposed that VCP functions as a mediator for both aggregate formation and clearance, depending on the concentration of soluble aggregate-prone proteins, indicating that VCP has dual functions as an aggregate formase and an unfoldase. All IBMPFD VCPs showed elevated aggregate formase activities on both polyglutamine and proteasome inhibitor-mediated aggregates. Biochemically, all IBMPFD VCPs showed elevated ATPase activities as well as elevated binding affinities not only for several VCP cofactors, but also for ubiquitinated proteins [33].

Unique to IBMPFD is the phenotypic overlap of three distinct diseases, which can be attributed individually to gene mutations similarly compromising ubiquitin-binding or targeting similar cellular pathways or proteins. For example, mutations affecting the ubiquitin-binding domain of *SQSTM1/p62* are a common cause of familial and sporadic Paget's disease of bone [34]. The ability of p62 to bind noncovalently to ubiquitin as well as to signaling proteins suggests that p62 may play a regulatory role that is connected to the ubiquitin system. Similar to VCP, p62 has been shown to co-localize with neuronal and glial ubiquitin-containing inclusions in Alzheimer's disease, Pick's disease, dementia with Lewy bodies, Parkinson's disease, and multiple system atrophy [35]. It is notable that p97/VCP has been shown to target $\text{I}\kappa\text{B}\alpha$ for ubiquitination and degradation by the proteasome. The degradation of $\text{I}\kappa\text{B}\alpha$ results in the translocation of $\text{NF}\kappa\text{B}$ from the cytoplasm to the nucleus where it activates the expression of specific cellular genes. PDB2 is caused by exon 1 mutations in the *TNFRSF11A* gene on chromosome 18q22.1, which encodes the Receptor Activator of $\text{NF}\kappa\text{B}$ (RANK), which is essential for osteoclast formation [36, 37].

Several novel VCP mutations have been described (Table 1) in families and individuals with sporadically occurring disease [13][16] [38][39]. Bersano et al. (2007) [38] reported a 69 year old male with the R159C mutation who had progressive muscle weakness since the age of 50 years, and FTD 18 years later. We have recently identified this mutation in a family with inclusion body myopathy, PDB, dementia and Parkinson's disease (Unpublished). Other phenotypes associated with VCP mutations include cardiomyopathy [7, 13], cataracts and liver disease in one family, the latter consisting of elevated liver enzymes, cholestasis, steatosis, and liver fibrosis [14]. Spina et al (2008) [42] reported three new families with IBMPFD associated with VCP mutations. One family had the R159C and another the R191Q mutation both of whom had several individuals with Parkinson's disease. A novel T262A mutation was found in a family of eight individuals with combinations of FTD, myopathy, Paget's disease, and primary progressive aphasia in one individual. We predict that more patients with VCP disease, both familial and simplex will be identified with better availability of testing (www.geneclinics.org) and wider appreciation of the variable clinical phenotype. Genotype-Phenotype correlations have been performed in our families and it is difficult to make any specific conclusions because of the enormous intrafamilial variations seen. The majority of the mutations are localized in the ubiquitin-proteasome domain and it can be predicted that increased severity would be noted amongst individuals with mutations in the ATPase domain. Indeed we reported a more severe phenotype with the A232E mutation in one family and other families are relatively small for any conclusions to be reached.

ACKNOWLEDGMENTS

The authors thank the numerous collaborators, researchers, health care providers and patients for their generous contribution to this work.

ACCEPTED MANUSCRIPT

REFERENCES

- [1] I. Eisenberg, N. Avidan, T. Potikha, H. Hochner, M. Chen, T. Olender, M. Barash, M. Shemesh, M. Sadeh, G. Grabov-Nardini, I. Shmlevich, A. Friedmann, G. Karpati, W.G. Bradley, L. Baumbach, D. Lancet, E.B. Asher, J.S. Beckmann, Z. Argov, S. Mitrani-Rosenbaum, The UDP-N-acetylglucosamine 2-epimerase/N-acetylmannosamine kinase gene is mutated in recessive hereditary inclusion body myopathy, *Nat Genet* 29 (2001) 83-87.
- [2] T. Kayashima, H. Matsuo, A. Satoh, T. Ohta, K. Yoshiura, N. Matsumoto, Y. Nakane, N. Niikawa, T. Kishino, Nonaka myopathy is caused by mutations in the UDP-N-acetylglucosamine-2-epimerase/N-acetylmannosamine kinase gene (GNE), *J Hum Genet* 47 (2002) 77-79.
- [3] M.J. Kovach, B. Waggoner, S.M. Leal, D. Gelber, R. Khardori, M.A. Levenstien, C.A. Shanks, G. Gregg, M.T. Al-Lozi, T. Miller, W. Rakowicz, G. Lopate, J. Florence, G. Glosser, Z. Simmons, J.C. Morris, M.P. Whyte, A. Pestronk, V.E. Kimonis, Clinical delineation and localization to chromosome 9p13.3-p12 of a unique dominant disorder in four families: hereditary inclusion body myopathy, Paget disease of bone, and frontotemporal dementia, *Mol Genet Metab* 74 (2001) 458-475.
- [4] W.S. Tucker, Jr., W.H. Hubbard, T.D. Stryker, S.W. Morgan, O.B. Evans, F.R. Freeman, G.B. Theil, A new familial disorder of combined lower motor neuron degeneration and skeletal disorganization, *Trans Assoc Am Physicians* 95 (1982) 126-134.
- [5] T.I. McBride, Paget's disease and muscular dystrophy. Report of an unusual association in one family, *Scott Med J* 11 (1966) 238-243.
- [6] J.E. Caughey, J.F. Gwynne, N.R. Jefferson, Dystrophia myotonica associated with familial Paget's disease (osteitis deformans) with sarcomata, *J Bone Joint Surg Br* 39-B (1957) 316-325.
- [7] V.E. Kimonis, M.J. Kovach, B. Waggoner, S. Leal, A. Salam, L. Rimer, K. Davis, R. Khardori, D. Gelber, Clinical and molecular studies in a unique family with autosomal dominant limb-girdle muscular dystrophy and Paget disease of bone, *Genet Med* 2 (2000) 232-241.
- [8] N.L. Foster, K. Wilhelmsen, A.A. Sima, M.Z. Jones, C.J. D'Amato, S. Gilman, Frontotemporal dementia and parkinsonism linked to chromosome 17: a consensus conference. Conference Participants, *Ann Neurol* 41 (1997) 706-715.
- [9] S.M. Rosso, W. Kamphorst, B. de Graaf, R. Willemsen, R. Ravid, M.F. Niermeijer, M.G. Spillantini, P. Heutink, J.C. van Swieten, Familial frontotemporal dementia with ubiquitin-positive inclusions is linked to chromosome 17q21-22, *Brain* 124 (2001) 1948-1957.
- [10] M. Baker, I.R. Mackenzie, S.M. Pickering-Brown, J. Gass, R. Rademakers, C. Lindholm, J. Snowden, J. Adamson, A.D. Sadovnick, S. Rollinson, A. Cannon, E. Dwosh, D. Neary, S. Melquist, A. Richardson, D. Dickson, Z. Berger, J. Eriksen, T. Robinson, C. Zehr, C.A. Dickey, R. Crook, E. McGowan, D. Mann, B. Boeve,

- H. Feldman, M. Hutton, Mutations in progranulin cause tau-negative frontotemporal dementia linked to chromosome 17, *Nature* 442 (2006) 916-919.
- [11] M. Cruts, I. Gijssels, J. van der Zee, S. Engelborghs, H. Wils, D. Pirici, R. Rademakers, R. Vandenberghe, B. Dermaut, J.J. Martin, C. van Duijn, K. Peeters, R. Sciot, P. Santens, T. De Pooter, M. Mattheijssens, M. Van den Broeck, I. Cuijt, K. Vennekens, P.P. De Deyn, S. Kumar-Singh, C. Van Broeckhoven, Null mutations in progranulin cause ubiquitin-positive frontotemporal dementia linked to chromosome 17q21, *Nature* 442 (2006) 920-924.
- [12] G.D. Watts, J. Wymer, M.J. Kovach, S.G. Mehta, S. Mumm, D. Darvish, A. Pestronk, M.P. Whyte, V.E. Kimonis, Inclusion body myopathy associated with Paget disease of bone and frontotemporal dementia is caused by mutant valosin-containing protein, *Nat Genet* 36 (2004) 377-381.
- [13] R. Schroder, G.D. Watts, S.G. Mehta, B.O. Evert, P. Broich, K. Fliessbach, K. Pauls, V.H. Hans, V. Kimonis, D.R. Thal, Mutant valosin-containing protein causes a novel type of frontotemporal dementia, *Ann Neurol* 57 (2005) 457-461.
- [14] L. Guyant-Marechal, A. Laquerriere, C. Duyckaerts, C. Dumanchin, J. Bou, F. Dugny, I. Le Ber, T. Frebourg, D. Hannequin, D. Campion, Valosin-containing protein gene mutations: clinical and neuropathologic features, *Neurology* 67 (2006) 644-651.
- [15] D. Haubenberger, R.E. Bittner, S. Rauch-Shorny, F. Zimprich, C. Mannhalter, L. Wagner, I. Mineva, K. Vass, E. Auff, A. Zimprich, Inclusion body myopathy and Paget disease is linked to a novel mutation in the VCP gene, *Neurology* 65 (2005) 1304-1305.
- [16] G.D. Watts, D. Thomasova, S.K. Ramdeen, E.C. Fulchiero, S.G. Mehta, D.A. Drachman, C.C. Wehl, Z. Jamrozik, H. Kwiecinski, A. Kaminska, V.E. Kimonis, Novel VCP mutations in inclusion body myopathy associated with Paget disease of bone and frontotemporal dementia, *Clin Genet* 72 (2007) 420-426.
- [17] A. Alvarez, Z. Simmons, E.W. K., V. Askanas, New autosomal dominant inclusion body myopathy (AD-IBM) with many congophilic muscle nuclei that contain paired-helical filaments (PHFs) composed of phosphorylated tau. , *Neuro* 50 (1998) A204.
- [18] T.P. Wehl CC, Miller SE, Watts G, Smith C, Forman M, Hanson PI, Kimonis V, and Pestronk A. , TDP-43 accumulation in IBM muscle suggests a common pathogenic mechanism with Frontotemporal dementia, (2008).
- [19] M. Neumann, I.R. Mackenzie, N.J. Cairns, P.J. Boyer, W.R. Markesbery, C.D. Smith, J.P. Taylor, H.A. Kretschmar, V.E. Kimonis, M.S. Forman, TDP-43 in the ubiquitin pathology of frontotemporal dementia with VCP gene mutations, *J Neuropathol Exp Neurol* 66 (2007) 152-157.
- [20] S.H. Ralston, A.L. Langston, I.R. Reid, Pathogenesis and management of Paget's disease of bone, *Lancet* 372 (2008) 155-163.
- [21] S.G. Mehta, G.D. Watts, J.L. Adamson, M. Hutton, G. Umberger, S. Xiong, S. Ramdeen, M.A. Lovell, V.E. Kimonis, C.D. Smith, APOE is a potential modifier gene in an autosomal dominant form of frontotemporal dementia (IBMPFD), *Genet Med* 9 (2007) 9-13.
- [22] M.S. Forman, I.R. Mackenzie, N.J. Cairns, E. Swanson, P.J. Boyer, D.A. Drachman, B.S. Jhaveri, J.H. Karlawish, A. Pestronk, T.W. Smith, P.H. Tu, G.D.

- Watts, W.R. Markesbery, C.D. Smith, V.E. Kimonis, Novel ubiquitin neuropathology in frontotemporal dementia with valosin-containing protein gene mutations, *J Neuropathol Exp Neurol* 65 (2006) 571-581.
- [23] V.E. Kimonis, S.G. Mehta, E.C. Fulchiero, D. Thomasova, M. Pasquali, K. Boycott, E.G. Neilan, A. Kartashov, M.S. Forman, S. Tucker, K. Kimonis, S. Mumm, M.P. Whyte, C.D. Smith, G.D. Watts, Clinical studies in familial VCP myopathy associated with Paget disease of bone and frontotemporal dementia, *Am J Med Genet A* 146 (2008) 745-757.
- [24] X. Zhang, A. Shaw, P.A. Bates, R.H. Newman, B. Gowen, E. Orlova, M.A. Gorman, H. Kondo, P. Dokurno, J. Lally, G. Leonard, H. Meyer, M. van Heel, P.S. Freemont, Structure of the AAA ATPase p97, *Mol Cell* 6 (2000) 1473-1484.
- [25] B. DeLaBarre, A.T. Brunger, Complete structure of p97/valosin-containing protein reveals communication between nucleotide domains, *Nat Struct Biol* 10 (2003) 856-863.
- [26] H. Richly, M. Rape, S. Braun, S. Rumpf, C. Hoegel, S. Jentsch, A series of ubiquitin binding factors connects CDC48/p97 to substrate multiubiquitylation and proteasomal targeting, *Cell* 120 (2005) 73-84.
- [27] E. Rabinovich, A. Kerem, K.U. Frohlich, N. Diamant, S. Bar-Nun, AAA-ATPase p97/Cdc48p, a cytosolic chaperone required for endoplasmic reticulum-associated protein degradation, *Mol Cell Biol* 22 (2002) 626-634.
- [28] Y. Ye, H.H. Meyer, T.A. Rapoport, The AAA ATPase Cdc48/p97 and its partners transport proteins from the ER into the cytosol, *Nature* 414 (2001) 652-656.
- [29] M. Hirabayashi, K. Inoue, K. Tanaka, K. Nakadate, Y. Ohsawa, Y. Kamei, A.H. Popiel, A. Sinohara, A. Iwamatsu, Y. Kimura, Y. Uchiyama, S. Hori, A. Kakizuka, VCP/p97 in abnormal protein aggregates, cytoplasmic vacuoles, and cell death, phenotypes relevant to neurodegeneration, *Cell Death Differ* 8 (2001) 977-984.
- [30] T. Kobayashi, K. Tanaka, K. Inoue, A. Kakizuka, Functional ATPase activity of p97/valosin-containing protein (VCP) is required for the quality control of endoplasmic reticulum in neuronally differentiated mammalian PC12 cells, *J Biol Chem* 277 (2002) 47358-47365.
- [31] C.C. Weihl, S.E. Miller, P.I. Hanson, A. Pestronk, Transgenic expression of inclusion body myopathy associated mutant p97/VCP causes weakness and ubiquitinated protein inclusions in mice, *Hum Mol Genet* 16 (2007) 919-928.
- [32] C.C. Weihl, S. Dalal, A. Pestronk, P.I. Hanson, Inclusion body myopathy-associated mutations in p97/VCP impair endoplasmic reticulum-associated degradation, *Hum Mol Genet* 15 (2006) 189-199.
- [33] A. Kakizuka, Roles of VCP in human neurodegenerative disorders, *Biochem Soc Trans* 36 (2008) 105-108.
- [34] L.J. Hocking, G.J. Lucas, A. Daroszewska, J. Mangion, M. Olavesen, T. Cundy, G.C. Nicholson, L. Ward, S.T. Bennett, W. Wuyts, W. Van Hul, S.H. Ralston, Domain-specific mutations in sequestosome 1 (SQSTM1) cause familial and sporadic Paget's disease, *Hum Mol Genet* 11 (2002) 2735-2739.
- [35] E. Kuusisto, A. Salminen, I. Alafuzoff, Ubiquitin-binding protein p62 is present in neuronal and glial inclusions in human tauopathies and synucleinopathies, *Neuroreport* 12 (2001) 2085-2090.

- [36] D.M. Anderson, E. Maraskovsky, W.L. Billingsley, W.C. Dougall, M.E. Tometsko, E.R. Roux, M.C. Teepe, R.F. DuBose, D. Cosman, L. Galibert, A homologue of the TNF receptor and its ligand enhance T-cell growth and dendritic-cell function, *Nature* 390 (1997) 175-179.
- [37] A. Daroszewska, S.H. Ralston, Genetics of Paget's disease of bone, *Clin Sci (Lond)* 109 (2005) 257-263.
- [38] A. Bersano, R. Del Bo, C. Lamperti, S. Ghezzi, G. Fagiolari, F. Fortunato, E. Ballabio, M. Moggio, L. Candelise, D. Galimberti, R. Virgilio, S. Lanfranconi, Y. Torrente, M. Carpo, N. Bresolin, G.P. Comi, S. Corti, Inclusion body myopathy and frontotemporal dementia caused by a novel VCP mutation, *Neurobiol Aging* (2007).
- [39] V. Viassolo, S.C. Previtali, E. Schiatti, G. Magnani, C. Minetti, F. Zara, M. Grasso, F. Dagna-Bricarelli, E. Di Maria, Inclusion body myopathy, Paget's disease of the bone and frontotemporal dementia: recurrence of the VCP R155H mutation in an Italian family and implications for genetic counselling, *Clin Genet* (2008).

Table 1. List of Mutations identified in VCP.

	Amino Acid	Base Change (ORF)	Exon	Domain	Exon bp	Number of Families	References
1	R93C	277C>T	3	CDC48	148	4	12, 38, 39
2	R95G	283C>G	3	CDC48	154	2	10
3	R95C	283C>T	3	CDC48	154	1	P/C
4	R155C	463C>T	5	CDC48	18	5	10, 11, 12, 39, 40
5	R155H	464G>A	5	CDC48	19	8	10, 39, 41
6	R155P	464G>C	5	CDC48	19	1	10
7	R159H	476G>A	5	CDC48	31	2	13
8	R159C	476G>A	5	CDC48	31	2	37, 42
9	R191Q	572G>A	5	Linker 1	127	1	10, 42
10	L198W	593T>G	6	Linker 1	17	1	14
11	A232E	695C>A	6	Junction (L1-D1)	119	1	10
12	T262A	N/A	7	AAA D1	103	1	42
13	N387H	1159A>C	10	AAA D1	78	1	14

N/A = not available. P/C= Personal communication Joline Dalton and John Day, Dept of Neurology, University of Minnesota, Minneapolis, MN.

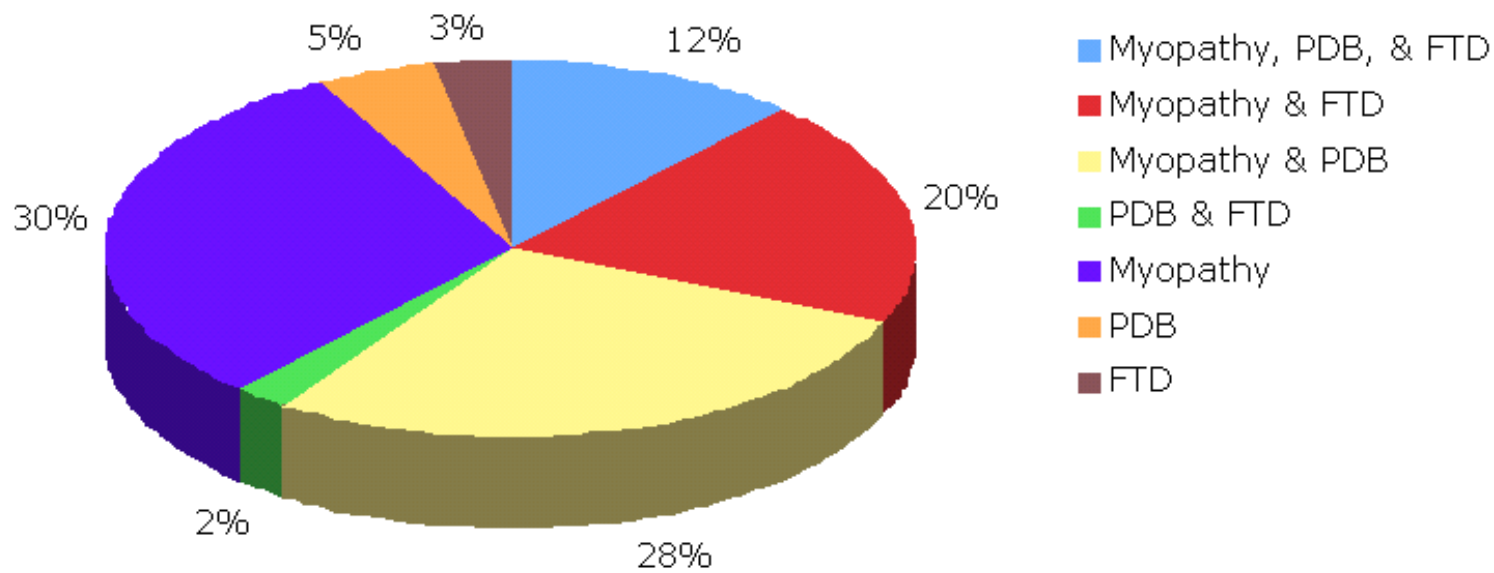


Figure 1. Phenotypes associated with VCP disease.