HAL
open science

Oculopharyngeal muscular dystrophy: Recent advances in the understanding of the molecular pathogenic mechanisms and treatment strategies

Aida Abu-Baker, Guy A. Rouleau

To cite this version:

Aida Abu-Baker, Guy A. Rouleau. Oculopharyngeal muscular dystrophy: Recent advances in the understanding of the molecular pathogenic mechanisms and treatment strategies. Biochimica et Biophysica Acta - Molecular Basis of Disease, 2007, 1772 (2), pp.173. 10.1016/j.bbadis.2006.10.003 . hal-00562732

HAL Id: hal-00562732

https://hal.science/hal-00562732v1

Submitted on 4 Feb 2011

HAL is a multi-disciplinary open access archive for the deposit and dissemination of scientific research documents, whether they are published or not. The documents may come from teaching and research institutions in France or abroad, or from public or private research centers.

L'archive ouverte pluridisciplinaire **HAL**, est destinée au dépôt et à la diffusion de documents scientifiques de niveau recherche, publiés ou non, émanant des établissements d'enseignement et de recherche français ou étrangers, des laboratoires publics ou privés.

Accepted Manuscript



Oculopharyngeal muscular dystrophy: Recent advances in the understanding of the molecular pathogenic mechanisms and treatment strategies

Aida Abu-Baker, Guy A. Rouleau

PII: S0925-4439(06)00201-8
DOI: doi: 10.1016/j.bbadis.2006.10.003
Reference: BBADIS 62645

To appear in: *BBA - Molecular Basis of Disease*

Received date: 2 September 2006
Revised date: 5 October 2006
Accepted date: 6 October 2006

Please cite this article as: Aida Abu-Baker, Guy A. Rouleau, Oculopharyngeal muscular dystrophy: Recent advances in the understanding of the molecular pathogenic mechanisms and treatment strategies, *BBA - Molecular Basis of Disease* (2006), doi: 10.1016/j.bbadis.2006.10.003

This is a PDF file of an unedited manuscript that has been accepted for publication. As a service to our customers we are providing this early version of the manuscript. The manuscript will undergo copyediting, typesetting, and review of the resulting proof before it is published in its final form. Please note that during the production process errors may be discovered which could affect the content, and all legal disclaimers that apply to the journal pertain.

ACCEPTED MANUSCRIPT

Oculopharyngeal muscular dystrophy: recent advances in the understanding of the molecular pathogenic mechanisms and treatment strategies

Aida Abu-Baker and Guy A. Rouleau.

Center for the Study of Brain Diseases, CHUM Research Center - Notre Dame Hospital, J.A. de Sève Pavillion, Room Y-3633, 1560, Sherbrooke Street East, Montreal, QC, H2L 4M1, CANADA

To whom correspondence should be addressed: Phone: (514) 890-8000, ext. 24699 Fax: (514) 412-7602. Email: guy.rouleau@umontreal.ca

Keywords: polyalanine, oculopharyngeal muscular dystrophy, intranuclear inclusions, poly(A) binding protein nuclear 1.

ACCEPTED MANUSCRIPT

ACCEPTED MANUSCRIPT

Abstract

Oculopharyngeal muscular dystrophy (OPMD) is an adult-onset disorder characterized by progressive eyelid drooping, swallowing difficulties and proximal limb weakness. OPMD is caused by a small expansion of a short polyalanine tract in the poly (A) binding protein nuclear 1 protein (PABPN1). The mechanism by which the polyalanine expansion mutation in PABPN1 causes disease is unclear. PABPN1 is a nuclear multi-functional protein which is involved in pre-mRNA polyadenylation, transcription regulation, and mRNA nucleocytoplasmic transport. The distinct pathological hallmark of OPMD is the presence of filamentous intranuclear inclusions (INIs) in patient's skeletal muscle cells. The exact relationship between mutant PABPN1 intranuclear aggregates and pathology is not clear. OPMD is a unique disease sharing common pathogenic features with other polyalanine disorders, as well as with polyglutamine and dystrophic disorders. This chapter aims to review the rapidly growing body of knowledge concerning OPMD. First, we outline the background of OPMD. Second, we compare OPMD with other trinucleotide repeat disorders. Third, we discuss the recent advances in the understanding of the molecular mechanisms underlying OPMD pathogenesis. Finally, we review recent therapeutic strategies for OPMD.

ACCEPTED MANUSCRIPT

ACCEPTED MANUSCRIPT

1. Oculopharyngeal muscular dystrophy (OPMD) background

OPMD (MIM 164300) is an autosomal dominant, adult-onset disease that usually starts in the fifth or sixth decade of life [1-3]. The disease is characterized by progressive eyelid drooping (ptosis), swallowing difficulties (dysphagia), and proximal limb weakness. OPMD was first described in a French-Canadian family in 1915 [4], and was recognized as a distinct disease in 1962 [5]. OPMD has a world-wide distribution and has been reported in at least 33 countries [6-16]. The largest OPMD cluster is in the French-Canadian population, where the estimated prevalence is 1:1000 [17-20], whilst its highest prevalence is amongst the Bukhara Jews in Israel (~1:600). In Europe, the estimated prevalence is 1:100 000 [21]

Filamentous intranuclear inclusions (INIs) in muscle fibers of OPMD patients are the pathological hallmark of this disease [22].

1.1 OPMD symptoms

The symptoms of OPMD, recently reviewed by [23]**,** usually start insidiously and become manifest in the fifth or sixth decade, with a slowly progressive course; eventually, beyond the age of 70, all patients are symptomatic [24]. The main symptoms are ptosis and dysphagia due to weakness of the levator palpebrae and pharyngeal muscles. Although other extraocular muscles may become gradually involved, complete external ophthalmoplegia is rare and intrinsic eye (ciliary, sphincter) muscles are not affected [20]. Ptosis is always bilateral, but may be asymmetrical. Upon progression of ptosis, patients try to compensate their limitation of the visual field by contracting the frontal muscle and reclining the head. The symptoms of dysphagia in OPMD typically are noticed first for solid foods. Later on, fluids may become difficult to swallow as well. Weakness and atrophy of the tongue can be observed in the vast majority of patients [25].

Disease progression varies from one individual to another. Complications include choking, regurgitation, aspiration and pneumonia [26]. Consecutive aspiration pneumonia, together with malnutrition or even starvation, are the leading causes of death in patients with OPMD. However, these events mostly occur at a later

ACCEPTED MANUSCRIPT

age and life expectancy seems not to be shortened, although quality of life may be substantially impaired during the last years of life. The myopathic process may become manifest with several symptoms other than ptosis and dysphagia, such as dysarthrophonia, proximal weakness and facial weakness [27]. A small number of patients in their late sixties will need a wheelchair [3,25], while others in their eighties present no significant limb weakness.

OPMD is a myopathy, which affects all voluntary muscles and appears to spare smooth and cardiac muscles. The muscle involvement is specific, symmetric and its severity, in descending order, is: levator palpebrae, tongue, pharynx, extraocular muscles, iliopsoas, adductor femoris, gluteus maximus, deltoid and hamstrings [26].

No medical treatment is presently available for OPMD. Surgical treatments are used to correct the ptosis [28] and improve swallowing [29,30] in moderately to severely affected individuals. However, ptosis and dysphagia typically will recur within five to fifteen years after the surgery.

1.2 OPMD genetics

OPMD is usually inherited as an autosomal dominant trait with complete penetrance and without gender preference. The OPMD locus was mapped to chromosome 14q11.2-q13 by linkage analysis [17], and has been confirmed by others [11,31,32]. OPMD is caused by expansions of the short (GCG) trinucleotide repeat in the coding sequence of the poly(A) binding protein nuclear 1 (PABPN1, also known as PABP2) gene [33]. The coding sequence of PABPN1 comprises seven exons. Dominant OPMD is caused by an expansion of a GCG trinucleotide repeat in the first exon [33]. The normal *PABPN1* gene has a $(GCG)_6$ repeat encoding a polyalanine (polyA) stretch at the 5' end, while in OPMD patients this repeat is expanded to $(GCG)_{8\text{-}13}$. Due to the presence of a GCA GCA GCA GCG coding sequence adjacent to the $(GCG)_6$ repeat, the wild-type PABPN1 protein has a 10 A stretch, whereas the mutated PABPN1 in dominant OPMD has 12 to 17 alanines in the N-terminal domain [33]. Interestingly, homozygosity for a $(GCG)_7$ allele leads to an autosomal recessive

ACCEPTED MANUSCRIPT

form of OPMD. The worst OPMD phenotype has been observed in patients homozygous for an autosomal dominant mutation in PABPN1 [34].

1.3 Neurological involvement in OPMD

To date OPMD is considered as a primary myopathic disorder and there is little morphologic evidence for neurogenic etiology, though the peripheral nervous system (PNS) seems to be affected in some rare cases [35]. The first of such cases reportedly presented a severe depletion of myelinated fibers in endomysial nerve twigs of extraocular, pharyngeal and lingual muscles pointing to neurogenic changes in these muscles and suggesting nerve involvement [35]. In accordance with these pioneering findings, other more recent reports showed PNS alterations in members of an OPMD family [36].

The existence of a concomitant axonal sensorimotor neuropathy in OPMD patients has also been reported [32,35,37-43]; more interestingly, one case showed involvement of the CNS [44]. Nevertheless, it remains unclear whether the neuropathy is causatively related to OPMD or whether it is a coincidental disorder in OPMD patients, or simply a process of ageing.

Recently, more evidence has emerged suggesting neurological involvement in OPMD. Boukriche et al. reported the case of an OPMD patient who developed a severe chronic axonal neuropathy [45]. Nakashima et al reported an OPMD patient with neurogenic features in the electrophysiological and pathological findings [46]. Recently, analysis of mitotic and postmitotic tissues in OPMD transgenic animals revealed ubiquitinated PABPN1-positive INIs in neuronal cells. Similar INIs in postmortem brain sections from an OPMD patient were also observed. These results indicate that mutant PABPN1, presumably via the toxic effects of its polyA tract, can lead to inclusion formation and neurodegeneration in both the mouse and the human [47]. These findings raise the possibility that neurogenic changes, as in polyQ diseases, may contribute to the pathophysiology of OPMD [47].

ACCEPTED MANUSCRIPT

1.4 OPMD histopathology

The histology of OPMD muscle biopsy specimens shows some particular changes: 1) small angulated fibres which may represent an ageing-related concomitant denervation process, and 2) rimmed vacuoles within the muscle fibres which most probably derive from an autophagic process (similar vacuoles are seen in inclusion body myositis). Electron microscopy reveals tubulofilamentous inclusions of about 8.5 nm in diameter within the nuclei of muscle fibres, which correspond to INIs and seem to be the most specific diagnostic sign of OPMD, after genetic testing [48]. These inclusions consist of mutated, aggregated PABPN1 (see below).

Other histological changes are common to many muscular dystrophies (loss of muscle fibres, abnormal variation in fibre size, increase in the number of nuclei, expanded interstitial fibrous and fatty connective tissue). Although probably all skeletal muscles are affected, the histologic changes are most pronounced in extraocular, lingual, pharyngeal and diaphragmatic muscles in autopsy findings [20].

1.5 Diagnosis of OPMD

To confirm the diagnosis in patients clinically suspected of having OPMD molecular genetic testing is performed. Considering DNA sequencing as the analytical gold standard, it is estimated that >99% of patients diagnosed with severe, autosomal dominant OPMD actually carry a pathogenic PABPN1 triplet repeat expansion [23].

Before genetic testing became available, the diagnosis of OPMD was made on purely clinical grounds. The presence of slowly progressive ptosis and dysphagia, an onset of symptoms after age 40, and a positive family history were pathognomonic. Later on, light and electron microscopy studies of muscle biopsy specimens provided further diagnostic confirmation by the presence of rimmed vacuoles within muscle fibres and OPMD-specific nuclear inclusion bodies. Additionally, electro(neuro)myographic studies were used to exclude other neuromuscular disorders.

ACCEPTED MANUSCRIPT

1.6 Poly (A) binding protein nuclear 1 (PABPN1): OPMD gene product

Wild-type PABPN1 is an abundant nuclear protein, with wide-spread staining in the nucleoplasm [49]. It is mostly concentrated in discrete nuclear domains called 'speckles' (domains within the nucleus that are enriched in splicing factors, poly(A) RNA, and other components of the mRNA processing machinery). Wild-type PABPN1 is a well studied protein. The predicted molecular weight of wild-type PABPN1 is 32.8 kDa, but the real molecular weight is higher due to post-translational modifications-closer to 50 kDa [51]. Wild-type PABPN1 is a multi-domain protein of 306 amino acids [51] that comprises a polyA stretch of 10 consecutive Ala and a proline-rich region in the acidic N-terminus. The residues located between positions 125 and 161 are predicted to form an α-helix structure which is required for the stimulation of the poly(A) polymerase [52]. The central region of wild-type PABPN1 also includes a putative ribonucleoprotein (RNP)-type RNA binding domain (RBD) (approximately from Met^{161} to Thr^{257} and 3) [51]. The basic C-terminal domain of wild-type PABPN1, which is rich in dimethylated arginine residues, contains a nuclear localization signal (NLS) (amino acids 249-306) (Figure 1) that interacts with transportin (a nuclear transport receptor) [51,53]. The association of wild-type PABPN1 and transportin occurs in a Ran GTP-sensitive manner, suggesting an active transport pathway [53]. Two potential oligomerization domains (ODs) of PABPN1 were mapped out. The first, OD1 (aa 155-294), overlaps with the RNA binding domain, and the second, OD2 (aa 264-306) overlaps with the NLS, is localized at the C-terminus of PABPN1 [54] (Figure 1).

All eukaryotic mRNA molecules are post-transcriptionally modified at their 3'-ends by addition of a poly(A) tail, which binds two different proteins: PABPN1 (nuclear), and PABPC (cytoplasmic). While wild-type PABPN1 stimulates the rapid and processive polymerization of the poly (A) tail in the nucleus [55,56], PABPC in the cytoplasm has a role in the initiation of translation and in the regulation of mRNA decay [57]. Several studies suggested that PABPC is a shuttling protein, entering the nucleus and being exported to the cytoplasm in

ACCEPTED MANUSCRIPT

association with mRNA [58]. Wild-type PABPN1 is also able to perform nucleocytoplasmic shuttling, as demonstrated by heterokaryon assays [59].

PABPN1 is an abundant nuclear protein, binds with high affinity to the poly(A) tail of mRNA and is involved in mRNA polyadenylation [55]. Polyadenylation is a two-step reaction whereby endonucleolytic cleavage of the nascent mRNA transcript is followed by the addition of ~250 adenylate residues to the up-stream cleavage product [60-62]. Poly(A) tail synthesis is catalyzed by poly(A) polymerase through interaction with CPSF, the cleavage and polyadenylation specificity factor. However, this process is slow and inefficient, and the length of poly(A) tail is poorly controlled. Adding PABPN1 to this reaction will stimulate processive poly(A) addition and control the size of the tail to be ~250 nucleotides in length [55,56,63]. The RNA binding domain of PABPN1 mediates its specific binding to the poly(A) tail of mRNA [50]. Poly(A) bound PABPN1 forms both linear filaments and discrete-sized, compact oligomeric particles *in vitro* [64]. Titration and gel retardation assays indicated that 12 adenylate residues are required for high affinity RNA binding and the packing density on the poly(A) tail is approximately 15 adenylate residues per PABPN1 molecule [50]. However, PABPN1 tends to form oligomers even in the absence of mRNA [51].

1.7 Intranuclear inclusions (INIs): OPMD pathological hallmark

In 1980, Tome and Fardeau studied deltoid muscle biopsies from OPMD patients by light and electron microscopy and identified for the first time a unique accumulation of nuclear filaments in OPMD muscle fibers [22]. Later reports further confirmed the presence of the intranuclear inclusions in muscle nuclei [65-70]. Under an electron microscope, OPMD inclusions can be visualized as filaments that have a tubular appearance with an outer diameter of 8.5 nm, an inner diameter of 3 nm and a length of $\leq$0.25 μm. Filamentous intranuclear inclusions are considered the pathological hallmark of OPMD [22,48]. The frequency of nuclei in which filament inclusions were seen varied from 2% to 5% per slide [3]. Only INI of the described size are considered the hallmark of OPMD, as they differ from all other types of inclusions so far described within

ACCEPTED MANUSCRIPT

nuclei of muscle fibers [71]. This finding can be considered as a criterion in making the definite diagnosis of OPMD.

Several *In vitro* OPMD cell culture models have shown that mutant PABPN1 over-expression is characterized by the accumulation of nuclear aggregates [54,72,73,74]. The composition of intranuclear inclusions might reflect the process of INI formation and contribute to the pathogenesis of OPMD. Mutant PABPN1 aggregates have been shown to contain mRNA [53] and various proteins, including heat shock proteins and components of the ubiquitin-proteasome pathway [72,73]. Recently, we have shown that the promyelocytic leukemia (PML) protein, a major component of nuclear bodies, strongly co-localized to intranuclear aggregates of mutant PABPN1 [75]. Some have hypothesised that sequestration into aggregates may impair the function of these proteins and perturb their downstream pathways. However, it is not clear if their presence in aggregates compromises protein function. In fact, many of the proteins demonstrated to be in aggregates are upregulated as a consequence of mutant PABPN1 expression [76]. In addition, it is possible that interaction may be transient and proteins may be able to diffuse in and out of mutant PABPN1 aggregates.

OPMD is one of a number of diseases that are associated with the formation of aggregates in affected tissues. Whether these aggregates are pathogenic, or the consequence of a molecular defense mechanism, remains controversial in these diseases. In the past, some reports provided data suggesting that mutant PABPN1 nuclear aggregates may promote cell death in OPMD [54,72]**.** Despite these observations, the role of mutant PABPN1 polyA aggregates as the primary causal event remains ambiguous. A recent report has shown that polyQ aggregates may have protective effects in Huntington's disease [77]. The debate is complex as it is difficult to differentiate experimentally between the effects of large aggregates, oligomeric species and the dynamic aggregation process itself. The polyA expansion mutation is not absolutely required for the aggregation of mutant PABPN1. Wild-type PABPN1 forms aggregates when transfected into culture cells and expressed at high levels [54,72,78] and aggregates comprising

ACCEPTED MANUSCRIPT

wild-type PABPN1 have been observed in oxytocin-producing neurons from normal rat hypothalamus [79].

Time-lapse experiments performed in an adenoviral OPMD model have recently indicated that INIs of mutant PABPN1 are dynamic structures and can disassemble during mitosis [80]. The dynamism of mutant PABPN1 INIs during cell cycle was corroborated in recent studies [78,79]. Apoptosis was also observed in a small proportion of cells that all had INIs. The authors suggest that as OPMD is a late onset disease, this slow but constant cell death mechanism could be implicated in OPMD pathology [80]. We have recently generated similar results in our OPMD cell model (Figure 2) (unpublished data).

2. OPMD is a trinucleotide repeat disorder

Many human pathologies involve trinucleotide expansions. Trinucleotide repeat diseases are caused by expansion of trinucleotide repeats in a gene. They can be classified according to the amino acid they code for: polyglutamine (polyQ) repeat diseases, polyalanine (A) repeat diseases. OPMD is a very unique polyalanine disease sharing common features with other polyQ disorders, as well as with polyA and dystrophic disorders [81].

PolyQ diseases that are caused by $(CAG)_n$ repeat expansions represent the largest group of trinucleotide repeat diseases. PolyQ diseases include Huntington's disease (HD), spinobullbar muscular dystrophy (SBMA), spinocerebellar ataxias (SCA) types 1,2,3 (or Machado-Joseph disease MJD), 6, and 7, 10, 12 and dentatorubral pallidoluysian (DRPLA) [82]. It is worth mentioning that the affected proteins in polyQ diseases and OPMD are widely expressed yet diseases target specific tissues/cell types.

The disease course and underlying mechanisms in OPMD appear to be in some ways similar to that seen in polyQ expansion disorders as protein misfolding and subsequent aggregation appear to be central to the pathogenesis [73]. Both OPMD and polyQ diseases are coding expanded triplet diseases and both are of late onset. Both polyQ and polyA are hydrophobic amino acids which are able to form β-sheet structures and induce intracellular protein aggregation. The most

ACCEPTED MANUSCRIPT

striking difference between OPMD and polyQ diseases is the repeat length. Short expansions (>2) of the polyA stretch in wild-type PABPN1 cause OPMD, while much longer expansions of polyQ (>35) are required to cause neurodegenerative diseases. It is proposed that polyA is more harmful to the cell than polyQ [83,84]. Another difference is that in OPMD the pathogenic effects are mostly observed in skeletal muscle cells as opposed to neuronal tissues in the case of polyQ disorders.

PolyA tract expansions have now been described in several human diseases. At least 9 disorders are associated with polyA expansions (Table 1). Examples of PolyA disorders include: Synpolydactyly [85,86], cleidocranial dysplasia [87], familial holoprosencephaly [88], hand–foot–genital syndrome [89], blepharophimosis/ptosis/epicanthus inversus syndrome type II [90], X-linked mental retardation and epilepsy [91], X-linked mental retardation with growth hormone deficiency [92], congenital central hypoventilation syndrome [93] and oculopharyngeal muscular dystrophy [33].

An Alanine expansion was first identified as the disease-causing mutation in synpolydactyly syndrome (SPD). Since, similar mutations have been described in eight additional disorders. In contrast to polyQ expansions which cause late onset neurodegenerative diseases, all polyA disorders, except for OPMD, result in early developmental defects, such as malformations of the brain, digits and other structures. All the mutated genes in polyA diseases, except poly(A) binding protein nuclear 1 (*PABPN1*) which causes OPMD, code for transcription factors that play important roles in early development. Furthermore, the size of the alanine expansion leading to a disease phenotype in OPMD is the smallest ever described in polyA diseases (Table 1)

Another contrast between polyA and polyQ is the mutational mechanism. Polymerase slippage has long been assumed to be the mechanism of expansion in polyQ diseases. In contrast, polyA expansions are thought to arise from unequal allelic homologous recombination during meiosis and/or mitosis [94]. Expanded polyA are meiotically and mitotically stable, whereas expanded polyQ tracts tend to be meiotically and mitotically unstable. PolyQ repeats show both

ACCEPTED MANUSCRIPT

somatic and germline instability. PolyA tracts show only a low degree of polymorphism [95].

Recent findings in OPMD, as well as other polyA diseases, indicate that protein misfolding and aggregation may be common features shared with other polyQ diseases. Until last year, among the family of polyA expanded proteins, PABPN1 was the only member believed to form intranuclear inclusions (INIs). Recently, it has been shown for at least 5 other polyA diseases that mutant protein forms aggregates [96-98]. Recent reviews focused on the details of polyA diseases [24,81,95,99,100,101].

3. OPMD recent molecular mechanisms

Different cellular and animal models, including mice and *Drosophila*, were generated to study the pathological mechanisms underlying OPMD [54,73,103,104,105]**.**

The mechanism by which the polyA expansion mutation in PABPN1 causes disease is unclear. However, the mutation is thought to confer a toxic gain-of-function on the protein. Repeat length appears to correlate with disease severity. Widespread expression of the human PABPN1 gene in transgeneic mice yielded polyA length-dependent muscle pathology, including vacuoles, central nuclei, and numerous dystrophic changes [104,105]. In these mice, muscle disease is progressive and associated with INIs formation [104,105].

The role of the oligomerization of PABPN1 in OPMD pathogenesis was documented [54]. Among the recent models put forward to better understand OPMD, some hypothesize that either involvement of the ubiquitin-proteasome pathway (UPP) [73] or of the cellular RNA metabolism [53] appears to contribute to the disease. OPMD intranuclear aggregates were shown to sequester wild-type PABPN1 [53], poly (A) RNA [53], hnRNP proteins [106], and components of the UPP and heat shock proteins (HSPs) pathways [53,72,73]. The role of the nucleus in OPMD pathogenesis has also been recently investigated [75] and the apoptosis pathway has been implicated in OPMD pathogenesis [103].

ACCEPTED MANUSCRIPT

3.1 PolyA-β sheets in OPMD pathogenesis

The biophysical properties of polyA were suggested to play an important role in the accumulation of mutant PABPN1 in OPMD muscle nuclei [24].

PolyA stretches have been found in 494 human proteins [95]. Under physiological conditions *in vitro*, alanine stretches form ß pleated sheet fibrillar macromolecules that are extremely resistant to chemical denaturation and enzymatic degradation [107,108]. Above a threshold of 19 alanines, the polypeptide aggregates and forms intracellular inclusions, leading to cell death [109]. Interestingly, alanine stretches within proteins do not exceed 20 alanines in humans making them relatively short homopolymeric repeats, when compared with polyQ repeats [101].

PolyA are frequent in eukaryotic cells, and preferentially found in transcription factors (TFs); 36% of proteins containing polyA stretches in humans are TFs [95,110]. Alanine tracts have been regarded as flexible spacer elements located between functional domains of the protein and therefore essential to protein conformation, protein–protein interactions and/or DNA binding [86,110].

Expanded polyQ and polyA protein repeats are thought to destabilize the native configuration of the mutant protein resulting in the formation of protein aggregates within the cell. It appears likely that an increase of alanine repeat length above 12–22 results in misfolding and/or aggregation of the protein due to biophysical limitations [111].

It seems surprising that extension of the alanine repeat by two residues in mutant PABPN1 should have such a drastic effect as causing OPMD. To find out whether alanine repeats tend to aggregate, Perutz et al. made the peptide $D_2A_{10}K_2$ and measured its Circular Dichroism (CD) spectra in solution as a function of pH. The spectra showed that the peptide forms α-helices at all pHs, with no sign of aggregation. α-Helices can adhere to each other by forming coiled coils, but it is most unlikely that expansion from six to eight alanines would have this effect. Perutz suggested the following interpretation: alanine repeats are hydrophobic and would, therefore, occupy internal positions in the protein. An

ACCEPTED MANUSCRIPT

additional alanine would be a misfit that lowers the free energy barrier to unfolding of the protein [111].

In a recent protein structural study, wild-type PABPN1 was shown to slowly form filaments, while mutant PABPN1 formed filaments more quickly. Structural analysis of the fibrils indicated antiparallel β-sheets [112].

In another recent study on polyA repeats, Shinchuk *et al*., analyzed the self-assembly of synthetic poly-(L-alanine) peptides containing 3-20 residues. They found that the conformational transition and structure of polyA assemblies in solution are not only length-dependent but also are determined by concentration, temperature, and incubation time. No β-sheet complex was detected for those peptides characterized by n < 8, where n are number of alanine residues [113]. Unlike the typical tinctorial properties of amyloid fibrils, polyalanine fibrils did not show fluorescence with thioflavin T or apple-green birefringence with Congo red. Shinchuk *et al.* postulated that the high stability of the macromolecular fibrills of an expanded polyA stretch could form a core β-sheet structure that mediates the intermolecular association of mutant proteins into fibrillar inclusions in human pathologies [113].

Two recent reports by Hung and Hall [114,115] investigated the kinetics simulation of fibril formation of polyA peptides. Fibril formation appeared to be a conformational conversion process in which small amorphous aggregates --> β-sheets --> ordered nucleus --> subsequent rapid growth of a small stable fibril or protofilament [114,115].

We have recently proposed a potential molecular mechanism for OPMD pathogenesis [21]. The expansion of the polyA repeat in mutant PABPN1 causes misfolding and exposes the hydrophobic alanine stretch, which would otherwise be buried inside the protein in the wild type form. The longer the polyA stretch is, the more exposed the hydrophobic region is.

ACCEPTED MANUSCRIPT

3.2 Oligomerization of mutant PABPN1 in OPMD pathogenesis

Wild-type PABPN1, when bound to poly(A) RNA, forms both linear filaments and discrete-sized, compact oligomeric particles *in vitro* [50]**.** Oligomerization of wild-type PABPN1 is mediated via two potential oligomerization domains (ODs), one in the middle of the protein and the other at the C-terminus [54]. In this study we provided evidence, in cell culture, that oligomerization of mutant PABPN1-A17 plays an important role in the formation of INIs and cell death in OPMD. Inactivating oligomerization of mutant PABPN1-A17 by deletions in either of the ODs prevented nuclear protein aggregation and significantly reduced cell death [54]. It should be noted that ODs do not overlap with the alanine stretch of PABPN1. These findings suggest that oligomerization of mutant PABPN1 plays a crucial role in the formation of OPMD nuclear protein aggregation, while the expanded polyA stretch is necessary but not sufficient to induce OPMD protein aggregation.

Both Congo red and doxycycline (anti-amyloid compounds) have been found to reduce aggregation and cell death in cell models of OPMD [116]. The parallel protection that Congo red affords against the cytotoxicity of expanded polyQ [117] and polyA is consistent with the idea that abnormal protein aggregation and accumulation may be deleterious in all intracellular amyloidoses, irrespective of the primary mutation. Recent work on a transgenic model of OPMD provided evidence that doxycycline (anti-amyloid compound) can be used as a treatment in OPMD, suggesting that this drug is able to inhibit oligomerization induced by mutant PABPN1 [103].

3.3 Transcription dysregulation in OPMD pathogenesis

The transcription of muscle-specific genes in OPMD may be compromised. One group suggested that the continuous remodeling of adult extraocular muscles leading to the accumulation of defective mRNA as a consequence of mutant PABPN1 production could be an explanation for selective craniofacial involvement in OPMD [118].

ACCEPTED MANUSCRIPT

A recent study has shown that ectopic expression of mutant PABPN1 in a muscle cell culture model reduced expression of several muscle-specific proteins including α-actin, muscle creatine kinase, and two myogenic transcription factors, myogenin and MyoD [119]. These findings should be confirmed in OPMD mice models.

Recent reports support wild-type PABPN1's involvement in transcription. First, wild-type PABPN1 directly interacts with the Ski-interacting protein (SKIP) [120], a muscle transcription regulatory protein which, along with MyoD, regulates muscle cell differentiation [120]. Second, normal PABPN1 associates with RNA polymerase II during transcription and accompanies the released transcript to the nuclear pore [121]. Modifications of these processes by expanded PABPN1 might play an important role in OPMD.

We have also recently found that both transcription factors CBP and p300 (histone acetyltransferases) are sequestered into protein aggregates of mutant PABPN1 in OPMD Hela and muscle models (Figure 3), reinforcing the role of transcriptional dysfunction in OPMD (unpublished data).

3.4 Involvement of Ubiquitin-proteasome pathway (UPP) and molecular chaperones in OPMD pathogenesis

The situation in OPMD appears to have many parallels with polyQ diseases and more recently with polyA diseases, raising the possibility that misfolded, aggregate-prone proteins may perturb similar pathways, irrespective of the nature of the mutation or protein context.

The appearance of ubiquitinated aggregates implies an underlying incapacitation of the cellular chaperones and proteasome machinery, which normally function to prevent the accumulation of misfolded proteins.

INI formation in mutant PABPN1 may result from an imbalance between protein refolding and aggregation. Different observations converge to suggest that a gain of function of PABPN1 may cause the accumulation of nuclear filaments observed in OPMD [22]. The involvement of the ubiquitin-proteasome pathway

ACCEPTED MANUSCRIPT

and molecular chaperones in OPMD is well documented in several studies. First, Calado et al. showed that OPMD-specific nuclear inclusions in deltoid muscle from OPMD patients recruit, in addition to wild-type PABPN1, ubiquitin and subunits of the proteasome [53]. Second**,** human, yeast, and chemical chaperones were shown to reduce both aggregation and cell death in an OPMD cell model without affecting the levels of mutant PABPN1 [72,73]. Third, Abu-Baker et al. presented evidence that the UPP and molecular chaperones are part of the cellular response to mutant polyA-containing PABPN1. Both HSP70 and ubiquitin were shown to be recruited into INIs of OPMD in cell-based models and human tissue. The proteasome inhibitor 'lactacystin' resulted in an enhancement of both nuclear and perinuclear protein aggregation that are associated with cellular toxicity. Moreover, overexpression of molecular chaperones (HSP40 and HSP70) suppressed protein aggregation and toxicity by increasing the solubility of mutant PABPN1-A17 [73]. Ravikumar et al**.** also demonstrated that epoxomicin (another proteasome inhibitor) did increase the proportion of COS-7 cells expressing green fluorescent protein-A19 (GFP-A19) aggregates [122].

Recent evidence has shown that over expression of heat shock proteins HSP70 and HSP40 in cells expressing mutant PABPN1 increases the solubility of the mutant PABPN1 protein, which consequently reduces the formation of INIs and cell toxicity [73]**.** Since these HSPs can promote refolding, solubilization, and degradation of damaged polypeptides, the loss of this protective response combined with aging in skeletal muscle might seriously compromise the cell's capacity to cope with the mutant PABPN1. Recently, microarray analysis of an adenoviral model of OPMD revealed that HSP70 was upregulated, suggesting that there is no compromise of HSP70 expression [76].

3.5 Possible impairment of mRNA transport or processing

To find out whether a loss-of function underlies OPMD, Calado *et al.* measured the steady-state poly(A) tail length in both OPMD and normal myoblasts. Surprisingly, there were no significant differences between the steady-state poly(A) tail length in OPMD and normal myoblasts. However, poly(A) RNA is

ACCEPTED MANUSCRIPT

detected in OPMD inclusions at higher concentrations than in the rest of the cell. These findings suggest that mRNA may be trapped in the inclusions. If this is the case, then the inclusions may interfere with mRNA export and the cellular traffic of poly(A) RNA. As a result, depending on the relative transcription and turnover rates of different mRNA species, in particular those that are specifically expressed in severely affected muscles, some protein levels may become inadequate and contribute to cell death [53].

We have recently identified two wild-type PABPN1 interacting proteins, the heterogenous nuclear ribonucleoproteins (hnRNP) A1 and A/B [106]. These hnRNPs are mRNA binding proteins that are involved in both mRNA processing and export from the nucleus to the cytoplasm [123]. Both hnRNP A1 and A/B can interact (via the C-terminus) with wild-type PABPN1 and they also co-localize with mutant PABPN1 in OPMD INIs [106]. More recently, mutant PABPN1 nuclear inclusions were found to sequester other proteins involved in mRNA biogenesis, such as poly(A) polymerase (PAP) [78]. It has also been proposed that wild-type PABPN1 plays a role in mRNA export [59]. The interaction between wild-type PABPN1 and hnRNP proteins might be required for the packaging of mRNA for the export process. Together, these observations and a recent report of OPMD INIs sequestering mRNA [53] suggest that OPMD INIs may be toxic by acting as “mRNA traps” interfering with the mRNA nucleocytoplasmic export.

Recent work on OPMD revealed that mutant PABPN1 overexpression leads to upregulating of genes encoding proteins that are sequestered in OPMD nuclear inclusions [76]. Interestingly, many of the upregulated genes encode proteins involved in RNA processing, mRNA splicing, packaging and transport [76].

Recently, it has been shown that the formation of mutant PABPN1 inclusions requires binding to poly(A), and interfering with any of the protein domains required for stimulation of poly(A) polymerase prevents the formation of inclusions [78]. Site-directed mutations within the RNA binding domain (RBD) of PABPN1 led to mutant protein no longer forming INIs [78].

ACCEPTED MANUSCRIPT

3.6 The role of RNA binding domain (RBD) of mutant PABPN1 in OPMD pathogenesis

Recently, Simonelig's group has suggested that the RNA-binding domain is crucial for OPMD associated toxicity [105]. Simonelig's group [105] has created a *Drosophila* model of OPMD that recapitulates the features of the human disorder: progressive muscle degeneration, with muscle defects proportional to the number of alanines in the tract, and formation of mutant PABPN1 nuclear inclusions. Strikingly, in their *Drosophila* model, the polyA tract was not absolutely required for muscle degeneration, whereas another domain of PABPN1, the RNA-binding domain and its function in RNA binding, are required. The authors suggest that OPMD does not result from polyA toxicity, but from an intrinsic property of mutant PABPN1 dependent on the RBD. They also identified several suppressors of the OPMD phenotype. For example, molecular chaperone HSP70 and anti-apoptotic protein P35 were efficient suppressors [105]. It is important to mention that there is an overlap between the RBD of wild-type PABPN1 and the oligomerization domains in wild-type PABPN1 that have been characterized by our group [54]. The oligomerization domains of mutant PABPN1 were shown to be relevant in OPMD associated toxicity *in vitro* [54]. Thus, the toxicity may be dependent on aggregation, which is dependent on the same domains as the RNA binding.

3.7 The role of the nucleus in OPMD pathogenesis

It is becoming increasingly clear that, although the expanded polyA stretch in mutant PABPN1 is crucial to initiate OPMD pathogenesis, residues outside the polyA stretch also play important roles in the disease [75,105]. We have recently also presented evidence that the nuclear environment is necessary for mutant PABPN1 inclusion formation and cellular toxicity [75]. This was achieved by inactivating the mutant PABPN1 nuclear localization signal (NLS) and by generating full-length mutant PABPN1 fused to a strong nuclear export signal. Targeting mutant PABPN1 to the cytoplasm resulted in a significant suppression

ACCEPTED MANUSCRIPT

of both intranuclear aggregate formation and cellular toxicity, two hallmarks of OPMD [75].

3.8 Apoptosis in OPMD pathogenesis

Recently, a study on OPMD transgenic mice demonstrated that doxycycline reduces susceptibility of cells to pro-apoptotic insults. Doxycycline treatment influenced Bax levels, as this protein permeabilizes mitochondria, leading to cytochrome *c* release and subsequent activation of caspases 9 and 3, after various pro-apoptotic insults [103]. Bax levels were elevated in the muscle of A17 mice, compared to wild-type littermates, and Bax levels in OPMD mice were reduced by doxycycline. Anti-apoptotic protein P35 was also efficient suppressors in OPMD *drosophila* model [105]. Indeed, other strategies that reduce apoptosis may be effective in OPMD; lithium decreases the toxicity induced by expression of a polyA expansion (tagged to GFP) in a *Drosophila* model, at least partially via activation of the anti-apoptotic wnt pathway [124].

4. Treatments advances for OPMD

4.1 Trehalose

The disaccharide chemical chaperone trehalose has been used effectively to alleviate symptoms in a mouse model of Huntington's disease [125]. Trehalose is thought to elicit its effect by binding and stabilizing partially folded polyQ proteins and inhibiting the formation of aggregates. In OPMD cell models [126] it was shown that trehalose decreases the aggregation and toxicity of mutant PABPN1 [126]. Furthermore, treatment of an OPMD mouse model with trehalose resulted in the attenuation of muscle weakness, decreased aggregate formation and a reduced number of TUNEL-positive nuclei in skeletal muscle fibres [126].

4.2 Single-domain intracellular antibody

Verheesen *et al.*, have recently isolated and characterized a diverse panel of single-domain antibody reagents (VHH), recognizing different epitopes in PABPN1. The antibody reagents specifically detected endogenous PABPN1 in

ACCEPTED MANUSCRIPT

cell lysates on Western blot and labeled PABPN1 in cultured cells and muscle sections. When expressed intracellularly as intrabodies in a cellular model for OPMD, aggregation of mutant PABPN1 was prevented in a dose-dependent manner. More importantly yet, these intrabodies could also reduce the presence of previously existing aggregates [127].

4.3 Induction of HSP70 expression

The reduction of mutant PABPN1 aggregation by chemical or molecular chaperones (e.g. HSP70, HSP40) correlates with decreased death in OPMD cell models [72,73].

Recently, Wang *et al*. tested four pharmacological agents for their ability to induce HSP70, and reduce mutant PABPN1 aggregation in a Hela cell culture model. They showed that exposure to moderate levels of $ZnSO_4$, 8-hydroxyquinoline, ibuprofen and indomethacin produced a robust stress response resulting in the induction of HSP70 in Hela cells expressing the mutant PABPN1-A17 as a GFP fusion protein [128]. A concomitant reduction of cell death in drug-treated mutant PABPN1 expressing cells was also observed [128]**.** Zinc sulfate ($ZnSO_4$) is an essential mineral nutrient. 8-hydroxyquinoline is an anti-microbial anti-parasitic agent used to treat infections in humans. Ibuprofen and indomethacin are well-known anti-inflammatory drugs.

4.4 Doxycycline (anti-aggregation and anti-apoptotic)

Rubinsztein's group has developed a transgenic mouse model of OPMD that manifests progressive muscle weakness accompanied by intranuclear aggregates and TUNEL-stained nuclei in skeletal muscle fibers. The onset and severity of these abnormalities were substantially delayed and attenuated by doxycycline treatment, which may exert its therapeutic effect by reducing aggregates and by distinct anti-apoptotic properties. The authors suggest that doxycycline may represent a safe and feasible therapeutic for OPMD [103].

ACCEPTED MANUSCRIPT

4.5 Other therapies: Myoblast transfer therapy

Using telomere measurements, *Mouly et al.* have shown that the proliferative capacity of satellite cells is dramatically decreased in muscle dystrophies, thus hampering the possibilities of autologus cell therapy [129]. The authors concluded that autologous cell therapy can be applied to specific targets when there is a source of satellite cells which is not yet exhausted. This is the case of OPMD, and patients suffering from this disease agreed to participate in a clinical trial using autologous satellite cells isolated from muscles spared by the disease. This resulted in a clinical trial for the pharyngeal muscles of patients suffering from OPMD. The results of this trial will not be available for 2 years [129].

5. Conclusions

Despite all the advances in OPMD research, there are still fundamental questions that need to be addressed for better understanding of the pathophysiology of OPMD: (1) *Which is the toxic form of the mutant protein: soluble or insoluble, or both? Does aggregation have a causative role in OPMD-associated cyto-toxicity? Does it have a role in disease progression, or is this process in some way protective? (2) Why is the muscle the most affected tissue in OPMD disease? (3) Is the underlying mechanism of expanded polyA toxicity in OPMD a loss or gain of function? (4) Are there mainly primary or parallel mechanisms acting together in OPMD?*

Understanding the molecular pathogenic mechanisms underlying OPMD will help to identify the appropriate treatments for this disease.

Acknowledgments

We thank Dr. Claudia Gaspar for her careful reading of this review.

ACCEPTED MANUSCRIPT

Table and Figure legends:

Table 1: Description of Polyalanine diseases.

Figure 1: Domains in wild-type PABPN1: The structural organization of wild-type PABPN1 is schematically illustrated.

Wild-type PABPN1 consists of the following domains: a short alanine stretch, a proline-rich region, an α-helical region, RNA binding domain overlaps with the first oligomerization domain, and a nuclear localization signal (NLS). The amino acid sequence of the C-terminal NLS domain is indicated.

Figure 2: Dynamics of mutant PABPN1 intranuclear aggregates. *In vivo* time-lapse images of HeLa cells transfected with mutant PABPN1-A17 showing nuclei containing protein aggregates (KCl-resistant) undergo cell division. Time is indicated in hours.

Figure 3: Both CBP and p300 transcription factors are recruited into protein aggregates of mutant PABPN1-A17 in both OPMD cellular models. Immunocytochemical detection on Hela and C2C12 cells transfected with mutant PABPN1-A17 (green), 48 h post-transfection. CY3 conjugated secondary antibody (red) was used to immunodetect CBP and p300 (top middle, bottom middle). Merging (yellow) of the two signals (red and green) illustrates co-localization.

ACCEPTED MANUSCRIPT

References

[1] K. Fried, A. Arlozorov, and R. Spira, Autosomal recessive oculopharyngeal muscular dystrophy, J. Med. Genet. 12 (1975) 416-418.

[2] A.C. Duranceau, G. Beauchamp, G.G. Jamieson, and A. Barbeau, Oropharyngeal dysphagia and oculopharyngeal muscular dystrophy, Surgical Clinics of North America 63 (1983) 825-832.

[3] B. Brais, G.A. Rouleau, J.P. Bouchard, M. Fardeau, F.M. and Tome, Oculopharyngeal muscular dystrophy, Semin Neurol. 19 (1999) 59-66.

[4] E.W. Taylor, Progressive vagus-glossopharyngeal paralysis with ptosis: a contribution to the group family diseases, J. Nerv. Ment. Dis. 42 (1915) 129-139.

[5] M. Victor, R. Hayes, and R.D. Adams, Oculopharyngeal muscular dystrophy: familial disease of late life characterized by dysphagia and progressive ptosis of the eyelids, New Eng. J. Med. 267 (1962) 1267-1272.

[6] G. Vita, R. Dattola, M. Santoro, and C. Messina, Familial oculopharyngeal muscular dystrophy with distal spread, J. Neurol. (1983) 57-64.

[7] C.T. Lim, C.T. Chew, and S.H. Chew, Oculopharyngeal muscular dystrophy: a case report and a review of literature, Ann. Acad. Med. Singapore 21 (1992) 399-403.

[8] S.C. Blumen, P. Nisipeanu, M. Sadeh, A. Asherov, F.M. Tome, and A.D. Korczyn, Clinical features of oculopharyngeal muscular dystrophy among Bukhara Jews, Neuromuscul. Disord. 3 (1993) 575-577.

[9] P.J. Jongen, H.L. Ter Laak, and A.M. Stadhouders, Rimmed basophilic vacuoles and filamentous inclusions in neuromuscular disorders, Neuromuscul. Disord. 5 (1995) 31-38.

[10] E. Uyama, O. Nohira, D. Chateau, M. Tokunaga, M. Uchino, T. Okabe, M. Ando, and F.M. Tome, Oculopharyngeal muscular dystrophy in two unrelated Japanese families, Neurol. 46 (1996) 773-778.

[11] B.T. The, A.A. Sullivan, F. Farnebo, C.Zander, F.Y. Li, N. Strachan, M. Schalling, C. Larsson, and P. Sandstorm, Oculopharyngeal muscular dystrophy (OPMD)-report and genetic studies of an Australian Kindred. Clin. Genet. 51 (1997) 52-55.

[12] M. Fardeau, and F.M. Tome, Oculopharyngeal muscular dystrophy in France, Neuromuscul. Disord. 7 (1997) Suppl. 1, S30-S33.

[13] S.C. Blumen, P. Nisipeau, M. Sadeh, A. Asherov, N. Blumen, Y. Wirguin, O. Khilkevich, R.L. Carasso, and A.D. Korczyn, Epidemiology and inheritance of oculopharyngeal muscular dystrophy in Israel, Neuromuscul. Disord. 7 (1997) Suppl., 1, S38-S40.

[14] M. Medici, C. Pizzarossa, D. Skuk, D. Yorio, G. Emmanuelli, and R. Mesa, Oculopharyngeal muscular dystrophy in Urguay, Neuromuscul. Disord. 7 (1997) Suppl. 1, S50-S52.

[15] G. Meola, V. Sansone, G. Rotondo, F.M. Tome, and J.P. Bouchard, Oculopharyngeal muscular dystrophy in Italy, Neuromuscul. Disord. 7 (1997) Suppl. 1, S53-S56.

[16] H. Porschke, W. Kress, H. Reichmann, H.H. Goebel, and T. Grimm, Oculopharyngeal muscular dystrophy in a northern German family linked to chromosome 14q, and presenting carnitine deficiency, Neuromuscul. Disord. 7 (1997) Suppl. 1, S57-S62.

ACCEPTED MANUSCRIPT

[17] B. Brais, Y.G. Xie, M. Sanson, K. Morgan, J. Weissenbach, A.D. Korczyn, S.C. Blumen, M. Fardeau, F.M. Tome, J.P. Bouchard, and GA Rouleau, The oculopharyngeal muscular dystrophy locus maps to the region of the cardiac alpha and beta myosin heavy chain genes on chromosome 14q11.2-q13. Hum Mol Genet., 4 (1995) 429-434.

[18] G. Brunet, F.M.Tome, F. Samson, F., et al, Dytrophie musculaire oculopharyngee. Recensement des familles francaises et etude genealogique. Rev Neurol., 4 (1990) 429-434.

[19] A. Barbeau, In Symposium Uber Progressive Muskeldystrophie (eds. Kuhn, E.) Springer-Verlag, Berlin. (1966) 102-109

[20] F. Tomé, and M. Fardeau, Oculopharyngeal muscular dystrophy, In: Engel AG, Franzini-Armstrong C, eds: Myology, 2 (1994) 1233–1245. McGraw-Hill, New York.

[21] X. Fan and G.A. Rouleau, Progress in understanding the pathogenesis of oculopharyngeal muscular dystrophy, *Can. J. Neurol. Sci.* 30 (2003) 8–14.

[22] F.M. Tome, and M. Fardeau. Nuclear inclusions in oculopharyngeal dystrophy. *Acta Neuropathol. (Berl.)* 49(1980) 85–87.

[23] S. Rüegg, M. Lehky Hagen, U. Hohl, L. Kappos, P. Fuhr, M. Plasilov, H. Hüller, and K. Heinimann, Oculopharyngeal muscular dystrophy an under-diagnosed disorder? SWISS MED WKLY 135 (2005) 574-586.

[24] B. Brais. Oculopharyngeal muscular dystrophy: a late-onset polyalanine disease. Cytogenet Genome Res, 100 (2003) 252-260.

[25] J.P. Bouchard, B. Brais, D. Brunet, P.V. Gould, and G.A. Rouleau, Recent studies on oculopharyngeal muscular dystrophy in Quebec, Neuromuscul Disord 7 (1997) (Suppl 1) :S22-S29.

[26] B.W. Little, and D.P. Perl, Oulopharyngeal muscular dystrophy. An autopsied case from the French-Canadian Kindred. J. Neuro Sci, 53 (1982) 145-158.

[27] B.M. van der Sluijs, L.H. Hoefsloot, G.W. Padberg, S.M. van der Maarel, B.G.M. van Engelen, Oculopharyngeal muscular dystrophy with limb girdle weakness as major complaint. J Neurol, 250 (2003)1307–1312.

[28] F. Codere, Oculopharyngeal muscular dystrophy, Can J Ophthalmol, 28 (1993) 1-2.

[29] A. Duranceau, Cricopharyngeal myotomy in the management of neurogenic and muscular dysphagia, Neuromuscul Disord, 7 (1997) S85-S89.

[30] J. Mathieu, G. Lapointe, A. Brassard, C. Tremblay, B. Brais, G.A. Rouleau, J.P. Bouchard, A pilot study on upper esophageal sphincter dilatation for the treatment of dysphagia in patients with oculopharyngeal muscular dystrophy, *Neuromuscul. Disord*, 7 (1997) S100-S104.

[31] J.M. Stajich, J.M. Gilchrist, F. Lennon, A. Lee, L. Yamaoka, B. Rosi, P.C. Gaskell, M. Pritchard, L. DonalsA.D. RosesJ.M. Vance, M.A. Pericak-Vance, Confirmation of linkage of oculopharyngeal muscular dystrophy to chromosome 14q11.2-q13 in American families suggests the existence of a second causal mutation, Neuromuscul Disord. 1 (1997) S75-S81.

[32] H. Porschke, W. Kress, H. Reichmann, H.H. Goebel, and T. Grimm , Oculopharyngeal muscular dystrophy in a northern German family linked to chromosome 14q, and presenting carnitine deficiency, Neuromuscul Disord. 7 (1997) (Suppl 1):S57–S62.

[33] B. Brais, J.P. Bouchard, Y.G. Xie, D.L. Rochefort, N. Chrétien, F.M. Tomé, R.G. Lafreniere, J.M. RommensE. Uyama, O. Nohira, S. Blumen, A.D. Korczyn, P. Heutink, J. Mathieu, A. Duranceau, F. Codere, M. Fardeau, and G.A. Rouleau, Short GCG expansions in the PABP2 gene cause oculopharyngeal muscular dystrophy, Nat Genet 18 (1998)164–167.

ACCEPTED MANUSCRIPT

[34] S.C. Blumen, B. Brais, A.D. Korczyn, S. Medinsky, J. Chapman, A. Asherov, et al. Homozygotes for oculopharyngeal muscular dystrophy have a severe form of the disease. Ann Neurol, 46 (1999)115–8.

[35] A. Pobst, W. Tackmann, H.R. Stoeckli, F. Jerusalem, and J. Ulrich, Evidence for a chronic axonal atrophy in oculopharyngeal 'muscular dystrophy', Acta Neuropathologica (Berlin), 57 (1982) 209–216.

[36] R. Schober, W. Kress, F. Grahmann, S. Kellermann, P. Baum, S. Gunzel, A. Wagner, Unusual triplet expansion associated with neurogenic changes in a family with oculopharyngeal muscular dystrophy, 21 (2001) 45-52.

[37] J. P. Bouchard, B. Brais, D. Brunet, P.V. Gould, and G.A. Rouleau, Recent studies on oculopharyngeal muscular dystrophy in Québec, Neuromuscul Disord, 7 (1997) (Suppl 1):S22–S29.

[38] H. P. Schmitt, and K.H. Krause, An autopsy study of a familial oculopharyngeal muscular dystrophy (OPMD) with dustal spread and neurogenic involvement, Muscle Nerve, 4 (1981) 296–305.

[39] O. Hardiman, J.J. Halperin, M.A. Farell, B.E. Shapiro, S.H. Wray, and R.H. Brown RH, Neuropathic findings in oculopharyngeal muscular dystrophy, A report of seven cases and a review of the literature, Arch Neurol. 50 (1993) 481–488.

[40] M. Mirabella, G. Silvestri, G. de Rosa, S. Di Giovanni, A. Di Muzio, A. Uncini, P. Tonali, and S. Servidei, GCG genetic expansions in Italian patients with oculopharyngeal muscular dystrophy, Neurology 54 (2000) 608–614.

[41] T. Müller, R. Schröder, and S. Zierz, GCG repeats and phenotype in oculopharyngeal muscular dystrophy, Muscle Nerve 24 (2001)120–122.

[42] R. Schober , W. Kress, F. Grahmann, S. Kellermann, P. Baum, S. Günzel, and A. Wagner, Unusual triplet expansion associated with neurogenic changes in a family with oculopharyngeal muscular dystrophy, Neuropathology 21 (2001) 45–52.

[43] Y. Boukriche, T. Maisonobe, and C. Masson, Neurogenic involvement in a case of oculopharyngeal muscular dystrophy, Muscle Nerve 25 (2002) 98–101.

[44] G. Linoli, G. Tomelleri, and M. Ghezzi, Oculopharyngeal muscular dystrophy. Description of a case with involvement of the central nervous system, Pathologica 83 (1991)325–334.

[45] Y. Boukriche, T. Maisonobe, and C. Masson, Neurogenic involvement in a case of oculopharyngeal muscular dystrophy, Muscle Nerve, 25(2002)98-101.

[46] D. Nakashima, H. Nakajima, S. Ishida, M. Sugino, F. Kimura, and T. Hanafusa, Preferential distal muscle involvement in case of oculopharyngeal muscular dystrophy with (GCG) 13 expansion, *Rinsho Shinkeigaku.* 43 (2003) 560-563.

[47] P. Dion, V. Shanmugam, C. Gaspar, C. Messaed, I. Meijer, A. Toulouse, A, J. Laganiere, , J. Roussel, D. Rochefort, S. Laganiere, A. Allen, G. Karpati, J.P. Bouchard, B. Brais, and G.A. Rouleau, Transgenic expression of an expanded (GCG)13 repeat PABPN1 leads to weakness and coordination defects in mice, Neurobiol Dis. 3 (2005) 528-536.

[48] F.M.S. Tomé, D. Chateau, A. Helbling-Leclerc, and M. Fardeau, Morphological changes in muscle fibers in oculopharyngeal muscular dystrophy, Neuromuscul Disord 7 (1997) (Suppl 1): S63–S69.

[49] S. Krause, S. Fakan, K. Weis, and E. Wahle, Immunodetection of poly(A) binding protein II in the cell nucleus, *Experimental Cell Research,* 214 (1994) 75-82.

[50] E. Wahle, A. Lustig, P. Jeno, and P. Maurer, Mammalian poly(A)-binding protein II. Physical properties and binding to polynucleotides, J Biol Chem. 268 (1993) 2937-2945.

ACCEPTED MANUSCRIPT

[51] A. Nemeth, S. Krause, D. Blank, A. Jenny, P. Jeno, A. Lusting, and E. Wahle, Isolation of genomic and cDNA clones encoding bovine poly(A) binding protein II, *Nucleic Acids Res*;23 (1995) 4034–4041.

[52] Y. Kerwitz, U. Kühn, H. Lilie, A. Knoth, T. Scheuermann, H. Friedrich, E. Schwarz, and E. Wahle, Stimulation of poly(A) polymerase through a direct interaction with the nuclear poly(A) binding protein allosterically regulated by RNA, *EMBO J*. 22 (2003) 3705–3714.

[53] A. Calado, F.M.S. Tome, B. Brais, G.A. Rouleau, U. Kuhn, E. Wahle, and M. Carmo-Fonseca, Nuclear inclusions in oculopharyngeal muscular dystrophy consist of poly (A) binding protein 2 aggregates which sequester poly(A) RNA, Hum Mol Genet. 9 (2000)2321-2328.

[54] X. Fan, P. Dion, J. Laganiere, B. Brais, and G.A. Rouleau, Oligomerization of polyalanine expanded PABPN1 facilitates nuclear protein aggregation that is associated with cell death, Hum Mol Genet. 10 (2001) 2341-2351.

[55] E. Wahle, A novel poly(A)-binding protein acts as a specificity factor in the second phase of messenger RNA polyadenylation, Cell 66 (1991) 759–768.

[56] E. Wahle, Poly(A) tail length control is caused by termination of processive synthesis, J Biol Chem. 270 (1995) 2800-2808.

[57] M. Gorlach, C.G. Burd, and G. Dreyfuss, The mRNA poly(A)-binding protein: localization, abundance, and RNA-binding specificity, Exp Cell Res, 211 (1994) 400-407.

[58] E. Afonina, R. Stauber, and G.N. Pavlakis, The human poly(A)-binding protein 1 shuttles between the nucleus and the cytoplasm, J Biol Chem. 273 (1998) 13015-13021.

[59] U. Calado, U. Kutay, E. Kühn, E. Wahle, and M. Carmo-Fonseca M, Deciphering the cellular pathway for transport of poly(A)-binding protein II, RNA 6 (2000) 245–256.

[60] D.F. Colgan, and J.L. Manley, Mechanism and regulation of mRNA polyadenylation, Genes Dev. 11(1997) 2755-2766.

[61] L. Minvielle-Sebastia, and W. Keller, mRNA polyadenylation and its coupling to other RNA processing reactions and to transcription, Curr Opin Cell Biol. 11(1999) 352-357.

[62] S.M.L. Barabino, and W. Keller, Last but not least: regulated poly(A) tail formation, Cell, 99 (1999) 9-11.

[63] S. Bienroth, W. Keller, and E. WahleAssembly of a processive messenger RNA polyadenylation complex, EMBO J., 12 (1993) 585-594.

[64] R.W. Keller, U. Kuhn, M. Aragon, L. Bornikova, E. Wahle, and D.G. Bear, The nuclear poly(A) binding protein, PABP2, forms an oligomeric particle covering the length of the poly(A) tail, J Mol Biol. 297 (2000) 569-583.

[65] F.M. Tome, and M. Fardeau, Ocular myopathies, Pathology, Research and Practice 180 (1985) 19-27.

[66] M. F. Pratt, and P.K. Meyers, Oculopharyngeal muscular dystrophy: recent ultrastructural evidence for mitochondrial abnormalities, Laryngoscope 96 (1986) 368-373.

[67] F.M. Tome, V. Askanas, W.K. Engel, R.B. Alvarez, and C.S. Lee, Nuclear inclusions in innervated cultured muscle fibers from patients with oculopharyngeal muscular dystrophy, Neurol. 39 (1989) 929-932.

ACCEPTED MANUSCRIPT

[68] J.P. Bouchard, F. Gagne, F.M. Tome, and D. Brunet, Nuclear inclusions in oculopharyngeal muscular dystrophy in Quebec, Ca. J. Neurol. Sci. 16 (1989) 446-450.

[69] M. Coquet, C. Vital, and J. Julien, Presence of inclusion body myositis-like filaments in oculopharyngeal muscular dystrophy. Ultrastructural study of 10 cases, Neuropathol. App. Neurobiol., 5 (1990), 393-400.

[70] S.C. Blumen, M. Sadeh, A.D. Korczyn, A. Rouche, P. Nisipeanu, A. Asherov, and F.M. Tome, Intranuclear inclusions in oculopharyngeal muscular dystrophy among Bukhara Jews, Neurol. 46 (1996) 1324-1328.

[71] F.M. S. Tome, and M. Fradeau, Nuclear changes in muscle disorders, Methods Achiev Exp Pathol. 12 (1986) 261-296.

[72] Y. P. Bao, L.J. Cook, D. O'Donovan, E. Uyama, and D.C. Rubinsztein, Mammalian, yeast, bacterial, and chemical chaperones reduce aggregate formation and death in a cell model of oculopharyngeal muscular dystrophy, J Biol Chem, 277 (2002)12263-12269.

[73] A. Abu-Baker, C. Messaed, J. Laganiere, C. Gaspar, B. Brais, and G.A. Rouleau, Involvement of the ubiquitin-proteasome pathway and molecular chaperones in oculopharyngeal muscular dystrophy, Hum Mol Genet. 12 (2003) 2609-2623.

[74] V. Shanmugam, P. Dion, D. Rochefort, J. Laganiere, B. Brais, and G.A. Rouleau, PABP2 polyalanine tract expansion causes intranuclear inclusions in oculopharyngeal muscular dystrophy, Ann. Neurol. 48 (2000) 798–802.

[75] A. Abu-Baker, S. Laganiere, X. Fan, J. Laganiere, B. Brais B, and G.A. Rouleau, Cytoplasmic targeting of mutant poly(A)-binding protein nuclear 1 suppresses protein aggregation and toxicity in oculopharyngeal muscular dystrophy, Traffic, 6 (2005)1-14.

[76] L.P. Corbeil-Girard, A.F. Klein, A.M. Sasseville, H. Lavoie, M.J. Dicaire, A. Saint-Denis, M. Page, A. Duranceau, F. Codere, J.P. Bouchard, G. Karpati, G.A. Rouleau, B. Massie, Y. Langelier, and B. Brais, PABPN1 overexpression leads to upregulation of genes encoding nuclear proteins that are sequestered in oculopharyngeal muscular dystrophy nuclear inclusions, Neurobiol Dis. 18 (2005) 551-567.

[77] M. Arrasate, S. Mitra, E.S. Schweitzer, M.R. Segal, and S. Finkbeiner, Inclusion body formation reduces levels of mutant huntingtin and the risk of neuronal death, Nature 43 (2004) 805-810.

[78] J.P. Tavanez, P. Calado, J. Braga, M. Lafarga, and M. Carmo-Fonseca, In vivo aggregation properties of the nuclear poly(A)-binding protein PABPN1, RNA, 5 (2005) 752-62.

[79] T.M. Berciano, T. Nuria, V. Jose, L. O.J. Navascues, A. Gomes, M. Lafarga and M.Carmo-Fonseca, Oculopharyngeal muscular dystrophy-like nuclear inclusions are present in normal magnocellular neurosecretory neurons of the hypothalamus, Human Molecular Genetics 13 (2004) 829-838.

[80] A.M.J. Sasseville, A.W. Caron, L.Bourget, A.F. Klein, M.J. Dicaire, G.A. Rouleau, B. Massie, Y. Langelier, and B. Brais, The dynamism of PABPN1 nuclear inclusions during the cell cycle, Neurobiol. Dis. (23) 2006 621-629.

[81] A. Abu-Baker, G.A. and Rouleau, Polyalanine and Polyglutamine Diseases: Possible Common Mechanisms? Genetic Instabilities and Neurological disorders, Second Edition, Chapter 33 (2006) 487-513,

[82] H.Y. Zoghbi, H.T. and Orr, Glutamine repeats and neurdegeneration, Annu. Rev. Neurosci. 23 (2000) 217–247.

ACCEPTED MANUSCRIPT

[83] C. Gaspar, M. Jannatipour, P. Dion, J. Laganiere, J. Sequeiros, B. Brais, and G.A. Rouleau, CAG tract of MJD-1 may be prone to frameshifts causing polyalanine accumulation, Hum Mol Genet. 9 (2000)1957–1966.

[84] A. Toulouse, F. Au-Yeung, C. Gaspar, J. Roussel, P. Dion, and G.A. Rouleau, Ribosomal frameshifting on MJD-1 transcripts with long CAG tracts, Hum Mol Genet. 15 (2005) 2649-60.

[85] Y. Muragaki, S. Mundlos, J. Upton, and B.R. Olsen, Altered growth and branching patterns in synpolydactyly caused by mutations in HOXD13, Science 272 (1996) 548–551.

[86] F.R. Goodman, S. Mundlos, Y. Muragaki, D. Donnai, M.L. Giovannucci-Uzielli, E. Lapi, F. Majewski, J. McGaughran, C. McKeown, W. Reardon, J. Upton, R.M. Winter, B.R. Olsen, P.J. Scambler, Synpolydactyly phenotypes correlate with size of expansions in HOXD13 polyalanine tract, Proc Natl Acad Sci. 94 (1997)7458–7463.

[87] S. Mundlos, F. Otto, C. Mundlos, J.B. Mulliken, A.S. Aylsworth, S. Albright, D. Lindhout, W.G. Cole, W. Henn, J.H. Knoll, M.J. Owen, R. Mertelsmann, B.U. Zabel, and B.R. Olsen, Mutations involving the transcription factor CBFA1 cause cleidocranial dysplasia, Cell 89 (1997) 773–779.

[88] S.A. Brown, D. Warburton, L.Y. Brown, C-Y. Yu, E.R. Roeder, S. Stengel-Rutkowski, R.C.M. Hennekam, and M. Muenke, Holoprosencephaly due to mutation in *ZIC2* a homologue of Drosophila odd-paired, Nat Genet. 20 (1998)180–183.

[89] D.P. Mortlock, and J.W. Innis, Mutation of HOXA13 in hand-foot-genital syndrome. Nat. Genet. 15 (1997) 179–180

[90] L. Crisponi, M. Deiana, A. Loi, F. Chiappe, M. Uda, P. Amati, L. Bisceglia, L. Zelante, R. Nagaraja, S. Porcu, S, M.S. Ristaldi, R.Marzella, M. Rocchi, M. Nicolino, A. Lienhardt-Roussie, A. Nivelon, A. Verloes, D. Schlessinger, P. Gasparini, D. Bonneau, A. Cao, and G. Pilia, The putative forkhead transcription factor FOXL2 is mutated in blepharophimosis/ptosis/epicanthus inversus syndrome. Nat Genet. 27(2001)159–166.

[91] P. Stromme, M.E. Mangelsdorf, M.A. Shaw, K.M. Lower, S.M. Lewis, H. Bruyere, V. Lutcherath, A.K. Gedeon, R.H. Wallace, I.E. Scheffer, G. Turner, M. Partington, S.G. Frints, J.P. Fryns, G.R. Sutherland, J.C. Mulley, and J. Gecz, Mutations in the human ortholog of Aristaless cause X-linked mental retardation and epilepsy, Nat. Genet., 30 (2002) 441–445.

[92] F. Laumonnier, N. Ronce, B.C. Hamel, P. Thomas, J. Lespinasse, M. Raynaud, C. Paringaux, H. Van Bokhoven, V. Kalscheuer, J.P. Fryns, J. Chelly, C. Moraine, and S. Briault, Transcription factor SOX3 is involved in X-linked mental retardation with growth hormone deficiency, Am. J. Hum. Genet., 71 (2002)1450–1455.

[93] J. Amiel, B. Laudier, T. Attie-Bitach, H. Trang, L. De Pontual, B. Gener, D. Trochet, H. Etchevers, P. Ray, M. Simonneau, M, M. Vekemans, A. Munnich, G.Gaultier, and S. Lyonnet, Polyalanine expansion and frameshift mutations of the paired-like homeobox gene PHOX2B in congenital central hypoventilation syndrome, Nat. Genet. 33 (2003) 459–461.

[94] S.T. Warren, Polyalanine expansion in synpolydactyly might result from unequal crossing-over of HOXD13. Science, 275 (1997) 408–409.

ACCEPTED MANUSCRIPT

[95] H. Lavoie, F. Debeane, Q.D. Trinh, J.F. Turcotte, L.P. Corbeil-Girard, M.J. Dicaire, A. Saint-Denis, M. Page, G.A. Rouleau, and B. Brais, Polymorphism, shared functions and convergent evolution of genes with sequences coding for polyalanine domains, Hum Mol Genet. 12 (2003) 2967-2979.

[96] S. Caburet, A. Demarez, L. Moumme, M. Fellows, E. De Baere, and R.A. Veitia, A recurrent polyalanine expansion in the transcription factor FOXL2 induces extensive nuclear and cytoplasmic protein aggregation, J Med Genet. 41(2004)931-946.

[97] I.M. Nasrallah, J.C. Minarcik, and J.A. Golden, A polyalanine tract expansion in Arx forms intranuclear inclusions and results in increased cell death. J. Cell. Biol. 167 (2004) 411-416.

[98] A.N. Albrecht, U. Kornak, A. Boddrich, K. Suring, P.N. Robinson, A.C. Stiege, R. Lurz, S. Stricker, E.E. Wanker, and S. Mundlos, A molecular pathogenesis for transcription factor associated poly-alanine tract expansions, Hum Mol Genet. 13 (2004) 2351-2359.

[99] F.R. Goodman, Limb malformations and the human *HOX* genes. Am. J. Med. Genet., 112 (2002) 256–265.

[100] F.R. Goodman, and P.J. Scambler, (2001) Human *HOX* gene mutations. Clin. Genet. 59 (2001)1–11.

[101] J. Amiel, D. Trochet, M. Clement-Ziza, A. Munnich, and S. Lyonnet, Polyalanine expansions in human, Hum. Mol. Genet. 13 (2004) R235-243.

[102] A. Albrecht, and S. Mundlos, The other trinucleotide repeat: polyalanine expansion disorders, Curr Opin Genet Dev. 3 (2005) 285-293.

[103] J.E. Davies, L. Wang, L. Garcia-Oroz, L.J. Cook, C. Vacher, D.G. O'donovan, and D.C. Rubinsztein, Doxycycline attenuates and delays toxicity of the oculopharyngeal muscular dystrophy mutation in transgenic mice, Nat Med. 6 (2005) 672-677.

[104] H. Hino, K. Araki, E. Uyama, M. Takeya, M. Araki, K. Yoshinobu, K. Miike, Y. Kawazoe, Y. Maeda, M. Uchino and K. Yamamura, Myopathy phenotype in transgenic mice expressing mutated PABPN1 as a model of oculopharyngeal muscular dystrophy, Hum. Mol. Genet. 13 (2004)181–190.

[105] A. Chartier, B. Benoit, M. Simonelig, A Drosophila model of oculopharyngeal muscular dystrophy reveals intrinsic toxicity of PABPN1. EMBO Journal. 25 (2006)2253-62.

[106] X. Fan, C. Messaed, P. Dion, L. Laganiere, B. Brais, G. Karpati, and G.A. Rouleau, HnRNP A1 and A/B interaction with PABPN1 in oculopharyngeal muscular dystrophy, Can J Neurol Sci. 30 (2003) 244-251.

[107] B. Forood, E. Perez-Paya, R.A. Houghten, and S.E. Blondelle, Formation of an extremely stable polyalanine beta-sheet macromolecule, Biochem Biophys Res Commun. 211 (1995) 7-13.

[108] S.E. Blondelle, B. Forood, R.A. Houghten, and E. Perez-Paya, Polyalanine-based peptides as models for self-associated beta-pleated-sheet complexes, Biochemistry 36 (1997) 8393-400.

[109] J. Gatesy, C. Hayashi, D. Motriuk, J. Woods, and R. Lewis, Extreme diversity, conservation, and convergence of spider silk fibroin sequences, Science 291 (2001) 2603–2605.

[110] S. Karlin, C. Chen, A.J. Gentles, and M. Cleary, Associations between human disease genes and overlapping gene groups and multiple amino acid runs, Proc. Natl Acad. Sci. 99 (2002) 17008–17013.

ACCEPTED MANUSCRIPT

[111] M.F. Perutz, B.J. Pope, D. Owen, E.E. Wanker, and E. Scherzinger, Aggregation of proteins with expanded glutamine and alanine repeats of the glutamine-rich and asparagine-rich domains of Sup35 and of the amyloid beta-peptide of amyloid plaques, Proc Natl Acad Sci. 99 (2002) 5596-600.

[112] T. Scheuermann, B. Schulz, A. Blume, E. Wahle, R. Rudolph, and E. Schwarz, Trinucleotide expansions leading to an extended poly-L-alanine segment in the poly (A) binding protein PABPN1 cause fibril formation, Protein Sci. 12 (2003) 2685-2692.

[113] L.M. Shinchuk, D. Sharma, S.E. Blondelle, N. Reixach, H. Inouye, and D.A. Kirschner, Poly-(L-alanine) expansions form core beta-sheets that nucleate amyloid assembly, Proteins. 61 (2005) 579-589.

[114] H.D. Nguyen, and C.K. Hall, Spontaneous fibril formation by polyalanines; discontinuous molecular dynamics simulations, J Am Chem Soc. 128 (2006) 1890-1901,

[115] H. D. Nguyen, and C.K. Hall, Kinetics of fibril formation by polyalanine peptides, J. Biol. Chem. 280 (2005) 9074-9082.

[116] Y.P. Bao, S. Sarkar, E. Uyama, and D.C. Rubinsztein, Congo red, doxycycline, and HSP70 overexpression reduce aggregate formation and cell death in cell models of oculopharyngeal muscular dystrophy, Journal of Medical Genetics 41 (2004) 47-51.

[117] I. Sanchez, C. Mahlke, and J. Yuan, Pivotal role of oligomerization in expanded polyglutamine neurodegenerative disorders, Nature. 421 (2003) 373-379.

[118] J. D. Wirtschafter, D.A. Ferrington, and L.K. McLoon, Continuous remodeling of adult extraocular muscles as an explanation for selective craniofacial vulnerability in oculopharyngeal muscular dystrophy, J Neuroophthalmol. 1 (2004) 62-67

[119] Q. Wang and J. Bag, Ectopic expression of a polyalanine expansion mutant of poly(A)-binding protein N1 in muscle cells in culture inhibits myogenesis, Biochem Biophys Res Commun. 340 (2006) 815-822.

[120] Y-J. Kim, S. Noguchi, Y.K. Hayashi, T. Tsukahara, T. Shimizu, and K. Arahata, The product of an oculopharyngeal muscular dystrophy gene, poly(A)-binding protein 2, interacts with SKIP and stimulates muscle-specific gene expression, Hum Mol Genet. 10 (2001) 1129–1139.

[121] D. G. Bear, N. Fomproix, T. Soop, B. Björkroth, S. Masich, and B. Daneholt, Nuclear poly(A)-binding protein PABPN1 is associated with RNA polymerase II during transcription and accompanies the released transcript to the nuclear pore, Exp Cell Res, 286 (2003) 332–344.

[122] B. Ravikumar, R. Duden, and D.C. Rubinsztein, Aggregate-prone proteins with polyglutamine and polyalanine expansions are degraded by autophagy, Hum Mol Genet. 11 (2002)1107-1117.

[123] S. Nakielny, and Dreyfuss G., Nuclear export of proteins and RNAs, Curr Opin Cell Biol. 9 (1997) 420-9.

[124] Z. Berger, E.K. Ttofi, C.H. Michel, M.Y. Pasco, S. Tenant, D.C. Rubinsztein and C.J. O'Kane, Lithium rescues toxicity of aggregate-prone proteins in Drosophila by perturbing Wnt pathway, Hum Mol Genet. 14 (2005) 3003-3011. Hum Mol Genet.

[125] M. Tanaka, Y. Machida, S. Niu, T. Ikeda, N.R. Jana, H. Doi, M. Kurosawa, M. Nekooki, and N. Nukina, Trehalose alleviates polyglutamine-mediated pathology in a mouse model of Huntington disease, Nature Medicine 10 (2004) 148 – 154.

ACCEPTED MANUSCRIPT

[126] J.E. Davies, S. Sarkar, and D.C. Rubinsztein, Trehalose reduces aggregate formation and delays pathology in a transgenic mouse model of oculopharyngeal muscular dystrophy, Hum Mol Genet. 15 (2006) 23-31.

[127] P. Verheesen, A. de Kluijver, S. van Koningsbruggen, M. de Brij, H.J. de Harrd, G.J. van Ommen, S.M. van der Maarel, Prevention of oculopharyngeal muscular dystrophy-associated aggregation of nuclear polyA-binding protein with a single-domain intracellular antibody, Hum Mol Genet. 15 (2006) 105-111.

[128] Q. Wang, D.D. Mosser, and J. Bag, Induction of HSP70 expression and recruitment of HSC70 and HSP70 in the nucleus reduce aggregation of a polyalanine expansion mutant of PABPN1 in HeLa cells, Hum Mol Genet. 14 (2005) 3673-3684.

[129] V. Mouly, A. Aamiri, S. Perie, K. Mamchaoui, A. Barani, A. Bigot, B. Bouazza, V. Francois, D. Furling, V. Jacquemin, E. Negroni, I. Riederer, A. Vignaud, J.L. St Guily, and G.S. Butler-Browne, Myoblast transfer therapy: is there any light at the end of the tunnel? Acta Myol. (2) 2005 128-133.

ACCEPTED MANUSCRIPT

ACCEPTED MANUSCRIPT

Table1: Polyalanine diseases

Disease	Symptoms	Gene	Protein's function	Normal polyAla tract size	Expanded polyAla tract size	Protein aggregates	Affected cells
Synpolydactyly (SPD)	Hand/foot malformation with syndactyly and polydactyly, brachydactyly	*HOXD13*	Transcription factor patterning of dorsal axis limbs, genitals	15	22-29	Cytoplasmic	Skeletal
Hand-Foot Genital Syndrome (HFGS)	Hand/foot malformation with short thumbs/great toes, abnormal genitalia	*HOXA13*	Transcription factor patterning of dorsal axis limbs, genitals	18	24-26	Cytoplasmic	Skeletal
Cleidocranial Dysplasia(CCD)	Skeletal dysplasia open fontanelles, tooth abnormalities, with hypoplastic clavicles, short stature	*RUNX2(CBFA1)*	transcription factor central role in morphogenesis of skeleton, osteoblast differentiation	17	27	Cytoplasmic	Skeletal
Congenital Central Hypoventilation Syndrome (CCSH)	Loss of ventilary response and Hirschsprung disease	*PHOX2B*	transcription factor development of brain	20	25-29		Nervous system
Holoprosencephaly(HPE)	Malformation of midline structures of the forebrain and facial cranium	*ZIC2*	transcription factor development of brain and limbs	15	25		Nervous system
Blepharophimosis/Ptosis/ Epicanthus inversus Syndrome(BPES)	Blepharophimosis, ptosis, epicanthus inversus ovarian failure	*FOXL2*	Helix/forkhead transcription factor expressed in developing eye and ovaries	14	22-24	Nuclear and Cytoplasmic	Nervous system
Infantile Spasm Syndrome X-linked (MR)	Mental retardation, epilepsy, dystonia	ARX	Transcription factor role in development of cerebral cortex and axonal guidance	16 12	18-23 20	Nuclear	Nervous system
X-linked Mental Retardation with Growth Hormone Deficiency (MR and GH)	Mental retardation, short stature caused by growth hormone deficiency	SOX3	Transcription factor, neuronal differentiation in brain and spinal cord	15	26	Cytoplasmic	Nervous system
Oculo-Pharyngeal Muscular Dystrophy (OPMD)	Progressive, late onset, muscular weakness of eyelid, pharyngeal	PABPN1 Poly(A) binding protein	Regulates length of poly(A) mRNA tails	10 10	12-17 11	Nuclear	Muscles

Figure 1

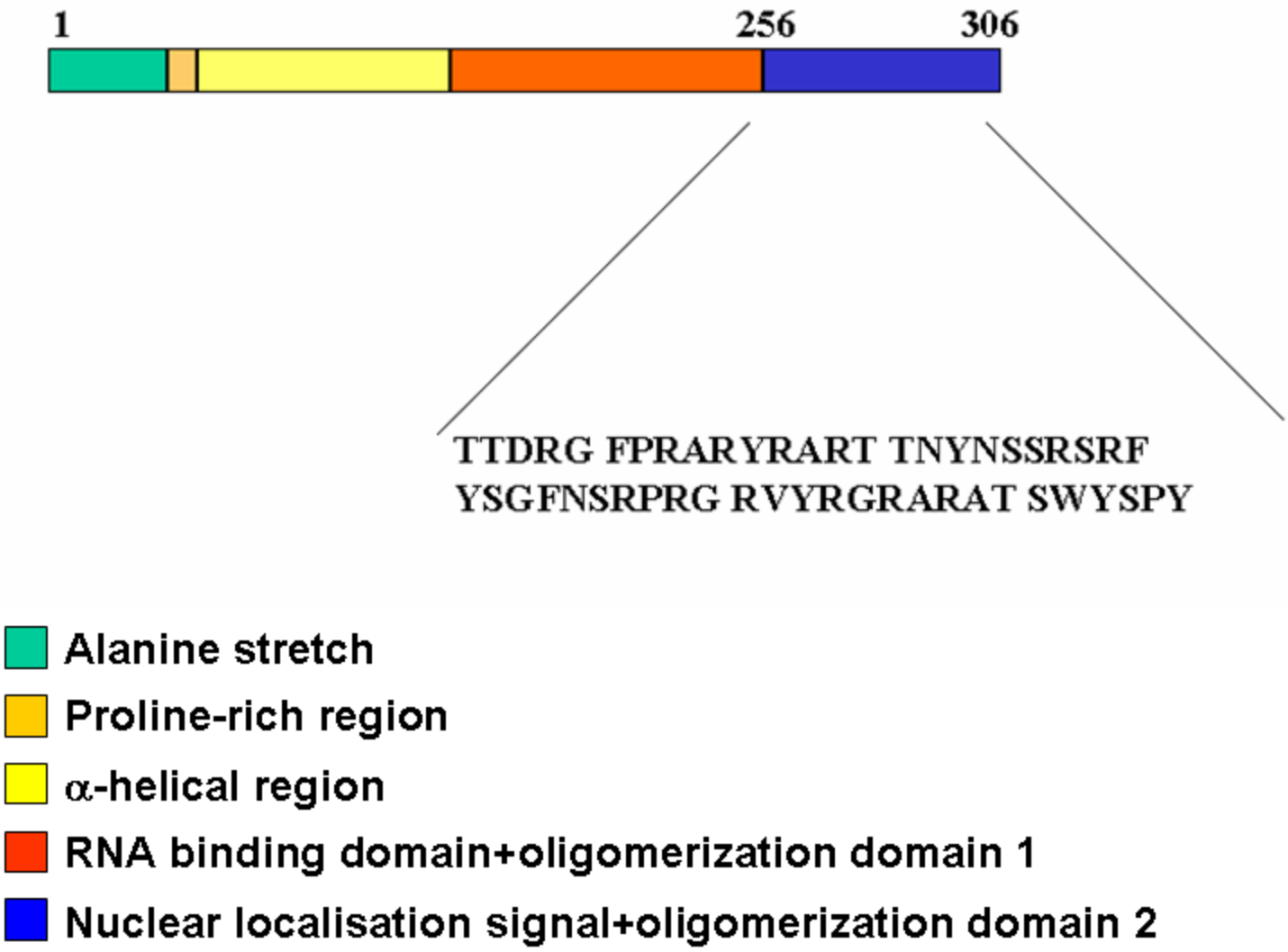

Figure 1

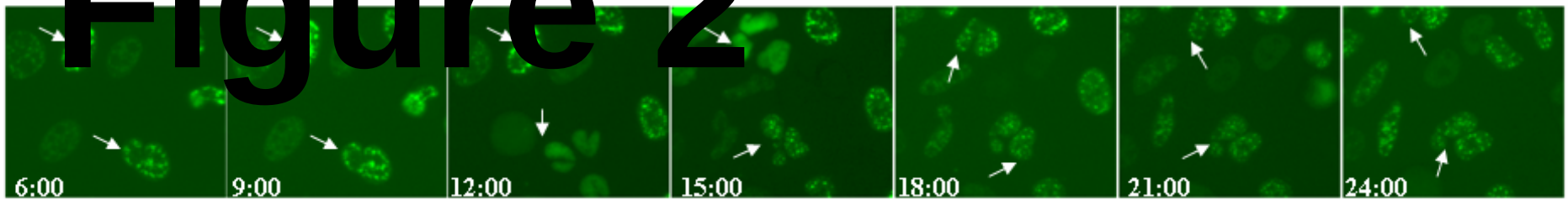

Figure 2

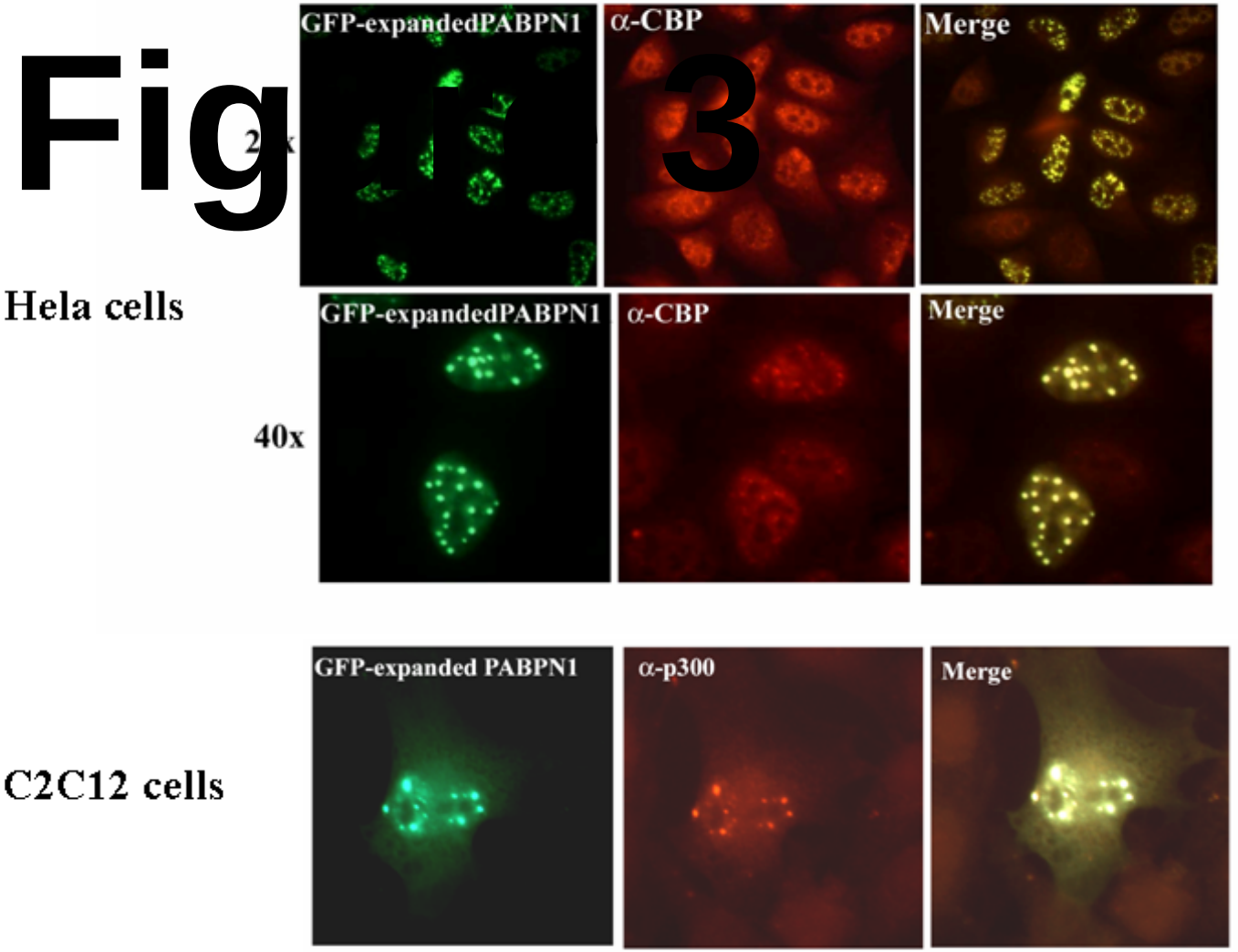
Fig 3
GFP-expandedPABPN1
α-CBP
Merge
Hela cells
40x
GFP-expandedPABPN1
α-CBP
Merge
C2C12 cells
GFP-expanded PABPN1
α-p300
Merge

Figure 3