



HAL
open science

Jessner–Kanof disease induced by leflunomide: a dermal variant of cutaneous lupus?

Laëtitia Sparsa, Naji Afif, Joëlle Goetz, Christelle Sordet, Emmanuel Chatelus, Dan Lipsker, Jean Sibia

► **To cite this version:**

Laëtitia Sparsa, Naji Afif, Joëlle Goetz, Christelle Sordet, Emmanuel Chatelus, et al.. Jessner–Kanof disease induced by leflunomide: a dermal variant of cutaneous lupus?. *Rheumatology International*, 2009, 31 (2), pp.255-258. <10.1007/s00296-009-1169-z>. <hal-00561306>

HAL Id: hal-00561306

<https://hal.science/hal-00561306v1>

Submitted on 1 Feb 2011

HAL is a multi-disciplinary open access archive for the deposit and dissemination of scientific research documents, whether they are published or not. The documents may come from teaching and research institutions in France or abroad, or from public or private research centers.

L'archive ouverte pluridisciplinaire **HAL**, est destinée au dépôt et à la diffusion de documents scientifiques de niveau recherche, publiés ou non, émanant des établissements d'enseignement et de recherche français ou étrangers, des laboratoires publics ou privés.



HAL Authorization

Jessner-Kanof disease induced by leflunomide: a dermal variant of cutaneous lupus?

Laëtitia Sparsa (1), Naji Afif (2), Joëlle Goetz (3), Christelle Sordet (1), Emmanuel Chatelus (1), Dan Lipsker (4), Jean Sibia (1)

(1) Rheumatology Department, CHU de Strasbourg - FRANCE.

(2) Rheumatology Department, CH de Mulhouse - FRANCE.

(3) Immunology Department, CHU de Strasbourg - FRANCE.

(4) Dermatology Department, CHU de Strasbourg - FRANCE.

Short running title: Jessner Kanof disease and subacute cutaneous lupus

Key words: subacute cutaneous lupus induced, leflunomide, Jessner Kanof disease, anakinra

Correspondence:

Laëtitia SPARSA- Rhumatologie

Hôpital de Hautepierre

Avenue Molière

67098 Strasbourg Cedex- FRANCE

Tel: 03.88.12.79.49

Fax: 03.88.12.81.50

Ms T., 56 years, was followed for seropositive rheumatoid arthritis (RA) with rheumatoid factors (RF) and anti-CCP antibodies (Ab) discovered in 2002.

She had received corticotherapy together with injectable gold salts until 2003, followed by methotrexate in 2004, which was replaced on account of its inefficacy by leflunomide (20 mg/day). Three weeks after the initiation of this treatment, the patient developed a maculopapular cutaneous eruption associated with annular lesions of the face (Figure 1A) extending to the thorax (Figure 1B) and then the limbs.

Biological tests showed a CRP level of 11.5 mg/L without anomalies of the blood profile and negative HCV and HBV serology. The immunological profile revealed the presence of anti-nuclear antibodies (ANA) (1/320 with a speckled appearance) of specificity anti-Ro/SSA which had not been detected in several previous series of blood tests. There were no anti-native DNA, anti-cardiolipid or anti- β 2GPI Ab. A search for cryoglobulin was negative and there was no monoclonal immunoglobulin.

The diagnosis of subacute cutaneous lupus (SCL) was retained on account of the characteristic clinical manifestations and the occurrence of anti-Ro/SSA Ab. However, the histological presentation was that of Jessner-Kanoff disease (JKD). A cutaneous biopsy of a thoracic lesion revealed a chronic perivascular lymphocytic infiltrate in the dermis without involvement of the epidermis (Figure 2), while immunofluorescence (IF) showed IgG deposits on the dermal papillae. The delay in

the appearance of these lesions with respect to the introduction of leflunomide pointed to an inductive role of the latter.

Discontinuation of leflunomide (without washout) and corticotherapy (20 mg/day) resulted in no significant improvement in the cutaneous lesions. Conversely, introduction of chloroquine (200 mg/day) combined with an antagonist of the interleukin-1 receptor (Ra Il-1) (anakinra) led to complete disappearance of the cutaneous and articular symptoms in two months.

Discussion

Leflunomide is used to treat lupus, in particular the articular manifestations [1]. This molecule can nevertheless have adverse effects, among which the most frequent are alopecia, digestive complaints, buccal ulceration and toxidermia. More rarely, cases of subacute cutaneous lupus have been described, to date in five patients suffering from RA or Sjögren's syndrome [2, 3, 4, 5] (Table 1). Recently, in an open label pilot study includes fifteen primary Sjögren's syndrome treated with leflunomid (20 mg/d), 30% of the patients had developed lupus-like skin lesions (6).

Cases of subacute cutaneous lupus induced by drugs have also been reported for thiazides and calcium inhibitors [4]. The mechanism may differ depending on the drug. Leflunomide, through its immunomodulatory effect, can favour the appearance of a Th2 lymphocyte immune response, potentially capable of inducing lupus. However, all known cases of lupus induced by leflunomide concern reports of subacute cutaneous lupus, without there being any precise explanation for this cutaneous tropism.

In our patient, the histological presentation was unusual, identical to that of Jessner-Kanof disease. On the other hand, the lesions were characterized by a dermal

infiltrate without involvement of the epidermis, as is observed in subacute cutaneous lupus. A recent study has suggested that Jessner-Kanof disease (JKD) could be a dermal form of lupus [7]. Among 210 cases of histologically confirmed JKD, 7.6% of the patients had systemic or cutaneous lupus, either known or appearing concomitantly with or after the diagnosis of JKD. This prompted a revision of the classification of cutaneous lupus, which has until now been divided into acute, subacute and chronic forms but could equally be classed as epidermal, dermal and hypodermal [7] (Table 2).

In conclusion, leflunomide can induce cutaneous lupus with anti-Ro/SSA Ab characterized by exclusively dermal involvement and histologically comparable to Jessner-Kanof disease. This observation therefore suggests that Jessner-Kanof disease could be a dermal variant of lupus. The last point of interest in our observation is the efficacy of a combination of chloroquine and anakinra, which led to complete remission of the articular and cutaneous symptoms after the failure of corticotherapy.

References

1. Wallace DJ (2002) Management of lupus erythematosus: recent insights. *Curr Opin Rheumatol* 14: 212-219.

2. Gensburger D, Kawashima M, Marotte H, Kanitakis J, Miossec P (2005) Lupus erythematosus with leflunomide: induction or reactivation? *Ann Rheum Dis* 64: 153-155.
3. Kerr OA, Murray S, Tidman MJ (2004) Subacute cutaneous lupus erythematosus associated with leflunomide. *Clin and Exp Dermatology* 29: 319-320.
4. Goëb V, Berthelot JM, Joly P, Mejjad O, De Quatrebarbes J, Reynaud-Hautin C et al (2005) Leflunomide-induced subacute cutaneous lupus erythematosus. *Rheumatology* 44: 823-824.
5. Elias AR, Tam CC, David Bajar KM (2005) Subacute cutaneous lupus erythematosus associated with Leflunomide. *Cutis* 76: 189-192.
6. van Woerkom JM, Kruize AA, Geenen R, van Roon EN, Goldschmeding R, Verstappen SM, van Roon JA, Bijlsma JW (2007) Safety and efficacy of leflunomide in primary Sjögren's syndrome. *Ann Rheum Dis* 66:1026-32.
7. Lipsker D, Mitschler A, Grosshans E, Cribier B (2006) Could Jessner's Lymphocytic Infiltrate of the skin be a dermal variant of lupus erythematosus? An analysis of 210 cases. *Dermatology* 213: 15-22.

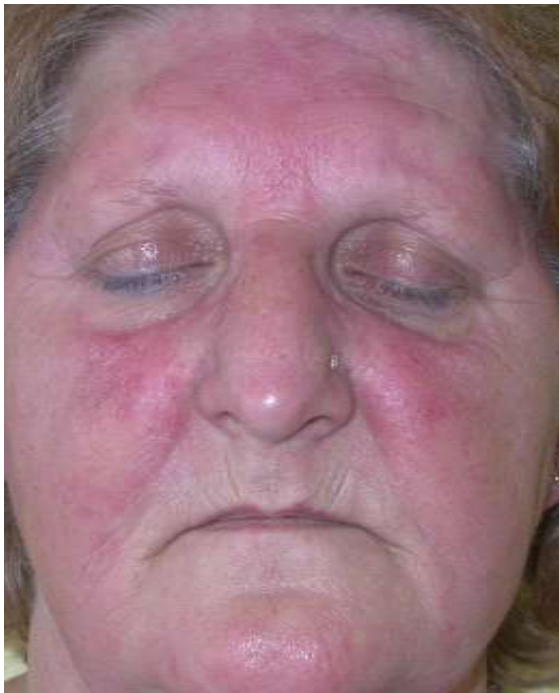Table 1: Cases of subacute cutaneous lupus described under leflunomide

(LeF: leflunomide; SCL: subacute cutaneous lupus; SAM: synthetic antimalarials; IF: immunofluorescence)

Table 2: The cutaneous lesions of lupus (Lipsker et al, 2006)

Figure 1: Annular macular eruption on the face (A) and the thorax (B) evoking systemic cutaneous lupus

Figure 2: Cutaneous histology of a lesion: quite dense perivascular lymphocytic infiltrate invading the entire dermis (except the papillae) without œdema and without involvement of the epidermis or basal membrane, a histological presentation evoking Jessner-Kanof disease.



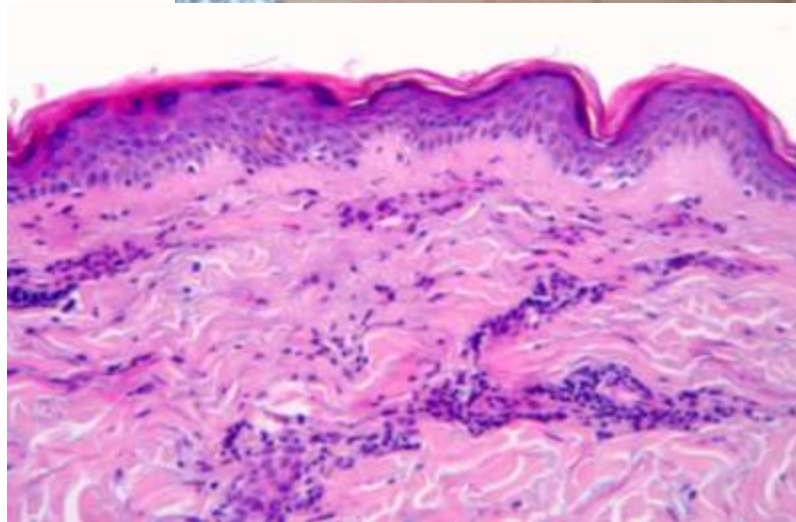
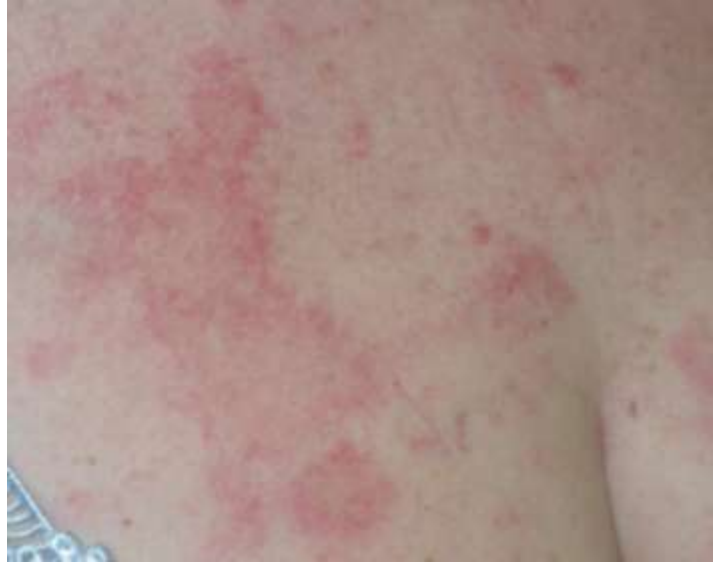

Table 1: Cases of subacute cutaneous lupus described under leflunomide

| Patient | Characteristics of the cutaneous lesions and time from introduction of LeF | ANA | Anti-Ro/SSA | Anti-histone | Anti-native DNA | Histological and IF analyses | Evolution |
|---|---|-----------------------|-------------|--------------|-----------------|---|---|
| 59 year-old man rheumatoid arthritis (Kerr et al, 2004) | - photosensitive distribution - annular, macular erythematous lesions evoking SCL - 6 weeks after introduction of LeF | absent | present | present | absent | - moderate but chronic perivascular dermal infiltrate - IgG in the papillary dermis | - failure of corticotherapy - favourable 5 months after discontinuation of LeF without washout and introduction of SAM - disappearance of anti-Ro/SSA and anti-histone Ab |
| 64 year-old woman rheumatoid arthritis (Elias et al, 2005) | - photosensitive distribution - scaly erythematous plaques - 4 months after introduction of LeF | present 1/320 | absent | absent | absent | - vacuolar alteration with scattered necrotic keratinocytes along the dermal-epidermal junction - superficial and mid-dermal perivascular lymphocytic infiltrate - IgG and complement staining at the dermal-epidermal junction | - failure of corticotherapy - favourable 8 weeks after discontinuation of LeF with washout |
| 58 year-old woman Goujerot-Sjögren syndrome (Gensburger et al, 2005) | - photosensitive distribution - malar rash, discoid lupus lesions at first, SCL after reintroduction of LeF - 4 weeks after reintroduction of LeF | present 1/2560 | present | absent | absent | - epidermal atrophy with lymphocytic infiltration - deposits of IgM and C3 at the dermal-epidermal junction | - failure of corticotherapy - favourable 4 weeks after discontinuation of LeF without washout and introduction of SAM - slow disappearance of anti-Ro/SSA |
| 59 year-old man rheumatoid arthritis (Goëb et al, 2005) | - photosensitive distribution - annular eruption resembling SCL - 11 months after introduction of LeF | present 1/1000 | present | absent | absent | - vacuolar degeneration of basal keratinocytes and a perivascular inflammatory infiltrate of lymphocytes in the superficial dermis - IgM and C3 deposits along the dermal-epidermal junction | - favourable 3 weeks after discontinuation of LeF without washout and introduction of corticotherapy - disappearance of anti-Ro/SSA |
| 56 year-old woman rheumatoid arthritis (Goëb et al, 2005) | - photosensitive distribution - papulosquamous rash resembling SCL - 9 months after introduction of LeF | absent | absent | absent | absent | - lupus band along the dermal-epidermal junction | - rapid and complete resolution after discontinuation of LeF without washout |

(LeF: leflunomide; SCL: subacute cutaneous lupus; SAM: synthetic antimalarials; IF: immunofluorescence)

Table 2: The cutaneous lesions of lupus (Lipsker et al, 2006)

1) Dermo-epidermal lupus (interfacial dermatitis)

- Acute lupus
- Subacute lupus
- Discoid lupus
- Vesiculobullous lupus

2) Dermal lupus

- Lupus tumidus
- Jessner-Kanof dermal lupus
- Papulonodular mucinosis
- Reticular erythematous mucinosis

3) Hypodermal lupus

- Lupus panniculitis