



HAL
open science

Sequential epiretinal membrane removal with internal limiting membrane peeling in brilliant blue G-assisted macular surgery

Ricarda G Schumann, Arnd Gandorfer, Kirsten H Eibl, Paul B Henrich, Anselm Kampik, Christos Haritoglou

► **To cite this version:**

Ricarda G Schumann, Arnd Gandorfer, Kirsten H Eibl, Paul B Henrich, Anselm Kampik, et al.. Sequential epiretinal membrane removal with internal limiting membrane peeling in brilliant blue G-assisted macular surgery. *British Journal of Ophthalmology*, 2010, 94 (10), pp.1369. 10.1136/bjo.2010.183210 . hal-00560857

HAL Id: hal-00560857

<https://hal.science/hal-00560857v1>

Submitted on 31 Jan 2011

HAL is a multi-disciplinary open access archive for the deposit and dissemination of scientific research documents, whether they are published or not. The documents may come from teaching and research institutions in France or abroad, or from public or private research centers.

L'archive ouverte pluridisciplinaire **HAL**, est destinée au dépôt et à la diffusion de documents scientifiques de niveau recherche, publiés ou non, émanant des établissements d'enseignement et de recherche français ou étrangers, des laboratoires publics ou privés.

1 **Sequential epiretinal membrane removal with internal limiting membrane**
2 **peeling in brilliant blue G-assisted macular surgery**

3

4 Ricarda G Schumann¹, Arnd Gandorfer¹, Kirsten H Eibl¹, Paul B Henrich², Anselm
5 Kampik¹, Christos Haritoglou¹.

6

7 ¹Department of Ophthalmology, Vitreoretinal and Pathology Unit, Ludwig-
8 Maximilians-University, Munich, Germany

9 ²Department of Ophthalmology, University Hospital Basel, Switzerland

10

11

12

13

14 Correspondence to:

15 Ricarda G. Schumann, MD

16 Department of Ophthalmology, Vitreoretinal and Pathology Unit,

17 Ludwig-Maximilians-University, Mathildenstr. 8, 80336 Munich, Germany.

18 Phone: ++49-89-5160 3811

19 Fax : ++49-89-5160 5160

20 E-mail: ricarda.schumann@med.uni-muenchen.de

21

22 Presented in part at the Annual Meeting of the Deutsche Ophthalmologische

23 Gesellschaft, Berlin, Germany, September 2009

24 The authors have no proprietary interest in any aspect of this study.

25 Source of funding: none

26 Conflict of interest: none

27

28 **Purpose.** To assess the selectivity of brilliant blue G (BBG) staining by analysing the
29 morphologic components of unstained and stained tissue obtained during epiretinal
30 membrane (ERM) removal with internal limiting membrane (ILM) peeling in BBG-
31 assisted macular surgery.

32 **Methods.** Twenty-six surgical specimens were removed from 13 eyes with epiretinal
33 gliosis during vitrectomy using BBG for ERM and ILM peeling. We included eyes with
34 idiopathic macular pucker, idiopathic macular hole, and vitreomacular traction
35 syndrome. The dye was injected into the fluid filled globe. Unstained and stained
36 epiretinal tissue was harvested consecutively and placed into separate containers. All
37 specimens were processed for conventional transmission electron microscopy.

38 **Results.** The first surgical specimen of all eyes showed no intraoperative staining
39 with BBG and corresponded to masses of cells and collagen. The second surgical
40 specimen demonstrated good staining characteristics and corresponded to the ILM in
41 all patients included. In seven eyes, the ILM specimens were seen with minor cell
42 proliferations such as single cells or a monolayer of cells. Myofibroblasts, fibroblasts
43 and astrocytes were present. In five cases, native vitreous collagen fibrils were found
44 at the ILM. In six of all eyes, ILM specimens were blank.

45 **Conclusion.** Our clinicopathologic correlation underlines the selective staining
46 properties of BBG. The residual ILM is selectively stained by BBG even when a small
47 amount of cells and collagen adheres to its vitreal side. To reduce the retinal
48 exposure to the dye, the surgeon might choose to remove the ERM without using the
49 dye, followed by a BBG injection to identify residual ILM.

50

51

52 **Introduction**

53 In macular surgery, the intravitreal administration of brilliant blue G (BBG) became a
54 favorable tool to visualize the otherwise translucent internal limiting membrane (ILM).
55 In contrast to other vital dyes such as indocyanine green (ICG), BBG was shown to
56 have a good safety profile providing satisfactory anatomical and functional
57 postoperative results.[1-8] Brilliant blue G is now considered the dye of choice to
58 stain the ILM by many vitreoretinal surgeons with respect to its selective staining
59 properties.

60 In order to perform macular surgery safely and obtain the best possible
61 functional results for the patient, it is of great importance that the surgeon can rely on
62 the staining pattern of BBG. However, in the presence of epiretinal tissue, the dye
63 has no access to the ILM. Therefore, ERM formation may impair sufficient staining of
64 the ILM. Poor staining may result in an incomplete removal of the ILM associated
65 with residual ILM fragments with an indefinite extent of cells and collagen remnants
66 at the vitreal side of the ILM.[9] ILM remnants may contribute to ERM recurrences or
67 reopening of a macular hole by serving as a scaffold for cellular proliferation.

68 Although vital dyes such as BBG facilitate macular surgery, we need to consider
69 tissue-dye interactions and potential adverse effects associated with these adjuncts.

70 The differentiation of ultrastructural components of unstained and stained
71 tissue removed by BBG-assisted peeling might have an impact on the intraoperative
72 procedure in macular surgery. Knowing about the staining pattern and the reliability
73 of staining characteristics will help the vitreoretinal surgeon to adjust the use of BBG
74 to situations, in which the dye provides relevant information. We conducted this
75 laboratory investigation to elucidate the morphologic correlate of sequentially peeled
76 ERM and ILM specimens after BBG staining.

78 Patients and methods

79 Thirteen eyes from thirteen patients underwent vitrectomy with removal of both the
80 ERM and the ILM as a sequential peeling procedure with double BBG staining during
81 January 2008 and April 2009 at the University Eye Hospital Munich. We included
82 nine patients with idiopathic macular pucker (IMP), two patients with idiopathic
83 macular holes (IMH), and two patients with vitreomacular traction syndrome (VMTS).
84 The study was approved by the local Institutional review board (IRB) and ethics
85 committee.

86 The surgical technique consisted of a standard three-port pars plana
87 vitrectomy with induction of a posterior vitreous detachment by suction with the
88 vitrectomy probe around the optic nerve head. A sterile 0.2mg/ml Brilliant blue G
89 solution (0.5 ml, 0.25%, Brilliant Peel[®]; Fluoron[®] GmbH, Neu-Ulm, Germany) was
90 injected into the fluid-filled vitreous cavity over the macular area and washed out
91 immediately. The staining characteristics were assessed by the surgeon. Then,
92 unstained tissue was removed in a first step. This was followed by a reinjection of a
93 few drops of BBG. In a second step, tissue stained with BBG was removed and
94 harvested respectively. ERM and ILM removal was conducted using an end-gripping
95 forceps. Surgery was completed by gas tamponade in IMH patients (15% C2F6 gas
96 mixture) after fluid-air exchange, and patients were encouraged to keep face-down
97 positioning for four days.

98 The ERM and ILM specimens harvested during vitrectomy were immediately
99 placed into phosphate-buffered 4% glutaraldehyde solution for fixation. Specimens
100 were processed for light and electron microscopy as reported previously.[10]
101 Analysis and imaging of about 50 ultrathin sections per specimen were performed
102 using a Zeiss light microscope and a Zeiss EM 9 S-2 electron microscope (Zeiss,
103 Jena, Germany). The morphological analysis was blinded and focused on both the

104 vitreal and the retinal side of the ILM if present which included the documentation of
 105 distribution and type of cells and collagen. The ultrastructural features of cells and
 106 extracellular matrix components were characterised as previously listed, and retinal
 107 debris at the ILM was rated using a four-point grading scale as previously
 108 reported.[11,12]

109

110 **Results**

111 Twenty-six surgical specimens from eighteen women and eight men were included in
 112 this study, corresponding to 16 right eyes and 10 left eyes. The average age at time
 113 of surgery was 70 years (range 62-80 years). In all eyes, two specimens per eye
 114 were analysed. Table 1 demonstrates the ultrastructural findings of all patients:

115

no. of patients	diagnosis	first surgical specimen, no staining					second surgical specimen, good staining				
		ILM	cell proliferation*	collagen			ILM	cell proliferation*	collagen		
				NVC	NFC	FLSC			NVC	NFC	FLSC
1	IMH	-	multilayer	++	+	+	present	single cells	-	-	-
2	IMH	-	multilayer	+	+	-	present	none	-	-	-
3	IMP	present	multilayer	++	++	+	present	single cells	-	-	-
4	IMP	present	multilayer	-	+++	-	present	single cells	+	-	-
5	IMP	-	monolayer	+++	+	-	present	monolayer	++	+	-
6	IMP	-	multilayer	-	+++	-	present	none	-	-	-
7	IMP	-	multilayer	+++	++	+	present	single cells	++	-	+
8	IMP	-	multilayer	++	++	-	present	none	-	-	-
9	IMP	-	multilayer	++	++	-	present	none	-	-	-
10	IMP	present	multilayer	+++	++	-	present	single cells	+	-	-
11	IMP	-	multilayer	++	++	-	present	none	-	-	-
12	VMTS	-	multilayer	+++	++	-	present	none	-	-	-
13	VMTS	-	multilayer	+++	++	-	present	monolayer	+	-	-

116

117 **Table 1.** Ultrastructural features of both the first and the second surgical specimens
 118 removed consecutively in macular surgery with brilliant blue G staining.

119

120 *cell proliferation at the vitreal side of the inner limiting membrane if present

121 IMH = idiopathic macular hole

122 IMP = idiopathic macular pucker

123 VMTS = vitreomacular traction syndrome

124 ILM = inner limiting membrane
125 NVC = native vitreous collagen
126 NFC = newly formed collagen
127 FLSC = fibrous long spacing collagen
128

129 The first surgical specimen of all eyes, which showed no staining with BBG
130 (fig. 1), revealed masses of cells and collagen (fig. 2A). In three specimens from eyes
131 with IMP we found fragments of the ILM, which were removed along with the first –
132 unstained - surgical specimen (fig. 2A). Cell proliferations were distributed as cell
133 multilayers on irregularly folded collagen strands (fig. 3A). Myofibroblasts were the
134 predominating cell type. They were characterised by a lobulated cell nucleus and
135 aggregates of 5-7 nm subplasmalemmal cytoplasmatic filaments with fusiform
136 densities. Cell proliferations often showed polarization with prominent microvillous
137 processes and interposition of native vitreous collagen as well as newly formed
138 collagen. Fibrils of native vitreous collagen were regularly arranged with a diameter
139 of 10 nm to 16 nm, whereas fibrils of newly formed collagen were irregularly
140 distributed with a diameter of more than 16 nm. In three specimens, fibrous long
141 spacing collagen was seen that presented with a symmetrical cross-striation of
142 periodicity. In about half of all eyes with IMP, collagen fibrils were densely packed
143 similar to a basal lamina like strand (fig. 3B).

144 The second surgical specimen was removed sequentially after a second
145 administration of BBG and demonstrated good staining characteristics
146 intraoperatively. The histological evaluation of these specimens confirmed that all
147 these membranes corresponded to the ILM (fig.2B). In five cases, some remaining
148 collagen fibrils were found at the vitreal side of the ILM, mainly described as native
149 vitreous collagen (fig. 3C). When collagen was found at the ILM, cell proliferation was
150 always present. In seven eyes, the ILM specimens were seen with minor cell
151 proliferations such as single cells or cell monolayers (fig. 3D). Myofibroblasts,
152 fibroblasts and fibrous astrocytes were present. Fibroblasts were characterised by

153 abundant rough endoplasmatic reticulum, prominent golgi complexes and the
154 absence of intracytoplasmatic filaments. Fibrous astrocytes were characterised by
155 masses of intracytoplasmatic intermediate-type filaments and polarization with
156 basement membrane production. Of note, cell or collagen remnants at the vitreal side
157 of the ILM did not interfere with the positive staining during surgery. In six of all eyes,
158 ILM specimens were devoid of cells and collagen. Retinal debris was solitarily
159 distributed as small round cell fragments directly adjacent to the retinal side of the
160 ILM.

161

162 **Conclusion**

163 Our findings indicate that epiretinal membrane formation reduces sufficient
164 visualization of the ILM during BBG-assisted macular surgery, and that BBG does
165 provide a selective staining of the ILM. In this study, ERM specimens showed
166 intraoperatively no staining with BBG, despite the presence of ILM fragments in some
167 of the ERM specimens, because massive epiretinal cell and collagen proliferation
168 prevented a positive staining with BBG independent from the diagnosis. After having
169 peeled the unstained ERM following the initial administration of BBG, residual
170 collagen fibrils and some epiretinal cells were seen to remain adherent at the ILM.
171 However, ILM remnants could be visualized reliably using BBG, even if a small
172 amount of cells and collagen fibrils adhered to the vitreal side of the ILM.

173 From previous investigations we have learned that the ILM is often only partly
174 removed along with an ERM.[13] Remaining ILM fragments have been associated
175 with recurrent ERM formation.[14-16] Therefore, a thorough removal of the ILM is
176 crucial for anatomic and functional long term success in order to remove the scaffold
177 for further cell proliferation and contraction.

178 We believe that our findings have implications for the surgical technique of
179 tractional maculopathies. In this context, firstly, we question whether it is necessary

180 to apply vital dyes to stain and remove epiretinal tissue. Secondly, in epiretinal
181 membrane surgery, when the surgeon intends to additionally remove the ILM, it has
182 to be questioned whether double staining procedures are indeed mandatory as
183 described previously.[17] We conclude from the present clinicopathological
184 correlation with BBG that it may be sufficient to remove epiretinal tissue without dye
185 assistance. The use of the dye could be limited to visualize ILM remnants, to peel
186 them off safely, thereby removing cells and collagen adherent to the vitreal side of
187 the ILM that otherwise being left behind at the macula. In other words, BBG helps to
188 identify the ILM and facilitates its complete removal.

189 In general, the application of vital dyes should be limited to situations when
190 they are really helpful and necessary. The results provided in this study represent a
191 step in that direction.

192

193 **Licence for Publication**

194 The Corresponding Author has the right to grant on behalf of all authors and does
195 grant on behalf of all authors, an exclusive licence (or non exclusive for government
196 employees) on a worldwide basis to the BMJ Publishing Group Ltd and its Licensees
197 to permit this article (if accepted) to be published in BJO editions and any other
198 BMJPGJL products to exploit all subsidiary rights, as set out in our licence
199 (<http://group.bmj.com/products/journals/instructions-for-authors/licence-forms/>).

200

201 **Competing Interest**

202 None declared.

203

204 **References**

- 205 1 Enaida H, Hisatomi T, Goto Y, et al. Preclinical investigation of internal limiting
206 membrane peeling and staining using intravitreal brilliant blue G. *Retina*
207 2006;26:623-30.
- 208 2 Enaida H, Ishibashi T. Brilliant blue in vitreoretinal surgery. *Dev Ophthalmol*
209 2008;42:115-25.
- 210 3 Haritoglou C, Thaler S, Kampik A, et al. Vital dyes in vitreoretinal surgery. *Current*
211 *application concepts. Ophthalmologe* 2009;106:7-10.
- 212 4 Henrich PB, Haritoglou C, Meyer P, et al. Anatomical and functional outcome in
213 brilliant blue G assisted chromovitrectomy. *Acta Ophthalmol* 2009 Apr 23. [Epub
214 ahead of print]
- 215 5 Kawahara S, Hata Y, Miura M, et al. Intracellular events in retinal glial cells
216 exposed to ICG and BBG. *Invest Ophthalmol Vis Sci* 2007;48:4426-32.
- 217 6 Lüke M, Januschowski K, Beutel J, et al. Electrophysiological effects of brilliant
218 blue G in the model of the isolated perfused vertebrate retina. *Graefe's Arch Clin Exp*
219 *Ophthalmol* 2008;246:817-22.
- 220 7 Remy M, Thaler S, Schumann RG, et al. An in vivo evaluation of brilliant blue G in
221 animals and humans. *Br J Ophthalmol* 2008;92:1142-47.
- 222 8 Schumann RG, Remy M, Grueterich M, et al. How it appears: electron microscopic
223 evaluation of internal limiting membrane specimens obtained during brilliant blue G
224 assisted macular hole surgery. *Br J Ophthalmol* 2008;92:330-31.
- 225 9 Kifuku K, Hata Y, Kohno R-I, Kawahara S, Mochizuki Y, Enaida H, Sonoda K-h,
226 Ishibashi T. Residual internal limiting membrane in epiretinal membrane surgery. *Br J*
227 *Ophthalmol* 2009;93:1016-19.
- 228 10 Schumann RG, Schaumberger MM, Rohleder M, et al. Ultrastructure of the
229 vitreomacular interface in full-thickness idiopathic macular holes: a consecutive
230 analysis of 100 cases. *Am J Ophthalmol.* 2006;141:1112-19.

231 11 Gandorfer A, Rohleder R, Grosselfinger S, et al. Epiretinal pathology of diffuse
232 diabetic macular edema associated with vitreomacular traction. *Am J Ophthalmol*
233 2005;139:638-52.

234 12 Schumann RG, Gandorfer A, Priglinger SG, et al. Vital dyes for macular surgery:
235 A comparative electron microscopy study of the internal limiting membrane. *Retina*
236 2009;29:669-76.

237 13 Kampik A, Green WR, Michels RG, et al. Ultrastructural features of progressive
238 idiopathic epiretinal membrane removed by vitreous surgery. *Am J Ophthalmol*
239 1980;90:797-809.

240 14 Kwok AK, Lai TY, Yuen KS. Epiretinal membrane surgery with or without internal
241 limiting membrane peeling. *Clin Exp Ophthalmol* 2005;33:379-85.

242 15 Maguire AM, Smiddy WE, Nanda SK, et al. Clinicopathologic correlation of
243 recurrent epiretinal membranes after previous surgical removal. *Retina* 1990;10:213-
244 22.

245 16 Shimada H, Nakashizuka H, Hattori T, et al. Double staining with brilliant blue G
246 and double peeling for epiretinal membranes. *Ophthalmology* 2009;116:1370-76.

247 17 Stalmans P, Freon EJ, Parys-Van Ginderdeuren R, et al. Double vital staining
248 using trypan blue and infracyanine green in macular pucker surgery. *Br J Ophthalmol*
249 2003;87:713-16.

250

251

252

253

254 **Figure legends**

255

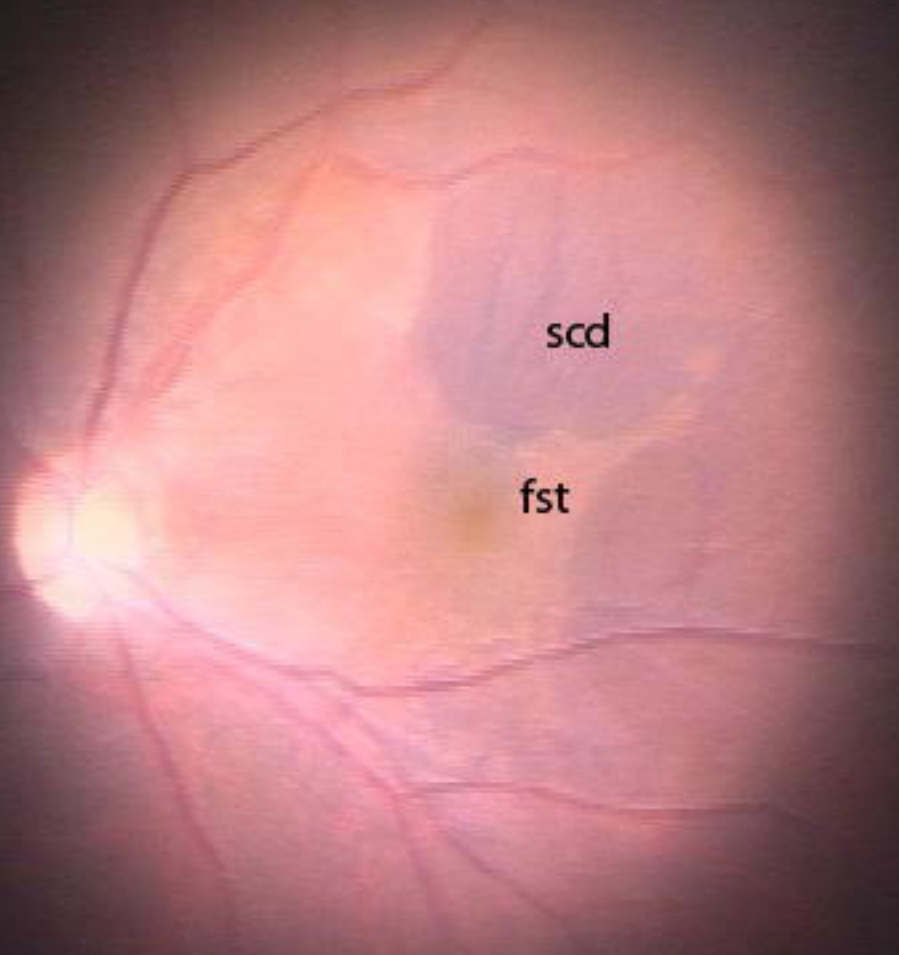
256 **Fig. 1:** Intraoperative observation of unstained tissue (fst) that was removed first, and
257 stained tissue (scd) that was sequentially removed presenting with a blue-coloured
258 appearance.

259

260 **Fig. 2:** Light micrographs of unstained (A) and stained (B) tissue removed
261 consecutively by brilliant blue G-assisted peeling in macular surgery for macular
262 pucker. (A) Cell proliferations (arrows) were irregularly distributed as cell multilayers
263 on folded collagen strands (arrowheads). (B) The internal limiting membrane
264 (asterisk) was seen devoid of cells and collagen with a characteristic undulated
265 retinal side (arrow) and a smooth vitreal side (arrowhead). (Original magnification: x
266 1000)

267

268 **Fig. 3:** Transmission electron micrographs of unstained (A, B) and stained (C, D)
269 tissue removed consecutively by brilliant blue G-assisted peeling in macular surgery
270 for macular pucker. (A) Myofibroblasts that were characterised by a lobulated cell
271 nucleus and aggregates of 5-7 nm subplasmalemmal cytoplasmatic filaments
272 dominated in cell proliferations on masses of newly formed collagen (arrow). Newly
273 formed collagen was irregularly packed with a fibril diameter of more than 16 nm. (B)
274 Collagen fibrils were often found densely packed similar to a basal lamina like strand
275 (arrow). (C) Single collagen fibrils (arrow) were distributed at the vitreal side of the
276 ILM (asterisk). (D) Native vitreous collagen fibrils (arrow) with a diameter of 10 nm to
277 16 nm were interposed between single epiretinal cells and the ILM (asterisk). Retinal
278 debris was mostly seen as small round cell fragments (arrowhead) at the undulated
279 side of the ILM. (Original magnification: (A) x 1800; (B, C, D) x 4800)



scd

fst

