



Usutu virus in wild birds in northern Italy

G. Manarolla, T. Bakonyi, D. Gallazzi, L. Crosta, H. Weissenböck, G.M.
Dorrestein, N. Nowotny

► To cite this version:

G. Manarolla, T. Bakonyi, D. Gallazzi, L. Crosta, H. Weissenböck, et al.. Usutu virus in wild birds in northern Italy. *Veterinary Microbiology*, 2010, 141 (1-2), pp.159. 10.1016/j.vetmic.2009.07.036 . hal-00560845

HAL Id: hal-00560845

<https://hal.science/hal-00560845>

Submitted on 31 Jan 2011

HAL is a multi-disciplinary open access archive for the deposit and dissemination of scientific research documents, whether they are published or not. The documents may come from teaching and research institutions in France or abroad, or from public or private research centers.

L'archive ouverte pluridisciplinaire **HAL**, est destinée au dépôt et à la diffusion de documents scientifiques de niveau recherche, publiés ou non, émanant des établissements d'enseignement et de recherche français ou étrangers, des laboratoires publics ou privés.

Accepted Manuscript

Title: Usutu virus in wild birds in northern Italy

Authors: G. Manarolla, T. Bakonyi, D. Gallazzi, L. Crosta, H. Weissenböck, G.M. Dorrestein, N. Nowotny

PII: S0378-1135(09)00358-7
DOI: doi:10.1016/j.vetmic.2009.07.036
Reference: VETMIC 4528

To appear in: *VETMIC*

Received date: 20-3-2009
Revised date: 20-7-2009
Accepted date: 31-7-2009



Please cite this article as: Manarolla, G., Bakonyi, T., Gallazzi, D., Crosta, L., Weissenböck, H., Dorrestein, G.M., Nowotny, N., Usutu virus in wild birds in northern Italy, *Veterinary Microbiology* (2008), doi:10.1016/j.vetmic.2009.07.036

This is a PDF file of an unedited manuscript that has been accepted for publication. As a service to our customers we are providing this early version of the manuscript. The manuscript will undergo copyediting, typesetting, and review of the resulting proof before it is published in its final form. Please note that during the production process errors may be discovered which could affect the content, and all legal disclaimers that apply to the journal pertain.

Usutu virus in wild birds in northern Italy

*Manarolla G.¹, Bakonyi T.^{2,3}, Gallazzi D.¹, Crosta L.⁴, Weissenböck H.⁵, Dorrestein G.M.⁶,
and Nowotny N.²

¹Dipartimento di Patologia Animale, Igiene e Sanità Pubblica Veterinaria, Università degli
Studi di Milano, via Celoria 10, 20133 Milano, Italy; ²Zoonoses and Emerging Infections
Group, Clinical Virology, Department of Pathobiology, University of Veterinary Medicine,
Vienna, Veterinärplatz 1, 1210 Vienna, Austria; ³Department of Microbiology and Infectious
Diseases, Faculty of Veterinary Science, Szent István University, Hungária krt. 23-25, 1143
Budapest, Hungary; ⁴Centro Servizi Veterinari Valcurone SRL, Via Kennedy S/N 79, 23873
Missaglia (LC) Italy; ⁵Institute of Pathology and Forensic Veterinary Medicine, Department
of Pathobiology, University of Veterinary Medicine Vienna, Veterinärplatz 1, 1210 Vienna,
Austria; ⁶Diagnostic Pathology Laboratory NOIVBD, Wintelresedijk 51, 5507 PP Veldhoven,
The Netherlands.

* Corresponding author - Phone number: 0039 02 50318104 Fax number: 0039 02 50318106
E-mail: giovanni.manarolla@unimi.it Correspondence address: Giovanni Manarolla c/o
DIPAV, Facoltà di Medicina Veterinaria, via Celoria 10, 20133 Milano – Italy

ABSTRACT

Usutu virus (USUV) infection was diagnosed in two free living blackbirds and in three captive owls belonging to two different species in northern Italy in the summers of 2006-2008. Diagnosis was established by immunohistochemistry and RT-PCR. RT-PCR was performed on frozen and on paraffin-embedded tissues (PET), respectively. From the frozen samples a partial sequence of the putative USUV E and NS1 proteins (1229 bp) was determined, whereas partial sequences of the putative NS3 (278 bp) and NS5 (159 bp) proteins were obtained from PET. Additionally, one partial sequence (163 bp) of the putative 3'UTR region was determined from all samples. Sequencing of the amplification products revealed 99.8 to 100% nucleotide identity of the Italian USUV strains to those from other central European countries.

Keywords: Usutu virus, wild birds, immunohistochemistry, RT-PCR, sequencing

INTRODUCTION

Usutu virus (USUV) is a mosquito-borne flavivirus closely related to important human pathogens such as Japanese encephalitis virus, Murray Valley encephalitis virus, Saint Louis encephalitis virus and West Nile virus (Kuno et al., 1998; Bakonyi et al., 2004). USUV infection emerged in Austria in 2001, and has been associated with avian mortality for five consecutive summers since, affecting predominantly blackbirds (*Turdus merula*) (Weissenböck et al., 2002; Bakonyi et al., 2007). USUV outbreaks have also been recently reported from Hungary (Bakonyi et al., 2007) and Switzerland (Steinmetz et al., 2007). The disease in birds is characterized by encephalitis, myocardial degeneration, and necrosis in liver and spleen (Chvala et al., 2004).

This paper reports the first detection of USUV antigens and nucleic acid in wild birds in northern Italy.

MATERIALS AND METHODS

Animals and samples

2006: The first case suspicious of USUV infection in Italy was identified nearby Milan in 2006, in a collection of 70 owls from all over the world belonging to 32 species. In August 2006, one great grey owl (*Strix nebulosa*) showed suddenly signs of apathy associated with ruffled plumage and increased water intake. The bird died within 2-3 days after onset of clinical symptoms on August 5th, 2006. Further 5 birds of the same species died within a time span of 6 weeks after showing similar signs. Other owls of different species belonging to the same owl collection remained healthy. The first-mentioned dead owl was submitted for diagnostic investigations, and was necropsied. Samples of liver, spleen, lung, kidney, ovary, adrenals, thyroids, bone marrow, proventriculus, gizzard, intestines and pancreas were collected, fixed in 10% buffered formalin, and routinely processed for histopathology.

2007: In summer 2007, 2 adult boreal owls (*Aegolius funereus*), one male and one female, of the same collection where the great grey owls had died in 2006, got sick. First, they looked apathetic and anorectic. After 24 hours they stood on the aviary floor looking for drinking water, and died within three days after onset of the first symptoms. Both birds were necropsied. Samples of liver, spleen, lung, kidneys ovary and adrenals were processed for histopathology as described below. Six offspring of the same species and birds of two other species - Eurasian pygmy owl (*Glaucidium passerinum*) and northern hawk-owl (*Surnia ulula*) - died with similar symptoms in the same time period but were not examined due to post mortal autolysis. On August 28th, 2007, one free-living adult female Eurasian blackbird (*Turdus merula*) was found in downtown Milan unable to fly, dull, and had been easily caught by hand. It died spontaneously a few minutes after submission to the Department and was immediately necropsied. Samples of liver, spleen, heart, lung, kidney, brain, eyes, proventriculus, gizzard, intestines and pancreas were fixed in 10% buffered formalin and routinely processed for histopathology. Additional samples of the same organs were stored at -20°C.

2008: One year later, in July 2008, a male wild Eurasian blackbird was found dead in the garden of the owl breeder in the Milan area. The bird was necropsied and samples of liver, spleen, lung, kidneys and heart were collected for histopathology.

Histopathology and immunohistochemistry

Four micrometer thick paraffin-wax sections of the investigated birds were stained with haematoxylin-eosin and examined by light microscopy. Additional sections from the great grey owl and the boreal owls, and from the first-mentioned Eurasian blackbird were stained for demonstration of viral antigen using a rabbit polyclonal antiserum to USUV (produced at the Department of Microbiology, Faculty of Veterinary Science, Budapest) and the avidin-

biotin complex technique, as described previously (Weissenböck et al., 2004). Brain sections of experimentally infected suckling mice were included as positive controls, and sections of the samples incubated with normal rabbit serum served as negative controls.

RT-PCR, sequencing, and sequence analysis

Paraffin-embedded tissue (PET) samples (from the owls and from the second (2008) blackbird) and frozen, unfixed organ samples (from the first blackbird) were submitted for molecular investigations. The PET samples were deparaffinated by xylol and ethanol treatment, and digested with proteinase K prior to nucleic acid extraction (Weissenböck et al., 2003). Unfixed organ samples were homogenized, suspended in RNase-free water, centrifuged at 6,000 ×g for 5 min, and the supernatants were used for RNA extraction. Viral nucleic acids were extracted by the QiaAmp Viral RNA Mini Kit (Qiagen, Germany) according to the manufacturer's instructions. The viral nucleic acid was reverse-transcribed and amplified in continuous RT-PCR assays, using USUV-specific oligonucleotide primers and the Qiagen One-Step RT-PCR kit (Bakonyi et al., 2004). From the frozen samples (2007 blackbird), one partial sequence of the putative E and NS1 proteins (1229 bp) was obtained. In the case of PET-derived samples, shorter genome regions were amplified, i.e. partial sequences of the putative NS3 protein (278 bp) from the great grey owl and of the putative NS5 protein (159 bp) for the boreal owls. In addition, one partial sequence (163 bp) of the putative 3'UTR region was determined for all samples. Detailed information on the primers is summarized in Table 1. The thermal profile of the amplifications contained a reverse transcription step at 50°C for 30 min, followed by HotStarTaq activation at 95°C for 15 min, and 40 cycles of amplification at 94°C – 40 sec, 57°C – 50 sec, 72°C – 1 min, respectively. After a final elongation step at 72°C for 7 min, the reaction mixtures were stored cooled until

1 electrophoresis. Amplification products were electrophoresed in 1.5% agarose gel, and
2 following ethidium bromide staining they were visualized under UV light.

3 PCR products with expected size were excised from the gel, purified, and the nucleotide
4 sequences were determined in both directions using fluorescence-based direct sequencing
5 reactions (Bakonyi et al., 2004). The nucleotide sequences were identified by BLAST search
6 against the GenBank database (<http://blast.ncbi.nlm.nih.gov/Blast.cgi>). After manual editing
7 and excluding primer regions, the sequences were compiled and aligned with the USUV
8 complete genome sequences deposited in GenBank database (accession numbers AY453411,
9 AY453412 and EF206350) with the help of the Align Plus 4 (Scientific and Educational
10 Software) and ClustalX (Thomson et al., 1997) programs. The putative amino acid sequences
11 were also deduced.

13 RESULTS

14 Gross and microscopic findings

15 **2006:** The great grey owl showed at necropsy an enlarged and congested liver. No other gross
16 changes were noticed. Lympho-plasmacytic infiltrates were detected in liver, spleen and
17 kidney. USUV positive immunolabelling was observed in liver, lung, spleen and ovary.

18 **2007:** The boreal owls were in good body condition. At necropsy the female showed only
19 nephromegaly. Hepatomegaly associated with enlargement and discoloration of the kidneys
20 were observed in the male. Histologically, liver and kidney sections of the female boreal owl
21 were characterized by locally extensive lympho-plasmacytic infiltrates. In male boreal owl,
22 liver sections revealed periportal lympho-plasmacytic infiltrates. The spleen was
23 characterized by zonal necrosis centred on the sheathed arteries associated with histiocytic
24 hyperplasia. Minimal lympho-plasmacytic perivascular cuffings were detectable in the lungs.

USUV positive immunolabelling was detected in liver, lung, kidney, spleen and ovary from the female boreal owl, and in lung, kidney, spleen and gizzard from the male.

The blackbird was moulting and lean. Liver and spleen were severely enlarged and hyperaemic (Figures 1-2). The liver was characterized by myriads of small (up to 1 mm) yellowish foci. The gallbladder was enlarged and distended. Meninges and brain were hyperaemic. The intestine was enlarged and contained numerous trematodes. Histopathological investigations revealed multifocal to coalescing areas of non zonal, coagulative necrosis in the liver associated with small, multifocal haemorrhages. Small, multifocal lympho-plasmacytic aggregates were also observed. The spleen was also characterized by small areas of coagulative necrosis. The cardiac sections revealed multifocal infiltrations of lymphocytes and plasma cells with lesser numbers of macrophages centred on fragmented cardiomyocytes. The brain was characterized by increased numbers of microglia with satellitosis and neuronophagia. Sections of the other organs were without pathological findings. Immunohistological examination revealed scattered foci of USUV-immunoreactivity in the encephalon (Figure 3), cerebellum and in some endothelial cells of lung and heart.

2008 The second blackbird showed no remarkable gross changes except for numerous trematodes in the coelom and respiratory tract. Histologically, small, scattered periportal lympho-plasmacytic infiltrates were observed in the liver sections. USUV immunolabelling was detected in liver, spleen, lung, kidneys and heart.

Positive and negative controls gave the expected results.

RT-PCR, sequencing, and sequence analysis. RT-PCR assays employing USUV-specific primer pairs generated amplification products of the expected molecular sizes. The nucleotide sequences of the amplification products were determined, and BLAST searches verified that they are USUV-specific sequences. The partial E protein coding region and the partial 3' UTR

were 100% identical with the corresponding regions of the "USUV-Vienna-2001-blackbird" strain (AY453411), and differed in one nucleotide (C₂₁₈₅ to U substitution) from the "USUV-Budapest-2005-blackbird" strain (EF206350, Bakonyi et al., 2004 and 2007). Within the partial NS3 coding region the great grey owl-derived sequence showed one nucleotide difference (A₄₉₀₀ to G), and in the partial NS5 coding region three nucleotide substitutions (U₉₀₈₇ to C, C₉₁₃₈ to U, and U₉₁₅₃ to C) were observed, compared to the Viennese and Budapest USUV strains. The nucleotide substitution in the NS3 region caused an Ile₁₆₀₂ to Val substitution in the deduced amino acid sequence, while the NS5 nucleotide substitutions remained silent.

DISCUSSION

This report is the first virological proof of USUV in Italy. USUV was detected in free-living blackbirds and in captive owls of two different species during summertime. Gross lesions observed in the dead birds consisted of general congestion, hepatomegaly and splenomegaly of varying severity. Microscopically, encephalitis, myocardial degeneration and necrosis of liver and spleen were found, and point towards multi-organ failure as the cause of death. The species of the affected birds, the season, the clinical and pathological similarities to the USUV cases reported earlier in Austria (Weissenböck, 2002; Chvala et al., 2004) supported a presumptive diagnosis of USUV infection, which was confirmed by IHC and RT-PCR. The partial nucleotide sequences of the Italian USUV strains revealed 99.8 to 100% identity to other central European strains. This result indicates that the USUV strains, which circulate in Italy, are closely related to other European strains, suggesting the possibility that these USUV strains spread to Italy from neighbouring central European countries, where the infection emerged earlier. On the other hand it should be mentioned that the affected bird species in those countries are quite sedentary with little tendency to fly during the season of virus

activity (Weissenböck et al., 2003). Also, these sequence similarities could be considered in a possible future development of an USUV vaccine, which could be potentially valuable to protect endangered and worthy birds such as owls.

In two previous reports (Rizzoli et al., 2007; Lelli et al., 2008) antibodies to USUV had been demonstrated in sentinel chickens in northern Italy; USUV-associated bird mortality, however, was not reported in these publications. Italy has implemented a flaviviral surveillance system for more than a decade including sentinel horses, chicken and cattle. This plan also includes investigations of wild birds found dead. Unfortunately, it is well known that only a fraction of birds dying in the wild are noticed and still only a small proportion of those are collected and made available for laboratory diagnosis (Chvala et al., 2007). Moreover, USUV diagnosis requires adequately conserved tissues. This is infrequent for birds, especially for wild birds, which are usually submitted for laboratory diagnosis with severe post mortal changes. Consequently, it can be argued that USUV infections remain underestimated and unnoticed unless associated with considerable avian mortality. Therefore, dead bird surveillance should be particularly encouraged as suggested by previous experiences (Chvala et al., 2007). Besides, this report points out that zoos and rescue centres can play an important role in monitoring USUV infections. Increased dead bird surveillance would uncover the geographic distribution of USUV-infected birds in Italy, the most frequently affected species, the seasonality of USUV infections, changes in the severity of pathological lesions, and similarities among strains through RT-PCR and subsequent sequencing of the amplification products. Our laboratory diagnosed relatively few cases of USUV infection in wild birds since summer 2007, and no particular mortality has been recorded. On the contrary, checking our database, unexplained outbreaks of blackbird mortality had been observed in Italy since the late 1990's. Blackbirds are considered to be one of the most susceptible host species for USUV infections. Unfortunately, no frozen material

1 from those cases was available. Preliminary results of RT-PCR applied to paraffin embedded
2 tissues of selected cases revealed no positivity for USUV (data not shown). Positivity for
3 West Nile virus is still to be ascertained. More extensive retrospective studies are necessary to
4 establish whether those outbreaks of blackbird mortality in the late nineties were related to
5 flavivirus infections. In that case, herd immunity could justify the few USUV cases recorded
6 in the last few years in Italy, as hypothesized for Austria. Both blackbirds of this report were
7 parasitized by trematodes. As a rule, free-ranging wild birds are commonly afflicted with
8 numerous parasites (Cole and Friend, 1999) which weaken their hosts, and thus might
9 contribute also to facilitate USUV infections. All these aspects need to be ascertained.
10 Therefore, further retrospective studies on archived material as well as prospective
11 surveillance systems should be encouraged worldwide to unveil the origin and other
12 epidemiological characteristics of USUV infection.

13 14 Acknowledgements

15 This study was partially supported by the grants OTKA K67900, OMFB00738/07 and by
16 funds from Regione Lombardia (Italy). T. Bakonyi is grantee of the Bolyai Research
17 Fellowship Grant of the Hungarian Academy of Sciences.

REFERENCES

- Bakonyi, T., Gould, E.A., Kolodziejek, J., Weissenböck, H., Nowotny N., 2004. Complete genome analysis and molecular characterization of Usutu virus that emerged in Austria in 2001: comparison with the South African strain SAAR-1776 and other flaviviruses. *Virology* 328, 301–310.
- Bakonyi, T., Erdélyi, K., Ursu, K., Ferenczi, E., Csörgo, T., Lussy, H., Chvala, S., Bukovsky, C., Meister, T., Weissenböck, H., Nowotny, N., 2007. Emergence of Usutu virus in Hungary. *J. Clin. Microbiol.* 45, 3870-3874.
- Chvala, S., Kolodziejek, J., Nowotny, N., Weissenböck H., 2004. Pathology and viral distribution in fatal Usutu virus infections of birds from the 2001 and 2002 outbreaks in Austria. *J. Comp. Pathol.* 131, 176–185.
- Chvala, S., Bakonyi, T., Bukovsky, C., Meister, T., Brugger, K., Rubel, F., Nowotny, N., Weissenböck, H., 2007. Monitoring of Usutu virus activity and spread by using dead bird surveillance in Austria, 2003-2005. *Vet. Microbiol.* 122, 237-45
- Cole, R.A., Friend, M., 1999. Miscellaneous parasitic diseases. In: Friend, M., Franson, J.C. (Eds.), *Field Manual of Wildlife Diseases—General Field Procedures and Diseases of Birds*, US Department of the Interior Fish and Wildlife Service, Washington, DC p. 249.
- Kuno, G., Chang, G.J., Tsuchiya, K.R., Karabatsos, N., Cropp, C.B., 1998. Phylogeny of the genus *Flavivirus*. *J. Virol.* 72, 73–83.

- Lelli, R., Savini, G., Teodori, L., Filipponi, G., Di Gennaro, A., Leone, A., Di Gialleonardo, L., Venturi, L., Caporale, V., . 2008. Serological evidence of Usutu virus occurrence in north-eastern Italy. *Zoonoses Public Health*. 55, 361-367.
- Rizzoli, A., Rosà, R., Rosso, F., Buckley, A., Gould, E., 2007. West Nile virus circulation detected in northern Italy in sentinel chickens. *Vector Borne Zoonotic Dis.* 7, 411-417.
- Steinmetz, H.W., Bakonyi, T., Chvala, S., Weissenböck, H., Eulenberger, U., Hatt, J.M., Robert, N., Hoop, R., Nowotny, N., 2007. Emergence of Usutu virus in Switzerland. In: *Proceedings 43rd International Symposium on Diseases of Zoo and Wild Animals*, Edinburgh, pp. 129-131.
- Thompson, J.D., Gibson, T.J., Plewniak, F., Jeanmougin, F., Higgins, D.G., 1997. The ClustalX windows interface: flexible strategies for multiple sequence alignment aided by quality analysis tools. *Nucleic Acids Res.* 24, 4876-4882.
- Weissenböck, H., Kolodziejek, J., Url, A., Lussy, H., Rebel-Bauder, B., Nowotny, N., 2002. Emergence of Usutu virus, an African mosquito-borne flavivirus of the Japanese encephalitis virus group, central Europe. *Emerg. Infect. Dis.* 8, 652-656.
- Weissenböck, H., Hubálek, Z., Halouzka, J., Pichlmair, A., Maderner, A., Fragner, K., Kolodziejek, J., Loupal, G., Kölbl, S., Nowotny, N., 2003. Screening for West Nile virus infections of susceptible animal species in Austria. *Epidemiol. Infect.* 131, 1023-1027.

- 1 Weissenböck, H., Bakonyi, T., Chvala, S., Nowotny, N., 2004. Experimental Usutu virus
2 infection of suckling mice causes neuronal and glial cell apoptosis and demyelination. *Acta*
3 *Neuropathol.* 108, 453-460.

4

Accepted Manuscript

Table 1. USUV-specific oligonucleotide primers used in RT-PCR assays, amplified genomic regions and product length

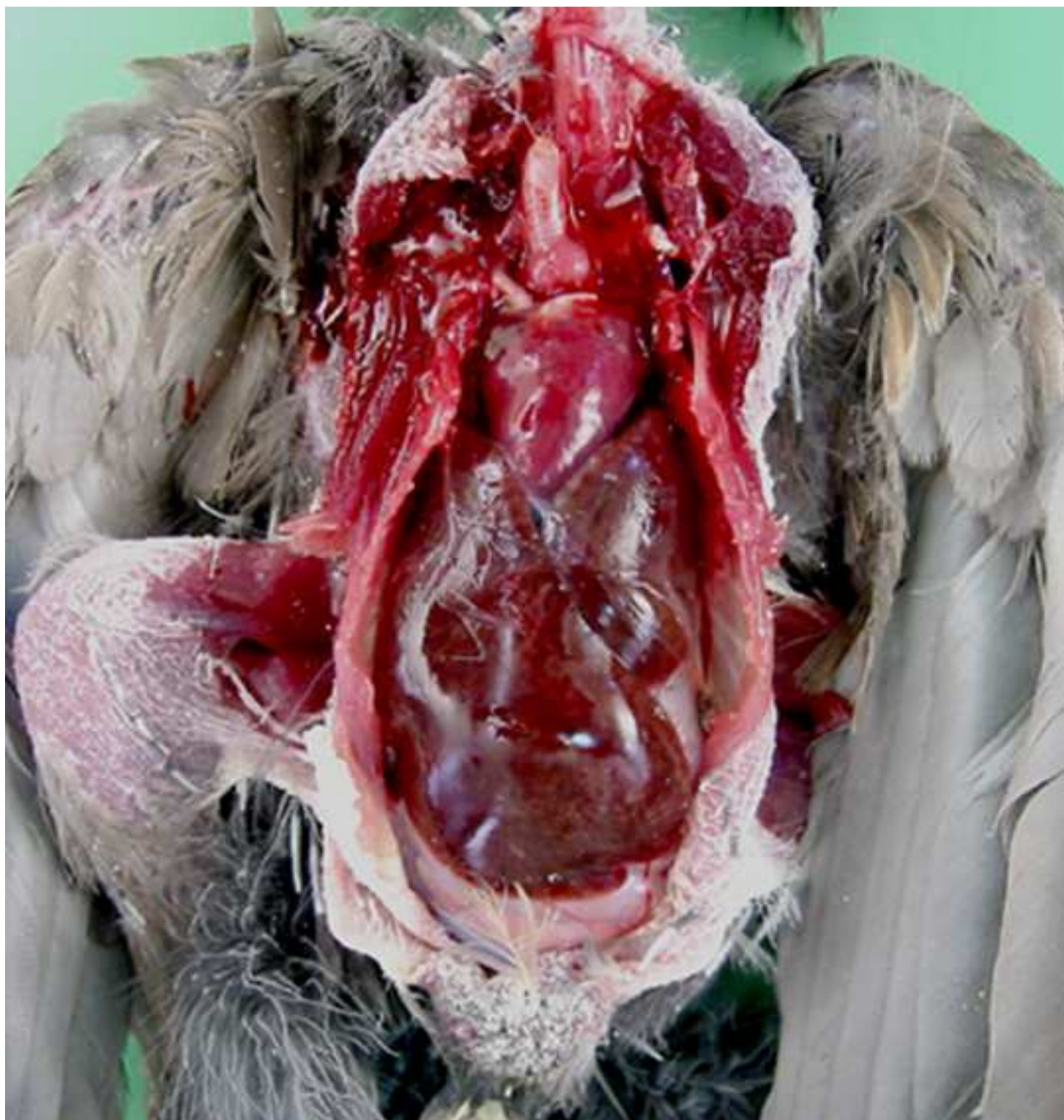Name ^a	Sequence 5' to 3'	Position ^b	Amplified genomic region	Product length (bp)
Usu1155f	CTAGCCACTGTCTCATATGT	1159-1178	partial E	425
Usu1600r	ATGTAGTATGCCTCGGTGTT	1564-1583		
Usu1537f	GGTTGAACACCGAGGCATAC	1555-1578	partial E and NS1	973
Usu2505r	CTTGTCCACAGCGCAACTCT	2508-2527		
<i>Usu4763f</i>	<i>TGGTGAAGGAAGGCTCACTC</i>	<i>4785-4804</i>	<i>partial NS3</i>	318
<i>Usu5080r</i>	<i>ACGATGGCACTGACATACGA</i>	<i>5083-5102</i>		
<i>Usu9247f</i>	<i>CGTGAGATGAGCCACCATTTC</i>	<i>9247-9266</i>	<i>partial NS5</i>	199
<i>Usu9445r</i>	<i>CTGTGCCAGGTCGCATAACT</i>	<i>9426-9445</i>		
<i>Usu10626f</i>	<i>AAGCTGACCGCTGATGATGG</i>	<i>10626-10645</i>	<i>partial 3'UTR</i>	203
<i>Usu10828r</i>	<i>CCACGAACAGTTCGCATCAC</i>	<i>10809-10828</i>		

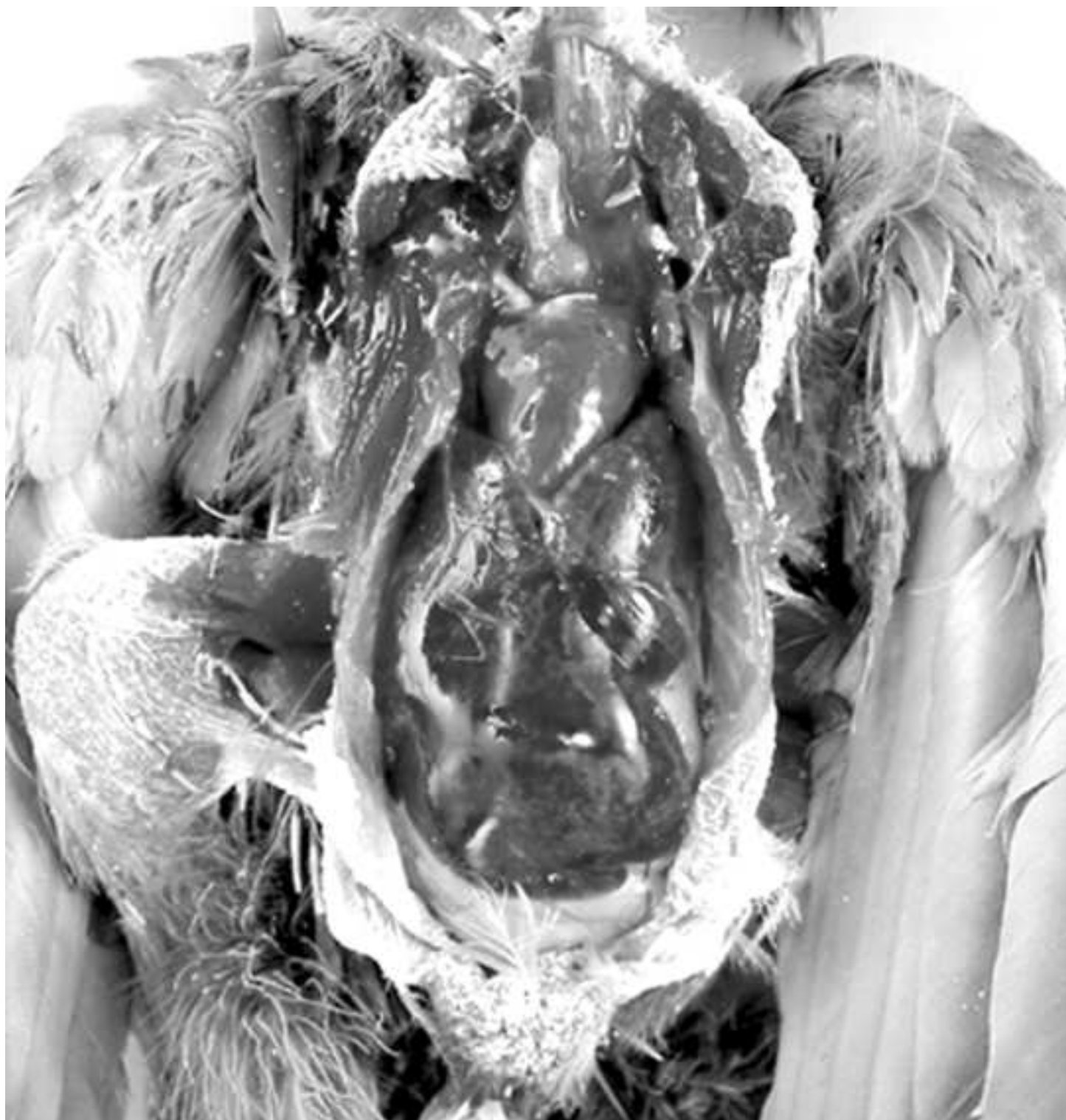^a *in Italics*: Primers used for virus RNA detection in PET-derived samples

^b Positions refer to the genome of USUV strain SAAR-1776 (GenBank accession number AY453412)

f: forward (genomic) primer; r: reverse (complementary) primer

- 1 Figures 1 and 2: Pathological findings in an USUV-infected blackbird: enlarged and
2 hyperaemic liver and spleen.
3
4 Figure 3: Brain section of an USUV-infected blackbird. Positive immunolabelling is
5 detectable in one neuron (arrow). ABC method, Mayer's haematoxylin counterstain. Bar:
6 20µm.





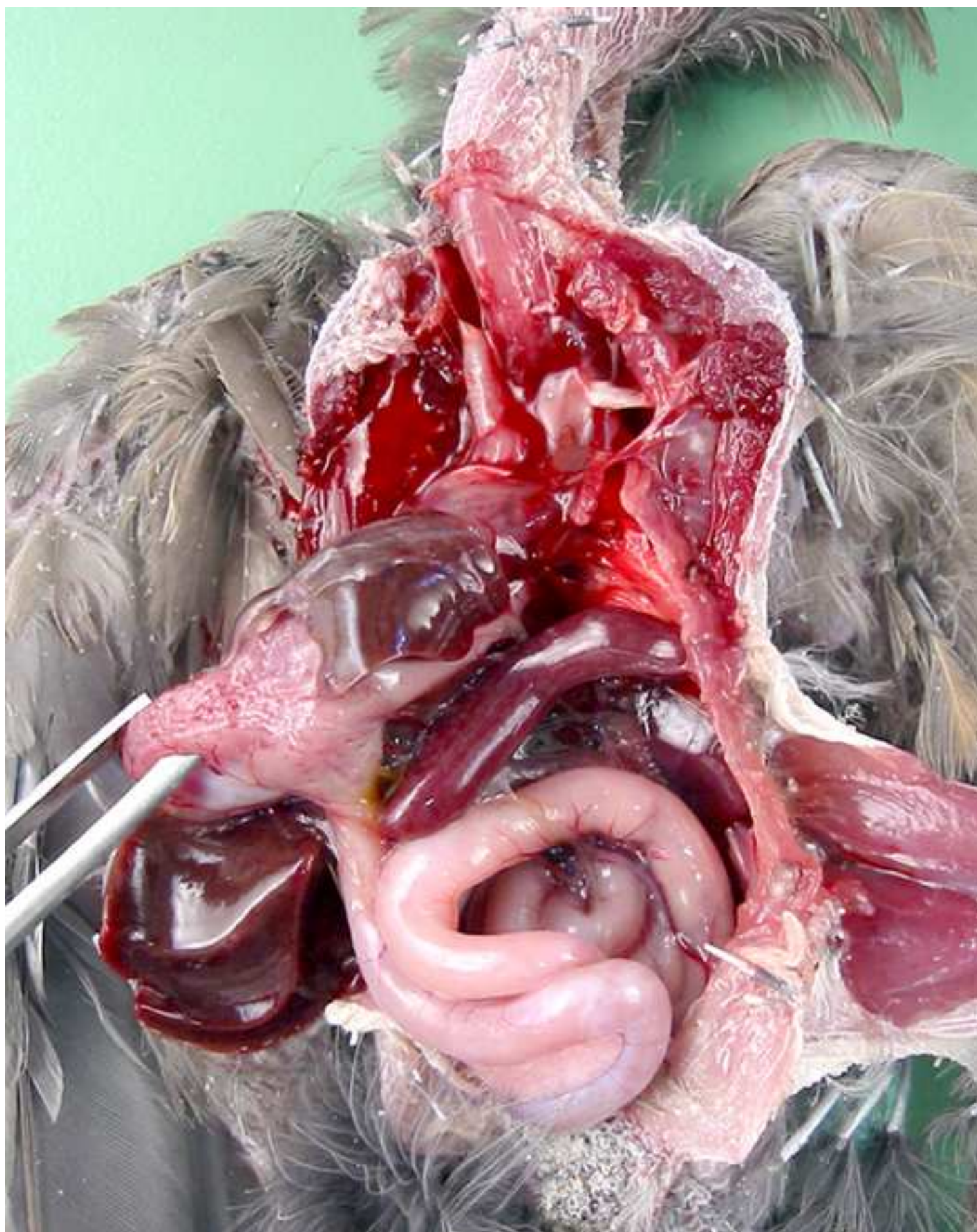

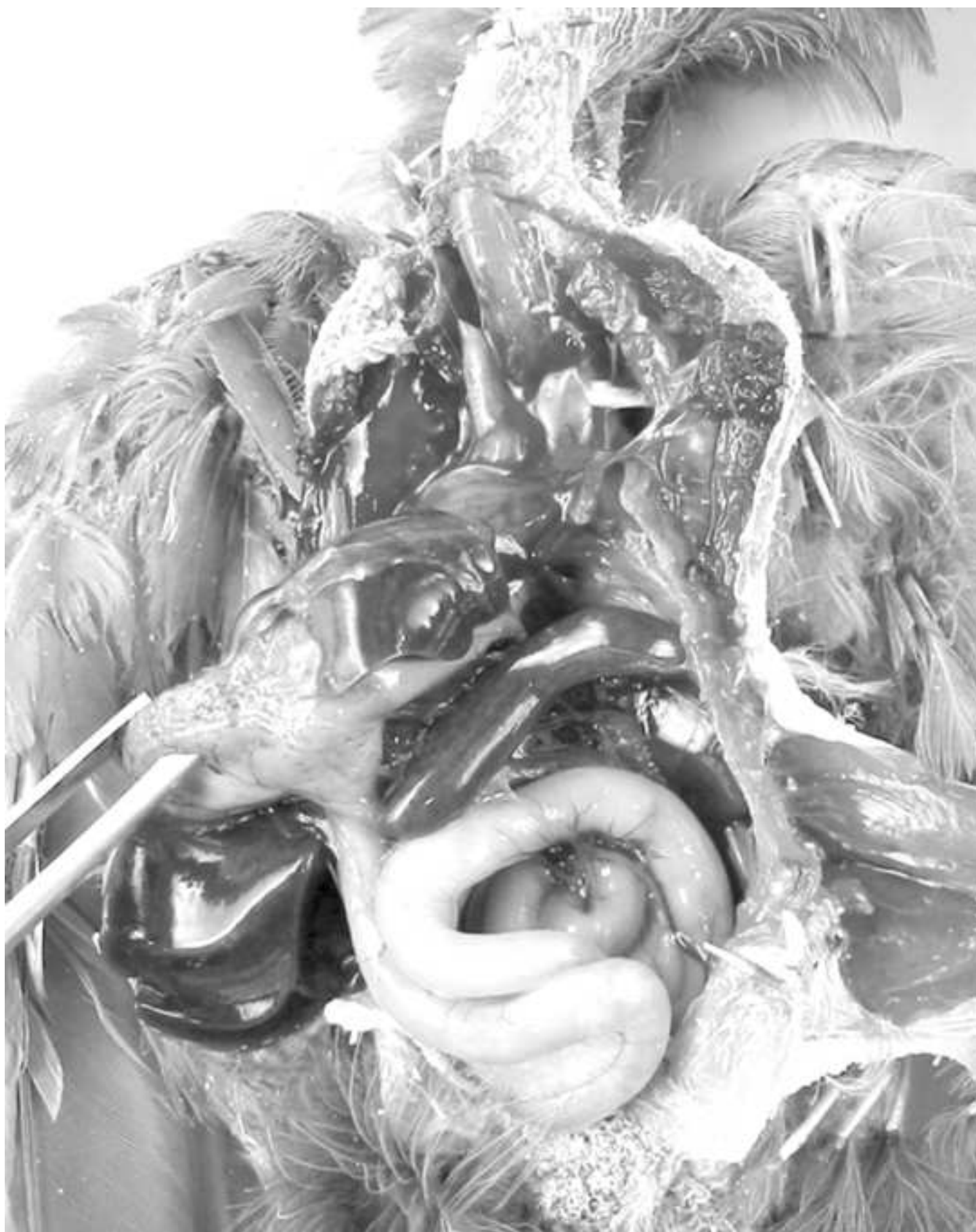


Figure 3

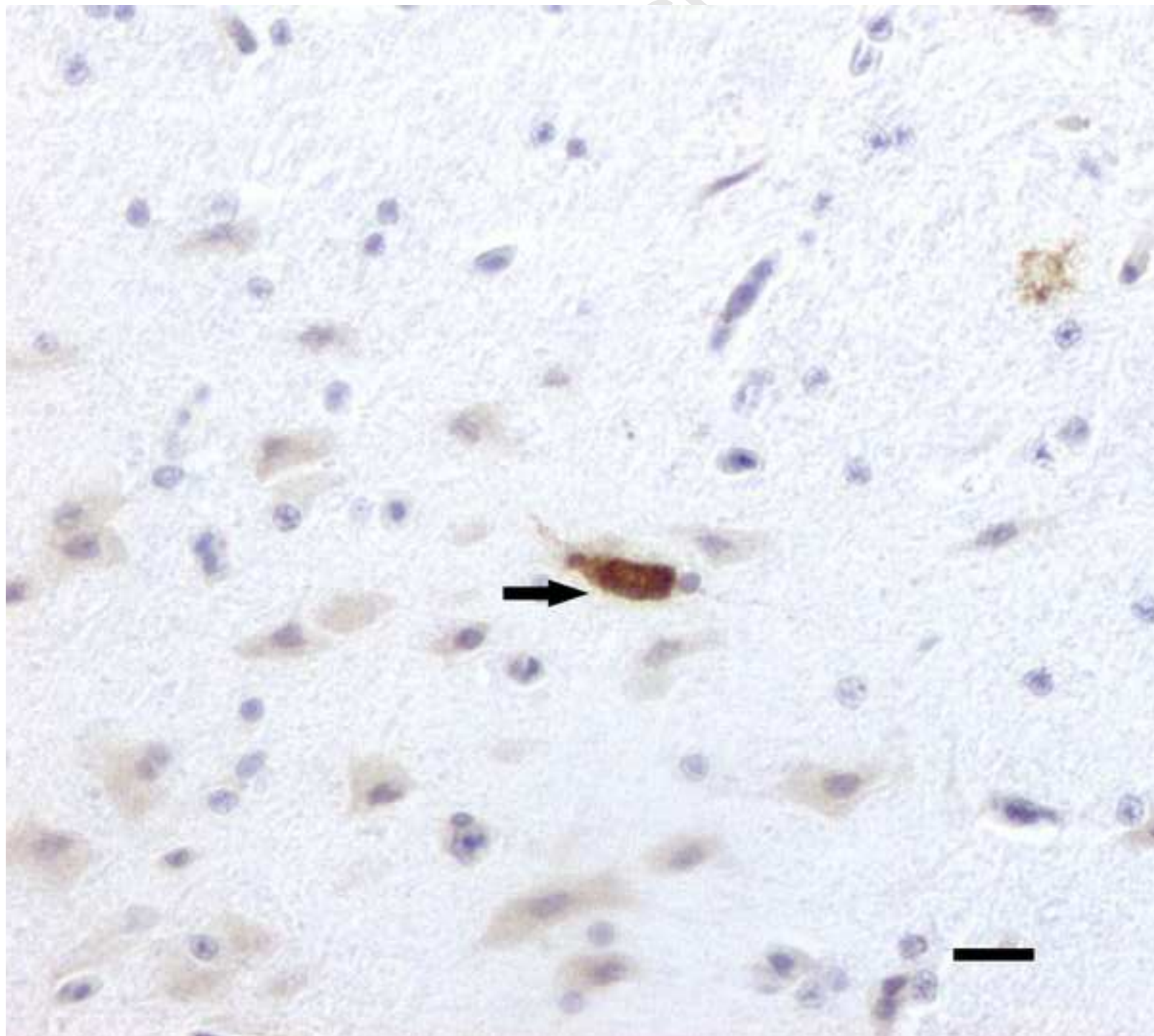


Figure 3

