



HAL
open science

Course of pattern-reversed visual evoked cortical potentials in 30 eyes after bony orbital decompression in dysthyroid optic neuropathy

Andreas Christoph Lipski, Anja Eckstein, Joachim Esser, Christian Loesch, Klaus Mann, Christoph Mohr, Bernhard Jurklies

► To cite this version:

Andreas Christoph Lipski, Anja Eckstein, Joachim Esser, Christian Loesch, Klaus Mann, et al.. Course of pattern-reversed visual evoked cortical potentials in 30 eyes after bony orbital decompression in dysthyroid optic neuropathy. *British Journal of Ophthalmology*, 2010, 95 (2), pp.222. 10.1136/bjo.2009.173658 . hal-00558527

HAL Id: hal-00558527

<https://hal.science/hal-00558527>

Submitted on 22 Jan 2011

HAL is a multi-disciplinary open access archive for the deposit and dissemination of scientific research documents, whether they are published or not. The documents may come from teaching and research institutions in France or abroad, or from public or private research centers.

L'archive ouverte pluridisciplinaire **HAL**, est destinée au dépôt et à la diffusion de documents scientifiques de niveau recherche, publiés ou non, émanant des établissements d'enseignement et de recherche français ou étrangers, des laboratoires publics ou privés.

Course of pattern-reversed visual evoked cortical potentials in 30 eyes after bony orbital decompression in dysthyroid optic neuropathy

Lipski A.¹, Eckstein A.¹, Esser J.¹, Loesch C.², Mann K.³, Mohr C.⁴, Jurklies B.¹

¹Zentrum für Augenheilkunde, Universität Essen

²Institut für Medizinische Informatik, Universität Essen

³Klinik für Endokrinologie, Universität Essen

⁴Klinik für Mund-/ Kiefer- und Gesichtschirurgie, Huysen-Stift, Essen

Competing interests: none to declare

References: 22

Figures: 5

Tables: 2

Word count: 2028 (text), 185 (abstract)

Keywords: pattern VEP, VECP, Graves' disease, DON

Corresponding author

Andreas Lipski, MD

Dept. Ophthalmology

Universitätsklinikum Essen

Hufelandstraße 55

D-45122 Essen, GERMANY

e-mail: andreas.lipski@uni-duisburg-essen.de

Phone: +49-201-723-2920

Fax: +49-201-723-5917

Abstract

Aim: To investigate optic nerve function using the pattern-reversed visual evoked potentials (VECP) before and after bony orbital decompression in dysthyroid optic neuropathy (DON) due to Grave's disease.

Methods: A total of 30 eyes of 15 patients (n=14 female) were observed over 30 ± 13 months after bony 3-wall orbital decompression. We examined visual acuity (VA), VECP P100 amplitudes and latencies as well as proptosis using Hertel's exophthalmometry.

Results: Mean logMAR VA increased, statistically significant, by 2.4 lines during 30 ± 13 months (from 0.38 ± 0.25 before surgery to 0.14 ± 0.1 at the end of observation, $p=0.0001$). All eyes maintained or improved vision by at least one line. Mean postoperative reduction of proptosis was 6.4 ± 3 mm. While VECP P100 amplitudes improved significantly, P100 latencies remained abnormal in 18 eyes (60%) during follow-up of 10 ± 7 months. 9 eyes (30%) with previous latency defects improved in at least one check test, 5 of which normalised completely. Worsening was evident in 7 eyes (23%), 3 previously normal eyes developed new pathologic latencies. P100 latencies in 14 eyes (47%) remained unchanged.

Conclusion: After decompression surgery, DON remission was observed in all patients regarding vision and VECP amplitudes. New or persistent P100 latency defects were seen in 60% of eyes after surgery. DON is considered to be caused by compressive ischemic damage which further underlines the importance of early decompression surgery.

Introduction

In up to 8.6% of patients with Graves' orbitopathy (GO), the clinical course is complicated by dysthyroid optic neuropathy (DON).[1, 2] Although exact mechanisms underlying DON still require illumination, the optic nerve with its vascular supply is vulnerable to compression especially in the orbital apex.[3] Secondary to inflammatory swelling of extraocular muscles and orbital soft tissue, apical orbital crowding may thus lead to altered blood supply and impairment of axonal transport resulting in functional impairment of the optic nerve.[4, 5]

As DON can be better correlated to periorbital swelling and impairment of motility than to lid retraction or proptosis, the diagnosis may be obscured in the absence of these clinical entities.[4, 6] Clinical signs for DON - decreased vision, an afferent pupillary defect or fundoscopic abnormalities such as papilledema - should promptly result in therapeutic intervention. To enhance diagnostic precision, conduction of visual evoked cortical potentials (VECP) may be accompanied by orbital imaging.[2-8] Pattern-reversal VECP retain a valuable tool in the diagnosis and follow-up of DON as the disease is significantly associated with P100 amplitude loss and delayed deflection.[2, 8-14] Pattern-VECP are furthermore capable to identify even subclinical courses of DON with high sensitivity.[12]

Established treatment for DON includes intravenous administration of corticosteroids and bony decompression of the orbit. Several surgical approaches with one- to four-wall orbital delamination have been considered with variable efficacy to reverse congestive proptosis and optic nerve impairment.[15]

Previous studies using VECP to monitor DON during courses of steroid or radiation treatment concluded partial remission of DON, but only few patient reports exist on VECP development after orbital bony decompression.

With intention to selectively focus on the restoration of optic nerve function as reflected by the pattern-reversal VECP, we retrospectively analyzed clinical courses from 30 eyes of 15 patients with DON using pattern-VECP before and after bilateral bony orbital 3-wall decompression.[16, 17]

Material and methods

We retrospectively analyzed clinical outcomes, the results and courses of VECP in 15 non-consecutive GO patients (n= 30 eyes) with DON undergoing orbital decompression. Inclusion criteria were symptoms of DON (at least one of the following signs): an otherwise unexplained visual loss in at least one eye, presence of a (relative) afferent pupillary deficit, colour desaturation and a pathologic VECP. Another prerequisite was a normalised thyroid hormone level as assessed by serologic quantification of free triiodothyronine and tetraiodothyronine (fT3, fT4). The study's intervention consisted of bilateral bony 3-wall orbital decompression using a combined coronar and anterior approach with osteotomy and resection of the lateral, medial and inferior orbital walls followed by dissection of the medial and

posterior ethmoidal cells. Furthermore, orbital fat resection was performed after slitting of the periorbita.[16] Postoperative systemic steroid treatment with fluocortolone was administered at a cumulative dose of 1.55 g over 6 weeks starting with 1 mg/kg body weight per day orally.

Visual acuity assessment was performed on the same day before VECP conductance within one week before decompression surgery using standardized tests of Landolt optotypes at a distance of 5 m according to DIN 58220. Values were converted to logMAR for statistical analyses. Vision was compared both between values at VECP examinations as well as between preoperative and last examination results. Significant vision improvement was assumed when vision increased by at least 2 lines. VECP conductance was followed by mydriatic ophthalmoscopy. At the same date, Hertel's exophthalmometry and biomicroscopic slit lamp examination with ophthalmoscopy were performed. Accordingly, clinical activity- and modified NOSPECS-scores were recorded as described elsewhere.[17] Presence of an RAPD was assayed using the swinging-flashlight test at symmetrical test- and background luminances. Patients with documented corneal pathology (stippled or eroded corneal epithelium) were excluded from the study.

VECP assessment was in full accordance with the ISCEV standards.[18] Cortical responses to reversing full-field checkerboard stimulations were measured using gold cup electrodes (Oz-Fz) and earlobe clip electrodes (Schuler GmbH, Freiburg, Germany) accessing a Jaeger/Toennies multiliner vision unit (Hoechberg, Germany). Ten20™ EEG paste (D.O. Weaver & Co, Aurora, US) served as conductive gel after alcoholic skin scouring to achieve impedances below 5 Ω . Checkerboard squares of four different sizes were consecutively presented in a darkened testing chamber on a 25 x 20 cm rectangular monitor screen with a fixation point in the center at a distance of 100 cm. Monocular stimulation was adopted in all investigations. Rectangular stimulation square sizes were 13.7, 27.5, 60 and 120 minutes of angle (arcmin) at each conduction, respectively. Mean monitor luminance was 50 cd/m² and the checkerboard-reversal rate was set to 2 Hz thereby achieving a contrast of 80% between white and black checks. Signals were filtered at 1-100 Hz, amplified and averaged from 200 cycles with 1% artefact tolerance. Latencies and amplitudes of the first positive through (N75 to P100) as well as of the second negative through (P100 to N140) were used for evaluation. Values of recordings prior to and after orbital decompression were analyzed and compared to results obtained from an age-

matched control group. P100 latency deterioration was defined as either prolongation of previously pathologic values or a newly pathologic latency in any of the four different checkerboard pattern sizes not registered during preoperative testing. Upper latency limits were calculated by adding two standard deviations to mean values from healthy age-matched subjects in our laboratory for each checkerboard pattern size. Upper latency limits were 129 ms at 13.7 arcmin, 125.5 ms at 27.5 arcmin, 124 ms at 60 arcmin and 126 ms at 120 arcmin.

Statistical analysis

Statistical evaluation was performed using a two-sided Student t-test (level of significance = 5%) after verification of parametric distribution using the Kolmogorow-Smirnoff index. Values in the text represent mean \pm sd unless otherwise indicated.

Results

Patients

Thirty eyes of 15 patients with GO were included into the study of which 93% were female. All patients were previously treated either by radioiodine therapy (n=4) or by thyroidectomy (n=11) and had progressive GO despite previous administration of at least one cycle of systemic steroid therapy. Furthermore, bilateral orbital irradiation was performed in 12 patients in the past without achieving sufficient remission. Because in most cases pretreatment was not coordinated by our center, both orbital irradiation and steroid therapy were administered at variable treatment and dosing regimes.[19] History of smoking was present in 87% of patients. One patient received octreotide immunosuppression because of psoriasis comorbidity. Additional patient characteristics are depicted in Table 1.

The mean interval of initial diagnosis of GO and orbital decompression was 1.1 ± 1.0 years. CAS before decompression was 7 ± 2 and NOSPECS was 9 ± 2 (mean \pm sd).

Table 1: Patient characteristics

pt.	age (years)	GD* (years)	GO* (months)	follow-up (months)		VA pre/post		Hertel pre/post		pretreatment	comorbidity	smoking
				Clinical	VECP	OD	OS	OD	OS			
1	60	1.2	5	35	11	0.2/0.7	0.4/0.6	22/13.5	23/15	2St, R, I	none	Y (20)
2	55	0.9	7	24	25	0.6/1.0	0.6/1.0	27/17	27/17	2St, R, S	none	Y (10)
3	51	8.6	30	39	7	0.3/0.4	0.5/0.7	22/15.5	22/15.5	2St, 2R, S	psoriasis	Y (30)
4	62	42.6	5	26	28	0.3/1.0	0.3/1.0	23/17	23/17	St, R, S	none	N
5	68	0.8	10	28	4	0.6/0.6	0.6/0.7	21/16	21/17	St, S, I	HT	Y (6)
6	46	0.9	13	24	17	0.9/1.0	0.9/1.0	21.5/17.5	22.5/18.5	St, R, S	none	Y (20)
7	55	0.5	9	54	3	0.3/0.8	0.16/0.63	27/22	27/20	2St, R, S	HT	Y (20)
8	43	1.6	23	28	35	0.8/0.8	0.6/1.0	20/14	21/14	St, R; S	none	Y (10)
9	67	51.7	8	55	79	0.6/0.6	0.5/0.7	16/14	18/14	St, R, S, 2I	MI; FH	N
10	46	0.9	8	27	3	0.9/0.9	0.9/1.0	22/13	23/14	2St, S	none	Y (20)
11	48	1.7	20	61	5	0.8/1.0	0.8/1.0	22/17	23/16.5	St, R, S	rheumatism	Y (20)
12	73	0.5	7	17	11	0.5/0.5	0.2/0.6	16/12	16/12	St, R, I	AA	Y (10)
13	44	1.0	0.7	0.6	1	0.8/1.0	0.5/0.8	23/17	24/16	2St, R, S	none	Y (10)
14	76	51.8	46	16	27	0.08/0.5	0.6/0.6	25/20	23/20	St, 2S	HT, AC	Y (30)
15	49	0.6	7	19	22	0.4/0.5	0.32/0.6	26/17	26/17	St, R, S	none	Y (10)

Visual acuity

During the postoperative period, mean logMAR visual acuity (VA) increased, statistically significant, by 2.4 lines (from 0.38 ± 0.25 right before surgery to 0.14 ± 0.1 after 30 ± 13 months). Mean vision of patients at follow-up VECP examinations 10 ± 7 months after decompression already improved significantly to logMAR VA= 0.18 ± 0.16 , $p=0.014$ ($p<0.02$). At last examinations 30 ± 13 months after decompression, further mean vision improvement to 0.14 ± 0.12 logMAR VA was denoted ($p=0.0001$; Fig. 1).

After decompression surgery, all eyes maintained or improved vision during follow-up. 50% of patients significantly gained vision by 2 or more lines. Figure 2 further itemizes vision responses to orbital decompression in 3 baseline decimal vision groups. Clearly, patients with low baseline vision preferentially profited from surgery. Vision gain of up to 6 lines in two eyes and a mean gain of 4.5 lines were evident in this subgroup of 8 eyes. Furthermore was stabilization or improvement evident both in the intermediate (0.5-0.32) as well as in the good baseline vision groups (Fig. 2).

Exophthalmometry

Hertel's exophthalmometry revealed statistically significant reductions of 6.4 ± 3 mm 30 ± 13 months after decompression, from 22.4 ± 3.3 mm before surgery to 16.1 ± 2.6 mm, $p<0.0001$).

VECP amplitudes

During the VECP observation period of 12 ± 11 months, mean VECP-P100 amplitudes of 30 eyes increased, statistically significant, by 4.4, 2.6, 2.6 and $1.9 \mu\text{V}$ at 13.7, 27.5, 60 and 120 arcmin stimulation checkerboard size, according to increases of 92%, 43%, 44% and 31%, respectively ($p=0.002$, 0.019, 0.012 and 0.064). P100 amplitudes generated by large patterns of 120 arcmin did not change after decompression. Figure 3 illustrates median courses of amplitudes in the respective check-size groups over the observation period and Table 2 depicts P100 amplitude and latencies before and after decompression in detail.

Table 2: VECP P100 latencies and amplitudes

	VECP P100 latencies (ms, OD pre/post//OS pre/post)				VECP P100 amplitudes (µV, OD pre/post//OS pre/post)			
	13.7°	27.5°	60°	120°	13.7°	27.5°	60°	120°
	133.2/115.8//121.8/117.6	132/112.8//130.8/115.8	129.6/114.6//129/116.4	129/116.4//124.8/115.2	2.7/15.8//3.7/11	3.6/9.6//3.7/9.1	6.6/10.4//6.8/9.4	7.2/9.9//7.7/8.1
	138.6/127.8//121.8/117.6	132/123.6//135.6/124.8	121.2/125.4//127.8/123.6	121.2/125.4//139.2/128.4	3.9/11//3.5/8.7	3.7/9.4//2.3/8.7	3/7.8//1.8/7.6	3.3/6.3//2.4/6.1
	131.4/133.8//130.2/129	137.4/131.4//141.6/145.8	131.4/133.8//141.6//140	129.6/125.4//132.6/138.6	1.7/1.5//2.4/0.9	5.5/5.5//7.9/5.7	6.9/6.3//6.5/6.5	9.2/7.1//8.7/5.1
	137.4/122.4//145.2/157.8	123/112.2//./.	123/106.2//111.6/106.8	129.6/105.6//130.8/111	3.4/27.2//2.3/28.3	3.9/24.3//4.7/14.5	3.3/21.2//7.9/23.2	9.3/20.7//7.6/19.1
	148.8/148.2//154.2/120	132/133.8//141/139.8	123/127.8//129/140	123/126.6//134.4/135	6.2/3.6//5.6/3.4	5.6/4.6//3.5/3.2	6.9/4.7//2.7/2.3	5.8/3.9//2.6/2.1
	112.8/114.6//159/152.4	109.8/106.2//108.6/108.6	107.4/105.6//108.6/105.6	109.8/108//112.8/109.2	5.8/10.5//5.9/10.1	5.4/5.3//5.5/4.6	6.6/6.5//5.5/7	5.6/6.2//6.4/7.1
	127.8/123//120/135	118.2/120.6//119.4/123.6	112.2/118.8//115.2/120	103.8/120.6//105/122.4	10.6/16//5/10	10.1/14.3//12.8/10.7	9.2/14.6//8/8.3	7.5/11//10.5/12.1
	144/127.8//131.4/133.2	133.2/119//116.4/118.2	123.6/116.4//109.8/114	123.6/120.6//113.4/120	3/10.7//7.4/8.4	2.4/11.4//8.2/9.9	4.8/11//6.5/11.7	5.2/10.9//6.7/9.1
	133.8/131.4//130.2/134.4	121.2/126.6//120/119.4	118.2/112.2//116.4/109.8	121.2/118.2//114/108.6	7.8/12.2//9.2/8.9	10.7/11.1//17.8/15.4	10.1/6.4//14.7/12.7	8.2/8.6//13.6/11.1
	130/132//127.8/156.6	123.6/123//115.2/126.5	110.4/112.2//111.6/109.2	114.6/124.8//108.6/124.2	3/7.2//3.8/4.6	6.9/6//7.1/3	7.5/5.4//8.2/4.7	4.5/4.1//7.6/4.1
	118.2/122.4//119.4/120	114/114.6//113.4/114	114/114.6//115.2/112.8	112.2/112.8//117.6/112.8	5.4/8.1//5.5/6.2	7.2/8.1//5.8/7.1	5.8/6.1//5/5.9	3.6/4.8//3.8/4.1
	148.8/147.00//126/138.6	129.6/129.6//./.	118.8/122.4//103.2/134.4	117/125.4//./.	.12.7//.19.8	.19.7//.18.7	.18.2//.18.5	.13.4//.15.3
	123.6/120.6//122.4/120.6	112.2/112.2//116.4/113.4	106.2/111.6//111/109.8	112.2/112.2//111.6/113.4	8/13.5/5.6/11.1	6.4/11.7//5/10.3	7.4/10.8//6.8/10	6.4/12//7/10.4
	./.	././153.6/144	125.4/148.8//139.8/156	115.8/173.4//137.4/162.6	.15.7//.12.6	.15.1//1.7/5.2	1.5/6.2//2.4/5.5	1/3.8//3.1/4.9
	127.2/125.4//130.2/126	124.8/123.6//126.6/126.6	111.6/112.2//111/122.4	116.4/124.8//128.4/124.2	3.2/6.2//1.5/3.0	4.3/6.8/2.8/2.5	2.3/5.1//3.1/5.2	2.7/7.5//1.6/4.1

VECP latencies

P100 latencies after decompression surgery were not different in a statistically significant manner compared to the recordings prior decompression. Total incidences of pathologic VECP P100 latency values decreased after decompression surgery.

Median latency outcome after 12 ± 11 months depended on the stimulation pattern size (figure 4). While decreased latencies were seen at 13.7 arcmin pattern size, prolongations were evident at 27.5 and 120 arcmin. Median P100 latencies at 60 arcmin remained stable but offered a leaning to increase during follow-up.

Figure 5 further depicts latency courses assigned to baseline vision groups before and after decompression. Here, all vision groups developed latency prolongation when stimulated by large pattern sizes (120 arcmin). In the intermediate vision group, patients initially and after decompression surgery had prolonged latencies during testing with small check-sizes with a tendency to normalise after therapy. New postoperative latency deterioration was punctually evident in all vision groups, always restricted to the smallest pattern size not affected in the preoperative examination (data not shown).

Worsening of latencies assigned to stimulation pattern size was evident in 4 patients of the low and intermediate vision groups, respectively, as well as in 3 patients in the high baseline vision group. Here, one patient developed latency deterioration in all of the four already preoperatively pathologic check-sizes despite maintaining unchanged vision during follow-up.

Discussion

Here we report on the beneficial results of bony orbital decompression to prevent irreversible vision loss due to DON. Efficient reduction of proptosis was associated with gain of visual acuity and improvement of pattern-evoked VECP amplitudes after 12 months in our group of patients showing persistent active disease despite previous systemic steroid therapy. To our knowledge, this is the largest study implementing VECP conductance to monitor optic nerve function before and after bony orbital decompression.

All patients were previously treated either by radioiodine or thyroidectomy and revealed a normalisation of fT3 and fT4 serum values at the timepoint of

decompression surgery as well as during follow-up. All patients previously received systemic steroids and 13 patients underwent additional orbital irradiation without sufficient or definite remission of GO prior decompression. Pretreatment was not always coordinated by our clinic and variations in prior treatment regimes were thus unavoidable. However the circumstances leading to DON in these patients were not subject of the study.

Bilateral surgical intervention was performed by the same surgeon with a standardized dosing regimen of postoperative steroids. The bilateral approach was chosen even in cases with asymmetrical optic nerve function because of relatively symmetric proptosis on both eyes in all patients.

Monitoring of DON in response to therapy has been achieved using different techniques of pattern- and flash- evoked VEP.[9, 10] Tsaloumas compared both during radiation or decompression therapy and concluded not to have found substantial differences between the techniques.[11] However pattern-evoked VEP may be affected by patient compliance, media opacities or blurred vision primarily impairing amplitude potentials while latencies remain unaffected or may be compromised to a much lesser extent as far as retinal luminance remains unaffected.[11, 21] Although our patients underwent systemic steroid treatment, significant cataract formation during the VEP follow-up period was not observed. Ongoing visual rehabilitation over the longer clinical follow-up period further underlines that cataract formation is unlikely to have affected VEP results in our study. Potential changes in retinal luminance caused by altered pupil diameters following orbital surgery secondary to intraoperative trauma to pupillomotoric nerve fibres remain unlikely and should not appear on a regular basis. Frequently occurring postoperative complications rather included strabism with diplopia and hypesthesia of the face skin.[16]

While Tsaloumas and co-workers reported on immediate mean latency recovery 2 weeks after orbital decompression in 7 eyes with DON using pattern-reversed stimuli, Setälä and associates observed indiscriminate mean flash-evoked cortical response latencies after 7 years of follow-up in 7 patients.[10, 11] This is in line with our findings after a mean follow-up of ten months - latencies did not reveal significant regeneration and even deteriorated in some patients after bony orbital decompression. Vision gain was furthermore not necessarily associated with restoration of P100 latency: 3 of 5 patients with postoperative full vision (100%)

simultaneously revealed pathologic P100 latencies in at least one check-size conduction group. Patient distribution into preoperative vision groups helped to align postoperative vision outcome but did not further help to identify correlations of preoperative clinical courses with postoperative P100 latency results. Neither the duration of GD before decompression nor clinical activity scores or preoperative history of radioiodine therapy, surgical thyroidectomy or orbital irradiation revealed consistent correlation with latencies before or after decompression surgery. Our observation of newly appearing latency defects after decompression surgery raises the question if other neuro-ophthalmic disorders or mechanisms underlying DON (which preoperatively were not represented by latency deterioration) may have led to axonal conduction defects at the end of follow-up. Because drastic latency defects due to demyelination frequently seen in encephalomyelitis disseminata were not evident in our study, DON may resume the potential of other compressive optic neuropathies to impair both amplitudes and latencies of the VECP.[22] Comparably, an underlying (compressive) vascular mechanism observable in ischemic optic neuropathies with limited latency defects and imposing amplitude loss has to be considered. In conclusion, Wijngaarde's early interpretations of his VECP results in DON suspecting rather circulatory disturbance through mechanical pressure on small or damaged vessel walls are further supported by our study.[8]

Statement

The Corresponding Author has the right to grant on behalf of all authors and does grant on behalf of all authors, an exclusive licence (or non-exclusive for government employees) on a worldwide basis to the BMJ Publishing Group Ltd and its Licensees to permit this article (if accepted) to be published in British Journal of Ophthalmology and any other BMJ PGL products to exploit all subsidiary rights

Competing interests: none to declare

References:

1. Werner SC, Ingbar SH: The thyroid. A fundamental and clinical text. 3rd ed. New York, Harper & Row, 1971, p536
2. Neigel JM, Rootman J, Belkin RI et al. Dysthyroid optic neuropathy. The crowded orbital apex syndrome. *Ophthalmology*. 1988;95(11):1515-21.
3. Kennerdell JS, Rosenbaum AE, El-Hoshy MH. Apical optic nerve compression of dysthyroid optic neuropathy on computed tomography. *Arch Ophthalmol*. 1981;99(5):807-9.
4. Trobe JD. Optic nerve involvement in dysthyroidism. *Ophthalmology*. 1981;88(6):488-92.
5. Forbes G, Gorman CA, Brennan MD et al. Ophthalmopathy of Graves' disease: computerized volume measurements of the orbital fat and muscle. *AJNR Am J Neuroradiol*. 1986;7(4):651-6.
6. Feldon SE, Muramatsu S, Weiner JM. Clinical classification of Graves' ophthalmopathy. Identification of risk factors for optic neuropathy. *Arch Ophthalmol*. 1984;102(10):1469-72.
7. Monteiro ML, Gonçalves AC, Silva CT et al. Diagnostic ability of Barrett's index to detect dysthyroid optic neuropathy using multidetector computed tomography. *Clinics*. 2008;63(3):301-6.
8. Wijngaarde R, van Lith GH. Pattern EPS in endocrine orbitopathy. *Doc Ophthalmol*. 1980;48(2):327-32.
9. Esser J, Sobczynski H. Therapy related follow-up studies of visually evoked cortical potentials in patients with endocrine ophthalmopathy (stage 6). *Fortschr Ophthalmol*. 1988;85(5):541-4.
10. Setälä K, Raitta C, Välimäki M et al. The value of visual evoked potentials in optic neuropathy of Graves' disease. *J Endocrinol Invest*. 1992;15(11):821-6.
11. Tsaloumas MD, Good PA, Burdon MA, Misson GP. Flash and pattern visual evoked potentials in the diagnosis and monitoring of dysthyroid optic neuropathy. *Eye*. 1994;8 (Pt 6):638-45.
12. Salvi M, Spaggiari E, Neri F et al. The study of visual evoked potentials in patients with thyroid-associated ophthalmopathy identifies asymptomatic optic nerve involvement. *J Clin Endocrinol Metab*. 1997;82(4):1027-30.

13. Rutecka-Debniak A, Lubiński W, Krzystolik Z. Visual evoked potentials in diagnosis and monitoring of optic neuropathy in the course of thyroid ophthalmopathy. *Klin Oczna*. 1999;101(5):361-5.
14. van Lith GH, Vijfvinkel-Bruinenga S, Graniewski-Wijnands H. Pattern evoked cortical potentials and compressive lesions along the visual pathways. *Doc Ophthalmol*. 1982;29;52(3-4):347-53.
15. Jorissen M, Feenstra L. Dysthyroid orbitopathy and orbital decompression. A review. *Acta Otorhinolaryngol Belg*. 1992;46(3):303-9.
16. Tveten S, Mohr C, Esser J. Orbital decompression in treatment of endocrine orbitopathy. *Mund Kiefer Gesichtschir*. 1998;2 Suppl 1:S102-6.
17. Eckstein A, Esser J. Thyroid-associated ophthalmopathy. Pathogenesis, clinical presentation and examination, stage-dependent therapy *Ophthalmologie* 2003;100(10) 857-80
18. Odom JV, Bach M, Barber C et al. Visual evoked potentials standard (2004). *Doc Ophthalmol*. 2004;108:115-123
19. Johnson KT, Wittig A, Loesch C et al. A retrospective study on the efficacy of total absorbed orbital doses of 12, 16 and 20 Gy combined with systemic steroid treatment in patients with Graves' orbitopathy. *Graefes Arch Clin Exp Ophthalmol*. 2010;248(1):103-9
20. Leatherbarrow B, Lendrum J, Mahaffey PJ et al. Three wall orbital decompression for Graves' ophthalmopathy via a coronal approach. *Eye*. 1991;5 (Pt 4):456-65.
21. Adachi-Usami E. Aging and pattern visual evoked cortical potentials. In: Heckenlively JR, Arden GB, eds. *Principles and practice of clinical electrophysiology of vision*. St. Louis: Mosby Year Book 1991;417-27
22. Holder GE. Chiasmal and retrochiasmal lesions. In: Heckenlively JR, Arden GB, eds. *Principles and practice of clinical electrophysiology of vision*. St. Louis: Mosby Year Book 1991;557-64

Legends to figures:

Fig.1: Log(MAR) vision before and after decompression surgery. All patients gained vision or remained stable during follow-up of 30 ± 13 months after therapy.

Fig.2: Decimal vision responses to decompression surgery assigned to baseline vision groups. All patients gained vision (arrows) or remained stable during follow-up of 30 ± 13 months after therapy (triangles). Patients with lower baseline vision experienced better vision increases.

*Fig.3: Pre- and postoperative P100 amplitudes in all eyes (n=30) at different stimulation pattern sizes (13.7 to 120 arcmin). Median (horizontal line in box), 25% and 75% percentile (box) and minimum/maximum (bars). *p<0.05, two-sided student t-test*

Fig.4: Pre- and postoperative P100 latencies in all eyes (n=30) at different stimulation pattern sizes (13.7 to 120 arcmin). Median (horizontal line in box), 25% and 75% percentile (box) and minimum/maximum (bars).

Fig.5: VECP P100 latency changes after decompression surgery assigned to baseline vision after stimulation with four different pattern sizes (13.7-120 arcmin). For details: see text.

*Tab. 1: Patient characteristics. Abbreviations: pt: patient, *: duration at timepoint of decompression surgery; GD: Graves' disease; GO: Graves' orbitopathy; VA: decimal visual acuity; OD: right eye; OS: left eye; St: systemic steroid therapy; R: orbital irradiation therapy; S: surgical thyroidectomy; I: radioiodine thyreoablation, HT: arterial hypertension, MI: myocardial infarction, AC: aortic coarctation, AA: aortic aneurysm, FH: family history of GD, Y: yes, N: no*

Tab. 2: VECP P100 amplitudes and latencies with different pattern check sizes before and after decompression surgery. Unavailable values due to missing P100 amplitudes are depicted as dots.

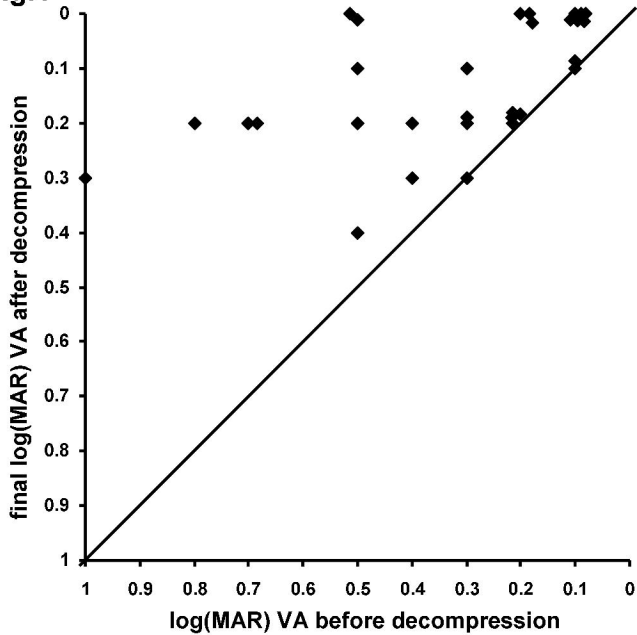
Fig.1

Fig.2 Vision response to surgery in 3 decimal vision groups

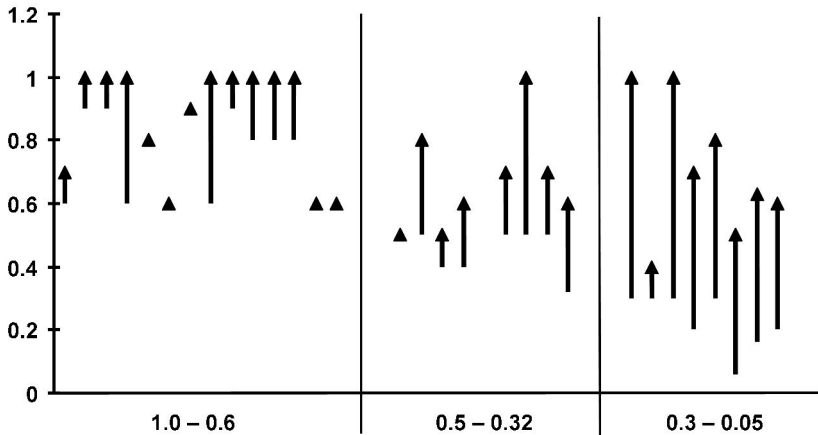


Fig.3 Median P100 amplitude changes

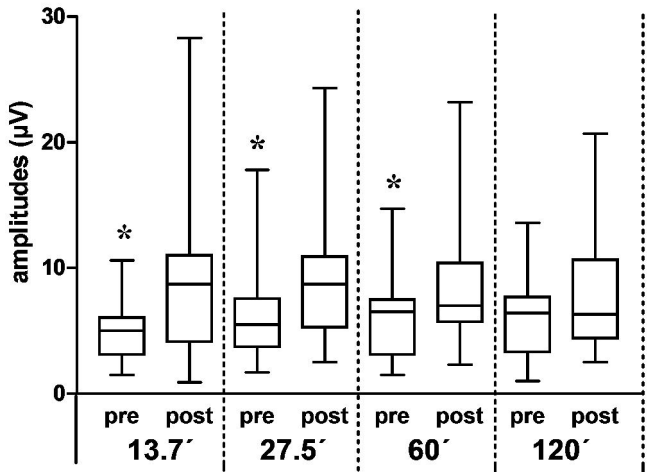


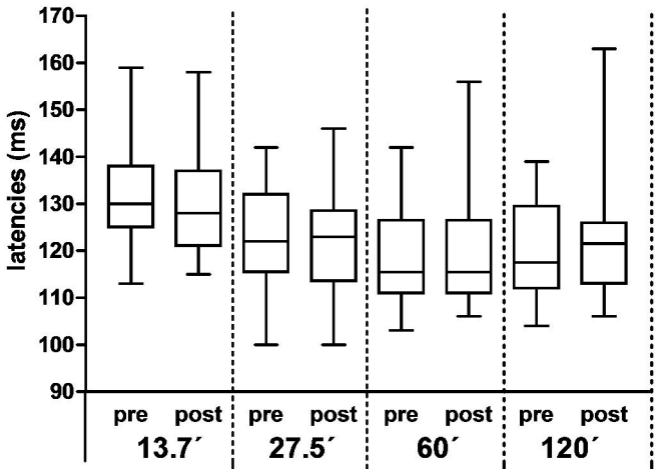
Fig.4**Median P100 latency changes**

Fig.5 Mean P100 latency courses in 3 vision groups

