



HAL
open science

A practical approach to manage additional lesions at preoperative breast MRI in patients eligible for breast conserving therapy: results

Lotte E. Elshof, Emiel J. Th. Rutgers, Eline E. Deurloo, Claudette E. Loo, Jelle Wesseling, Kenneth E. Pengel, Kenneth G.A. Gilhuijs

► **To cite this version:**

Lotte E. Elshof, Emiel J. Th. Rutgers, Eline E. Deurloo, Claudette E. Loo, Jelle Wesseling, et al.. A practical approach to manage additional lesions at preoperative breast MRI in patients eligible for breast conserving therapy: results. *Breast Cancer Research and Treatment*, 2010, 124 (3), pp.707-715. 10.1007/s10549-010-1064-z . hal-00558512

HAL Id: hal-00558512

<https://hal.science/hal-00558512>

Submitted on 22 Jan 2011

HAL is a multi-disciplinary open access archive for the deposit and dissemination of scientific research documents, whether they are published or not. The documents may come from teaching and research institutions in France or abroad, or from public or private research centers.

L'archive ouverte pluridisciplinaire **HAL**, est destinée au dépôt et à la diffusion de documents scientifiques de niveau recherche, publiés ou non, émanant des établissements d'enseignement et de recherche français ou étrangers, des laboratoires publics ou privés.

A Practical Approach To Manage Additional Lesions At Preoperative Breast MRI In Patients Eligible For Breast Conserving Therapy – Results

Lotte E. Elshof¹, Emiel J.Th. Rutgers², Eline E. Deurloo¹, Claudette E. Loo¹, Jelle Wesseling³, Kenneth E. Pengel¹, Kenneth G.A. Gilhuijs¹

¹Department of Radiology, ²Department of Surgery, ³Department of Pathology
The Netherlands Cancer Institute, Antoni van Leeuwenhoek Hospital,
Plesmanlaan 121, 1066 CX Amsterdam, The Netherlands

Corresponding author:

K.G.A. Gilhuijs

The Netherlands Cancer Institute, Antoni van Leeuwenhoek Hospital,
Plesmanlaan 121, 1066 CX Amsterdam, The Netherlands

Tel: +31-20-512-2941; Fax: +31-20-512-2934; E-mail: k.gilhuijs@nki.nl

This work was financially supported by The Dutch Cancer Foundation, grant number NKB 2004-3082.

Abstract

PURPOSE: The aim of this prospective study was to evaluate the efficacy of directives, established to handle additional lesions at preoperative contrast-enhanced magnetic resonance imaging (MRI).

METHODS: Six-hundred-and-ninety consecutive patients with pathology-proven breast cancer planned for BCT based on clinical examination and conventional imaging underwent preoperative breast MRI. The incidence of additional lesions detected at MRI and impact on management were evaluated. Additional findings were pathology-proven or considered benign by follow-up. Findings for which no pathology proof was available prior to surgery, were defined as Unidentified Breast Objects (UBOs). Patients with multicentric or contralateral UBOs underwent BCT as planned with annual follow-up. Multifocal UBOs in the vicinity of the index cancer were excised with wider local margins.

RESULTS: Preoperative MRI detected 141 additional lesions in 121 patients (17.5%). Of these lesions, 44.0% were proven malignant. Additional findings classified as UBOs were found in 81 patients (11.7%). None of the UBOs outside the primary tumour region resulted in malignant disease at follow-up after BCT (mean follow-up time: 57.1 months). However, most multifocal UBOs (in the vicinity of the primary) were malignant (77.5%).

CONCLUSIONS: The strategy to pursue BCT with larger wide-local excisions for multifocal UBOs and to follow up multicentric and contralateral UBOs with conventional imaging is effective to exclude malignancy at follow-up. After second-look targeted ultrasound has been performed, MRI-guided biopsy of

BIRADS-3 multicentric and contralateral additional findings may have limited complementary clinical value.

Keywords

MRI – Breast cancer – Breast-conserving therapy - Additional lesions – Unidentified Breast Objects - Directives

Introduction

Contrast-enhanced magnetic resonance imaging (MRI) of the breast has shown superior sensitivity to detect invasive breast cancer compared to conventional imaging (mammography, ultrasonography) and clinical examination [7, 10, 14, 23]. MRI detects additional foci of disease in the ipsilateral breast of patients with known breast cancer in 10-30% of cases [30]. Clinically and mammographically occult cancer in the contralateral breast is detected in 3-5% of patients who undergo preoperative breast MRI [30]. As a result, MRI frequently changes the therapy of patients initially eligible for breast-conserving therapy (BCT) [5, 8, 11-13, 15, 18, 22, 27]. Because the majority of the additional cancer may, however, be controlled with radiotherapy [9, 38], the clinical relevance of these findings is currently debated [27, 31-34]. Consequently, the clinical indications for breast MRI are still subject of research and discussion. The use of MRI, specifically for breast cancer staging prior to BCT, is recommended by a number of studies [5, 11, 19, 22, 24, 26], but remains controversial in others [9, 27, 31-34].

Parallel to these efforts to define the role of preoperative MRI in the ipsilateral breast, both the European Society of Breast Imaging and the American College of Radiology have recommended the use of MRI to screen the contralateral breast in patients with proven cancer [1, 30]. These reports recommend that simultaneous bilateral MRI should be performed, because the breasts are symmetric organs, and there is negligible time penalty for imaging

both breasts [1]. Consequently, preoperative breast MRI is thus increasingly used, and the need for clinical guidelines rises.

In our hospital, prospective directives were established to handle additional findings in the breast detected at MRI [15, 35]. The aim of this study was twofold. First, to prospectively evaluate the efficacy of these directives in a large patient population. Secondly, to establish recommendations to further improve the efficacy of this approach.

Materials and methods

Patient cohort

Patients who participated in the MARGINS (Multi-modality Analysis and Radiological Guidance *IN* breast conServing therapy, 2000-2008) single-institution trial were included. In this study, patients with pathology-proven breast cancer planned for BCT on the basis of clinical assessment and conventional imaging by mammography and breast-ultrasound, were recruited for an additional preoperative breast MRI. The MARGINS study was performed after approval of the institutional review board and written informed consent of all patients. Patients were excluded if therapy was changed to neoadjuvant chemotherapy. Proof of breast cancer was obtained using image directed fine-needle aspiration (FNA) or core biopsy. Treatment plans were established in consensus by a multi-disciplinary team of breast cancer specialists in all patients.

Magnetic resonance imaging

Initially MRI was performed with a 1.5-tesla scanner (Magnetom, Siemens, Erlangen, Germany) using a dedicated double-breast array coil. From April 2007, MRI was performed with a 3.0-tesla scanner (Achieva, Philips, Best, The Netherlands) using a dedicated 7-elements Sense breast coil. Both breasts were simultaneously imaged in prone position. An unenhanced coronal 3D thrive sense T1-weighted sequence was acquired before the administration of contrast agent. Subsequently, four consecutive series were acquired after the intravenous

administration of contrast. A bolus (14mL) of gadolinium containing contrast agent (gadoteridol, gadopentetate dimeglumine or gadoteric acid) was administered intravenously at 3mL/s using a power injector followed by a bolus of 30ml of saline solution. These series were acquired with a voxel size of 1.35 x 1.35 x 1.35 mm³ (1.5T) or 1.1 x 1.1 x 1.1 mm³ (3.0T). The following scanning parameters were used: acquisition time 90 s (1.5T and 3.0 T); TR/TE: 8.1/4.0 1.5T (4.4/2.3 3.0T); flip angle 20° 1.5T (10° 3.0T); FOV 310 1.5T (360 3.0T).

A viewing station that permitted simultaneous viewing of two series reformatted and linked in three orthogonal directions was used for the interpretation of the breast MRI [20]. The viewing station displayed all image series (unenhanced and contrast enhanced), subtraction images at initial, and at late enhancement, and maximum intensity projection of both breasts. The subtraction images were also colour coded, representing different degrees and curve types of enhancement. The largest tumour diameter was assessed in the three reformatted planes (sagittal, axial and coronal) at initial enhancement.

Additional lesions

Additional lesions at MRI were defined as lesions separate from the index tumour, categorized BIRADS (Breast Imaging Reporting And Data System [2]) 3, 4 or 5 and occult at clinical examination and initial conventional imaging.

Additional lesions were classified in three groups, based on the localization with respect to the index lesion: (1) multifocal (maximum diameter of volume including index tumour and additional lesions < 3 cm), (2) multicentric

(ipsilateral, maximum diameter of volume including index tumour and additional lesion > 3 cm), and (3) contralateral. The first group included additional lesions close to the index tumour (total lesion bearing region < 3 cm), whereas the last two groups represented additional lesions far from the index tumour.

Unidentified Breast Objects (UBOs) were defined as additionally enhancing findings, from which no pathology proof was available before surgery. They were pathology-proven after surgery or considered benign by follow-up. For all other additional lesions, pathology proof was available preoperatively using second-look ultrasound and FNA or core biopsy.

Directives for management of additional lesions at MRI

Directives were established to handle additional lesions detected at MRI, aiming to minimize additional procedures and treatment changes due to benign findings [15, 35]. In short, attempts were made to obtain proof of malignancy for multicentric and contralateral additional lesions by second-look targeted ultrasound and FNA or core biopsy. If pathology confirmed malignant disease over a region too large to allow cosmetically acceptable BCT, a conversion to mastectomy was advised. If pathology proof could not be obtained, the therapy plan was not changed and follow-up by MRI was advised. For multifocal additional lesions additional second-look ultrasound was not advised and these findings typically led to BCT with larger wide-local excision margins to include the additional finding. Depending on the size of the breast, the total diameter of disease in patients eligible for BCT typically did not exceed 3cm. The final

treatment plan was implemented after consultation with the patient including the advice after multidisciplinary discussion of the MRI findings.

Surgery

The aim of the surgical procedures was to achieve tumour-free margins with the best possible cosmetic outcome [36, 37]. The procedures were performed according to accepted surgical standards and were carried out or directly supervised by fully trained surgeons specialized in breast surgery. Wide local excisions in our hospital are generally performed according to the technique described by Aspegren et al. [3]. Non-palpable lesions were typically marked preoperatively by using intra-lesional injection of ^{99m}Tc -nanocolloid (Nanocoll; GE-Healthcare, Eindhoven, The Netherlands) administered under ultrasound guidance, and detected and removed intraoperatively, guided by a gamma-ray probe [40]. Results of MRI and other preoperative diagnostic imaging were available for review in the operating theatre. The number of patients in which surgical treatment was changed due to additional lesions was assessed.

Pathology

Excision specimens were handled according to a protocol adopted from the approach described by Egan [17]. Briefly, each specimen was cut into 3-4 mm slices and fixed in 4% formalin overnight. Subsequently, a radiograph from the slices was obtained. Based on macroscopic, radiographic, and MRI findings,

samples were taken to enable adequate microscopic investigation of the lesions and their surrounding.

Additional procedures

The number of additional procedures caused by additional lesions was assessed. These procedures included preoperative second-look targeted ultrasound, ultrasound-guided FNA, ultrasound-guided or stereotactic core biopsy, second MRI and follow-up.

Statistics

The ability of preoperative breast MRI to detect malignant additional lesions was defined by the positive-predictive value (PPV), i.e., the number of malignant lesions divided by the total number of additional lesions. UBOs that were lost to follow-up were not included in the calculation of PPV. Chi-squared tests were performed to explore differences in diagnosis between multifocal and distant lesions. To compare age in different groups Mann-Whitney U tests were used. SPSS Version 15.0; SPSS Chicago, Ill, was used for the analyses. A P-value of less than 0.05 was considered to be significant.

Results

Patient cohort

Between November 2000 and January 2008, 715 patients participated in the MARGINS study. In the current study, 690 patients with 698 cancers (8 bilateral) passed the inclusion criteria. The pathological types of the 698 index cancers were as follow: IDC: 505, ILC: 93, DCIS: 36, tubular carcinoma: 17, colloid carcinoma: 8, medullary carcinoma: 6, other: 33.

Additional lesions

At preoperative MRI, 141 additional lesions were detected in 121 patients ($121/690 = 17.5\%$; Table 1, Figure 1). UBOs were found in 81 patients ($81/690 = 11.7\%$).

Of a total of 141 additional lesions, 44 multicentric and contralateral findings were followed up and considered benign (table 1), i.e., in none of the patients these UBOs were found to be malignant during follow-up ($44/141 = 31.2\%$). Forty of these UBOs were categorized BIRADS-3 at MRI. Follow-up was performed using conventional x-ray mammography in all cases. In addition, 16 UBOs were followed up by MRI. The patients who were followed up by MRI were significantly younger than the patients who were followed up by conventional imaging alone (52.3 years vs 57.7 years, $p = 0.01$). The mean follow-up time was 57.1 months (55.0 months median, range: 22–103 months). Approximately half the number of these UBOs had follow-up time ≥ 60 months ($21/44 = 47.7\%$). Four patients, each with one additional finding were lost to follow-up after BCT. A

pathological substrate could not be found for seven multifocal additional findings in the wider-local excision specimens. These findings at MRI were assumed to be caused by benign fibrocystic changes (Table 1). Twenty-four lesions were proven to be benign (Table 1), i.e. fibroadenoma, cyst, benign lymph node or intraductal papilloma: 3 multifocal, 13 multicentric, and 8 contralateral.

Surgery

Preoperative MRI resulted in a change in surgical management in 66 out of 690 patients (9.6%). Due to multicentric malignant additional lesions in 18 patients, treatment was changed to mastectomy.

In one patient, the MRI showed that the index tumour was closer to the capsula of the protheses than could be appreciated at conventional imaging. As a result the therapy was converted to mastectomy. Moreover, this patient also showed an additional lesion that was reported malignant by FNA cytology prior to surgery. At final pathology the additional tumour was not found in the mastectomy specimen. This lesion was proven benign (fibroadenoma) after revision of the cytology.

In another patient, with a multifocal malignant additional lesion, treatment was changed to mastectomy. Because this patient also had a breast augmentation and the tumour was located near the capsula of the protheses, BCT was expected to result in a bad cosmetic outcome. Moreover a complete wide local excision of both cancers was expected to result in incomplete margins.

Forty-one patients underwent more extensive wide local excision for multifocal disease, of whom 33 were confirmed to have one or more malignant additional

lesions. In one of these patients a mastectomy was done after an incomplete surgical excision.

In four patients a contralateral additional lesion was proven malignant. One mastectomy was performed according to the wish of the patient. The other three patients underwent wide local excision.

One patient underwent bilateral mastectomy, because of a malignant additional multicentric lesion and an additional lesion in the contralateral breast which turned out to be invasive lobular carcinoma with extensive lobular carcinoma in situ.

Additional procedures

As a result of the detection of additional lesions at preoperative MRI, 114 additional procedures were performed preoperatively and 34 procedures were done during follow-up (Figure 2, Figure 3).

Positive predictive value

A total of 62 malignant lesions were detected at MRI in 56 patients ($56/690 = 8.1\%$). To remind, these series do not include unexpected larger extent of the index tumour. Four UBOs were lost to follow-up and excluded from the PPV calculations. More than two-fifth of MRI detected additional lesions was proven malignant (PPV: $62/137 = 45.3\%$; Table 1). Multifocal lesions were more often malignant than multicentric and contralateral lesions (PPV: $35/45 = 77.8\%$ vs. $22/66 = 33.3\%$ and $5/26 = 19.2\%$, $p < 0.0001$). Notably, none of the multicentric

and contralateral UBOs resulted in malignant disease during follow-up after radiotherapy.

Discussion

We evaluated directives for the management of additional lesions detected at MRI. The guidelines were sensitive to include malignant lesions in surgical planning without causing conversions to mastectomy for benign lesions. Despite this high sensitivity, the fraction of additional findings for which follow-up procedures were applied and that did not yield malignant disease is still relatively high. In this section we discuss additional recommendations to enhance the directives.

Three situations can be distinguished in the management of additional lesions: (1) the additional lesion is preoperatively proven to be malignant, (2) the additional lesion is preoperatively proven to be benign, and (3) no pathology proof of the additional finding can be obtained prior to surgery (UBO).

Preoperatively proven malignant additional lesions led to changes in treatment. In patients with multifocal malignant disease, BCT could still be performed, but larger wide-local margins were excised to include additional lesions and avoid potentially incomplete excisions. Multicentric and contralateral malignant additional lesions led to more radical changes in patient treatment (e.g., change to mastectomy or bilateral surgery). It was considered that the detection of these lesions at preoperative MRI could result in treatment at an earlier stage and prevent multiple operations.

The assumption that surgery of additional tumour corresponding to the additional MRI abnormality is beneficial for the patient is debated. Small additional tumour foci in the ipsilateral breast may not be of clinical relevance, because patients treated with BCT generally receive postoperative external-beam radiation of the whole breast [9, 31, 33]. Nonetheless, it is also known that radiotherapy is ineffective to eradicate large residual tumour burden [4, 16, 41]. Moreover, the contralateral breast does not receive radiotherapy.

Local failure after BCT is an uncommon event: 96% of women without a preoperative MRI undergo BCT without local recurrence at 8 years [38]. Furthermore, the prevalence of additional malignant lesions exceeds the current local recurrence rates after BCT [38]. On the other hand, long-term impact of additional lesions on local recurrence is currently unknown.

The issue whether preoperative MRI reduces the rate of incomplete tumour excision has also recently been addressed [29, 35, 39]. The results from the COMICE trial, which randomized between women with and without preoperative MRI, show no significant difference in rate of incomplete tumour excision with or without preoperative MRI. Nonetheless, MRI was reported to be helpful to improve the localization of breast cancer. Two retrospective cohort studies indicate that preoperative MRI may be helpful to reduce incomplete excision of breast cancer in subgroups of tumours. Pengel et al. noted a significant reduction in incomplete excision of IDC in the MRI group. In a cohort study including 267 patients with ILC, Mann et al. showed significantly lower re-excision rates in the preoperative MRI group.

Preoperatively proven benign additional lesions contributed to a different aspect of preoperative MRI. To obtain pathology-proof for these lesions, additional procedures were performed, which may have resulted in redundant inconvenience and expense. On the other hand, some patients may have benefited from the assurance that no other malignant disease was detected at MRI. The combination of radiological reading and a computer system is able to reliably identify benign lesions and may be helpful to reduce the number of lesions that require further workup [15].

The last group of UBOs causes the greatest clinical dilemma. Our study suggests that multifocal UBOs should be considered separately from multicentric and contralateral UBOs, because the large majority of the multifocal lesions were malignant. These findings are in agreement with the pathology studies performed by Holland [25]. It does not appear to be necessary to evaluate these findings prior to surgery, because BCT can be pursued with larger wide-local excisions. Preoperative evaluation of multifocal findings may lead to redundant additional procedures and unnecessary expense.

Our results suggest that it may be safe to follow up findings considered to be benign on targeted ultrasound after BCT. Moreover, the use of MRI to follow-up multicentric and contralateral UBOs may be limited, because no malignant disease associated with UBOs could be detected at follow-up (mean of 57.1 months). In the current study, follow-up was performed using conventional x-ray

mammography in all cases, but not all findings were followed up using MRI. Patient preference, breast density, and low suspicion of presence of malignant disease on targeted ultrasound following MRI were the most important underlying reasons for this discrepancy. Patients who were followed up by MRI were significantly younger than patients who were followed up by conventional imaging alone (52.3 years vs 57.7 years, $p = 0.01$). The decision was always based on consensus by the multidisciplinary team of breast-cancer specialists. Our observations suggest that patients with additional breast findings may be followed up after BCT in the same fashion as patients without additional findings. Previous studies do not recommend MRI as routine breast cancer surveillance in patients without a high clinical suspicion of local recurrence following breast conservation surgery and radiotherapy as it will incur significant cost and will be unlikely to improve overall survival [21, 28]. The use of preoperative MRI may further reduce the need for screening MRI at the time of annual follow-up evaluations [21].

Several studies described the use of MRI-guided biopsies to sample regions containing MRI-detected abnormalities [6, 22]. The European Society of Breast Imaging emphasizes the importance of this diagnostic device and states that MRI should only be offered by institutions that can also offer MRI-guided biopsy [30]. In the current study approximately half the number of additional lesions further away from the index tumour were detected by targeted ultrasound and FNA or core biopsy. If not visible at targeted ultrasound, these findings did not manifest

as malignant disease at follow-up after BCT. Again these results suggest that MRI-guided biopsy of BIRADS-3 multicentric and contralateral additional findings following targeted ultrasound may have limited impact on patient outcome.

A prior study discussed the differences in incidence of additional findings and malignant additional findings in patients with breast cancer, ranging from 8% to 51% and 4% to 28% respectively [15]. Differences in study design (retrospective vs. prospective), inclusion criteria and focus are mentioned as a cause. In the present study, *only* lesions separate from the index tumour and previously occult were evaluated. More extensive enhancement of the index lesion, was evaluated in a prior study [35]. Also, BIRADS-2 findings (benign) were not defined as additional lesions, because they do not require further workup and typically do not cause problems in patient management due to their low suspicion of harbouring malignant disease.

Our study also has some limitations. First, not all additional findings could be identified as malignant or benign lesions. Without the use of MRI-guided biopsy, findings not visible at conventional imaging could not be biopsied and therefore remained unverified before surgery. Hence, we are unable to discriminate between preoperative benign lesions and potentially malignant disease that was eradicated by radiotherapy. Our results should therefore always be interpreted with postoperative radiotherapy in mind. With regard to multifocal findings, two were excised and proved benign after surgery. These two lesions might have

been identified using MRI-guided biopsy, thus potentially avoiding two wider local excisions. On the other hand, 35 of the 45 wider local excisions showed additional disease at pathology, leaving relatively little room for MRI-guided biopsy to improve these results while incurring additional expense and an invasive procedure.

Another limitation of our study is that four patients with unverified findings were lost to follow-up. Furthermore, patients were not randomized to compare workup with and without MRI, but were consecutively recruited for an MRI prior to surgery. Moreover, this is a single-institution study. Although some of our findings are in agreement with those from other studies, details may vary depending on clinical implementation. In this study, the MRI findings for each individual patient were discussed and translated into clinical actions by a multi-disciplinary team of breast cancer specialists based on prior established directives.

Conclusions

Prospective directives to manage additional lesions at preoperative breast MRI proved to be sensitive to include malignant disease in the surgical planning without causing conversions to mastectomy for benign lesions. The strategy to pursue BCT with larger wide-local excisions for multifocal UBOs and to follow up multicentric and contralateral UBOs with conventional imaging is effective to exclude malignancy at follow-up. After second-look targeted ultrasound has been performed, MRI-guided biopsy of BIRADS-3 multicentric and contralateral additional findings may have limited complementary clinical value.

Acknowledgements

We thank Anita Paape and Angelique Schlieff for the data management. Jelle Teertstra, Robert Kröger, Charlotte Lange, Warner Prevoo, Peter Besnard, Wim Koops, Frank Pameijer, Marie-Jeanne Vrancken Peeters, Hester Oldenburg, Saar Muller, Marc van de Vijver and Hans Peterse[†] are thanked for their dedicated input.

Reference List

1. ACR Guidelines and Standards Committee et al (2008) ACR practice guideline for the performance of contrast-enhanced magnetic resonance imaging (MRI) of the breast.
2. American College of Radiology (ACR) (2003) Breast Imaging Reporting and Data System Atlas (BI-RADS® Atlas). Reston, Va: © American College of Radiology.
3. Aspegren K, Holmberg L, Adami HO (1988) Standardization of the surgical technique in breast-conserving treatment of mammary cancer. *Br J Surg* 75:807-810
4. Bartelink H et al (2001) Recurrence rates after treatment of breast cancer with standard radiotherapy with or without additional radiation. *N Engl J Med* 345:1378-1387
5. Bedrosian I et al (2003) Changes in the surgical management of patients with breast carcinoma based on preoperative magnetic resonance imaging. *Cancer* 98:468-473
6. Bedrosian I et al (2002) Magnetic resonance imaging-guided biopsy of mammographically and clinically occult breast lesions. *Ann Surg Oncol* 9:457-461
7. Berg WA et al (2004) Diagnostic accuracy of mammography, clinical examination, US, and MR imaging in preoperative assessment of breast cancer. *Radiology* 233:830-849
8. Bilimoria KY et al (2007) Evaluating the impact of preoperative breast magnetic resonance imaging on the surgical management of newly diagnosed breast cancers. *Arch Surg* 142:441-445
9. Bleicher RJ, Morrow M (2007) MRI and breast cancer: role in detection, diagnosis, and staging. *Oncology (Williston Park)* 21:1521-8, 1530
10. Boetes C et al (1995) Breast tumors: comparative accuracy of MR imaging relative to mammography and US for demonstrating extent. *Radiology* 197:743-747
11. Braun M et al (2008) Influence of preoperative MRI on the surgical management of patients with operable breast cancer. *Breast Cancer Res Treat* 111:179-187

12. Crowe JP, Patrick RJ, Rim A (2009) The importance of preoperative breast MRI for patients newly diagnosed with breast cancer. *Breast J* 15:52-60
13. del Frate C et al (2007) Role of pre-surgical breast MRI in the management of invasive breast carcinoma. *Breast* 16:469-481
14. Deurloo EE et al (2006) Contrast-enhanced MRI in breast cancer patients eligible for breast-conserving therapy: complementary value for subgroups of patients. *Eur Radiol* 16:692-701
15. Deurloo EE et al (2005) Additional breast lesions in patients eligible for breast-conserving therapy by MRI: impact on preoperative management and potential benefit of computerised analysis. *Eur J Cancer* 41:1393-1401
16. Early Breast Cancer Trialists' Collaborative Group (EBCTCG) (2005) Effects of radiotherapy and of differences in the extent of surgery for early breast cancer on local recurrence and 15-year survival: an overview of the randomised trials. *The Lancet* 366:2087-2106
17. Egan RL (1982) Multicentric breast carcinomas: clinical-radiographic-pathologic whole organ studies and 10-year survival. *Cancer* 49:1123-1130
18. Fischer U, Kopka L, Grabbe E (1999) Breast carcinoma: effect of preoperative contrast-enhanced MR imaging on the therapeutic approach. *Radiology* 213:881-888
19. Fischer U et al (2004) The influence of preoperative MRI of the breasts on recurrence rate in patients with breast cancer. *Eur Radiol* 14:1725-1731
20. Gilhuijs KG et al (2002) Breast MR imaging in women at increased lifetime risk of breast cancer: clinical system for computerized assessment of breast lesions initial results. *Radiology* 225:907-916
21. Gorechlad J et al (2008) Screening for Recurrences in Patients Treated with Breast-Conserving Surgery: Is there a Role for MRI? *Ann Surg Oncol* 15:1703-1709
22. Grobmyer SR et al (2008) Is there a role for routine use of MRI in selection of patients for breast-conserving cancer therapy? *J Am Coll Surg* 206:1045-1050
23. Hata T et al (2004) Magnetic resonance imaging for preoperative evaluation of breast cancer: a comparative study with mammography and ultrasonography. *J Am Coll Surg* 198:190-197
24. Heywang-Kobrunner SH et al (1997) Contrast-enhanced MRI of the breast: accuracy, value, controversies, solutions. *Eur J Radiol* 24:94-108

25. Holland R et al (1990) Extent, distribution, and mammographic/ histological correlations of breast ductal carcinoma in situ. *The Lancet* 335:519-522
26. Hollingsworth AB, Stough RG (2006) Preoperative breast MRI for locoregional staging. *J Okla State Med Assoc* 99:505-515
27. Houssami N et al (2008) Accuracy and surgical impact of magnetic resonance imaging in breast cancer staging: systematic review and meta-analysis in detection of multifocal and multicentric cancer. *J Clin Oncol* 26:3248-3258
28. Khatcheressian J et al (2006) American Society of Clinical Oncology 2006 Update of the Breast Cancer Follow-Up and Management Guidelines in the Adjuvant Setting. *J Clin Oncol* 24:5091-5097
29. Mann R et al (2010) The impact of preoperative breast MRI on the re-excision rate in invasive lobular carcinoma of the breast. *Breast Cancer Res Treat* 119:415-422
30. Mann RM et al (2008) Breast MRI: guidelines from the European Society of Breast Imaging. *Eur Radiol* 18:1307-1318
31. Morrow M (2004) Magnetic resonance imaging in breast cancer: one step forward, two steps back? *JAMA* 292:2779-2780
32. Morrow M (2004) Magnetic resonance imaging in the preoperative evaluation of breast cancer: primum non nocere. *J Am Coll Surg* 198:240-241
33. Morrow M (2008) Magnetic resonance imaging in the breast cancer patient: curb your enthusiasm. *J Clin Oncol* 26:352-353
34. Orel S (2008) Who should have breast magnetic resonance imaging evaluation? *J Clin Oncol* 26:703-711
35. Pengel KE et al (2009) The impact of preoperative MRI on breast-conserving surgery of invasive cancer: a comparative cohort study. *Breast Cancer Res Treat* 116:161-169
36. Rutgers EJ (2001) Quality control in the locoregional treatment of breast cancer. *Eur J Cancer* 37:447-453
37. Rutgers EJ (2004) Sentinel node procedure in breast carcinoma: a valid tool to omit unnecessary axillary treatment or even more? *Eur J Cancer* 40:182-186
38. Solin LJ et al (2008) Relationship of breast magnetic resonance imaging to outcome after breast-conservation treatment with radiation for women with

early-stage invasive breast carcinoma or ductal carcinoma in situ. *J Clin Oncol* 26:386-391

39. Turnbull L et al (2010) Comparative effectiveness of MRI in breast cancer (COMICE) trial: a randomised controlled trial. *The Lancet* 375:563-571
40. van Rijk MC et al (2007) Sentinel node biopsy and concomitant probe-guided tumor excision of nonpalpable breast cancer. *Ann Surg Oncol* 14:627-632
41. Vrieling C et al (2003) Can patient-, treatment- and pathology-related characteristics explain the high local recurrence rate following breast-conserving therapy in young patients? *European Journal of Cancer* 39:932-944

Table 1

Number of additional lesions, Unidentified Breast Objects (UBOs), and localization compared with the diagnosis of the lesions

Localization	Number of additional lesions (number of UBOs)					
	Benign			Malignant	Lost to Follow-up	Total
	Pathology proven	Considered by follow-up*	Assumed after excision			
Multifocal	3 (2)	-	7 (7)	35 (31)	-	45 (40)
Multicentric	13 (1)	31 (31)	-	22** (-)	1 (1)	67 (33)
Contralateral	8 (2)	13 (13)	-	5 (-)	3 (3)	29 (18)
Total	75 (56)			62 (31)	4 (4)	141 (91)

* Mean follow-up time: 57.1 months

** Two of these lesions were categorized Birads-5 at preoperative MRI, and therefore no histological confirmation was deemed necessary. After mastectomy they were proven malignant by pathology.

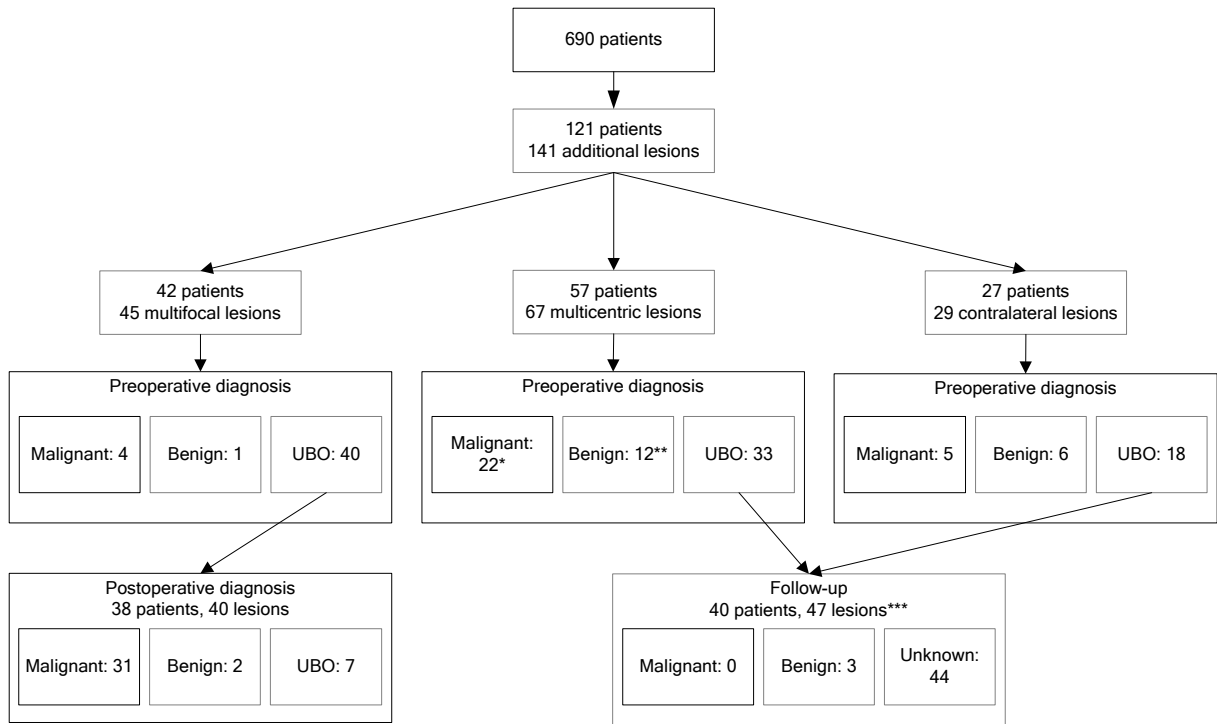


Fig. 1 Work-up and outcome of additional lesions

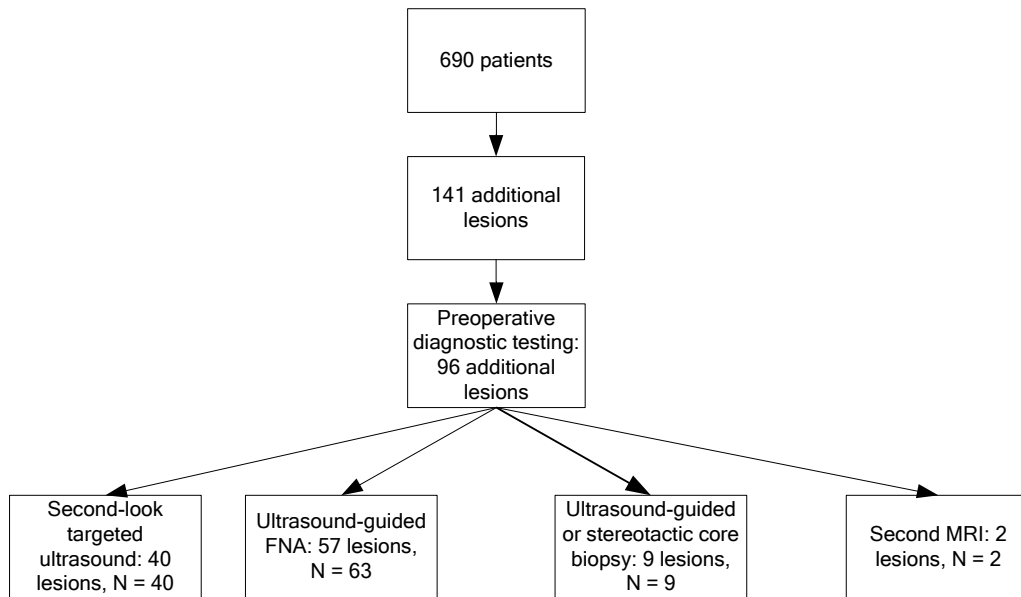


Fig. 2 Additional lesions and procedures performed preoperatively

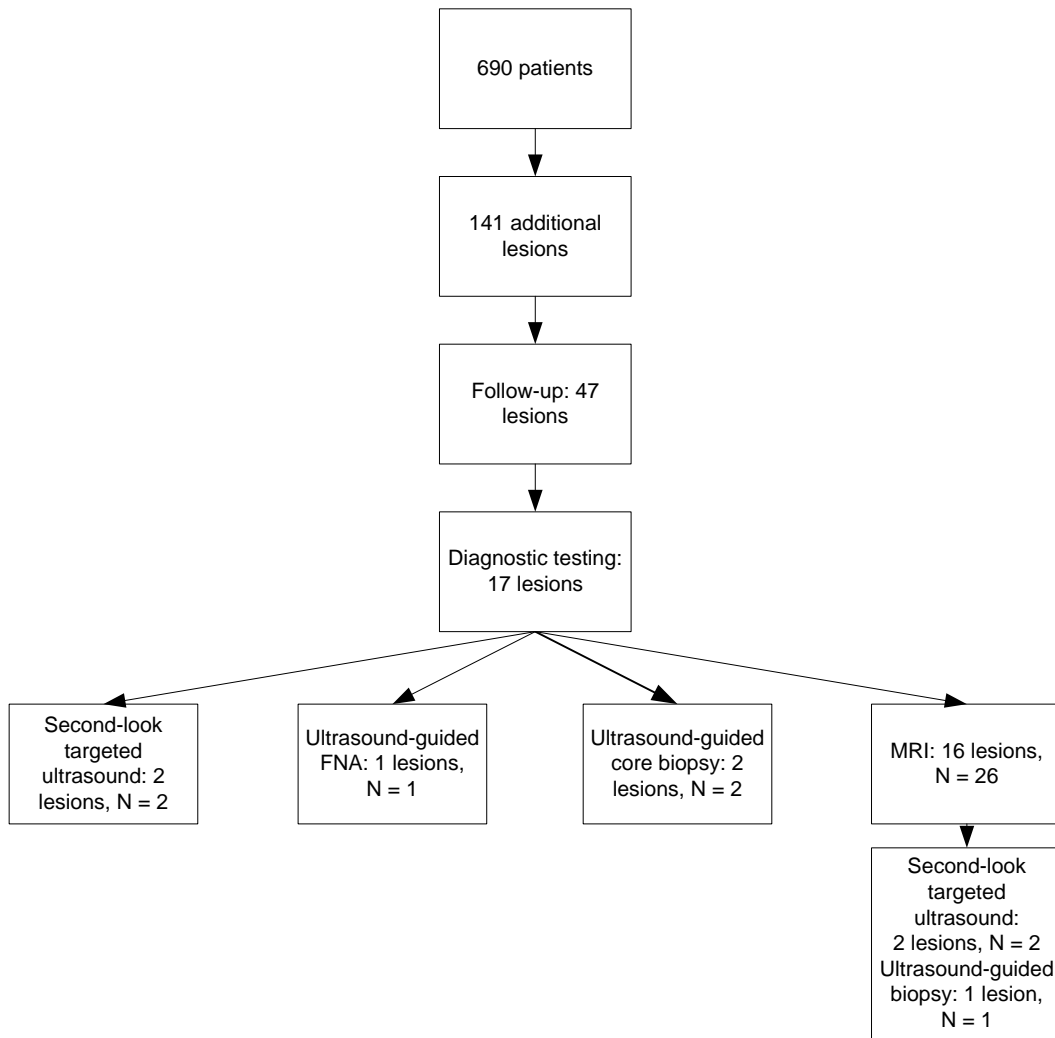


Fig. 3 Additional lesions and procedures performed during follow-up

