



HAL
open science

Changing the composition of buffered eye drops prevents undesired side effects

Norbert F Schrage, Markus Frentz, Martin Reim

► **To cite this version:**

Norbert F Schrage, Markus Frentz, Martin Reim. Changing the composition of buffered eye drops prevents undesired side effects. *British Journal of Ophthalmology*, 2010, 94 (11), pp.1519. 10.1136/bjo.2009.177386 . hal-00558106

HAL Id: hal-00558106

<https://hal.science/hal-00558106>

Submitted on 21 Jan 2011

HAL is a multi-disciplinary open access archive for the deposit and dissemination of scientific research documents, whether they are published or not. The documents may come from teaching and research institutions in France or abroad, or from public or private research centers.

L'archive ouverte pluridisciplinaire **HAL**, est destinée au dépôt et à la diffusion de documents scientifiques de niveau recherche, publiés ou non, émanant des établissements d'enseignement et de recherche français ou étrangers, des laboratoires publics ou privés.

Changing the composition of buffered eye drops prevents undesired side effects

Norbert F. Schrage^{1, 2, 3}; Markus Frenz²; Martin Reim³

¹ Dept. of Ophthalmology, Hospital Cologne- Merheim, Ostmerheimer Strasse 200,
51109 Cologne, Germany

² Aachen Center of Technology Transfer in Ophthalmology, Karlsburgweg 9,
52070 Aachen, Germany

³ Dept. of Ophthalmology Aachen University, Pauwelsstraße 30,
52057 Aachen, Germany

Corresponding address:

Prof. Dr. N. Schrage

ACTO e. V.

Karlsburgweg 9

52070 Aachen

schrage@acto.de

Phone: + 49 241 9974180

Fax: + 49 241 9974181

Key words:

Cornea, calcification, phosphate, side effects, citrate buffer, hyaluronic acid, healing

Word count: 1.958 Words

Abstract:

Purpose:

The *Ex Vivo Eye Irritation Test* (EVEIT) is used to analyse the clinical observations of corneal calcification attributed to the presence of phosphate within applied eye drops used in treating glaucoma, Still-Chauffard syndrome, ocular burns and dry eyes.

Method:

Live corneas from abattoir rabbit eyes were cultured in order to study epithelial healing following mechanical abrasion of the corneal surface combined with repeated exposure to various eye drops.

Results:

Obvious corneal calcification of the wound area along with a complete epithelial healing covering the calcified area was observed following exposure to phosphate hyaluronate eye drops. Epithelial healing without calcification was achieved using citrate hyaluronate eye drops.

Conclusion:

Clinical observations show that topical use of artificial tears containing phosphate on injured eyes may lead to sight-threatening corneal complications. Simulation of such treatment conditions by the EVEIT convincingly demonstrate that changes in the composition of the pharmaceutically used treatments can prevent this undesired side effect.

Although considerable healing was achieved during the repeated application of eye drops, using either phosphate or citrate buffered, only the drops containing citrate did not develop corneal calcification on the eye. We therefore recommend discontinuing the use of phosphate buffered eye drops, or other topically applied solutions, to avoid further injury to the patient.

Introduction:

It is well known that the phosphate concentration is very low in the stroma of human corneas [2]. This is also true for the stroma of rabbit corneas [1], making them an excellent animal model for analysing the effects of ophthalmologic treatments on corneas. The development of calcified patches on corneas is usually slow under physiological conditions, sometimes lasting months or years as been reported by Huige et al. for phosphate containing steroids [3]. Nevertheless, Bernauer et al. [4] described the development of calcification in conjunction with corneal wounds which have been treated with phosphate buffered artificial tears in conjunction with corneal wounds. The same effects were observed previously [5] during the treatment of corneal burns with phosphate containing drugs [6] and in an experimental eye burn model on rabbit corneas treated with phosphate buffer rinsing. Recent reports [4,7] from clinical practice concerning calcified human corneas has finally led to considerable changes in the formulation of artificial tears [8] by replacing phosphate with citrate in treatment buffers. In this study we aimed to evaluate the presence or absence of corneal calcification after clinical use of such eye drops by taking advantage of the EVEIT approach. In studying the morphological changes in the cornea during the wound healing process, determining residual clarity and the appearance of calcification or other types of turbidity is a simple but convincing approach in the evaluation and development of new ophthalmologic treatments. By exposing *ex vivo* cultured corneas to pharmaceutical preparations we have shown that removing phosphate from these solutions prevents the calcification found with use of phosphate containing solutions.

Materials and Methods:

EVEIT

The *Ex Vivo Eye Irritation Test* (EVEIT) is a non-animal-consuming, self-healing system that uses living corneal tissue. This procedure uses corneas taken from animals which are otherwise slaughtered for food preparation. The heads are decapitated and the eyes are treated with Polyspectran[®] drops (Alcon Pharma, Freiburg, Germany) and sealed with plaster. The heads are immediately transported at 4°C and prepared for experimentation within no more than 8 hours.

After re-opening the eye lids for preparation, the corneas were excised with a 12 mm trephine and adhering tissues were gently removed. The corneas were placed in special culture chambers (ACTO e.V., Aachen, Germany). The chambers were gently filled with serum-free minimal essential medium (MEM) (Cat. No. T031-05, Biochrom AG, Berlin, Germany, containing 200 mg CaCl₂ and 140 mg NaH₂PO₄•2H₂O in its Earle's salt composition), supplemented with Piperacillin (2 mg/ml; Ratiopharm GmbH, Ulm, Germany), Amikacin (0.2 mg/ml; Fresenius Kabi Deutschland GmbH, Bad Homburg vor der Höhe, Germany), and Nystatin (400 U/ml; Valeant Pharmaceuticals Germany GmbH, Eschborn, Germany). The medium was continuously replenished by a micropump with an entrance pH of 7.4 ± 0.2 and a flow rate of 6µl/min. The culture chambers were held at 32°C in normal air without supplementary CO₂ and 100% relative humidity for 24 hours before the explanted corneas were used for further experiments.

Examination techniques

The epithelial surface was microscopically examined daily for the duration of the experiment. Surface staining was performed with fluoresceine solution (1.7 mg/ml fluoresceine; Sigma–Aldrich, St. Louis, MO, USA in 0.9 % saline). The corneas were briefly flushed with isotonic Ringer’s solution (DeltaSelect GmbH, Pfullingen, Germany) to remove excess fluoresceine prior to being photographed. Samples of MEM from the artificial anterior chamber outflow were taken according to our protocol and analysed for glucose, lactate and pH (Bayer Automatic Analyser; Rapid Lab 860; Siemens Diagnostics, Fernwald, Germany) to monitor the corneal metabolism.

Healing measurements and corneal calcification

After one day of stabilization in the EVEIT culturing system and establishment of the epithelial integrity by fluoresceine staining of the surface, we applied four small abrasions (3–6 mm²) with a small dental drill (Arkansasschleifer 638XF, Meisinger, Stuttgart, Germany). All corneas were then cultured and treated with either eye drops or MEM (serving as control) for the following 3 days and all defects were monitored daily with fluoresceine staining. The green fluorescence (Fig.1) indicates the areas of epithelial defects. The areas were photographed and measured by means of Diskus[®] software (Hilgers, Königswinter, Germany). Corneal calcifications were visually defined as distinct white, opaque structures and interpreted as either present or absent. To substantiate the asserted calcification by histological examination, all corneas were snap frozen at the end of the experimental time (4 days). Cryosections were prepared and stained according to von Kossa to detect calcium deposits within the exposed corneas. Here, a grading

scheme to quantify the calcium deposits within the cornea was applied ranging from 0 (no staining) to 4 (complete staining of epithelium and upper stroma).

Application of test substances

We used an artificial tear replacement solution adjusted to this citrate content of 14.581mmol/l Ca^{2+} in 0.9% saline solution (Delta Select, Germany). This solution was applied once per hour onto the corneas, providing 11.7 μg Ca^{2+} .

During the experiment we compared HYLO-COMOD[®] and HYLO-CARE[®] both of which contain a phosphate buffer and are longer commercially available, with HYLO-LASOP[®], which now contains citrate buffer (all Ursapharm GmbH, Saarbruecken, Germany).

Each one of these unpreserved hyaluronate drops were applied, along with the artificial tear replacement by using two separate dropping devices, exactly over the apex of the cornea. Controls were represented by corneas treated with MEM and artificial tear replacement in the same manner.

A 20 μl drop of each solution was applied hourly for 3 days, with a time difference of 30 minutes between applications of the test substance and the artificial tears. A soft-tipped cannula, applying continuous suction, was placed on the lower side of the cornea in culture to remove excess fluid.

Osmometry

Osmolarities of all eye drops were measured with the Osmomat[®] 030 (Gonotec, Berlin, Germany). The applied substances were in the range of 260–390 mOsmol/kg (hyaluronate phosphate eye drops 262 \pm 1.9 mOsmol/kg; hyaluronate citrate 272 \pm 1.5

mOsmol/kg; MEM 383 ± 3.3 mOsmol/kg; artificial tears containing CaCl_2 317 ± 1.3 mOsmol/kg).

Results:

All 10 corneas which were treated with hyaluronate phosphate and artificial tears showed distinct white opaque spots at all 40 abraded areas, suggesting strong corneal calcifications. Coincidentally, as shown in figure 2a, the calcified corneas showed significant closure of the epithelial defects after 3 days (as determined by negative fluoresceine staining; Fig. 2a). Histological analysis of these corneas via von Kossa staining confirmed the visual appearances and highlighted the dense calcifications especially at the location of epithelial scrapings (Fig. 2b).

However, the five corneas treated with hyaluronate citrate and artificial tears showed a completely clear, smooth surface devoid of any visual calcification after 3 days of treatment. A slight positive fluorescein staining of the surface was still detectable at the end of the experiment, which indicates that some epithelial damage remained (Fig. 2 c).

None of the corneas exposed to these drops showed a positive result for the von Kossa stain (Fig. 2 d).

Throughout the 3 days of culture, all 6 controls (24 drops MEM/day) showed considerable healing down to approximately half of the surface area of the initial abrasions (Fig. 2 e) and no calcification was visually apparent.

Although the MEM contains a small amount of phosphate (0.9mmol/l), calcification is therefore possible however was not detectable in our experimental conditions. No calcium deposits in the corneal stroma were visually observed, as compared to that seen

in the cases of phosphate buffered eye drop (50.9mmol/l [4]) treatment, only the histological analysis showed trace evidence of calcium deposits or calcium salts (Fig. 2 f).

Sample	No. of corneas	mean healing (% of initially damaged area)	von Kossa (0-4)	visual calcification
HYLO-COMOD phosphate	2	94.5 ± 0.70	4 / 4	+ / +
HYLO-CARE phosphate	8	75.25 ± 4.23	4 / 4 / 4 / 4 / 4 / 4 / 4 / 4	+ / + / + / + / + / + / + / +
HYLO-LASOP citrate	5	84.4 ± 9.81	0 / 0 / 0 / 0 / 0	- / - / - / - / -
MEM	6	57.8 ± 12.73	1 / 1 / 1 / 1 / 1 / 1	- / - / - / - / - / -

Tab.1: Summary of all performed experiments

All treated corneas, as displayed in table 1, showed predominately good healing. Slower healing was detected for MEM compared to advanced healing achieved by using HYLO-LASOP[®] and HYLO-COMOD[®] (p<0.01, Fisher's test). However, there was no statistical difference (p >0.05) between the hyaluronate treatments, either buffered with phosphate or citrate.

The dense, white opacifications, macroscopically apparent at the sites of injury and whose damage is further highlighted by light microscopy, as demonstrated by the von Kossa stains, could only be due to the application of phosphate containing hyaluronate eye drops.

No opacification caused by stromal calcification was found in any other group. . Statistically, the staining of the hyaluronate phosphate treated corneas showed to be significant different (p < 0.001, Dunns multiple comparison test) to the results achieved after treatment with the citrate buffered hyaluronate eye drops.

The Fisher's test revealed a highly significant correlation of the achieved corneal calcification to the presence of phosphate in the used eye drops (p<0.001).

However, histological analysis of the MEM treated corneas demonstrated very slight amounts of surplus calcium.

During the experimental time the measured pH values in all groups always stayed in the defined range of 7.4 ± 0.2 . Monitoring the corneal metabolism according to our protocol by measuring the lactate production in the outflow medium of chamber showed that all corneas in each group exceeded the determined lowest value of 1.0 mMol/l.

Discussion:

There is no doubt that mixtures of phosphate and calcium ions immediately form calcium phosphate or calcium apatite. Both compounds have a very low water solubility which decreases with increasing pH or temperature. Stanley [9], Leopold [10] and Caldeira [11] published the calcium content in tears to be in the order of 0.0211 to 0.041 $\mu\text{g}/\mu\text{l}$ with a basic secretion rate of 120 to 240 $\mu\text{l}/\text{h}$ [12]: this results in a calcium introduction onto the corneal surface in the range of 2.53 to 9.84 $\mu\text{g}/\text{h}$ for the healthy eye. As the tear secretion rate is upregulated during eye injury as simulated here, values above this range are expected.

A limitation to the EVEIT experimental system is an obvious absence of natural tear production which provides the corneal surface with calcium. This absence would undermine the natural emergence of possible calcified spots while using phosphate buffered eye drops. Additionally, the citrate buffer in the new formulated hyaluronate drops can withdraw calcium ions from the corneal surface thereby affecting epithelial

healing. To overcome these obstacles we introduced artificial tears containing a physiological amount of calcium.

The capability of the EVEIT in effectively and reproducibly predicting the potential toxic effects of topical application on the eye has been demonstrated in earlier experiments [13,14,15] and we here could exemplify the practicability of the EVEIT in the evaluation of pharmaceutical products. This study identified that the addition of phosphate in eye drops is an important factor in inducing calcification of the corneal surface following injury. We were able to support experimentally the clinical findings of Bernauer et al. [4,7] who observed this in cases of keratoconus [16], dry eye [17] and vernal conjunctivitis [18] and demonstrate that excessive use of phosphate containing drugs is associated with corneal calcification. These results also confirm that calcified deep stromal tissue is related to early changes in the mineral composition of the cornea. This has similarly been shown for eye burns [1,6] due elevated phosphate concentrations in combination with the normal tear calcium content [10] leading to undesired side effects. We have demonstrated that using a citrate based buffer instead of phosphate based in eye drop formulations to be a better and safe choice of therapy. Even with high dropping rates it is unlikely that the citrate buffer chelating capacity will exceed the calcium supply by normal [11,12] or elevated tear secretion especially in dry eye syndromes or superficial corneal damages the artificial tears most likely will be used.

Additionally we observed distinct stages of corneal healing following the various types of repeated applications. These results led us to the assumption that hyaluronate eye drops improved epithelial healing after deliberate damages, even in large areas of corneal damages such as used in these particular experiments.

With these available ophthalmologic lubricants relevant epithelial defects such as those caused by severe dry eyes, mechanical scraping, photorefractive and phototherapeutic excimer ablations, corneal ulcers and eye burns can also be treated successfully without any risk of calcification.

Acknowledgements:

This work was partially supported by Ursapharm Arzneimittel GmbH & Co. KG, Saarbrücken, Germany, who supplied the hyaluronate eye drops containing citrate. Staff costs, equipment, and other materials were financed by ACTO e.V., and by the Department of Ophthalmology, University Hospital, Aachen, Germany. Ursapharm GmbH had no influence on the proposed working programme, or on the results, data interpretation or text presented here.

We also thank Sara D. Sackett and Felix Spöler for their selfless help in revising this manuscript.

Licence for Publication:

The Corresponding Author has the right to grant on behalf of all authors and does grant on behalf of all authors, an exclusive licence (or non exclusive for Government employees) on a worldwide basis to the BMJ Publishing Group Ltd and its Licensees to permit this article (if accepted) to be published in BJO editions and any other BMJPG

products to exploit all subsidiary rights, as set out in our licence

(<http://group.bmj.com/products/journals/instructions-for-authors/licence-forms/>).

Competing Interest:

None to declare

References:

- [1] von Fischern T, Lorenz U, Burchard WG, Reim M, Schrage NF. Changes in the mineral composition of the rabbit cornea after alkali burns. *Graefe's Archive for Clinical and Experimental Ophthalmology* 1998; 236:553-8.
- [2] Langefeld S, Reim M, Redbrake C, Schrage NF. The corneal stroma, an inhomogenous structure. *Graefe's Archive for Clinical and Experimental Ophthalmology* 1997;235:480-5.
- [3] Huige WMM, Beekhuis WH, Rijnfeld WJ, Schrage NF, Remeijer L. Deposits in the superficial corneal stroma after combined topical corticosteroid and beta-blocking medication. *European Journal of Ophthalmology* 1991;1:198-9.
- [4] Bernauer W, Thiel MA, Kurrer M, Heiligenhaus A, Rentsch KM, Schmitt A, Heinz C, Yanar A. Corneal calcification following intensified treatment with sodium hyaluronate artificial tears. *British Journal of Ophthalmology* 2006;90:285-8.
- [5] Schrage NF, Schlossmacher B, Aschenbrenner W, Langefeld S. Phosphate buffer in alkali eye burns as an inducer of experimental corneal calcification. *Burns* 2001;27:459-64.
- [6] Schrage NF, Kompa S, Ballmann B, Reim M, Langefeld S. Relationship of eye burns with calcifications of the cornea? *Graefe's Archive for Clinical and Experimental Ophthalmology* 2005;243:780-4.
- [7] Bernauer W, Thiel MA, Langenauer UM, Rentsch KM. Phosphate concentration in artificial tears. *Graefe's Archive for Clinical and Experimental Ophthalmology* 2006;244:1010-4.

- [8] HYLO-COMOD: citrate buffered hyaluronate artificial tears. Medical information, Ursapharm pharmazeutische Fabrik, 2007.
- [9] Stanley JA. Water permeability of the human cornea. Archives Ophthalmology 1992;87:568-73.
- [10] Leopold IH, Lieberman TW. Chemical injuries of the cornea. Federation proceedings 1971;30:92-5.
- [11] Caldeira JA, Sabbaga E, Ianhez LE. Conjunctival and corneal changes in renal failure. Influence of renal transplantation, British Journal of Ophthalmology 1970;54:399-404.
- [12] Maurice DM. The tonicity of an eye drop and its dilution by tears. Experimental eye research 1971;11:30-3.
- [13] Frenz M, Goss M, Reim M, Schrage NF. Repeated exposure to benzalkonium chloride in the Ex Vivo Eye Irritation Test (EVEIT): observation of isolated corneal damage and healing. ATLA 2008;36:25-32.
- [14] Spöler F, Frenz M, Först M, Kurz H, Schrage NF. Analysis of hydrofluoric acid penetration and decontamination of the eye by means of time-resolved optical coherence tomography. Burns. 2008;34:549-55.
- [15] Spöler F, Först M, Kurz H, Frenz M, Schrage NF. Dynamic analysis of chemical eye burns using high-resolution optical coherence tomography. Journal of Biomedical Optics. 2007;12:041203.
- [16] Lema I, Duran JA. Inflammatory molecules in the tears of patients with keratoconus. Ophthalmology 2005;112:654-9.

- [17] Luo L, Li DQ, Doshi A, Farley W, Corrales RM, Pflugfelder SC. Experimental dry eye stimulates production of inflammatory cytokines and MMP-9 and activates MAPK signaling pathways on the ocular surface. *Investigative ophthalmology & visual science* 2004;45:4293-301.
- [18] Ebihara N, Funaki T, Takai S, Miyazaki M, Fujiki K, Murakami A. Tear chymase in vernal keratoconjunctivitis. *Current eye research* 2004;28:417-20.

Figures:

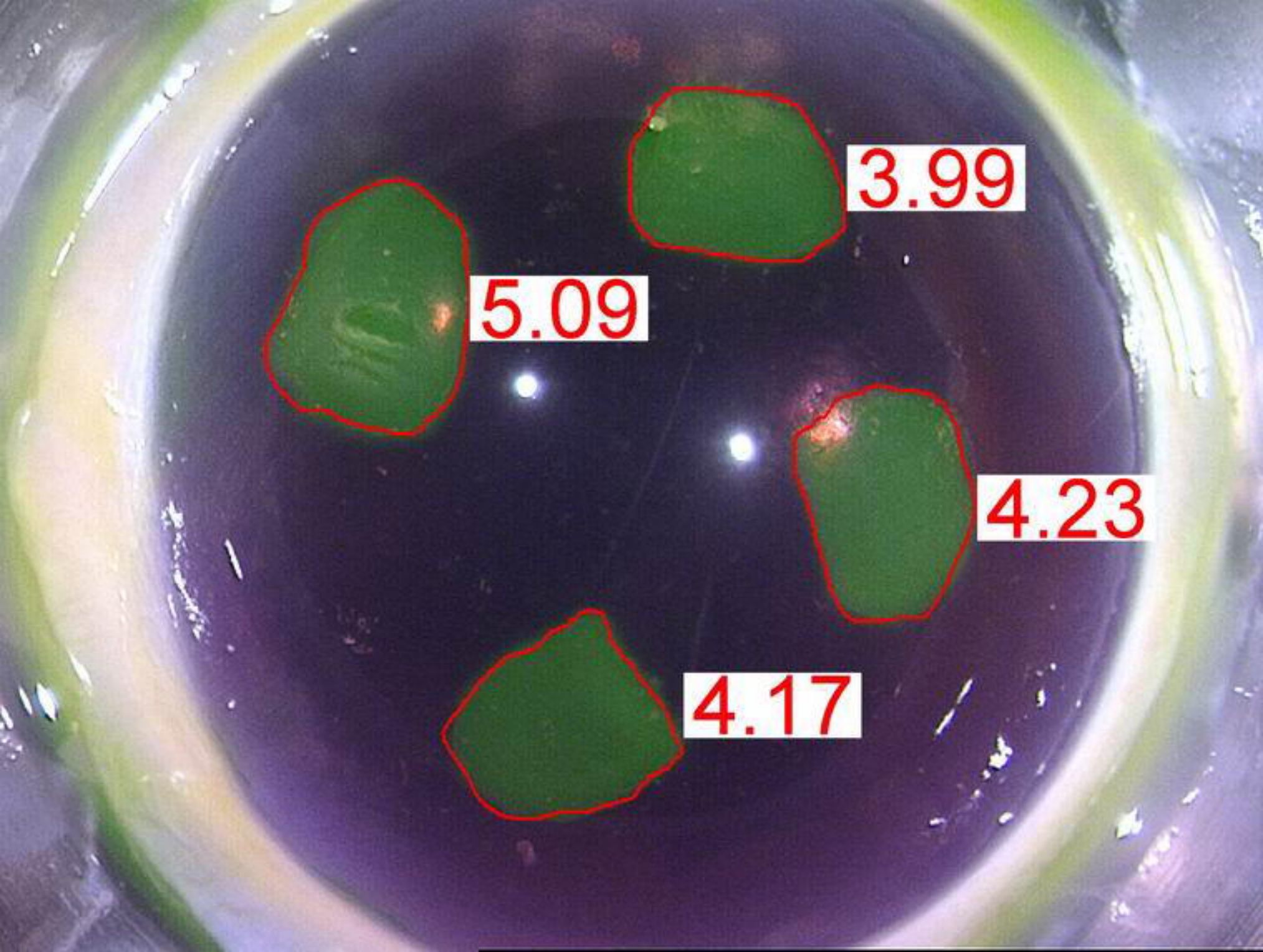
Fig.1: Fluoresceine stained cornea with measurements of injured area [mm^2]

Fig.2: Visual appearances of representative corneas after 3 day of treatment.

(a) Healed but calcified spots caused by dropping the corneal surface with phosphate containing eye drops and artificial tears (1/h). (b) Positive von Kossa stain of one of the calcified areas. (c) Citrate buffered hyaluronate eye drops and artificial tears produced a smooth and clear corneal surface. (d) No excessive calcium deposits are visible with von Kossa, and the formerly wounded epithelium has healed completely. (e) Abraded cornea after treatment with medium and artificial tears. (f) The verification stain for calcium showed slightly elevated levels of the targeted ion at the site of injury.

Tables:

Tab.1: Summary of all performed experiments



5.09

3.99

4.23

4.17

