



HAL
open science

Image-guided resection of small lesions in the cavernous sinus and Meckel's cave

M. Nakamura, J.K. Krauss

► **To cite this version:**

M. Nakamura, J.K. Krauss. Image-guided resection of small lesions in the cavernous sinus and Meckel's cave. *EJSO - European Journal of Surgical Oncology*, 2010, 36 (2), pp.208. 10.1016/j.ejso.2009.07.004 . hal-00557763

HAL Id: hal-00557763

<https://hal.science/hal-00557763>

Submitted on 20 Jan 2011


HAL is a multi-disciplinary open access archive for the deposit and dissemination of scientific research documents, whether they are published or not. The documents may come from teaching and research institutions in France or abroad, or from public or private research centers.

L'archive ouverte pluridisciplinaire **HAL**, est destinée au dépôt et à la diffusion de documents scientifiques de niveau recherche, publiés ou non, émanant des établissements d'enseignement et de recherche français ou étrangers, des laboratoires publics ou privés.

Accepted Manuscript

Title: Image-guided resection of small lesions in the cavernous sinus and Meckel's cave

Authors: M. Nakamura, J.K. Krauss



PII: S0748-7983(09)00226-1

DOI: [10.1016/j.ejso.2009.07.004](https://doi.org/10.1016/j.ejso.2009.07.004)

Reference: YEJSO 2858

To appear in: *European Journal of Surgical Oncology*

Received Date: 7 March 2009

Revised Date: 27 June 2009

Accepted Date: 2 July 2009

Please cite this article as: Nakamura M, Krauss JK. Image-guided resection of small lesions in the cavernous sinus and Meckel's cave, *European Journal of Surgical Oncology* (2009), doi: 10.1016/j.ejso.2009.07.004

This is a PDF file of an unedited manuscript that has been accepted for publication. As a service to our customers we are providing this early version of the manuscript. The manuscript will undergo copyediting, typesetting, and review of the resulting proof before it is published in its final form. Please note that during the production process errors may be discovered which could affect the content, and all legal disclaimers that apply to the journal pertain.

TITLE

Image-guided resection of small lesions in the cavernous sinus and Meckel's cave

AUTHORS:

M. Nakamura, MD and J.K. Krauss, MD

Department of Neurosurgery, Medical University Hannover, Hannover, Germany

CORRESPONDING AUTHOR AND REPRINT REQUESTS:

Makoto Nakamura, MD

Department of Neurosurgery

Medizinische Hochschule Hannover

Carl-Neuberg-Str. 1

30625 Hannover, Germany

Phone: +49 – 511 – 5323770

Fax: +49 – 511 – 5325864

E-Mail: nakamura.makoto@mh-hannover.de

Key words: neuronavigation; computer assisted surgery; cavernous sinus; Meckel's cave

Running head: Image-guided surgery in the cavernous sinus and Meckel's cave

Objective: The microsurgical resection of tumors or vascular lesions in the cavernous sinus and the neighbouring Meckel's cave has been considered as hazardous because of often associated cranial nerve morbidity. Despite increasing consent that many of such tumors should not undergo surgical therapy, the cavernous sinus and Meckel's cave may harbour small lesions of various origin, which are amenable for surgical resection. Surgery in this anatomical area needs a well directed approach. In this setting, neuronavigational guidance may provide a useful tool. We report on a series of patients operated on guided by neuronavigation.

Methods: Five patients underwent a pterional approach for microsurgical resection. The procedures were planned and assisted by a pointer based neuronavigation system (Medtronic Stealth Station). Pathological entities included schwannoma, epidermoid, cavernoma and capillary hemangioma. Three lesions were located in the Meckel's cave and two lesions in the cavernous sinus.

Results: Intraoperative guidance by neuronavigation appeared to be particularly instrumental in identification of the appropriate site of dural incision over the target region for microsurgical resection. Except of a mild increase of facial hypesthesia in one patient, there were no new cranial nerve deficits. In three patients, preoperative symptoms improved immediately after surgery.

Conclusion: The surgical resection of small tumors or vascular lesions within the Meckel's cave or cavernous sinus is facilitated by neuronavigational guidance with sufficient intraoperative reliability and safety. In consideration of well known anatomical landmarks, targeted entry into the cavernous sinus or Meckel's cave directed by neuronavigation enables a tailored approach for microsurgical resection.

Introduction

The cavernous sinus, located at the central cranial base, and the neighbouring Meckel's cave represent a complex anatomical region, which is surrounded by dural walls containing important neurovascular structures^{1,2}. It may harbour various neoplastic and vascular lesions of different origin, which are increasingly found in an early stage of growth because of the advent and availability of modern imaging studies³. The issue concerning the best treatment option for such lesions and preferable surgical approaches to this region are still a matter of debate⁴⁻⁷. Since the pioneering work of Parkinson⁸ various surgical approaches have been described to approach the cavernous sinus or Meckel's cave including either an intra- or extradural transcranial approach⁵⁻¹⁰ or more recently the endoscopic transsphenoidal approach^{11,12}. Although the microsurgical anatomy of this region has been extensively described in the past^{8,10,13-16}, surgical exposure is still challenging. Because of the complex anatomy and density of critically important neurovascular structures, many lesions in this area have been considered as unresectable¹⁷⁻¹⁹. The microsurgical exposure itself may often lead to high cranial nerve morbidity. In addition, the advent of radiosurgery has resulted in a decrease of patients undergoing microsurgical resection of lesions in the cavernous sinus¹⁷⁻¹⁹.

Despite increasing consent that many tumors with intracavernous infiltration, for example cavernous sinus meningiomas, should not undergo surgical resection, the cavernous sinus and Meckel's cave may harbour small lesions of other origin, which are amenable for a cure with surgical therapy. In consideration of other therapeutic options nowadays, microsurgical resection in this anatomical area needs a well directed approach with avoidance of any cranial nerve morbidity. In this setting, intraoperative image guidance may provide a useful tool. We have reported on our experience with navigated approaches to the clivus and the anterior skull base elsewhere²⁰. In this report, we present a series of patients

operated on small lesions of the cavernous sinus and Meckel's cave guided by neuronavigation.

Patients and Methods

Our surgical series included 5 patients, who underwent neuronavigation guided microsurgical resection of a small neoplastic or vascular lesion in the cavernous sinus or Meckel's cave between 2007 and 2008 at the Department of Neurosurgery, Hannover Medical University, Germany.

Lesions included a cavernous angioma and an epidermoid tumor in the cavernous sinus. Three lesions were confined to the Meckel's cave including a capillary hemangioma²¹, schwannoma and a tumor of unconfirmed origin (histologically most consistent with schwannoma) (Table 1).

There were 4 women and 1 man, mean age at surgery was 42,4 years (16-71 years).

Imaging Studies

Preoperative CT and MRI scans were obtained in all patients with and without intravenous administration of a contrast agent.

Surgery

Surgeries were planned and assisted by advanced Computer-assisted surgical techniques with image fusion of preoperative CT and MRI (Treon, Medtronic Stealth Station). Registration for the neuronavigation system was achieved via surface matching.

Surgery was performed in general anaesthesia using the operating microscope and microsurgical instrumentation in all cases. The lesion was approached by a

standard pterional craniotomy. The surgical corridor to the cavernous sinus or Meckel's cave was determined by the location of the lesion and its extension along the dural surface. Once the lesion was identified with the help of image guidance, entry into the cavernous sinus was performed over the lesion starting with superficial incision of the meningeal layer of the cavernous sinus dura directing the incision in parallel to the extended intracavernous course of the entering cranial nerves. Dural incision was never performed perpendicular to the presumed course of the nerves. Incision of the dura over the Meckel's cave was performed in an analogous fashion according to the trigeminal nerve. These measures enabled us to enter the cavernous sinus or Meckel's cave without damage to the nerves at risk and cautious dissection was possible in small lesions.

In general, the set up and application of neuronavigation during the surgical procedure required 30-45 minutes additionally per case.

Results

Clinical features

The presenting clinical symptoms depended on the anatomical location of the lesions. Double vision was claimed in both patients with a cavernous sinus lesion (Figures 1 A and B) and symptoms of trigeminal affection were reported in all three patients harbouring a lesion in the Meckel's cave.

The clinical symptoms and signs were summarized in Table 1.

Neuronavigational guidance

The accuracy of neuronavigation was verified preoperatively and several times intraoperatively comparing landmarks such as the pterion, anterior clinoid process and other fixed structures. There were no problems with shift of anatomical structures at the skull base during the course of surgery.

Margins of the lesions were defined by using neuronavigation in the coronal and axial plane on gadolinium enhanced MRI scans (Figures 1 A and B). Neuronavigational guidance revealed to be useful in defining the anterior and posterior margins of the lesion. Particularly, it was instrumental in defining the depth of each lesion into the cavernous sinus or Meckel's cave. There was no interacting shift of assumed borders of the lesion both in the cavernous sinus and Meckel's cave.

Radicality of tumor removal

Total tumor removal was achieved in 3 out of 5 patients. In one patient with an interdural epidermoid tumor of the cavernous sinus, the medial capsule of the tumor was left in situ because of severe adherence to the oculomotor nerve. In one patient with a tumor of the Meckel's cave (patient no. 5), a subtotal resection was performed because of significant tumor adherence to the trigeminal nerve (Table 1).

Clinical outcome

In three patients, preoperative cranial nerve deficits improved immediately after surgery. In one patient, facial numbness increased postoperatively and in another patient there was no improvement of preoperative abducens nerve palsy after surgery.

No new postoperative deficits of cranial nerves occurred and there was no procedure related morbidity or mortality.

The mean follow-up time was 13.4 months (7-20 months). A recurrence of the lesion was not found during this follow up period.

Discussion

Treatment strategies for lesions of the cavernous sinus and Meckel's cave

Treatment strategies for neoplastic and vascular lesions of the cavernous sinus and Meckel's cave have undergone considerable changes since the introduction of cavernous sinus surgery decades ago by Bowder and Parkinson⁸. Detailed microanatomical studies of the cavernous sinus and Meckel's cave have initially contributed to the development of various surgical approaches to this critical region⁵⁻¹⁰. Intra- or extradural approaches usually via a frontotemporal or pterional craniotomy with different amount of additional osteotomy (including the orbit or zygoma) were described⁸⁻¹⁰ in order to attempt exposure of cranial nerves and the carotid artery within the cavernous sinus. In neoplastic lesions, like meningiomas of the cavernous sinus, the main aim to enter the cavernous sinus was to achieve radical tumor removal and lower the risk of early tumor recurrence. Some authors favoured aggressive surgical removal^{22,23} even with intracavernous neural and vascular reconstruction²⁴, while others have shown that there is no oncological benefit in performing radical surgery within the cavernous sinus²⁵. Instead, radical removal of big tumors in the cavernous sinus has increasingly shown to be associated with a very high risk of injury to the carotid artery and almost always lead to cranial nerve deficits with unacceptable impairment of life quality after surgery²⁵. Reports have consecutively emphasized that the surgical exploration of the cavernous sinus itself is often associated with cranial nerve deficits or excessive bleeding, even when meticulous microsurgical dissection within the cavernous sinus was performed. Although techniques to approach the cavernous sinus have been extensively described^{2,6,16}, the visualization of intracavernous cranial nerves and the carotid artery requires elaborate extradural bone removal and hazardous dissection between the two dural layers of the cavernous sinus. Therefore, there are still controversial opinions concerning the optimal treatment options for tumors like meningiomas, which lead to extensive infiltration of the cavernous sinus. Some authors prefer a more conservative approach with

combination of limited extracavernous tumor resection and adjuvant radiosurgery²⁶⁻²⁸ or radiosurgery alone^{18,29,30}.

Surgery of small vascular or nonmeningeal neoplastic lesions

Surgery for nonmeningeal tumors of the cavernous sinus are considered safer than surgery for meningiomas and total tumor removal may often be achieved². Due to the density of important neurovascular structures within the cavernous sinus and Meckel's cave, small vascular or other nonmeningeal neoplastic lesions can lead to early compression syndromes of cranial nerves. Even when dealing with small nonmeningeal lesions of the cavernous sinus or Meckel's cave, the mainstay of cavernous sinus surgery was to visualize most of the intracavernous cranial nerves along with the intracavernous carotid artery in an early step of surgery to gain initial control over these critical structures. It was often recommended that proximal and distal control of flow through the internal carotid artery should be achieved before proceeding to the cavernous sinus². With this approach, the surgical preparation until entrance into the cavernous sinus would require time consuming bone work (for example drilling of the anterior clinoid or exposure of the carotid artery along its petrous segment) and the surgical exposure of these structures itself may present an additional risk of morbidity.

Image-guidance in surgery of the cavernous sinus or Meckel's cave

In limited and small symptomatic lesions of the cavernous sinus or Meckel's cave, a direct intradural exposure of the lesion through the dural walls of the cavernous sinus or Meckel's cave can be feasible without superfluous anatomical dissection. However, for this purpose, a well directed approach to the lesion with opening of the dural layer precisely over the target needs to be accomplished. Small lesions lying within the cavernous sinus or Meckel's cave may not always be visible through inward protrusion or bulging into the parasellar cisterns. In those cases,

the use of neuronavigation revealed to be useful to guide the surgeon to the lesion, allowing a targeted opening of the dura over the cavernous sinus or Meckel's cave. In such lesions, which were large enough to be recognized due to bulging of the dura, still the determination of tumor extension, especially to the anterior, posterior and medial direction, was helpful to estimate the grade of resection and particularly the distance to the intracavernous carotid artery. The application of a pointer based neuronavigation system with surface matching of the data revealed to be sufficient for a reliable and safe image guidance at the base of the skull, particularly the cavernous sinus and Meckel's cave. With image-guidance, the site of the lesion may be delineated on the surface of the cavernous sinus wall or Meckel's cave, however, the method of entrance into the cavernous sinus will be crucial to avoid any nerve injury during exposure of the lesion. It is not possible to identify the nerves directly using the image-guidance pointer, but the operative measures described previously, enabled us to enter the cavernous sinus or Meckel's cave without damage to the nerves at risk. The overall outcome of cranial nerve function after surgery was excellent and there was no new cranial nerve deficit related to the surgical opening of the cavernous sinus or Meckel's cave. However, larger numbers of patients, who undergo image-guided resection of such lesions, need to be further investigated and the results compared with cases, which underwent surgery without the application of image-guidance.

Image-guided skull base surgery

Intracranial neuronavigation and image guided surgery is already well established in neurosurgery and in ENT surgery, while there is still relatively little experience in skull base surgery. Although rarely used, image guided surgery for skull base lesions appears to be an ideal application as no or only minimal intraoperative shift of relevant structures is to be expected compared to its application to surgery of intracerebral or other lesions. The application of image guidance and its

advantages for a targeted resection of lesions in the cavernous sinus or Meckel's cave have not been reported so far. In our series, selected small lesions of the cavernous sinus and Meckel's cave could be resected with image guidance without any new cranial nerve deficit, which reportedly is the most common morbidity after cavernous sinus surgery.

In our experience, the use of neuronavigation may help to achieve a targeted exposure of selected small lesions in the cavernous sinus and Meckel's cave, obviating the need for extensive surgical dissection of this densely packed and critical anatomical region. Although image guidance at the cavernous sinus or Meckel's cave seems to be precise enough to accurately guide the surgeon to the lesion, it cannot replace detailed microanatomical knowledge of this complex region, which every skull base surgeon needs to acquire beforehand.

Conclusion

The microsurgical resection of small lesions of the cavernous sinus and Meckel's cave can be enhanced by image-guidance allowing targeted exposure of the lesion with safe removal under preservation of important neurovascular structures within this highly sophisticated region.

Reference List

1. Rhoton AL, Jr., Harris FS, Renn WH. Microsurgical Anatomy of the Sellar Region and Cavernous Sinus. *Clin Neurosurg* 1977; 24: 54-85.
2. Yasuda A, Campero A, Martins C, Rhoton AL, Jr., de Oliveira E, Ribas GC. Microsurgical Anatomy and Approaches to the Cavernous Sinus. *Neurosurgery* 2008; 62(6 Suppl 3): 1240-63.
3. Razek AA, Castillo M. Imaging Lesions of the Cavernous Sinus. *AJNR Am J Neuroradiol* 2009; 30(3): 444-52.
4. Al Mefty O, Smith RR. Surgery of Tumors Invading the Cavernous Sinus. *Surg Neurol* 1988; 30(5): 370-81.
5. Sepehrnia A, Samii M, Tatagiba M. Management of Intracavernous Tumours: an 11-Year Experience. *Acta Neurochir Suppl (Wien)* 1991; 53: 122-6.
6. Dolenc VV. Surgery of Vascular Lesions of the Cavernous Sinus. *Clin Neurosurg* 1990; 36: 240-55.
7. Sekhar LN, Linskey ME, Sen CN, Altschuler EM. Surgical Management of Lesions Within the Cavernous Sinus. *Clin Neurosurg* 1991; 37: 440-89.
8. Parkinson D. A Surgical Approach to the Cavernous Portion of the Carotid Artery. *Anatomical Studies and Case Report. J Neurosurg* 1965; 23(5): 474-83.
9. Hakuba A, Tanaka K, Suzuki T, Nishimura S. A Combined Orbitozygomatic Infratemporal Epidural and Subdural Approach for Lesions Involving the Entire Cavernous Sinus. *J Neurosurg* 1989; 71(5 Pt 1): 699-704.
10. Inoue T, Rhoton AL, Jr., Theele D, Barry ME. Surgical Approaches to the Cavernous Sinus: a Microsurgical Study. *Neurosurgery* 1990; 26(6): 903-32.
11. Alfieri A, Jho HD. Endoscopic Endonasal Approaches to the Cavernous Sinus: Surgical Approaches. *Neurosurgery* 2001; 49(2): 354-60.
12. Jho HD, Ha HG. Endoscopic Endonasal Skull Base Surgery: Part 2--The Cavernous Sinus. *Minim Invasive Neurosurg* 2004; 47(1): 9-15.
13. Kawase T, van Loveren H, Keller JT, Tew JM. Meningeal Architecture of the Cavernous Sinus: Clinical and Surgical Implications. *Neurosurgery* 1996; 39(3): 527-34.
14. Krisht A, Barnett DW, Barrow DL, Bonner G. The Blood Supply of the Intracavernous Cranial Nerves: an Anatomic Study. *Neurosurgery* 1994; 34(2): 275-9.
15. van Loveren HR, Keller JT, el Kalliny M, Scodary DJ, Tew JM, Jr. The Dolenc Technique for Cavernous Sinus Exploration (Cadaveric Prosection). *Technical Note. J Neurosurg* 1991; 74(5): 837-44.
16. Umansky F, Nathan H. The Lateral Wall of the Cavernous Sinus. With Special Reference to the Nerves Related to It. *J Neurosurg* 1982; 56(2): 228-34.

17. Duma CM, Lunsford LD, Kondziolka D, Harsh GR, Flickinger JC. Stereotactic Radiosurgery of Cavernous Sinus Meningiomas As an Addition or Alternative to Microsurgery. *Neurosurgery* 1993; 32(5): 699-704.
18. Iwai Y, Yamanaka K, Ishiguro T. Gamma Knife Radiosurgery for the Treatment of Cavernous Sinus Meningiomas. *Neurosurgery* 2003; 52(3): 517-24.
19. Nicolato A, Foroni R, Alessandrini F, Bricolo A, Gerosa M. Radiosurgical Treatment of Cavernous Sinus Meningiomas: Experience With 122 Treated Patients. *Neurosurgery* 2002; 51(5): 1153-9.
20. Nakamura M, Stover T, Rodt T, Majdani O, Lorenz M, Lenarz T, Krauss JK. Neuronavigational Guidance in Craniofacial Approaches for Large (Para)Nasal Tumors Involving the Anterior Skull Base and Upper Clival Lesions. *Eur J Surg Oncol* 2008.
21. Montibeller GR, Nakamura M, Brandis A, Krauss JK. Capillary Hemangioma of the Meckel Cave in an Adolescent. Case Illustration. *J Neurosurg Pediatrics* 2008; 1(2): 170.
22. DeMonte F, Smith HK, Al Mefty O. Outcome of Aggressive Removal of Cavernous Sinus Meningiomas. *J Neurosurg* 1994; 81(2): 245-51.
23. George B, Ferrario CA, Blanquet A, Kolb F. Cavernous Sinus Exenteration for Invasive Cranial Base Tumors. *Neurosurgery* 2003; 52(4): 772-80.
24. Sekhar LN, Burgess J, Akin O. Anatomical Study of the Cavernous Sinus Emphasizing Operative Approaches and Related Vascular and Neural Reconstruction. *Neurosurgery* 1987; 21(6): 806-16.
25. Sindou M, Wydh E, Jouanneau E, Nebbal M, Lieutaud T. Long-Term Follow-Up of Meningiomas of the Cavernous Sinus After Surgical Treatment Alone. *J Neurosurg* 2007; 107(5): 937-44.
26. Abdel-Aziz KM, Froelich SC, Dagnew E, Jean W, Breneman JC, Zuccarello M, van Loveren HR, Tew JM, Jr. Large Sphenoid Wing Meningiomas Involving the Cavernous Sinus: Conservative Surgical Strategies for Better Functional Outcomes. *Neurosurgery* 2004; 54(6): 1375-83.
27. Maruyama K, Shin M, Kurita H, Kawahara N, Morita A, Kirino T. Proposed Treatment Strategy for Cavernous Sinus Meningiomas: a Prospective Study. *Neurosurgery* 2004; 55(5): 1068-75.
28. Pamir MN, Kilic T, Bayrakli F, Peker S. Changing Treatment Strategy of Cavernous Sinus Meningiomas: Experience of a Single Institution. *Surg Neurol* 2005; 64 Suppl 2: S58-S66.
29. Kuo JS, Chen JC, Yu C, Zelman V, Giannotta SL, Petrovich Z, MacPherson D, Apuzzo ML. Gamma Knife Radiosurgery for Benign Cavernous Sinus Tumors: Quantitative Analysis of Treatment Outcomes. *Neurosurgery* 2004; 54(6): 1385-93.
30. Roche PH, Regis J, Dufour H, Fournier HD, Delsanti C, Pellet W, Grisoli F, Peragut JC. Gamma Knife Radiosurgery in the Management of Cavernous Sinus Meningiomas. *J Neurosurg* 2000; 93 Suppl 3: 68-73.

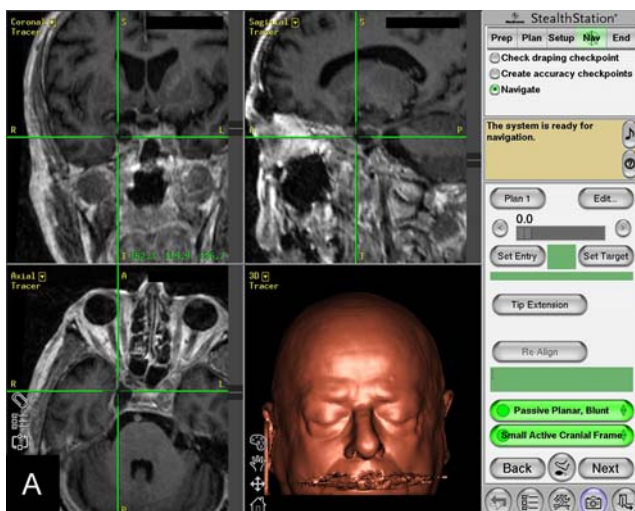
Figure legends

Figure 1: Case No. 2. 71-year-old man presenting with an epidermoid tumor of the right cavernous sinus. The patient presented with a right sided oculomotor and abducens nerve palsy. **A:** Intraoperative application of neuronavigation based on T1-weighted MRI demonstrating the anterior border of the epidermoid tumor which corresponds to the tip of the navigation pointer. **B:** Posterior border of the tumor corresponding to the tip of the navigation pointer.

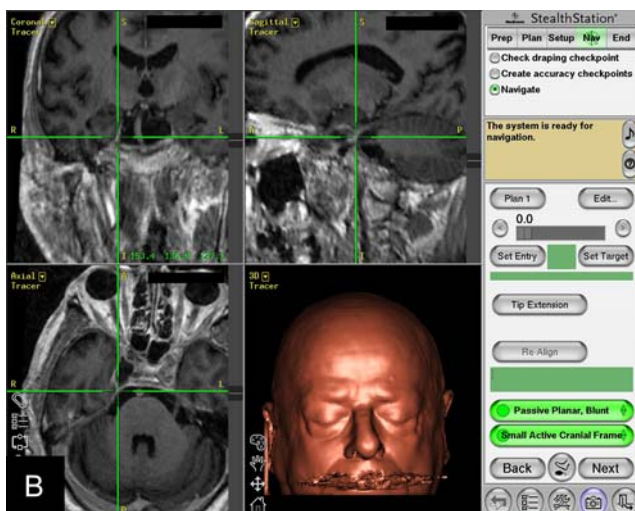
ACCEPTED MANUSCRIPT

Patient No.	Age / gender	Location	Size	Symptoms	Signs	MRI	Approach	Histology	Surgical removal	Outcome	Recurrence
1	44 F	CS	7 mm	Double vision, headache	CN VI palsy	T1-hypo + Gd-enhanc. T2-hyper	Pterional	Cavernous hemangioma	Total	No improvement of CN VI palsy	No
2	71 M	CS	12 mm	Double vision	CN III + VI palsy	T1-hypo - Gd-enhanc. T2-hyper	Pterional	Epidermoid	Subtotal	Improvement of CN III + VI palsy	No
3	16 F	CM	10 mm	Facial paresthesia	Paresthesia CN V1 + V2	T1-iso + Gd-enhanc. T2-hyper	Pterional	Capillary hemangioma	Total	Improvement of facial paresthesia	No
4	24 F	CM	14 mm	Facial hypesthesia	Hypesthesia CN V1-3	T1-iso + Gd-enhanc. T2 N/A	Pterional	Schwannoma	Total	Improvement of facial hypesthesia	No
5	57 F	CM	12 mm	Facial hypesthesia	Hypesthesia CN V1 + V2	T1-iso + Gd-enhanc. T2-iso	Pterional	Schwannoma ?	Subtotal	Increased facial hypesthesia	No

Table 1: Overview of patients who underwent image guided resection of lesions of the cavernous sinus or Meckel's cave. Abbreviations: CS, Cavernous sinus; CM, Cavum meckeli; CN, cranial nerve; enhance., enhancement; F, female; Gd, gadolinium; hyper, hyperintense; hypo, hypointense; iso, isointense; M, male; V1, 1st division of trigeminal nerve; V2, 2nd division of trigeminal nerve; V3, 3rd division of trigeminal nerve



ACCEPTED MANUSCRIPT



ACCEPTED MANUSCRIPT