HAL
open science

Brain microbleeds as a potential risk factor for antiplatelet-related intracerebral haemorrhage: hospital-based, case-control study

Simone M Gregoire, Hans R Jager, Tarek A Yousry, Constantinos Kallis, Martin M Brown, David J Werring

To cite this version:

Simone M Gregoire, Hans R Jager, Tarek A Yousry, Constantinos Kallis, Martin M Brown, et al.. Brain microbleeds as a potential risk factor for antiplatelet-related intracerebral haemorrhage: hospital-based, case-control study. Journal of Neurology, Neurosurgery and Psychiatry, 2010, 81 (6), pp.679. 10.1136/jnnp.2009.198994 . hal-00557436

HAL Id: hal-00557436

https://hal.science/hal-00557436v1

Submitted on 19 Jan 2011

HAL is a multi-disciplinary open access archive for the deposit and dissemination of scientific research documents, whether they are published or not. The documents may come from teaching and research institutions in France or abroad, or from public or private research centers.

L'archive ouverte pluridisciplinaire **HAL**, est destinée au dépôt et à la diffusion de documents scientifiques de niveau recherche, publiés ou non, émanant des établissements d'enseignement et de recherche français ou étrangers, des laboratoires publics ou privés.

Research Paper

Brain microbleeds as a potential risk factor for antiplatelet-related intracerebral haemorrhage: hospital-based, case-control study

S M Gregoire,[1] H R Jäger,[2] T A Yousry,[2] C Kallis,[3] M M Brown[1] and D J Werring[1]

Author affiliations: [1]Stroke Research Group and [2]Academic Neuroradiological Unit, Department of Brain Repair and Rehabilitation, UCL Institute of Neurology and National Hospital for Neurology and Neurosurgery, Queen Square, London, United-Kingdom; [3]Medical Statistics Unit, London School of Hygiene and Tropical Medicine, London, United-Kingdom.

Word count: Body text: 3434 (max 3500); Abstract: 249 (max 250)

Search terms: Stroke, Cerebral Haemorrhage, MRI, Aspirin

Correspondence to: Dr David J Werring, PhD, Stroke Research Group, National Hospital for Neurology and Neurosurgery Box 6, Queen Square, London WC1N 3BG, United-Kingdom; d.werring@ion.ucl.ac.uk. Telephone: +44 20 78298753. Fax: +44 20 78338613.

ABSTRACT

Background: Intracerebral haemorrhage (ICH) is an uncommon but devastating complication of regular antiplatelet use: identifying high risk patients before treatment could potentially reduce this hazard. Brain microbleeds on gradient-recalled echo (GRE) T2*-weighted MRI are considered a biomarker for bleeding-prone small vessel diseases. We hypothesized that microbleeds are a risk factor for antiplatelet-related ICH, and investigated this in a hospital-based matched case-control study.

Methods: Cases of spontaneous ICH were ascertained, using overlapping methods, from a prospective database of 1017 consecutive unselected patients referred to our stroke unit and associated clinics. For each case of antiplatelet-related ICH, 2 controls matched for age, sex and hypertension without history of ICH on antiplatelet therapy were selected. Microbleeds were identified by a trained observer blinded to clinical details.

Results: Microbleeds were more frequent in antiplatelet users with ICH than in matched antiplatelet users without ICH (13/16[81%] vs 6/32[19%], *p*=0.004) and patients with non antiplatelet-related ICH (13/16[81%] vs 15/33[45%], *p*=0.03). The frequency of lobar microbleeds was 11/16[69%] in antiplatelet-related ICH vs 11/33[33%] in non antiplatelet-related ICH (p=0.032). Microbleeds were more numerous in antiplatelet users with ICH compared to controls (*p*=0.016). The number of microbleeds was associated with the risk of antiplatelet-related ICH (adjusted OR 1.33 per additional microbleed, 95%CI 1.06-1.66, *p*=0.013).

Conclusions: Brain microbleeds are associated with antiplatelet-related ICH. In patients with a large number of lobar microbleeds, the risk of ICH could outweigh the benefits of antiplatelet therapy. Larger prospective studies to investigate the prognostic significance of microbleeds in regular antiplatelet users are warranted.

Antiplatelet agents, especially aspirin, are widely used for the primary and secondary prevention of ischaemic stroke (IS) and cardiovascular diseases. Intracerebral haemorrhage (ICH) is an uncommon but often fatal or disabling complication of long term antiplatelet use,[1,2] for which effective treatment remains limited. A meta-analysis of 16 randomized, placebo-controlled clinical trials showed that treatment with aspirin was associated with a relative risk of haemorrhagic stroke of 1.84 (p=0.001).[3] In patients at high cardiovascular risk the benefit of aspirin in preventing vascular events outweighs the risk of ICH.[2,4] However, in those with lower cardiovascular risk (e.g. healthy elderly individuals who take aspirin because of a widespread perception of overall benefit), the benefits of aspirin are minimal [5] and could be offset by even a small increase in the risk of ICH.[3,6] A clinical decision about the use of antiplatelet treatment must weigh the benefits of treatment against the risks, including ICH. If patients at high risk of ICH could be identified prior to treatment they could potentially be spared this potentially devastating hazard. This is especially important since the increasing use of anticoagulants and antiplatelet drugs in an ageing population has led to a dramatic increase in antithrombotic-related ICH in the past two decades.[7]

Clinical factors associated with an increased ICH risk during anticoagulation include age, previous stroke and severe hypertension.[2] Brain imaging studies using computed tomography (CT) suggest that leukoaraiosis is a risk factor for ICH in patients taking Warfarin (RR~7),[8,9] but there have been few studies of imaging risk factors for aspirin-related ICH. Microbleeds detected on magnetic resonance imaging (MRI) of the brain are considered a biomarker of bleeding-prone small vessel diseases (in particular hypertensive small vessel arteriopathy and cerebral amyloid angiopathy [CAA]), and several studies in stroke patients suggest that they increase

the future risk of ICH.[10,11] They are very common in patients with stroke or TIA[12] and in healthy elderly individuals (up to 40%).[13] Recent studies have suggested an association between microbleeds and antiplatelet use,[14] and between microbleeds and the risk of antithrombotic-related ICH with a dose-dependent effect.[15] In patients with CAA, this risk could be particularly high, especially in the elderly.[7] Since CAA is radiologically characterised by microbleeds in a lobar distribution in the brain,[13] we hypothesized that brain microbleeds – especially lobar - are associated with antiplatelet-related ICH. We used a case-control study design to compare microbleed prevalence and distribution in antiplatelet users with symptomatic ICH compared with matched ICH-free antiplatelet users. Because microbleeds are known to be associated with ICH regardless of antiplatelet use, we also conducted a case-case comparison study between antiplatelet users with ICH and patients with spontaneous ICH unrelated to antiplatelets.

METHODS

Subjects

We studied a population of 1017 unselected consecutive patients referred to the Stroke Unit and associated neurovascular clinics at the National Hospital for Neurology and Neurosurgery (NHNN) from December 2000 to February 2008. The Stroke Unit takes all suspected stroke patients admitted from the surrounding district and has a policy of performing MRI with GRE T2* sequence in all patients with ICH and IS unless contra-indicated, allowing us to minimize selection bias. MRIs are performed within 5 days of admission or on the day of the clinic. All patients have standard questions including questions about antithrombotic use recorded onto a written proforma.

Cases were patients with spontaneous symptomatic ICH occurring whilst taking regular antiplatelet treatment. All patients with ICH were ascertained with overlapping methods including MRI images, reports and medical records. The intake and duration of antiplatelet treatment at the time of admission or visit was ascertained from hospital and GP records. For each antiplatelet user with ICH two controls matched for age, sex and hypertension and without any history of ICH were selected randomly (blinded to other clinical details or microbleed ratings) from prospective databases of consecutive patients admitted to the stroke unit and associated neurovascular clinics. Controls were patients using antiplatelet agents admitted to the department due to suspected ischaemic stroke or TIA.

We recorded the blood pressures taken at the time of admission or visit. Patients were considered hypertensive when they were on anti-hypertensive drugs or when their blood pressure was ≥140/90 for more than 7 days after admission. We compared baseline demographics, prevalence of leukoaraiosis and presence, number and distribution of microbleeds between cases and controls. We also performed a case-case comparison between antiplatelet users and non-antiplatelet users with ICH. The study received ethics approval by The NHNN & Institute of Neurology Joint Research Ethics Committee.

Imaging analysis

MRIs were carried at 1.5T field strength. GRE T2* sequences were obtained in the axial plane on a Genesis Signa Scanner [repetition time (TR) 300 milliseconds, echo time (TE) 40 milliseconds, flip angle (FA) 20°, FoV 24x18, matrix 256x160, slice thickness 5mm, slice gap 1.5mm, NEX 1]. A minority of patients was scanned on a Siemens Avanto Scanner [TR 800 milliseconds, TE 26 milliseconds, FA 20°, FoV

24x18, matrix 512x448, slice thickness 5mm, slice gap 1.5mm, NEX 1]. Microbleeds were identified by a neurologist trained in microbleed identification (SG) and blinded to all clinical information, who rated microbleed presence, number and distribution on GRE T2* images using the microbleed anatomical rating scale (MARS), a validated scale for microbleed reporting in all brain locations.[16] Leukoaraiosis was defined as the presence of early confluent or confluent white matter lesions, corresponding to a Wahlund score equal or above 2.[17] Lacunes were defined as brain infarcts measuring between 3 and 20mm in size and mostly present in the deep brain structures [18]. According to previous descriptions, they were characterized as being hypointense in T1-weighted and FLAIR images, and surrounded by a hyperintense rim in FLAIR images.[19,20] ICHs were classified as deep, lobar and posterior fossa. According to MARS, microbleed distribution was classified as deep, lobar and posterior fossa.

Statistical analysis

Blinded analysis of the data was performed with the Data Analysis and Statistical Software STATA Intercooled version 8.0 and the Statistical Package for the Social Sciences (SPSS) for Windows version 16.0. Conditional logistic regression analysis was used for the comparison of characteristics between the case group (antiplatelet users with ICH) and matched control group (antiplatelet users without ICH). A two-sided independent groups t-test was used for variables that are normally distributed in each group, Fisher's exact test for comparison of proportions, and Mann–Whitney U test for comparison of variables that are not normally distributed in at least one of the two groups. We investigated the effects of the number of microbleeds in predicting antiplatelet-related ICH, with adjustment for leukoaraiosis. For the case-case comparison study, we used two-sided independent t-test, Fisher's exact tests

and non parametric Mann-Whitney U tests to compare demographics and radiological features between the two groups. Statistical significance was declared if $p<0.05$.

RESULTS

Demographics

We identified a total of 164 subjects (N=16%) with ICH admitted during the study period. Of these we excluded patients with structural and secondary causes of ICH (aneurysms, tumours, cavernomas, arterio-venous malformations, coagulation disorders or use of oral anticoagulants, venous thrombosis or head injuries) (N=69). We then excluded patients in whom the MRI images were not of satisfactory quality (N=3), did not include a GRE T2* sequence (N=8) or were not performed (N=35). Of the remaining 49 patients (30%), we identified 16 cases (patients on regular antiplatelet therapy) and 33 non antiplatelet users with ICH (Figure 1). Patients included in the study were slightly older than patients excluded due to lack of MRI (p=0.043). However, there was no significant difference between the 2 groups for any of the other vascular risk factors: hypertension, systolic blood pressure, diastolic blood pressure, statin use, median cholesterol total, smoking history, diabetes, previous history of stroke, history of atrial fibrillation, ischaemic heart disease and antithrombotic use. The proportion of patients scanned on the Siemens Avanto scanner was small: antiplatelet-related ICH (N=1, 6%), controls (N=2, 6%), nonantiplatelet-related ICH (N=3, 9%).

We selected 32 matched controls from the database of antiplatelet users without ICH. Cases and controls were well matched for all clinical characteristics and potential confounding factors including previous history of IS, ischaemic heart

disease, lacunar infarcts, median dose of aspirin and duration on antiplatelets (Table 1). Antiplatelet agents used by patients and controls were: aspirin (N=43), clopidogrel (N=3), aspirin plus dipyridamole (N=1), or clopidogrel plus aspirin (N=1).

Table 1 Characteristics of antiplatelet users with and without history of ICH

	With ICH (N=16)	**Without ICH (N=32)**	**P value**
Clinical characteristics†			
Mean age in yrs (range)	70+/-10.5 (52-86)	67.25+/-9.9 (53-94)	*NS*
Men, N (%)	10 (62.5)	20 (62.5)	*NS*
Hypertension (%)	12 (75)	24 (75)	*NS*
Systolic blood pressure (mmHg)	165+/-26	154.85+/-25	*NS*
Diastolic blood pressure (mmHg)	87+/-12	81.5+/-15.51	*NS*
Diabetes (%)	4 (25)	7 (22)	*NS*
Cholesterol total >6mmol/L (%)	1 (6)	3 (9)	*NS*
Statin use (%)	5 (31)	14 (52)	*NS*
Ischaemic heart disease (%)	6 (37.5)	13 (40.6)	*NS*
Atrial fibrillation (%)	2 (12.5)	6 (18.7)	*NS*
Previous stroke (%)	8 (50)	16 (50)	*NS*
Smoking (%)	10 (62.5)	17 (53)	*NS*
Duration, months (%)	41.6+/-48.4	37.7+/-43.4	*NS*
Number taking aspirin (%)	15 (94)	30 (94)	*NS*
Median dose of aspirin in aspirin users in mg (range)	75 (75-300)	75 (75)	*NS*
Median interval stroke-MRI in days (range)	11 (2-115)	17 (0-131)	*NS*
Imaging characteristics			
Microbleeds			
Presence (%, range)	13 (81.2, 0-28)	6 (18.8, 0-15)	0.004*
Median (range)	6.0 (0-28)	0 (0-15)	0.016*
Lobar			
Presence (%)	11 (69)	5 (15.6)	0.004*
Median (range)	3.0 (0-15)	0 (0-8)	0.016*
Deep (basal ganglia and thalamus)			
Presence (%)	9 (56.2)	3 (9.4)	<0.001*
Median (range)	1.0 (0-11)	0 (0-3)	NS
Posterior fossa (brainstem and cerebellum)			
Presence (%)	6 (37.5)	4 (12.5)	*NS*
Median (range)	0 (0-2)	0 (0-5)	*NS*
Lacunes			
Presence (%)	12 (80)	27 (84)	*NS*
Median (range)	2.0 (0-9)	2.5 (0-10)	*NS*
Leukoaraiosis			
Presence (%)	8 (50)	7 (22)	*NS*

NS: not significant; IQ range: interquartile range

*p<0.05

† Plus–minus values are means+/-SD

Among patients with ICH related and unrelated to antiplatelet agents, the groups were similar for most clinical characteristics (Table 2), but as expected, previous ischaemic heart disease and stroke were more prevalent among antiplatelet than nonantiplatelet users (p=0.003 and <0.001).

Table 2 Characteristics of subjects with symptomatic spontaneous ICH

	Antiplatelet users (N=16)	**Non-antiplatelet users (N=33)**	**P value**
Clinical characteristics†			
Mean age in yrs (range)	70+/-10.5 (52-86)	66+/-10.6 (41-87)	*NS*
Men, N (%)	10 (62.5)	18 (54.5)	*NS*
Hypertension (%)	12 (75)	27 (81.8)	*NS*
Systolic blood pressure (mmHg)	165+/-26	151+/-32	*NS*
Diastolic blood pressure (mmHg)	87+/-12	83+/-16	*NS*
Diabetes (%)	4 (25)	2 (6.1)	*NS*
Cholesterol total >6mmol/L (%)	1 (6)	2 (6)	*NS*
Statin use (%)	5 (31)	4 (13)	*NS*
Ischaemic heart disease (%)	6 (37.5)	1 (3)	0.003*
Atrial fibrillation (%)	2 (12.5)	3 (9.1)	*NS*
Previous stroke (%)	8 (50)	2 (6.1)	<0.001*
Smoking (%)	10 (62.5)	10 (30.3)	*NS*
Median interval stroke-MRI in days (range)	11 (2-115)	7 (0-222)	*NS*
Imaging characteristics			
Microbleeds			
Presence (%, range)	13 (81.2, 0-28)	15 (45.4, 0-31)	0.030*
Median (range)	6.0 (0-28)	0.0 (0-31)	0.012*
Lobar			
Presence (%)	11 (69)	11 (33)	0.032*
Median (range)	3.0 (0-15)	0 (0-12)	0.016*
Deep (basal ganglia and thalamus)			
Presence (%)	9 (56.2)	9 (27.3)	*NS*
Median (range)	1.0 (0-11)	0 (0-17)	0.032*
Posterior fossa (brainstem and cerebellum)			
Presence (%)	6 (37.5)	5 (15)	*NS*
Median (range)	0 (0-2)	0 (0-8)	*NS*
Lacunes			
Presence (%)	12 (80)	24 (75)	*NS*
Median (range)	2.0 (0-9)	2.0 (0-7)	*NS*
Leukoaraiosis			
Presence (%)	8 (50)	8 (24)	*NS*

NS: not significant; IQ range: interquartile range

*p<0.05

† Plus–minus values are means+/-SD

Incidence and location of ICHs

The majority of subjects had single ICHs (N=14 [87.5%] and N=28 [85%] in antiplatelet users and non antiplatelet users). The ICHs were most often located in the cerebral lobes (Table 2). Multiple acute ICHs were seen in 2 antiplatelet users (12%) and 5 nonantiplatelet users (18%). Two patients had prior ICH, one on long-term antiplatelet therapy (6%) and one nonantiplatelet user (3%). Example GRE T2* images of an antiplatelet user who developed two acute lobar haemorrhages are shown in Figure 2.

Comparison between cases and controls

Thirteen (81.2%) antiplatelet users with symptomatic ICH had microbleeds compared to 6 (18.8%) antiplatelet users without any history of ICH (p=0.004) (Table 1). Microbleeds were more numerous in subjects with ICH compared to controls (median: 6.0, range 0-28, vs median: 0, range 0-15; p=0.016). In both groups, microbleeds were most common in the lobes than in the deep or posterior fossa regions. The prevalence of leukoaraiosis was higher in antiplatelet users with ICH compared to controls (50% vs 22%, p=0.069).

Factors associated with the risk of antiplatelet-related ICH

In a conditional logistic regression, the total number of microbleeds was a significant predictor of antiplatelet-related ICH (OR 1.27, 95%CI 1.04-1.55, p=0.016), even after adjusting for the presence of leukoaraiosis (OR 1.33, 95% CI 1.06-1.66, p=0.013) (Table 3). Lobar microbleeds were significantly associated with antiplatelet-related ICH after adjusting for the presence of leukoaraiosis (OR 1.42, 95%CI 1.07-1.89,

p=0.016) whereas deep microbleeds were not (OR 5.69, 95%CI 0.95-34.22, p=0.057). However, the OR for the association between antiplatelet-related ICH and deep microbleeds was greater than that of lobar microbleeds (albeit with wide confidence intervals), and approached statistical significance.

Table 3 Logistic regression analyses testing the factors predicting the likelihood of ICH in antiplatelet users with ICH and antiplatelet users without ICH matched for age, sex and hypertension

	Odds Ratio	95% CI for OR	P value
Presence and number of microbleeds			
Total number of microbleeds	1.27	1.04-1.55	0.016*
Total number of microbleeds adjusted for leukoaraiosis	1.33	1.06-1.66	0.013*
Distribution of microbleeds			
Number of Lobar microbleeds	1.35	1.06-1.72	0.016*
Number of Lobar microbleeds adjusted for leukoaraiosis	1.42	1.07-1.89	0.016*
Number of Deep microbleeds	5.86	0.96-35.69	0.055
Number of Deep microbleeds adjusted for leukoaraiosis	5.69	0.95-34.22	0.057

*p<0.05

Comparison between cases of ICH differing in the use of antiplatelets

Microbleeds were more frequent in antiplatelet users with ICH compared to patients with non-antiplatelet-related ICH (13/16 [81.2%] versus 15/33 [45.4%]; p=0.030). Microbleeds were more numerous in antiplatelet users (range 0-28, median 6.0 versus range 0-31, median 0; p=0.012) and lobar microbleeds more prevalent (69% versus 33%, p=0.032). Both deep and lobar microbleeds were more numerous in antiplatelet users than in nonantiplatelet users (p=0.032 for deep and p=0.016 for lobar microbleeds). Finally, leukoaraiosis was more prevalent in antiplatelet users with ICH compared to subjects with ICH unrelated to antiplatelets, but the difference was not statistically significant (50% vs 24%, p=0.106).

DISCUSSION

In this case-control study we found that microbleeds were more prevalent and numerous in antiplatelet users who developed symptomatic ICH compared to matched antiplatelet-users who did not develop ICH. The microbleed number was strongly associated with ICH risk even after controlling for the presence of leukoaraiosis and other potential confounding factors. Our study suggests that the association of ICH with microbleeds may be more powerful than that with leukoaraiosis, although microbleeds and leukoaraiosis may reflect similar pathological damage to small vessels.[20] In separate regression analyses adjusted for the presence of leukoaraiosis, lobar (but not deep) microbleeds were a statistically significant predictor of antiplatelet-related ICH. These data support a potential role for brain microbleeds, particularly in a lobar distribution, as a risk factor for antiplatelet-associated ICH.

We have confirmed previous observations of a predominance of lobar microbleeds in patients with ICH;[21,22] we also found that lobar microbleeds were more common in antiplatelet-associated ICH than in ICH unrelated to antiplatelet agents ($p=0.032$). Moreover, regression analyses indicated that lobar microbleeds were significantly associated with antiplatelet-related ICH. These observations suggest that lobar microbleeds may be more strongly related to antiplatelet-related bleeding than deep microbleeds, although our sample size is too small to confirm this hypothesis, which requires confirmation in larger studies. Previous autopsy and MRI studies suggest that lobar microbleeds are related to CAA.[23,24] In CAA, amyloid β-protein is deposited in the walls of superficial cortical and leptomeningeal vessels, causing them to become brittle and prone to bleeding. CAA may account for a large proportion of spontaneous ICH in the elderly[25] and has been suggested as a risk

factor for ICH associated with warfarin,[24] and aspirin,[25] as well as with ICH after thrombolysis for IS.[26] Our data are consistent with the hypothesis that CAA is an important risk factor for ICH related to antiplatelet use, and suggest that patients with clinical and imaging findings suggestive of CAA should be treated with antiplatelet agents only if there are compelling reasons to treat to reduce their overall risk of ischaemic vascular events.

Very few previous studies have investigated the association between microbleeds and antiplatelet-associated haemorrhage.[27,28] Moreover, these were in Chinese patients in whom hypertension and microbleeds are more common than in Europeans, so may not be generalizable to all stroke populations. Nevertheless, Wong et al found microbleeds in 19 of 21 aspirin users with symptomatic ICH, compared to 7 of 21 matched aspirin users without ICH, a result consistent with our findings. In contrast with our study, no cases of ICH unrelated to aspirin were included, and no adjustment was made for the presence of leukoaraiosis, a potentially important confounding factor. A recent randomized trial comparing the new antiplatelet drug cilostazol to aspirin found that in the 6 patients who developed ICH, all had previous microbleeds in the location of the ICH;[28] this observation is also consistent with the hypothesis that microbleeds could be used to identify patients at the highest risk of antiplatelet-associated ICH, but the small number of outcome events makes it difficult to draw firm conclusions.

Our study has a number of methodological strengths. First, our data were prospectively collected, with standardized clinical data and MRI imaging sequences; because of our policy of performing routine GRE MRI on all patients unless contra-indicated, we were able to minimize selection bias. Second, we used a case-control

design, which is the most powerful way to identify risk factors for rare outcome events. Given the very low absolute risk of antiplatelet-associated ICH (about 0.1-0.2% per year), prospective studies would require large number of patients and long follow-ups: indeed, the few prospective studies so far available failed to reach definite conclusions because of small sample sizes and low statistical power.[20,29,30] Third, we were able to specifically investigate the independent effect of microbleeds on ICH risk because important known confounding factors (age, sex, hypertension, duration on antiplatelets, previous history of stroke and presence of leukoaraiosis) were controlled for in the matching process and logistic regression analysis. We adjusted for leukoaraiosis which is a risk factor for warfarin-associated ICH and is associated with microbleeds.[8,9,21,31,32] Fourth, we used a reliable anatomical microbleed rating scale with good intra- and inter-observer agreement.[16] Finally, we included patients with ICH unrelated to antiplatelet treatment, ascertained from the same population as our main case group, making it less likely that our finding is confounded by the well-described association of microbleeds with ICH overall. However, in this case-case ICH comparison, a greater proportion of patients with ICH taking antiplatelet agents had a history of previous ischaemic stroke, which could contribute to the higher microbleed prevalence in this group.

The main limitations of our study include the small cohort and retrospective design. We obtained large confidence intervals in the estimation of ICH risk for the number of deep microbleeds, likely to be due to the small number of deep microbleeds in our cohort overall. We could only include patients who had MRI, which biased the study towards including slightly older cases of ICH. Our overall prevalence of microbleeds could therefore overestimated, but this should not affect the case-control and case-

case comparisons that we have reported. Another limitation comes from the fact that our “controls” presented with non-ICH stroke symptoms, and therefore were not “true” controls. However, this should not have biased our study towards positive results as our controls are likely to have more microbleeds than “true” controls. Finally, like all case-control studies, ours can only provide evidence of an association between microbleeds and antiplatelet-related ICH, and not that microbleeds are causally associated. For these reasons, our results need to be confirmed in other prospective studies.

In summary, we have demonstrated a strong independent association between brain microbleeds and antiplatelet-related ICH. The predominance of lobar microbleeds in patients on antiplatelets who develop an ICH suggests that CAA may be an important underlying risk factor for ICH in patients taking antiplatelets. Our findings suggest that patients with numerous microbleeds, particularly in a lobar distribution, may be at higher risk of ICH, which could outweigh the benefits of antiplatelet therapy in these patients.[15] Therefore, microbleed screening may be an important component in the design of future antiplatelet trials. Large prospective studies and systematic analyses are needed to further clarify the risks and benefits of antiplatelet therapy in patients with microbleeds.

Ackowledgements

We thank Adrienne Wallis and Helen Green from the Lysholm Department of Neuroradiology for their help with retrieving the MRIs from the store and restoring some of them to the work stations. Our thanks also go to Teresa Feeney from the stroke unit for giving access to the clinical data. The imaging was conducted at the Lysholm Department of Neuroradiology of the National Hospital for Neurology and Neurosurgery. The study was sponsored by the University College London Hospitals NHS Foundation Trust (project ID 07/N020).

Competing interests

Dr Jäger serves as a consultant to Biogen Idec and GlaxoSmithKline. Dr Yousry served on a scientific advisory board for UCB and serves on the editorial board of European Radiology. Dr Brown serves as a Section Editor for Stroke; serves as a consultant to Pfizer Inc. and AGA Medical Corporation and serves on a Data and Ethics Monitoring Committee for Bayer Schering Pharma.

Funding

Dr Gregoire receives research support from the Stroke Association. Dr Jäger has received research support from the Samantha Dickson Brain Tumour Trust and the Brain Research Trust. Professor Brown receives support from the Reta Lila Weston Trust for Medical Research (supports him as Chair in Stroke Medicine). Dr Werring receives research support from the Department of Health/Higher Education Funding Council for England (Clinical Senior Lectureship Award) and the Stroke Association. This work was undertaken at UCLH/UCL who received a proportion of funding from the Department of Health's NIHR Biomedical Research Centres funding scheme.

Ethics approval: The study was approved by the Joint Institute of Neurology and National Hospital for Neurology and Neurosurgery Research Ethics Committee

Contributors

SMG was responsible for the data acquisition, analyses, interpretation and writing of the manuscript. DJW and SMG contributed to the conception and design of the study. DJW also contributed to the data analysis, interpretation and review of the manuscript and supervised the whole project. HRJ helped with the review of the manuscript. TAY provided useful feedback on the manuscript. CK, statistician at the London School of Hygiene and Tropical Medicine was responsible for the statistics. All authors revised and approved the final version of the manuscript.

Licence for Publication

The Corresponding Author has the right to grant on behalf of all authors and does grant on behalf of all authors, an exclusive licence (or non exclusive for government employees) on a worldwide basis to the BMJ Publishing Group Ltd to permit this article (if accepted) to be published in PMJ and any other BMJPGL products and sublicences such use and exploit all subsidiary rights, as set out in our licence.

References

1. **Saloheimo P**, Ahonen M, Juvela S, *et al*. Regular aspirin-use preceding the onset of primary intracerebral hemorrhage is an independent predictor for death. *Stroke* 2006;**37**:129-33.
2. **Hart RG**, Tonarelli SB, Pearce LA. Avoiding central nervous system bleeding during antithrombotic therapy. Recent data and ideas. *Stroke* 2005;**36**:1588-93.
3. **He J**, Whelton PK, Vu B, *et al*. Aspirin and risk of hemorrhagic stroke: a meta-analysis of randomized controlled trials. *JAMA* 1998;**280**:1930-5.
4. **Gorelick PB**, Weisman SM. Risk of hemorrhagic stroke with aspirin use. An update. *Stroke* 2005;**36**:1801-7.
5. **Antithrombotic Trialists' (ATT) Collaboration.** Aspirin in the primary prevention and secondary prevention of vascular disease: collaborative meta-analysis of individual participant data from randomised trials. *Lancet* 2009;**373**:1849-60.
6. **Kronmal RA**, Hart RG, Manolio TA, *et al*; CHS Collaborative Research Group. Aspirin use and incident stroke in the cardiovascular health study. CHS Collaborative Research Group. *Stroke* 1998;**29**:887-94.
7. **Flaherty ML**, Kissela B, Woo D, *et al*. The increasing incidence of anticoagulant-associated intracerebral hemorrhage. *Neurology* 2007;**68**:116-21.
8. **Algra A**, Gorter JW, Kappelle LJ, *et al;* Stroke Prevention in Reversible Ischemia Trial (SPIRIT) Study group. A randomized trial of anticoagulants

versus aspirin after cerebral ischemia of presumed arterial origin. *Ann Neurol* 1997;**42**:857-65.

9. **Smith EE**, Rosand J, Knudsen KA, *et al*. Leukoaraiosis is associated with Warfarin-related hemorrhage following ischemic stroke. *Neurology* 2002;**59**:193-7.
10. **Greenberg SM**, Eng JA, Ning M, *et al*. Hemorrhage burden predicts recurrent intracerebral hemorrhage after lobar hemorrhage. *Stroke* 2004;**35**:1415-20.
11. **Jeon SB**, Kang DW, Cho AH, *et al*. Initial microbleeds at MR imaging can predict recurrent intracerebral hemorrhage. *J Neurol* 2007;**254**:508-12.
12. **Werring DJ**, Coward LJ, Losseff NA, *et al*. Cerebral microbleeds are common in ischemic stroke but rare in TIA. *Neurology* 2005;**65**:1914-8.
13. **Vernooij MW**, van der Lugt A, Ikram MA, *et al*. Prevalence and risk factors of cerebral microbleeds: The Rotterdam Scan Study. *Neurology* 2008;**70**:1208-14.
14. **Vernooij MW**, Haag MD, van der Lugt A, *et al*. Use of antithrombotic drugs and the presence of cerebral microbleeds. The Rotterdam Scan Study. *Arch Neurol* 2009;**66**:714-20.
15. **Soo YO**, Yang SR, Lam WW, *et al*. Risk vs benefit of anti-thrombotic therapy in ischaemic stroke patients with cerebral microbleeds. *J Neurol* 2008;**255**:1679-86.
16. **Gregoire SM**, Chaudhary UJ, Jäger HR, *et al*. The Microbleed Anatomical Rating Scale (MARS): reliability of a tool to map brain microbleeds. *Neurology* 2009, in press.
17. **Wahlund LO**, Barkhof F, Fazekas F, *et al;* European Task Force on Age-Related White Matter Changes. A new rating scale for age-related white matter changes applicable to MRI and CT. *Stroke* 2001;**32**:1318-22.

18. **Bryan RN**, Cai J, Burke G, *et al*. Prevalence and anatomic characteristics of infarct-like lesions on MR images of middle-aged adults: the Atherosclerosis Risk in Communities Study. *AJNR Am J Neuroradiol* 1999;**20**:1273-80.
19. **Kwon HM**, Kim BJ, Lee SH, *et al*. Metabolic syndrome as independent risk factor for silent brain infarction in healthy people. *Stroke* 2006;**37**:466-70.
20. **Naka H**, Nomura E, Takahashi T, *et al*. Combinations of the presence or absence of cerebral microbleeds and advanced white matter hyperintensity as predictors of subsequent stroke subtypes. *AJNR Am J Neuroradiol* 2006;**27**:830-5.
21. **Roob G**, Lechner A, Schmidt R, *et al*. Frequency and location of microbleeds in patients with primary intracerebral hemorrhage. *Stroke* 2000;**31**:2665-9.
22. **Tsushima Y**, Aoki J and Endo K. Brain Microhemorrhages detected on T2*-Weighted Gradient-Echo MR images. *AJNR Am J Neuroradiol* 2003;**24**:88-96.
23. **Greenberg SM**. Cerebral amyloid angiopathy: prospects for clinical diagnosis and treatment. *Neurology* 1998;**51**:690-4.
24. **Rosand J**, Hylek EM, O'Donnell HC, *et al*. Warfarin-associated hemorrhage and cerebral amyloid angiopathy: a genetic and pathologic study. *Neurology* 2000;**55**:947-51.
25. **Wong KS**, Mok V, Lam WW, *et al*. Aspirin-associated intracerebral hemorrhage: clinical and radiologic features. *Neurology* 2000;**54**:2298-301.
26. **McCarron MO** and Nicoll JA. Cerebral amyloid angiopathy and thrombolysis-related Intracerebral haemorrhage. *Lancet Neurol* 2004;**3**:484-92.
27. **Wong KS**, Chan YL, Liu JY, *et al*. Asymptomatic microbleeds as a risk factor for aspirin-associated intracerebral hemorrhages. *Neurology* 2003;**60**:511-3.
28. **Huang Y**, Cheng Y, Wu J, *et al*; Cilostazol versus Aspirin for Secondary Ischaemic Stroke Prevention cooperation investigators. Cilostazol as an

alternative to aspirin after ischaemic stroke: a randomized, double-blind, pilot study. *Lancet Neurol* 2008;**7**:494-9.

29. **Fan YH**, Zhang L, Lam WW, *et al*. Cerebral Microbleeds as a risk factor for subsequent intracerebral haemorrhages among patients with acute ischaemic stroke. *Stroke* 2003;**34**:2459-62.
30. **Boulanger JM**, Coutts SB, Eliasziw M, *et al*; VISION Study Group. Cerebral microhemorrhages predict new disabling or fatal strokes in patients with acute ischaemic stroke or transient ischaemic attack. *Stroke* 2006;**37**:911-4.
31. **Diener HC**, Bogousslavsky J, Brass LM, *et al*; MATCH investigators. Aspirin and clopidogrel compared with clopidogrel alone after recent ischaemic stroke or transient ischemic attack in high-risk patients (MATCH): randomized, double-blind, placebo-controlled trial. *Lancet* 2004;**364**:331-7.
32. **Jeong SW**, Jung KH, Chu K, *et al*. Clinical and radiologic differences between primary intracerebral hemorrhage with and without microbleeds on gradient-echo magnetic resonance images. *Arch Neurol* 2004;**61**:905-9.

Figure legends

Figure 1. Patient flow diagram

Figure 2. GRE T2* MRI of an antiplatelet user who developed two lobar intracerebral haemorrhages

GRE T2*-weighted axial images of a patient with antiplatelet-related ICH demonstrating numerous lobar microbleeds (small white arrows) and three lobar haemorrhages (temporal left, parietal right, frontal right, large grey arrows). Cerebral amyloid angiopathy is likely to be the underlying cause of the microbleeds and multiple ICHs in this patient.

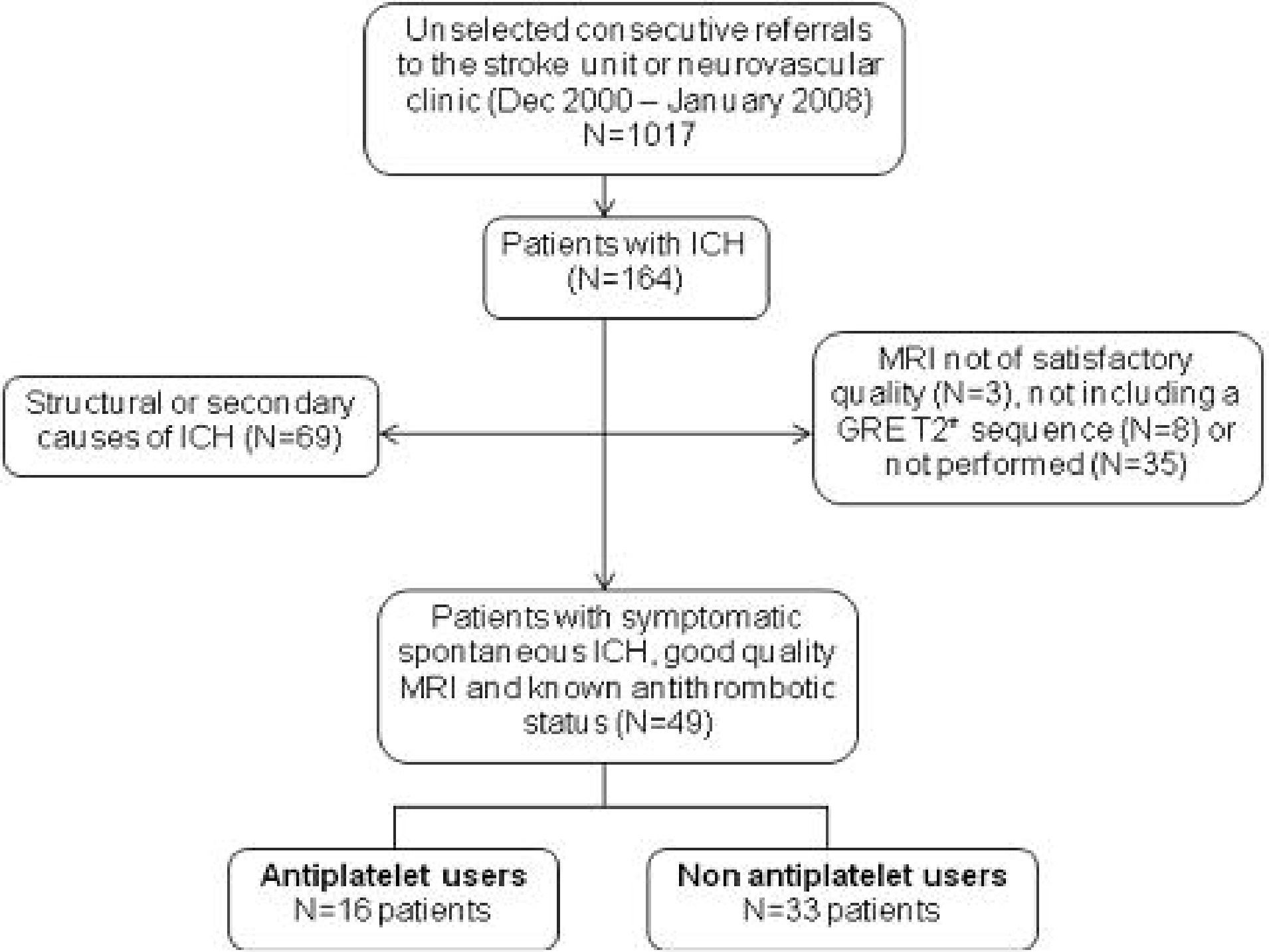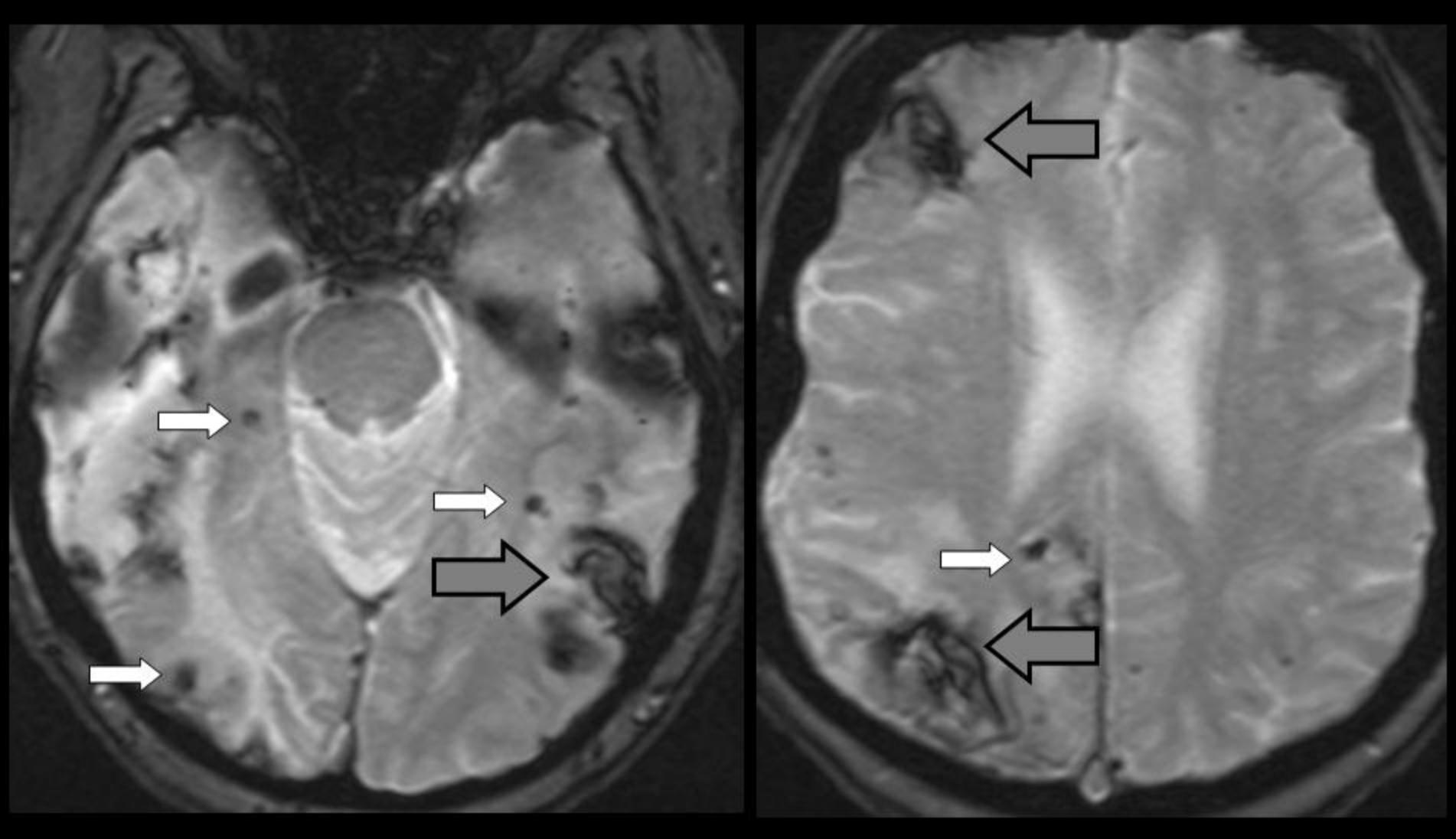
Unselected consecutive referrals to the stroke unit or neurovascular clinic (Dec 2000 – January 2008) N=1017
Patients with ICH (N=164)
Structural or secondary causes of ICH (N=69)
MRI not of satisfactory quality (N=3), not including a GRE T2* sequence (N=8) or not performed (N=35)
Patients with symptomatic spontaneous ICH, good quality MRI and known antithrombotic status (N=49)
Antiplatelet users N=16 patients
Non antiplatelet users N=33 patients