



HAL
open science

“Hemispheric asymmetry in the Meyer’s Loop” – a prospective study of visual field deficits in 105 cases undergoing anterior temporal lobe resection for epilepsy

Noor Ul Owase Jeelani, Panitha Jindahra, Mandeep S Tamber, Tak Lap Poon, Paul Kabasele, Merle James-Galton, John Stevens, John Duncan, Andrew W Mcevoy, William Harkness, et al.

► **To cite this version:**

Noor Ul Owase Jeelani, Panitha Jindahra, Mandeep S Tamber, Tak Lap Poon, Paul Kabasele, et al.. “Hemispheric asymmetry in the Meyer’s Loop” – a prospective study of visual field deficits in 105 cases undergoing anterior temporal lobe resection for epilepsy. *Journal of Neurology, Neurosurgery and Psychiatry*, 2010, 81 (9), pp.985. 10.1136/jnnp.2009.182378 . hal-00557406

HAL Id: hal-00557406

<https://hal.science/hal-00557406>

Submitted on 19 Jan 2011

HAL is a multi-disciplinary open access archive for the deposit and dissemination of scientific research documents, whether they are published or not. The documents may come from teaching and research institutions in France or abroad, or from public or private research centers.

L’archive ouverte pluridisciplinaire **HAL**, est destinée au dépôt et à la diffusion de documents scientifiques de niveau recherche, publiés ou non, émanant des établissements d’enseignement et de recherche français ou étrangers, des laboratoires publics ou privés.

“Hemispheric asymmetry in the Meyer’s Loop” – a prospective study of visual field deficits in 105 cases undergoing anterior temporal lobe resection for epilepsy

N u Owase Jeelani MBA, MPhil(Med. Law), FRCS (NeuroSurg) ¹
Panitha Jindahra MD, MRCP (UK) ²
Mandeep S Tamber MD, FRCSC ⁶
Tak Lap Poon FCS (HK), FHKAM (SURG), FRCS (SN) ³
Paul Kabasele MD ²
Merle James-Galton MA ²
John Stevens MD, FRCR ⁴
John Duncan MA DM FRCP FMedSci ⁵
Andrew W McEvoy MD, FRCS, FRCS(SN) ²
William Harkness MD, FRCS ¹
Gordon T Plant MA MD FRCP FRCOphth²

Departments of Neuro-ophthalmology², Neurosurgery³, Neuroradiology⁴ and Neurology⁵
The National Hospital For Neurology and Neurosurgery
Queen Square
London WC1N 3BG

Department of Neurosurgery ¹
Great Ormond Street Hospital
London WC1N 3JH

Department of Neurosurgery⁶
Hospital for Sick Children
555 University Avenue
Toronto, Canada
M5G 2R3

Address for correspondence:

Mr N u Owase Jeelani
Consultant Paediatric Neurosurgeon
Department of Neurosurgery
Great Ormond Street Hospital
London WC1N 3JH
Email: jeelan@gosh.nhs.uk
jeelan@mac.com

The authors did not receive any financial sources of support to undertake this study.

Licence for Publication:

The Corresponding Author has the right to grant on behalf of all authors and does grant on behalf of all authors, an exclusive licence (or non exclusive for government employees) on a worldwide basis to the BMJ Publishing Group Ltd to permit this article (if accepted) to be published in JNNP and any other BMJ PGL products and sublicences such use and exploit all subsidiary rights, as set out in our licence. (<http://group.bmj.com/products/journals/instructions-for-authors/licence-forms>)

Abstract

Objectives

Visual field deficits following temporal lobe surgery have been reported in the literature. In this prospective study, we analyse our experience of visual field deficits in 105 consecutive cases undergoing temporal lobe surgery performed by a single surgeon, with particular consideration to the laterality of the deficit and its functional implications.

Methods

105 consecutive patients undergoing an anterior temporal lobe resection for epilepsy, between March 1998 and June 2004 were selected. The patient population had a mean age of 35 years (range 19-60 years); 53 had a left-sided resection and 52 a right-sided resection. 91 patients had mesial temporal sclerosis, 3 gangliogliomas, 4 DNETs, 2 neurocytomas, 2 cavernomas and in 3 cases the histology was inconclusive.

Pre and post-operative visual field tests were obtained using the Humphrey Esterman binocular functional test for all cases. The test was set to stimulus white III, with a single intensity of 10 DB on the background of 31.5 ASB for all patients. A minimum follow-up period of 12 months post surgery was employed. Post-operative MRI scans were carried out on all patients. 60 scans were randomly selected and the extent of temporal lobe resection calculated manually for each.

Results

Of the 105 cases, 16 patients had a visual field deficit post operatively which was not present pre operatively; 12 following a left and 4 following a right-sided resection. The Odds Ratio for incurring a postoperative visual field defect following left vs. right-sided surgery was 3.51 (95% CI 1.05-11.73, $p=0.04$). In 4 patients the deficit was severe enough to preclude them from driving in the UK (3 left and 1 right sided resection). There was no association between the extent of tissue resection and the incidence of post-operative visual field deficits.

Conclusions

This study suggests left / right hemispheric asymmetry in the Geniculocalcarine tracts with field deficits being 3.5 times more likely following left sided anterior temporal lobe resections compared with right sided resections. This has significant implications on counselling patients for these procedures. MR tractography may provide an anatomical substrate for these clinical findings, perhaps revealing a more anterior course of the optic radiations within the temporal lobe in one hemisphere versus the other.

Key Words

Temporal lobe surgery, Meyer's loop, visual field deficits, hemispheric asymmetry.

Introduction

Visual field deficits (VFDs) as a complication of temporal lobe surgery are a well documented entity, with numerous publications over the decades reporting varying degrees of field deficits occurring in 50% to a 100% of such cases^{1,2,5,7-15,18,22,23} (see Table 1). The deficits are believed to be due to disruption of the proposed pathways of the optic radiations in the temporal lobes, the anterior portion of which is termed as the Meyer's loop.

It is well established that there is considerable inter-subject variability in the anatomy of the Meyer - Flechsig loop^{1,16,21}. Compounded with different surgical approaches employing varying degrees of neocortical resection and variations in the methods whereby visual fields are assessed has resulted in a wide discrepancy in the quoted incidence of this complication.

In this report we carried out a prospective study of 105 patients in our epilepsy programme undergoing an anterior temporal lobe resection between 1998 and 2004. Post-operative visual fields were compared with the preoperative studies and new deficits highlighted. These were correlated with the resection size on post-operative imaging. The incidence and functional implications of the VFDs in our series is presented, and we highlight, for the first time, hemispheric asymmetry with respect to the incidence of post-operative VFDs following temporal lobectomy for epilepsy.

Methods

A prospective study was designed to assess the incidence and functional implications of post-operative VFDs in patients undergoing temporal lobe surgery for epilepsy. The seizure outcome in this population is also documented.

105 consecutive cases undergoing surgery between March 1998 and June 2004 were selected. The mean age of patients was 35 years (range, 19-60 years). 53 had a left-sided resection and 52 a right-sided resection. 91 patients had mesial temporal sclerosis and 14 other lesions which were composed of 3 gangliogliomas, 4 DNETs, 2

neurocytomas, 2 cavernomas and in 3 the neuropathology was inconclusive. All the operations were carried out by a single right-handed surgeon (WH) employing the technique advocated by Spencer²⁰. The resection is performed in two stages; the lateral neocortical resection is stereotyped with the variation in resection size being primarily along the mesial structures. In all cases the temporal horn of the lateral ventricle is entered from below at the apex of the collateral sulcus, rather than perpendicular through the middle temporal gyrus. Subpial dissection is used for resection of the superior temporal gyrus and about 4 cms of the neocortical is resected measured from the temporal tip. The uncus is cleared with the CUSA, the hippocampus dissected out and sent for histology, the length variable on a case per case basis. No fixed retraction is used. For the 14 lesional cases, the pathology was all incorporated within the standard resection.

Pre and post-operative visual field tests were obtained using the Esterman binocular protocol functional test for all cases carried out on a Humphrey visual field analyser model 611 (Allergan:California). The test was set to stimulus white III, with a single intensity of 10 dB on the background of 31.5 ASB for all patients. The test was chosen because of its use by the UK Driver and Vehicle Licensing Authority in assessing fitness to drive. All the field analyses were carried out by one experienced operator (MG) and reviewed by a neuro-ophthalmologist (GTP). If there was a concern regarding the accuracy of the fields assessed the test was carried out again on up to three different occasions and the best one employed. This is in line with the UK Driving and Vehicle Licensing Authority (DVLA) recommendations³. In cases with a single point loss in the relevant quadrant, the testing was repeated and if reproduced, this was categorised as a field deficit for the purposes of this study. A patients ability to drive was assessed in accordance with the criteria set out by the DVLA³.

The mean time interval between the pre-op assessment and the surgery was 6.4 months, ranging from 3 days to 47 months. The mean time interval between surgery and the post-op assessment was 5.4 months, ranging from 1 month to 54 months. Seizure status was assessed at 12 months post operatively, according to the Engel classification⁶.

Post-operative MRI scans were obtained on all patients. Of these, the first 60 scans with a diagnosis of hippocampal sclerosis retrieved randomly from the imaging archives were chosen for quantitative statistical analysis. This sample was checked for a chronological bias. There were an equal number of left and right-sided resections. The particular acquisitions used were the volumetric FSPGR IR prepped (Fast spoiled gradient IR prepped: slice thickness 1.5 mm) acquired in the coronal plane and the FLAIR (fluid attenuated inversion recovery: slice thickness 5 mm) also obtained in the coronal plane (Fig. 4). The mesial posterior resection limit was categorised utilising its relation to the adjacent pons; either as far as the anterior surface of the adjacent pons (4 cases), just behind the frontal pons (13 cases), at the mid-point of the pons (12 cases) or up to the posterior margin of the pons (32 cases). In this location, the position of the lateral geniculate body was noted. This method of quantifying resection size offered the best reproducibility and accounted for inter-patient variability in terms of head size. Most if not all of the amygdala was excised in these cases with a small residual noted in 20 of the 60 scans analysed. There was also a variable amount of signal change in the brain surrounding the resection. This was interpreted as mechanical damage with gliosis. Its extent was recorded qualitatively as absent (5 cases), mild (20 cases), moderate (20 cases) or severe (15 cases). For statistical analysis, the data was recoded in a binomial manner contrasting absent/mild changes with moderate/severe changes.

Statistical Analysis

Univariate logistic regression models were used to explore the relationship between post-operative VFDs (dependent variable) and certain key predictor variables that were hypothesized to have an influence of the incidence of such deficits following temporal lobe surgery for epilepsy. These variables included the side of resection, the presence and severity of post-operative signal change in the vicinity of the resection (as defined above), and the extent of resection in the randomly selected subset of 60 patients with hippocampal sclerosis. Multiple univariate models were constructed in order to assess if there was a relationship between the occurrence of post-operative VFDs and the posterior limit of the hippocampal resection (to the anterior, middle, or posterior surfaces of the pons), and whether or not the amygdala was taken. In this exploratory analysis, a

p value < 0.05 was used to declare statistical significance. All analyses were undertaken using Stata version 10.0 for Mac (StataCorp, College Station, Texas).

Results

Of the 105 cases, 16 patients (15.3%) had a visual field deficit post operatively (Fig 2b); 12 following a left temporal lobectomy and 4 following a right-sided resection (Fig.1). Whilst there was no statistical difference between the extent of mesial resection between the left and right-sided cases ($p=0.4$), there was a significant association between the laterality of the temporal lobe resection and the odds of manifesting a post-operative VFD (OR 3.51, 95% CI 1.05-11.73, $p=0.04$ for a deficit following a left sided temporal lobe resection). Preoperatively, a peripheral field loss was present in 1 patient who was undergoing treatment with Vigabatrin. This remained unchanged after the operation and she was included in the study. In 4 patients (3.8%) (Fig. 3) the deficit was severe enough to preclude them from driving in the UK³ (3 left and 1 right sided resection). The VFD did not extend to the lower quadrants in any patient.

There was no association between the extent of the mesial resection and the incidence of VFDs in this population of patients. We analyzed the signal change at the resection margins and again this was not associated with the incidence of VFDs.

78 patients (74.3%) achieved seizure freedom (Engle 1) at 12 months follow up. There was no association between the incidence of VFD and seizure outcome in our series. Three of the 4 patients with VFDs severe enough to preclude them from driving continued to have seizures resulting in one patient being prevented from driving solely due to their post operative visual loss.

Analysing the 91 (86.7%), mesial temporal sclerosis cases separately, 67 (73.6%) achieved seizure freedom. 14 patients (23.1%) had VFDs and 3 (3.3%) were unable to drive. The finding that VFDs were approximately 3.5x as common in left vs. right-sided resections remained robust (OR=3.52, 95%CI 1.01-12.21, $p=0.05$).

Figure 1: Bar graph comparing the incidence of VFDs in our patient population segregated by pathology

Figure 2a and 2b: Case 39

Figure 3a and 3b: Case 22

Figure 2a shows the pre-operative and Figure 2b the post-operative visual fields in a patient with a characteristic partial upper quadrantanopia “pie in the sky” defect following a left temporal lobectomy. This patient was able to retain their driving license.

Figure 3a and 3b shows the pre and post operative visual fields in whom the VFD precluded them from driving based on the DVLA guidelines.

Discussion

Numerous studies (including one from our unit)¹³ have previously analysed the anatomy of the optic radiations and the functional implications of damage to these during temporal lobe surgery^{1,2,4,7-12,14-16,18,21-23}. These studies have aimed to identify the anatomy of the optic radiations including the anterior extent of the Meyer's loop within the temporal lobe, the relationship of the optic radiation to the temporal horn of the lateral ventricle, the degree of inter-subject variability and any relationship between the size of surgical resection or different surgical techniques and the incidence of field deficits (see Table 1). The results of these studies have not always been consistent. Potential sources of bias have been a relatively small sample size, retrospective reviews, inter-observer and inter-surgical variability and different criteria being used for defining visual field deficits. In this study the authors attempted to rectify these biases by designing and conducting a prospective study. A follow-up from our original study published in 2000¹³, our aim here was to collate data on over 100 consecutive patients and perform preoperative visual fields on these patients to ensure any deficits identified postoperative were temporally related to the surgery. A single surgeon employed the same surgical technique in all the cases and the same operator carried out all pre and post-operative visual fields analyses. The Humphrey Esterman binocular functional test was employed as this is the standard used by the UK DVLA and offers better inter-observer reproducibility. In addition to intra-operative measurements, postoperative imaging was obtained in all cases and resection size was calculated for a random subset. With these measures, we attempted to identify factors that may predispose to the development of post-operative VFDs following a temporal lobe resection in our study population.

The literature poses considerable variation in the anterior limit of the Meyer's loop within the temporal lobe and its implications for post operative visual field deficits in temporal lobe surgery. Table 1 lists the recent literature on this subject to highlight the variation in the methodology and the resultant variation in the quoted incidence. In 1954, Penfield stated that a resection within the anterior 60mm of the temporal tip would not produce a VFD¹⁸. Over the years this 'safe zone' has progressively been getting smaller. Falconer⁷ put the limit at 40 mm and Bjork² and his group to a value between 30 and 40 mm. In 1968, Marino and Rasmussen stated that defects occurred at resection sizes down to

40mm. These studies utilised intra operative estimation of resection lengths. More recent studies have analysed post-operative MRI to estimate resection sizes and have highlighted significant inter-subject variability. Krolak et al¹² using automatic static perimetry and post operative MRI analyses put the anterior most point of the Meyer's loop between 20 and 30 mm. Nilsson et al¹⁵ compartmentalised the temporal lobe on post operative MRI and correlating this with VFDs concluded that VFDs were present in certain cases when the superior temporal gyrus was involved between 18 – 36mm from the temporal pole. Another study carried out pathological dissections and put the mean value at 27mm (SD 3.5) with emphasis on inter subject variability⁴. Barton et al¹ correlated post operative MRI findings with VFDs and employing regression analyses put the anterior limit at 24mm for the nasal field and 28mm for the temporal field deficits. However as mentioned direct comparison's between these studies is problematic as different methodologies have been employed.

[Table 1:]

In our study, a maximal resection size of 45mm was employed in all patients, and resulted in a 15.3% incidence of VFDs. Our data concurs with the recent literature putting the Meyer's loop more anterior to 45mm. We however did not find a link between the size of resection and the incidence of VFDs. As stated, on post-operative MRI analyses the resections within the neocortex were stereotyped ranging between 40 and 45mm, with variation solely being in the volume of mesial structures resected. As the Meyer's loop is a white matter structure it is not surprising that a correlation between the extent of mesial resection and damage to it was not identified.

A VFD incidence of 15.3% is low compared to earlier series^{1,5,9,11-13,15,21,22}, including those employing similar assessments of post-operative visual deficits and of resection size. In addition to the above, the other manoeuvres that we feel may be responsible for this finding is the approach used to enter the temporal horn from below and the absence of any fixed retraction, those this cannot be proven with the current study design.

Tractography is likely to play a significant role in further elucidating the anatomic substrate for the findings demonstrated in this study. A recent study from our unit¹⁹ correlated a post-operative VFD with a disruption of the optic tract on DTI analyses.

Nilsson¹⁶ analysed the optic tracts in 7 healthy volunteers and 2 patients and confirmed the wide inter subject variability. More recently, Taoka²¹ and his group used pre surgical tractography in 14 patients undergoing temporal lobe resection for epilepsy. Their findings are interesting as they found an association between the incidence of the VFD and the size of disruption of the Meyer's loop but not one between the incidence of VFDs and the size of resection from the temporal tip. This study further highlights the difficulties in obtaining post-operative tractography using current paradigms. Though validation of diffusion tensor tractography remains a work in progress this technique does offers great promise in this field. Further studies are awaited.

Notwithstanding the variance in the reported incidence of VFDs in this patient population, a more pertinent question remains - what is the functional significance of this for any given patient? Egan et al⁵ documented a VFD incidence of over 80% in their study population but concluded that all of these deficits were asymptomatic. Ability to drive is one of the main reasons put forward by patients choosing to undergo temporal lobe surgery for epilepsy and this serves as an objective criteria to answer the above question, at least in the UK. In our series, out of the 16 cases with a VFD following surgery, in 4 cases (3.8%) the deficit was severe enough to preclude them from obtaining a driving license in the UK. This figure is considerably less than the 25% incidence quoted in our previous paper¹³ also using the Humphrey Analyser Esterman protocol, which analyse data between 1986 and 1995 or the 50% incidence quoted by another UK study analysing 14 patients¹⁷. The reduction in incidence of symptomatic VFDs is most likely to be due to the surgical technique as described and the cumulative caseload of our epilepsy service. The UK Driving and Vehicle Licensing Authority (DVLA) criteria³ are amongst the most stringent internationally and these patients may be able to drive in other countries. Though small, it is imperative that patients are advised about this potential risk before the surgery.

The question of hemispheric asymmetry in the anatomy of the optic radiations has been raised previously. In one study from 1976, Jensen and his colleagues¹⁰ found that larger field defects extending to the lower fields were more likely following a right sided resection; this was attributed to the larger resections on that side. More recent studies have reported a larger resection size on the right side but with no difference in the incidence of VFD^{1,9,22}. It is arguable that a difference in the resection size but not VFDs

in these studies alludes to a more anterior limit of the Meyer's loop on the left side. In a recent study, Yeni and his colleagues²³ analysed 30 patients with mesial temporal sclerosis for VFDs following temporal lobe surgery. It is interesting to note that although 10 of the 21 patients (47.6%) with left sided resections developed a VFD compared with just 1 of the 9 patients (11.1%) with right sided resection the authors did not find the hemispheric asymmetry statistically significant.

In our series we found we found VFDs to be 3.5 times more likely following left sided resections. The strength of the present study was a large cohort of patients operated on by a single surgeon who carries out similar neocortical resections on both sides. As the subject of a follow up study, we are currently employing diffusion tensor tractography to analyse this finding further. Why the Meyer's loop would be more anterior on the left side remains to be answered. One hypothesis proposed by the authors is that as the language areas in the left posterior temporal lobes expanded in humans the phylogenetically older optic radiation was pushed more anterior on that side.

Conclusion

Visual field deficits occur following anterior temporal lobe resections even when the resection size is less than 45mm. The incidence is low and in most cases these deficits do not carry any functional implications. In 4% of cases the deficits were severe enough to preclude the patient from driving in the UK. Patients need to be adequately counselled for this possibility. We found significant hemispheric asymmetry in the anatomy of the optic radiations, with field deficits being 3.5 times more likely following a left sided resection. This finding taken in conjunction with the greater functionality of the left lobe in most patients has led to the jocular remark "When it comes to temporal lobectomies, do what is right and think about what is left". Further information may come from Diffusion Tensor Imaging (tractography) studies performed prospectively pre- and post-operatively.

Bibliography

1. Barton JJ, Hefter R, Chang B, Schomer D, Drislane F: The field defects of anterior temporal lobectomy: a quantitative reassessment of Meyer's loop. **Brain** **128**:2123-2133, 2005
2. Bjork A, Kugelberg E: Visual field defects after temporal lobectomy. **Acta Ophthalmol (Copenh)** **35**:210-216, 1957
3. DVLA: At a glance Guide to the Current Medical Standards of Fitness to Drive, in (<http://www.dvla.gov.uk/medical/ataglance.aspx>) Swansea, 2009, p 42
4. Ebeling U, Reulen HJ: Neurosurgical topography of the optic radiation in the temporal lobe. **Acta Neurochir (Wien)** **92**:29-36, 1988
5. Egan RA, Shults WT, So N, Burchiel K, Kellogg JX, Salinsky M: Visual field deficits in conventional anterior temporal lobectomy versus amygdalohippocampectomy. **Neurology** **55**:1818-1822, 2000
6. Engel JJ, Ness PV, T R: Outcome with respect to epileptic seizures., in Jr EJ (ed): **Surgical Treatment of Epilpesies**. New York: Raven Press, 1993, Vol 2nd, pp 609-621
7. Falconer MA, Wilson JL: Visual field changes following anterior temporal lobectomy: their significance in relation to Meyer's loop of the optic radiation. **Brain** **81**:1-14, 1958
8. Guenot M, Krolak-Salmon P, Mertens P, Isnard J, Ryvlin P, Fischer C, et al: MRI assessment of the anatomy of optic radiations after temporal lobe epilepsy surgery. **Stereotact Funct Neurosurg** **73**:84-87, 1999
9. Hughes TS, Abou-Khalil B, Lavin PJ, Fakhoury T, Blumenkopf B, Donahue SP: Visual field defects after temporal lobe resection: a prospective quantitative analysis. **Neurology** **53**:167-172, 1999
10. Jensen I, Seedorff HH: Temporal lobe epilepsy and neuro-ophthalmology. Ophthalmological findings in 74 temporal lobe resected patients. **Acta Ophthalmol (Copenh)** **54**:827-841, 1976
11. Katz A, Awad IA, Kong AK, Chelune GJ, Naugle RI, Wyllie E, et al: Extent of resection in temporal lobectomy for epilepsy. II. Memory changes and neurologic complications. **Epilepsia** **30**:763-771, 1989
12. Krolak-Salmon P, Guenot M, Tiliket C, Isnard J, Sindou M, Mauguiere F, et al: Anatomy of optic nerve radiations as assessed by static perimetry and MRI after tailored temporal lobectomy. **Br J Ophthalmol** **84**:884-889, 2000
13. Manji H, Plant GT: Epilepsy surgery, visual fields, and driving: a study of the visual field criteria for driving in patients after temporal lobe epilepsy surgery with a comparison of Goldmann and Esterman perimetry. **J Neurol Neurosurg Psychiatry** **68**:80-82, 2000
14. Marino R, Jr., Rasmussen T: Visual field changes after temporal lobectomy in man. **Neurology** **18**:825-835, 1968
15. Nilsson D, Malmgren K, Rydenhag B, Frisen L: Visual field defects after temporal lobectomy -- comparing methods and analysing resection size. **Acta Neurol Scand** **110**:301-307, 2004

16. Nilsson D, Starck G, Ljungberg M, Ribbelin S, Jonsson L, Malmgren K, et al: Intersubject variability in the anterior extent of the optic radiation assessed by tractography. **Epilepsy Res** **77**:11-16, 2007
17. Pathak-Ray V, Ray A, Walters R, Hatfield R: Detection of visual field defects in patients after anterior temporal lobectomy for mesial temporal sclerosis-establishing eligibility to drive. **Eye** **16**:744-748, 2002
18. Penfield W: Temporal lobe epilepsy. **Br J Surg** **41**:337-343, 1954
19. Powell HW, Parker GJ, Alexander DC, Symms MR, Boulby PA, Wheeler-Kingshott CA, et al: MR tractography predicts visual field defects following temporal lobe resection. **Neurology** **65**:596-599, 2005
20. Spencer DD, Spencer SS, Mattson RH, Williamson PD, Novelly RA: Access to the posterior medial temporal lobe structures in the surgical treatment of temporal lobe epilepsy. **Neurosurgery** **15**:667-671, 1984
21. Taoka T, Sakamoto M, Nakagawa H, Nakase H, Iwasaki S, Takayama K, et al: Diffusion tensor tractography of the Meyer loop in cases of temporal lobe resection for temporal lobe epilepsy: correlation between postsurgical visual field defect and anterior limit of Meyer loop on tractography. **AJNR Am J Neuroradiol** **29**:1329-1334, 2008
22. Tecoma ES, Laxer KD, Barbaro NM, Plant GT: Frequency and characteristics of visual field deficits after surgery for mesial temporal sclerosis. **Neurology** **43**:1235-1238, 1993
23. Yeni SN, Tanriover N, Uyanik O, Ulu MO, Ozkara C, Karaagac N, et al: Visual field defects in selective amygdalohippocampectomy for hippocampal sclerosis: the fate of Meyer's loop during the transylvian approach to the temporal horn. **Neurosurgery** **63**:507-513; discussion 513-505, 2008

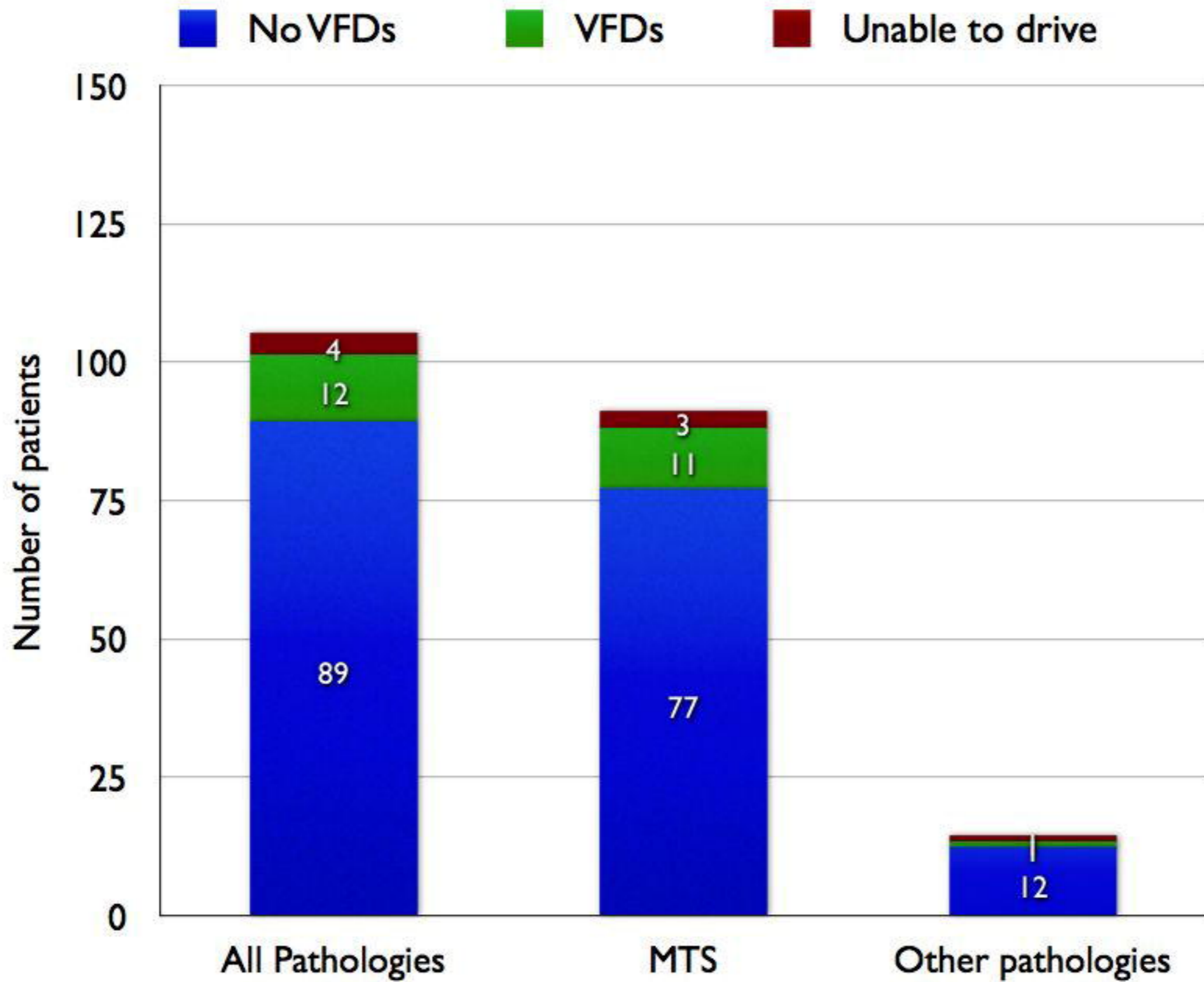
Figure 1: Bar graph comparing the incidence of VFDs in our patient population segregated by pathology

Figures 2a shows the pre-operative and Figure 2b the post-operative visual fields in a patient with a characteristic partial upper quadrantanopia “pie in the sky” defect following a left temporal lobectomy. This patient was able to retain their driving license.

Figure 3a and 3b shows the pre and post operative visual fields in whom the VFD precluded them from driving based on the DVLA guidelines.

Figure 4: (Case 73) Post operative volumetric FSPGR IR prepped (Fast spoiled gradient IR prepped: slice thickness 1.5 mm) coronal MRI images employed to calculate the extent of resection. In this case the mesial resection was taken as far back as the posterior border of the pons. Most of the amygdala has been excised as well. The signal change at the resection margins was classified as mild

Table 1: Recent literature comparing the incidence of VFDs following temporal lobe resection for epilepsy and the methodology used



INOCULAR

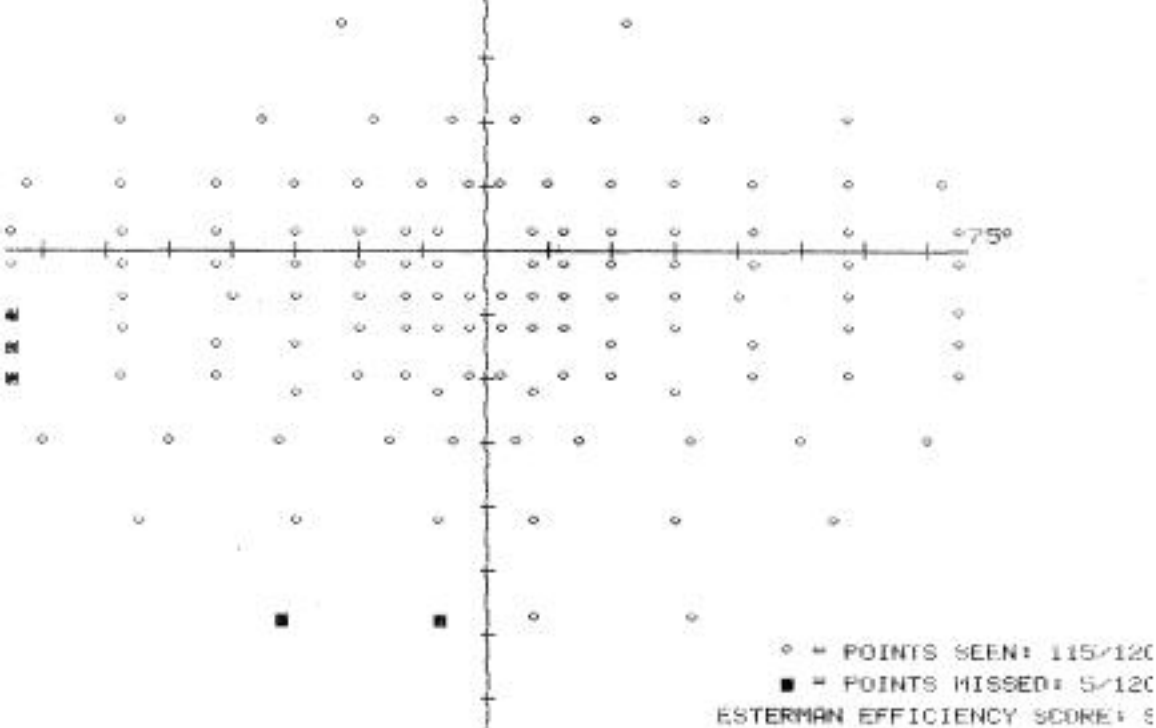
FIXATION LOSSES 0/0

FALSE POS ERRORS 0/9

FALSE NEG ERRORS 0/3

TEST TIME 00:05

HFA S/N 605-73



BINOCLAR

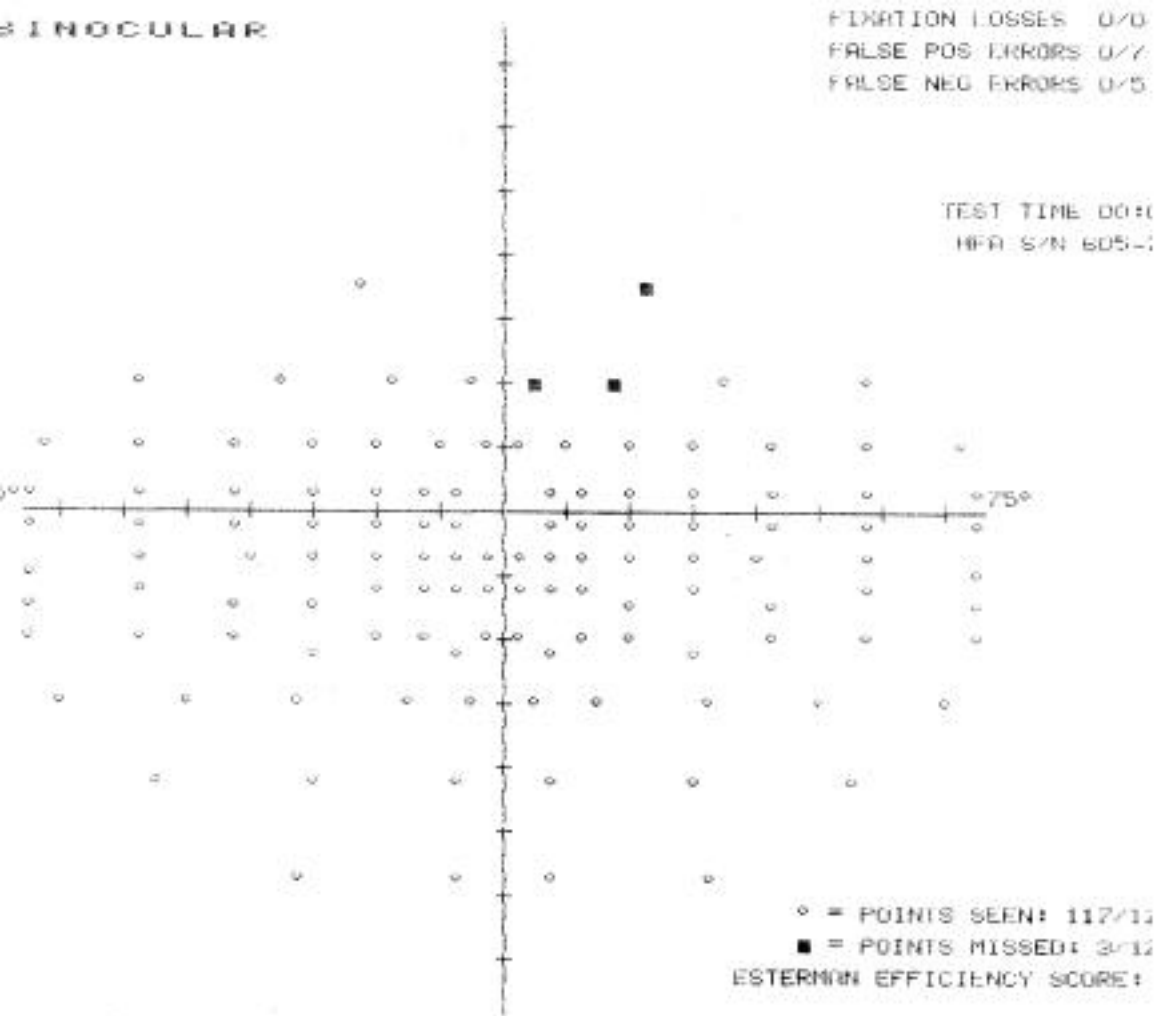
FIXATION LOSSES 0/0

FALSE POS ERRORS 0/7

FALSE NEG ERRORS 0/5

TEST TIME 00:0

HFA S/N 605-1



BINOCULAR

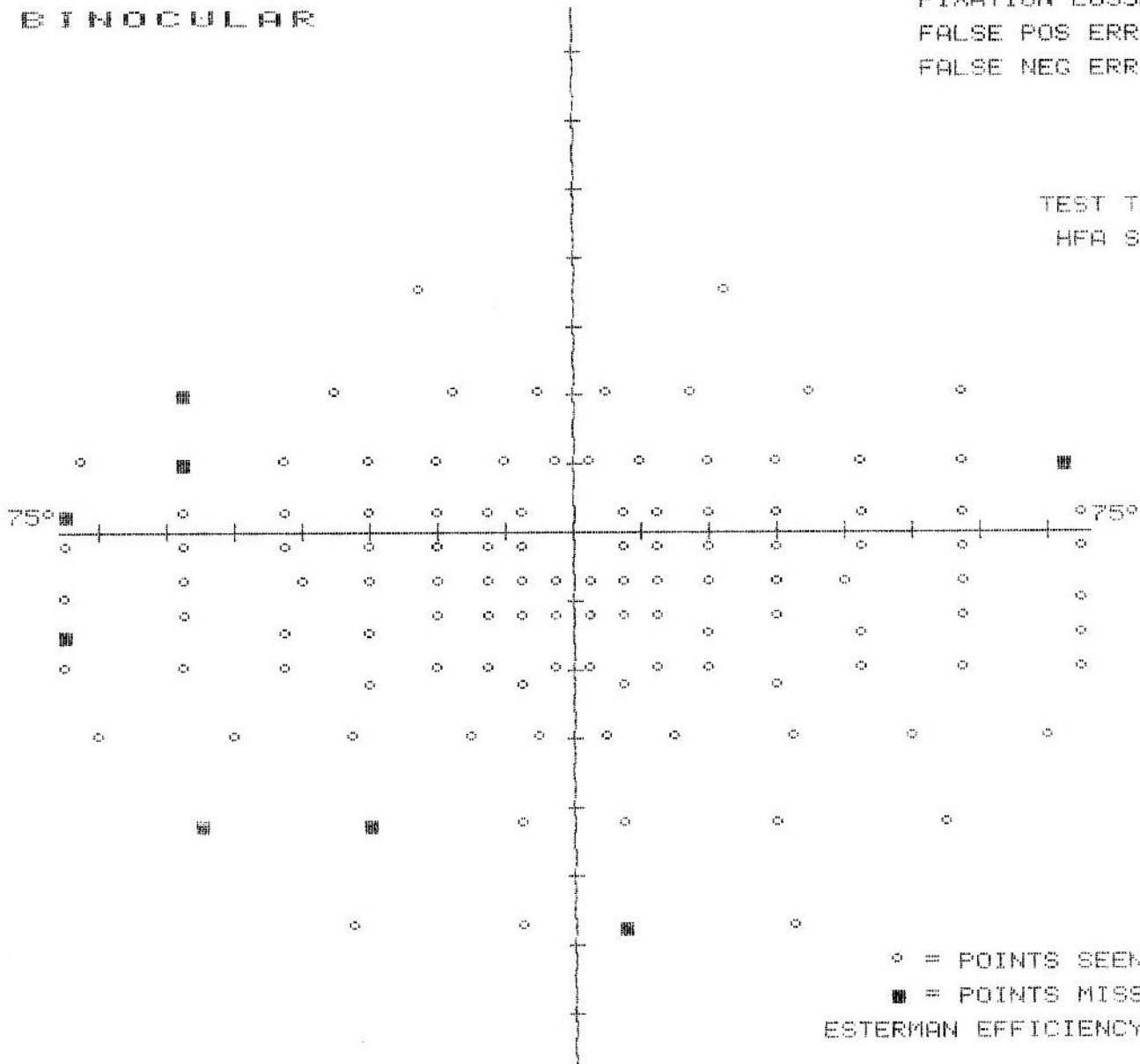
FIXATION LOSSES 0/0

FALSE POS ERRORS 0/9

FALSE NEG ERRORS 0/5

TEST TIME 00:05:

HFA S/N 605-739



○ = POINTS SEEN: 112/120

■ = POINTS MISSED: 8/120

ESTERMAN EFFICIENCY SCORE: 93

BINOCULAR

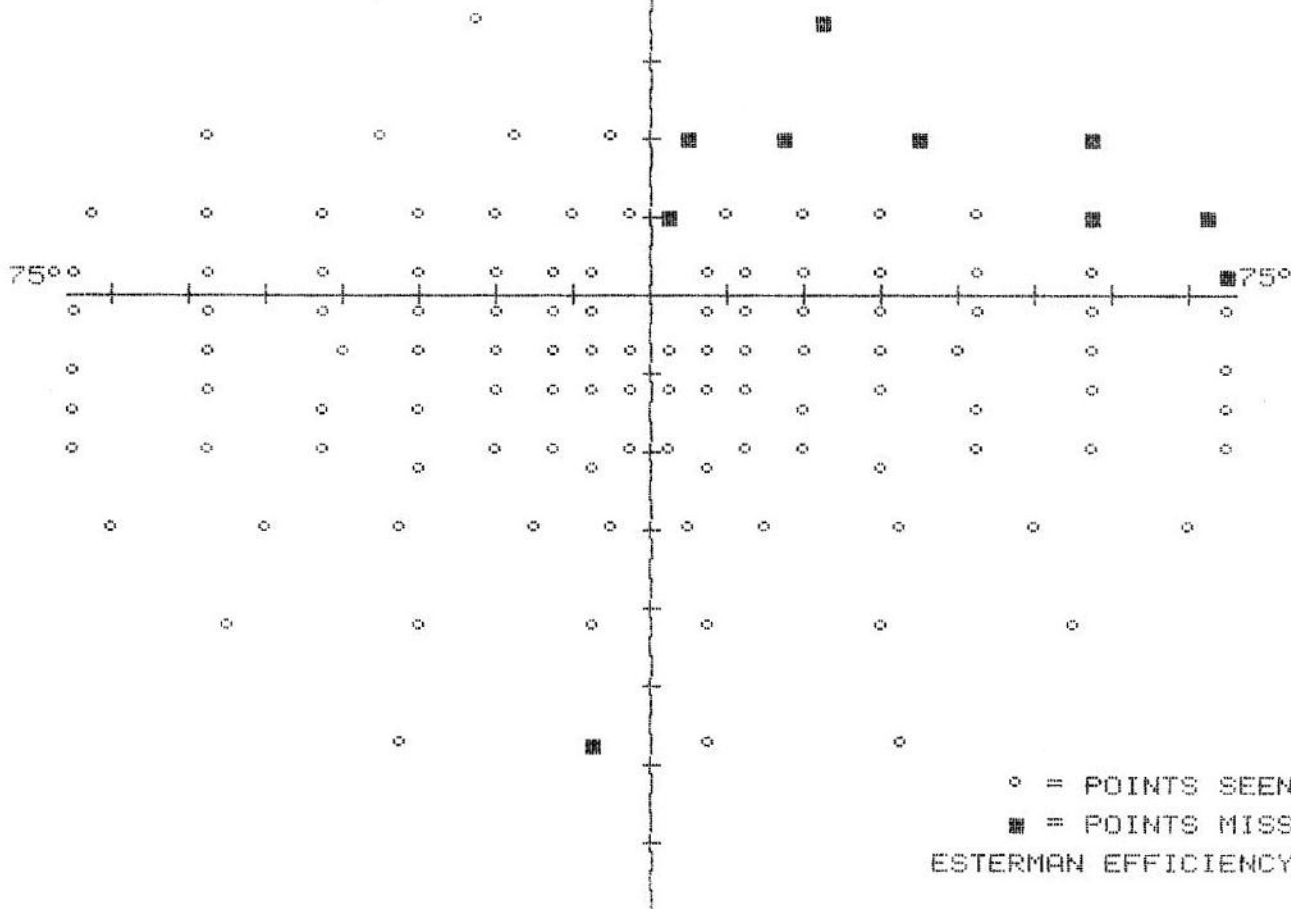
FIXATION LOSSES 0/0

FALSE POS ERRORS 0/8

FALSE NEG ERRORS 0/5

TEST TIME 00:05:3

HFA S/N 605-7397



○ = POINTS SEEN: 110/120
■ = POINTS MISSED: 10/120

ESTERMAN EFFICIENCY SCORE: 91

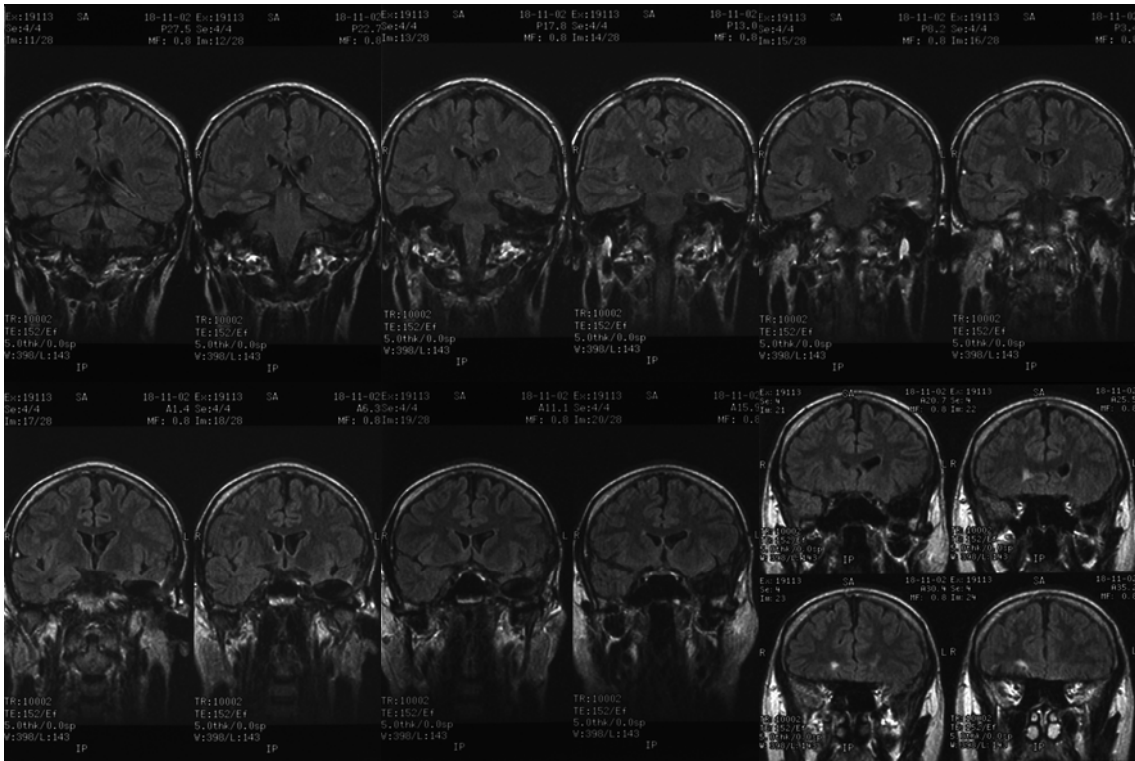


Figure 4: (Case 73) Post operative volumetric FSPGR IR prepped (Fast spoiled gradient IR prepped: slice thickness 1.5 mm) coronal MRI images employed to calculate the extent of resection. In this case the mesial resection was taken as far back as the posterior border of the pons. Most of the amygdala has been excised as well. The signal change at the resection margins was classified as mild.

Study	Year	Number of patients	Incidence of VFD	Method of Perimetry	Method of assessing resection size
Jeehani	2009	165	15.3%	ASP	post-operative MRI
Tsoka	2008	14	71.4%	ASP	post-operative MRI
Barton	2005	29	100%	Goldmann	post-operative MRI
Nilsson	2004	50	50%	Goldmann	post-operative MRI
Manj	2000	24	54% 46%	Goldmann ASP	Intra-operative measurement
Egan	2000	15	78%	Goldmann	Intra-operative measurement
Krolak-Salmon	2000	18	83%	ASP	post-operative MRI
Hughes	1999	32	97%	ASP	Intra-operative measurement
Ticconi	1992	22	55%	Clinical Examination	Intra-operative measurement
Katz	1989	29	68%	Goldmann	post-operative MRI