



HAL
open science

Clinical characterization of 29 neurofibromatosis type-1 patients with molecularly ascertained 1.4 Mb type-1 NF1 deletions

Victor-Felix Mautner, Lan Kluwe, Angelika C. Roehl, Simone Bammert, David N Cooper, Hildegard Kehrer-Sawatzki

► To cite this version:

Victor-Felix Mautner, Lan Kluwe, Angelika C. Roehl, Simone Bammert, David N Cooper, et al.. Clinical characterization of 29 neurofibromatosis type-1 patients with molecularly ascertained 1.4 Mb type-1 NF1 deletions. *Journal of Medical Genetics*, 2010, 47 (9), pp.623. 10.1136/jmg.2009.075937 . hal-00557391

HAL Id: hal-00557391

<https://hal.science/hal-00557391>

Submitted on 19 Jan 2011

HAL is a multi-disciplinary open access archive for the deposit and dissemination of scientific research documents, whether they are published or not. The documents may come from teaching and research institutions in France or abroad, or from public or private research centers.

L'archive ouverte pluridisciplinaire **HAL**, est destinée au dépôt et à la diffusion de documents scientifiques de niveau recherche, publiés ou non, émanant des établissements d'enseignement et de recherche français ou étrangers, des laboratoires publics ou privés.

Clinical characterization of 29 neurofibromatosis type-1 patients with molecularly ascertained 1.4 Mb type-1 *NF1* deletions

Victor-Felix Mautner¹, Lan Kluwe¹, Reinhard E. Friedrich¹, Angelika C. Roehl², Simone Bammert², Josef Högel², Helene Spöri², David N. Cooper³, Hildegard Kehrer-Sawatzki²

1: Department of Maxillofacial Surgery, University Medical Centre, Hamburg-Eppendorf, Germany

2: Institute of Human Genetics, University of Ulm, Ulm, Germany

3: Institute of Medical Genetics, School of Medicine, Cardiff University, Cardiff, UK

Correspondence to:

Hildegard Kehrer-Sawatzki

Institute of Human Genetics, University of Ulm

Albert-Einstein-Allee 11, 89081 Ulm, Germany

Phone: 0049 731 50065421, FAX: 0049 731 50065402

Email: hildegard.kehrer-sawatzki@uni-ulm.de

Key words: Neurofibromatosis type 1, NF1 microdeletions, genotype-phenotype correlation, hereditary cancer syndrome

Word count: 4600

ABSTRACT

Background Large deletions of the *NF1* gene region occur in ~5% of patients with neurofibromatosis type-1 (NF1) and are associated with particularly severe manifestations of the disease. However, until now, the genotype-phenotype relationship has not been comprehensively studied in patients harbouring large *NF1* gene deletions of comparable extent (giving rise to haploinsufficiency of the same genes).

Method We have performed the most comprehensive clinical/neuropsychological characterization so far undertaken in *NF1* deletion patients, involving 29 patients with precisely determined type-1 *NF1* (1.4 Mb) deletions.

Results Novel clinical features found to be associated with type-1 *NF1* deletions included pes cavus (17% of patients), bone cysts (50%), attention deficit (73%), muscular hypotonia (45%) and speech difficulties (48%). Type-1 *NF1* deletions were found to be disproportionately associated with facial dysmorphic features (90% of patients), tall stature (46%), large hands and feet (46%), scoliosis (43%), joint hyperflexibility (72%), delayed cognitive development and/or learning disabilities (93%) and mental retardation (IQ<70; 38%), as compared with the general NF1 patient population. Significantly increased frequencies (relative to the general NF1 population) of plexiform neurofibromas (76%), subcutaneous neurofibromas (76%), spinal neurofibromas (64%) and MPNSTs (21%) were also noted in the type-1 deletion patients. Further, 50% of the adult patients exhibited a very high burden of cutaneous neurofibromas ($N \geq 1000$).

Conclusion These findings emphasize the importance of deletion analysis in NF1 since frequent monitoring of tumour presence and growth could potentiate early surgical intervention thereby improving patient survival.

INTRODUCTION

Approximately 5% of all patients with neurofibromatosis type 1 (NF1) possess large deletions in 17q11.2 that include both the *NF1* gene and its flanking regions.[1] Three types of *NF1* deletion (type-1, type-2 and atypical) are distinguishable on the basis of their size and the locations of their respective breakpoints. The most common (type-1), accounting for 60-70% of all large *NF1* deletions, are generated by non-allelic homologous recombination (NAHR) between segmental duplications (NF1-REP A and NF1-REP C). These recurrent type-1 deletions encompass 1.4 Mb and lead to the loss of 14 functional genes (figure 1).[2-6] The less common type-2 *NF1* deletions, accounting for ~10-20% of all large *NF1* deletions span 1.2 Mb, but although similarly recurrent and generated by NAHR, they result in the loss of only 13 functional genes since *LRRC37B* is not deleted. The breakpoints of type-2 deletions are located within the *SUZ12* gene and its pseudogene and are frequently associated with somatic mosaicism.[7-9] By contrast, atypical *NF1* deletions are of variable size and are characterized by non-recurrent breakpoints. Consequently, atypical *NF1* deletions can differ in terms of the number of genes included within the deleted region.[10-12] A particular characteristic of type-1 deletions is that the NAHR breakpoints cluster within two preferred regions, termed paralogous recombination sites 1 and 2 (PRS1 and PRS2) both of which are located within NF1-REPs A and C.[5, 6] From a clinical vantage point, large *NF1* deletions are of considerable interest since they are frequently associated with more severe clinical manifestations than those observed in patients with intragenic *NF1* gene mutations.[13, 14 and references therein] More specifically, by comparison with other NF1 patients, those individuals harbouring *NF1* deletions have been reported to have an increased risk of malignant peripheral nerve sheath tumours [15], lower average intelligence [16], connective tissue dysplasia, skeletal malformations and dysmorphic facial features [13, 14] as well as accelerated growth (height) and carpal bone age.[17]

Although, as a group, there is a general tendency for patients possessing large *NF1* deletions to display a more severe form of NF1 than patients with intragenic *NF1* mutations, considerable clinical variability has been observed between individuals with large deletions.[18] Hence, the general validity of reported genotype-phenotype correlations in association with large *NF1* deletions remains unclear. One of the reasons for a lack of clarity could be that many studies have failed to demarcate the *NF1* deletion breakpoints precisely enough for the number of genes residing within the deletion intervals to be accurately determined. Indeed, in the majority of *NF1* deletion analyses performed to date, the deletions were characterized by FISH, a method which is insufficiently precise to distinguish between type-1 deletions and those atypical deletions with breakpoints located close to the NF1-REPs. Over the last few years, multiplex ligation-dependent probe amplification (MLPA) has been deployed in order to identify *NF1* deletions.[19, 20] Whilst the commercially available MLPA-kit (P122 version C1) can successfully distinguish type-1 from type-2 *NF1* deletions, type-1 deletions cannot be reliably distinguished from atypical deletions which can also encompass the genes *GOSRI*, *TBC1D29*, *RHOT1*, *RHBDL3* and *C17orf75* in addition to the 14 genes included in the type-1 deletion interval (figure 1). This failing is due to the poor positioning of the probes in this MLPA-kit. FISH and/or MLPA are therefore unable to determine the *NF1* deletion breakpoints with the degree of precision required to determine accurately the number of deleted genes. In order to improve deletion characterization, customized oligonucleotide array comparative genomic hybridization has recently been developed; this technique is able to differentiate unambiguously between all three types of *NF1* deletion.[12] The latter is a prerequisite for the meaningful analysis of the genotype-phenotype relationship in the context of *NF1* deletions. To date, only Descheemaeker et al.[16] have employed precisely characterized *NF1* deletions to explore genotype-phenotype relationships in NF1; these authors analysed 10 NF1 patients

harbouring type-1 deletions with breakpoints located in the PRS1 and PRS2 hotspot regions. However, these authors confined their clinical investigation to the cognitive abilities of the patients and neglected to study other clinical manifestations of the disease. Thus, until now, no comprehensive study of the genotype-phenotype relationship in patients harbouring large precisely characterized *NF1* gene deletions has been performed. Here, we analyse clinical data from 29 patients with precisely demarcated type-1 *NF1* deletions to derive a comprehensive assessment of the clinical phenotype associated with this type of gross deletion.

PATIENTS AND METHODS

Patients

The 29 patients with type-1 *NF1* deletions were identified by screening ~800 NF1 patients, clinically examined in the Hamburg NF-Centre (Department of Maxillofacial Surgery, University Medical Centre, Hamburg-Eppendorf), using microsatellite markers as previously described.[1] The deletion patients were not selected by clinical phenotype but rather were simply identified from among 800 sequential NF1 patients who came to the clinic to receive medical care, advice or genetic counselling. All patients (or their parents) gave written informed consent not only for the molecular studies to be performed but also for the publication of photographs and clinical data. Two patients inherited the deletion from their mothers (patients 284 and 763) whilst the remaining 27 patients had *de novo* deletions, adjudged on the basis of the absence of a clinically affected parent. The mother of patient 284 (patient 1454-1), herself clinically affected as a result of a *de novo* type-1 *NF1* deletion, was also included in the analysis. Among the 29 patients included in this study (12 males and 17 females) were 9 children between the ages of 4 and 15.

Characterization of the deletions

DNA was isolated from patient peripheral blood samples using the Qiamp kit (Qiagen, Valencia, CA, USA). All 29 type-1 deletion patients were investigated by MLPA using the SALSA P122 C1 MLPA assay (MRC-Holland, Amsterdam, Netherlands) according to the manufacturer's instructions and as described by Wimmer et al.[19]. In order to detect type-1 *NF1* deletions with breakpoints located in the PRS1 and PRS2 hotspots, breakpoint-spanning PCRs were performed using the Expand Long Template PCR system (Roche, Penzberg, Germany) with the primers listed in suppl. table 1, as previously described.[4, 5] In patients where the breakpoints were not assigned to the PRS1 and PRS2 breakpoint regions, the extent of the deletion was determined by SNP or microsatellite marker analysis using PCR (primers listed in suppl. table 2).

FISH analysis

The type-1 deletions identified by the methods described above were also investigated by fluorescent *in situ* hybridisation (FISH) as previously described [7, 8] to exclude mosaicism. A total of 30 metaphase spreads and at least 100 interphase nuclei were evaluated in order to exclude the presence of normal cells lacking the deletion.

Clinical investigation

The 29 patients were investigated according to a standardized protocol that included a comprehensive anamnestic evaluation as well as the assessment of various clinical parameters and NF1-associated manifestations at the University Medical Centre, Hamburg-Eppendorf, as outlined in supplementary text 1.

Statistical analysis

The χ^2 goodness-of-fit test was used to assess whether the frequency of clinical symptoms differed between NF1 patients with large deletions and patients from the general NF1 population. Exact 95%-confidence intervals were determined wherever possible for patients manifesting certain clinical symptoms. Confidence intervals for IQ scores were assigned under the assumption of a normal distribution.

RESULTS

Characterization of the deletions

The 28 large *NF1* deletions investigated in this study were identified in 29 patients including patients 1454-1 and 284, who are mother and daughter. The deletions were ascertained by FISH and microsatellite marker analysis. Mosaicism with normal cells bearing two copies of the *NF1* gene was not observed by FISH analysis of patient lymphocytes. Breakpoint-spanning PCR analysis indicated that 24 of the 28 deletions had breakpoints within either the PRS1 or PRS2 recombination hotspot regions of the NF1-REPs (suppl. table 3). Thus, the deletion breakpoints were narrowed down to regions of length 3.5 kb (PRS2) and 2.9 kb (PRS1), respectively. The high resolution breakpoint mapping in these 24 deletions indicated that they encompassed a total of 14 genes. However, 4 of the 29 patients did not generate a product in the PRS1 and PRS2 deletion breakpoint-spanning PCRs, even although the MLPA results were suggestive of a type-1 deletion. In these patients, the breakpoints could have been located either within the NF1-REPs (but not within the PRS1 and PRS2 regions) or proximal or distal to the NF1-REPs. In the latter case, the deletions might have been larger than 1.4 Mb and hence could have included up to five additional genes (figure 1). MLPA was unable to provide any better resolution owing to the distance between the NF1-REPs and the next available MLPA probes (suppl. figures 1, 2). To determine whether or not these abovementioned genes flanking the NF1-REPs were present within the deletion intervals of the four patients who were negative for the PRS1/PRS2, breakpoint-spanning PCRs, flanking SNPs and a microsatellite marker were investigated. Heterozygosity patterns for these polymorphisms indicated that the breakpoints of the respective deletions were located within the NF1-REPs in all four cases (suppl. table 4). Hence, we may conclude that all 29 *NF1* deletions in these patients encompass the same 14 functional genes.

Clinical phenotype associated with the type-1 *NF1* deletions

In what follows, the clinical and neuropsychological features of 29 patients with type-1 *NF1* deletions are described. Further, the frequencies of the observed features are compared with those reported previously in patients with large *NF1* deletions. In this regard, we make particular reference to the studies of Venturin et al.[13] and Mensink et al.[14], who not only investigated their own *NF1* deletion patients but also undertook a retrospective review of the literature on previously published patients with large *NF1* deletions. Finally, the frequency of each clinical feature associated with type-1 *NF1* deletions is compared with the available corresponding frequencies reported in the general NF1 population (suppl. table 5).

Dysmorphic facial features

Facial dysmorphism was noted in 26 of the 29 patients studied (90%; suppl. table 6; figures 2, 3) and hence was present at a higher frequency than reported previously.[13, 14] Hypertelorism was the most common feature observed in 86% of our patients. Coarse facial appearance and facial asymmetry were also frequent. However, not all NF1 patients investigated here exhibited dysmorphic facial features that might immediately have raised suspicion of a large *NF1*

deletion. Patient 1338 for, example, did not exhibit dysmorphic facial features (suppl. figure 3). Thus, although our study indicated that dysmorphic facial features are present in the majority of patients with type-1 *NF1* deletions, facial dysmorphism is by no means a universal feature of type-1 deletions.

Overgrowth and unusual body habitus

Tall-for-age stature with height measurements at or above the 94th percentile, and large hands and feet, were noted in 46% of the patients studied (suppl. table 7). By contrast, growth retardation and short stature are relatively common features in the general NF1 population.[21-23] Accelerated height growth and carpal bone age have been previously reported to occur frequently in patients with large *NF1* deletions, especially in pre-school children aged 2-6 years in whom overgrowth is most evident.[17] In our study, two of the three children in the pre-school age bracket were unusually tall (99th and 100th percentiles in height, respectively). Macrocephaly, measured as occipital-frontal circumference at or above the 97th percentile, was ascertained in 39% of patients (suppl. table 7). Since macrocephaly is observed in 29-45% of all individuals with NF1 [24-26], the frequency of this feature does not appear to be elevated in patients with type-1 deletions.

In 5 of the 29 patients studied, we observed pes cavus, a deformity of the feet that has not so far been described in patients with *NF1* deletions (suppl. table 7; suppl. figure 4).

Café-au-lait-macules (CALM), freckling and Lisch nodules

CALM and Lisch nodules were observed in 27 of the 29 patients in our study (93%; suppl. table 8) whereas intertriginous freckling was noted in 28 patients. The frequencies of these clinical features in deletion patients are concordant with their respective rates previously observed in the general NF1 population.[27, 28]

Cognitive ability

A significant delay in cognitive development was ascertained in 14 of the 29 type-1 deletion patients (48%), whereas learning difficulties were recorded in 13 patients (45%) (suppl. table 9). Learning difficulties have been previously noted in 30-60% of all NF1 children.[29-34] A significant delay in cognitive development and/or learning difficulties were therefore observed in 93% of our patients, a rate markedly higher than that reported by Mensink et al. (70%; suppl. table 5).

In 21 of our patients under study, a mean full-scale IQ (FSIQ) of 76.9 was ascertained (sd:14.6; 95% CI: 70.2-83.5). Seven of these 21 patients were children. Mental retardation (IQ<70) was evident in 8 of the 21 patients (38%; 4 children and 4 adults) whilst borderline mental retardation (70<IQ<85) was noted in a further 5 of the 21 patients (24%). By contrast, an IQ<70 has been previously observed in only 6-8% of the general NF1 patient population.[29] The mean FSIQ (76.9) observed in the 21 patients investigated in this study is similar to the mean FSIQ of 76.0 determined in 11 patients with type-1 *NF1* deletions by Descheemaeker et al.[16] These authors also ascertained the mean FSIQ in 106 NF1 individuals without an *NF1* deletion to be 88.5. Thus, in general, the mean FSIQ in patients with type-1 *NF1* deletions would appear to be significantly lower than the mean FSIQ in NF1 patients without a deletion. Although the average intelligence of type-1 *NF1* deletion patients is generally lower than that of patients without deletions, it should be appreciated that there is a substantial overlap between the two groups.

Attention deficit hyperactivity disorder (ADHD)

ADHD was diagnosed in 8 of 24 deletion patients investigated (33%, 3 children and 5 adults; suppl. table 9). In a further 8 of these 24 patients, the Test of Variables of Attention (T.O.V.A.) revealed abnormal results even although the strict definitional criteria for ADHD were not met. Taken together, 73% of the patients investigated in this study were considered to have attention difficulties. Among the 8 children investigated, 7 showed abnormal T.O.V.A. results and three of these met the strict criteria for ADHD (37%). However, we noted ADHD in 49% of the children in the Hamburg NF1 patient cohort (N=~800) unselected with respect to their mutation.[35] Hence, ADHD does not appear to occur at an elevated frequency in children with large *NF1* deletions as compared with children in the general NF1 population.

Skeletal anomalies

Anomalies of the skeletal system were detected in 22 of the 29 patients studied here (76%). The most frequent skeletal anomaly was scoliosis which was noted in 43% of the patients (scoliosis with a curve of ≥ 10 degrees; suppl. table 10). Hence, scoliosis was encountered significantly more frequently in patients with type-1 *NF1* deletions (χ^2 -test, $p = 0.005$, 1d.f.) than in the general NF1 population, in whom 10-20% have been reported to present with scoliosis.[36, 37] Severe scoliosis with a curve of ≥ 20 degrees was observed in 4 of the 12 deletion patients with scoliosis.

Pectus excavatum was observed in 9 of the 29 patients (31%), a frequency in accord with previous findings (33%) in patients with *NF1* deletions.[14] In the general NF1 population, pectus excavatum has been reported to occur at a frequency of 12% or even up to 50%.[38, 39] Bone cysts were noted to occur with a remarkably high frequency in our group of type-1 deletion patients (suppl. table 10). Indeed, eight of the 16 patients investigated by MRI had bone cysts. In 5 of these patients, the bone cysts were noted in association with fractures. Bone cysts have not previously been reported in patients with large *NF1* deletions, probably because radiography and MRI investigations were not performed.

Connective tissue anomalies and heart defects

Hyperflexibility of joints was observed in 21 of the 29 patients (72%) with type-1 *NF1* deletions (suppl. table 6). Mensink et al.[14] also reported a high frequency of this feature (58%) in patients with large deletions. These authors noticed that in addition to joint laxity, other connective tissue abnormalities were also frequently associated with large *NF1* deletions, including soft skin on the palms and cardiovascular anomalies. In our own study, soft fleshy palms with an excess of connective tissue were observed in 50% of patients whilst congenital heart defects were observed in 21%. Previously, Venturin et al.[13] noted cardiovascular malformations in 18% of *NF1* deletion patients. Various kinds of congenital heart disease have been repeatedly observed in NF1 patients but data concerning their frequency in the general NF1 population are not congruent between different studies (the prevalence ranging from 2% to 27%).[40-43]

Muscular hypotonia and reduced speech intelligibility

Mild muscular hypotonia was documented in 13 of the 29 type-1 *NF1* deletion patients (45%; suppl. table 11). This feature has not previously been noted in association with large *NF1* deletions. Reduced speech intelligibility was observed in 14 patients (48%); this feature has not previously been reported in association with large *NF1* deletions. Although the overall prevalence of speech disorders in NF1 is not yet known, speech difficulties generally appear to

occur more frequently in patients with NF1 as compared to the normal population.[44, 45] Speech difficulties due to deficits in articulation occur in ~25% of children with NF1.[46]

Subcutaneous and cutaneous neurofibromas

Subcutaneous neurofibromas were observed in 22 of the 29 patients (76%; suppl. table 12). If we consider only the 20 adult patients in our cohort, then all 20 patients had subcutaneous neurofibromas. Six of the 29 patients investigated here had ≥ 1000 subcutaneous neurofibromas (21%). The prevalence of subcutaneous neurofibromas appears to be significantly elevated in patients with type-1 *NF1* deletions (χ^2 -test, $p = 0.008$, 1 d.f.), since subcutaneous neurofibromas were ascertained in only 48% of 468 NF1 patients unselected by *NF1* mutation type and hence probably reflecting the general NF1 population.[47]

Cutaneous neurofibromas were observed in 86% of our 29 type-1 deletion patients. Tucker et al.[47] observed cutaneous neurofibromas in 85% of 443 NF1 patients examined, a rate that may reflect the presence of these tumours in the general NF1 population. In our own study, a high burden of cutaneous neurofibromas ($N \geq 1000$) was noted in 10 patients (34%). If we consider only the 20 adult patients in our group, then 10 of these patients (50%) had ≥ 1000 neurofibromas. Eleven patients either lacked, or exhibited fewer than 10, cutaneous neurofibromas. However, eight of these 11 patients were children whilst three were young adults (suppl. table 12).

In previous studies, it has been suggested that patients with large *NF1* deletions frequently exhibit early onset growth of cutaneous neurofibromas.[2] In our study, 4 of the 9 children included lacked cutaneous neurofibromas, whereas the other 5 children had fewer than 9 cutaneous neurofibromas. By contrast, subcutaneous neurofibromas ($N \geq 20$) were noted in 4 of the 9 children in our study (44%). Thus, the early onset of subcutaneous neurofibromas would appear to be more pronounced in our own group of children with type-1 deletions than cutaneous neurofibromas.

Plexiform neurofibromas

Plexiform neurofibromas (PNF) were observed in 22 of the 29 patients studied here (76%; suppl. table 12). Thus, PNF appear to be more prevalent in our patients with precisely demarcated type-1 deletions than has been previously observed in studies of patients with less well characterized *NF1* deletions. The prevalence of PNF in the general NF1 population has been estimated by CT and MRI imaging to be 43-50%.[48-50] Hence, the prevalence of PNF would appear to be significantly increased in patients with type-1 deletions as compared to all NF1 patients (χ^2 -test, $p = 0.008$, 1 d.f.).

Multiple plexiform neurofibromas reportedly occur in 9–21% of patients with NF1.[24, 49] In our study, 9 of the 29 type-1 deletion patients exhibited multiple superficial plexiform neurofibromas (31%).

Spinal neurofibromas

Paraspinal or spinal neurofibromas were observed in 9 of 14 patients investigated by MRI of the spine (64%; suppl. table 12). In previous studies, spinal neurofibromas were observed much less frequently in patients with large deletions (6%; suppl. table 5), probably because spinal MRI was not performed. Based on the analysis of Tucker et al.[47], it may be inferred that spinal neurofibromas occur in ~30% of all NF1 patients. Thus, spinal neurofibromas appear to occur more frequent among patients with type-1 NF1 deletions than in all individuals with NF1 (χ^2 -test, $p = 0.008$, 1 d.f.).

Optic pathway gliomas and structural brain abnormalities

Cerebral MRI revealed optic pathway gliomas in 5 of 27 patients (19%; suppl. table 12). The overall incidence of optic pathway gliomas in NF1 has been reported to be 15-19%. [51, 52] Thus, the prevalence of optic pathway gliomas is not significantly increased in patients with type-1 deletions as compared to the general NF1 population.

Structural brain abnormalities were observed, upon MRI investigation, in 5 of our 29 patients (17%) (suppl. table 12). Korf et al. [53] previously observed structural brain abnormalities in 3 of 5 patients with large *NF1* deletions. T2 hyperintensities (T2H) are focal areas of high signal intensity on T2-weighted images that are thought to represent foci of neural dysplasia or dysmyelination. [54] Here, T2H were observed in 13 of the 29 deletion patients investigated (45%). By contrast, all five patients with large *NF1* deletions investigated by Korf et al. [53] had multiple regions of bright T2 signal intensity. However, discrete T2H are seen in an average of 64% of all individuals with NF1. [37, 54-57] Although T2H tend to be more common in children and to decrease with age [58], 57% of NF1 patients between 16 and 30 years have been reported to exhibit T2 hyperintensities. [56] Thus, we conclude that the prevalence of T2H in patients with type-1 *NF1* deletions is not significantly elevated as compared to the general NF1 population.

Epilepsy

Epilepsy was noted in two of our patients (7%) and hence does not occur at an increased frequency in patients with type-1 deletions as compared with the general NF1 population, in whom epilepsy has been observed with a frequency of 3-7%. [24, 25, 59]

Malignant peripheral nerve sheath tumours (MPNSTs)

Six of the 29 patients investigated (21%) here had an MPNST (suppl. table 12). In their review of the literature, Mensink et al. [14] reported MPNSTs in 13% of patients with *NF1* deletions. Long-term clinical follow-up is essential in order to assess whether or not a patient has developed an MPNST. The long-term follow-up that we provided to our own patients may well be the factor responsible for the higher rate of MPNSTs detected in this study as compared with the review of the literature published by Mensink et al. [14] The prevalence of MPNSTs in all individuals with NF1 has been estimated to be 2-5%. [60]

DISCUSSION

The first patient with a large *NF1* gene deletion was described by Kayes et al. [61] Since this report, a total of 166 patients with large deletions of the *NF1* gene region have been identified and described in terms of their clinical phenotypes. [13, 14] Much information has been obtained from these studies regarding the delineation of the *NF1* deletion-associated clinical phenotype. However, the establishment of genotype-phenotype correlations has been hampered by the incomplete clinical and molecular investigation of patients. Indeed, in most previous reports, the extent of the deletions was not precisely determined.

In this study, we have analysed 29 patients harbouring precisely defined type-1 *NF1* deletions with breakpoints located within NF1-REPs A and C. Hence, all 29 *NF1* deletions in these patients encompass the same 14 functional genes (fig 1). The clinical investigation of these 29 patients indicated that type-1 *NF1* deletions are frequently associated with facial dysmorphic features, tall-for-age stature, large hands and feet, an excess of connective tissue in the hands and feet, hyperflexibility of the joints, cognitive impairment and scoliosis. These associations have already been noted in previous studies of large *NF1* gene deletions even although these earlier studies often included less well characterized patients. [13, 14] Our findings reported

here serve to confirm that these clinical features are indeed frequent in patients with type-1 *NF1* deletions. However, our study also indicates that even within this relatively homogeneous group of 29 patients (with comparable deletions leading to the loss of the same 14 functional genes), some variability is apparent in terms of the presence or absence of some of the above mentioned features.

The majority of clinical features observed in our type-1 deletion patients occurred at a higher frequency than has been previously reported in published reviews of the literature (suppl. table 5).[13, 14] This is probably due to the fact that these reviews included many different studies in which the clinical phenotypes of the *NF1* patients had neither been comprehensively nor uniformly described and in which the sample sizes of analysed patients were often quite low. In this study, however, the patients were uniformly ascertained with only those patients harbouring clearly defined type-1 *NF1* deletions being included.

Additional clinical features that we observed at high frequency in patients with type-1 *NF1* deletions included pes cavus (noted in 17% of patients), bone cysts (50% of patients), attention deficit (73% of patients), muscular hypotonia (45%) and speech difficulties (48%). These features have not been reported to occur at increased frequency in previous studies of large *NF1* deletions. This may be related to the comprehensive nature of our clinical investigation protocol and to the care that we took in selecting patients with comparable deletions.

Remarkably, 73% of the deletion patients in our study exhibited an attention deficit as indicated by abnormal results in the Test of Variables of Attention (T.O.V.A.). It may be inferred from our observations that stimulant-based medication of attention deficit could help to improve both the learning capability and the social interactions of patients with type-1 *NF1* deletions.

Clinical features observed at increased frequency in patients with large *NF1* deletions
We noted that the prevalence of subcutaneous, plexiform and spinal neurofibromas as well as MPNSTs is significantly higher in patients with type-1 *NF1* deletions than in the general *NF1* population. Importantly, 76% of the patients with type-1 deletions investigated here had subcutaneous neurofibromas. The proportion of patients with type-1 *NF1* deletions manifesting subcutaneous neurofibromas appears to be significantly higher than in the general *NF1* population ($p = 0.008$). This is important to consider because subcutaneous neurofibromas are associated with mortality in *NF1*. [62] Patients with subcutaneous neurofibromas are roughly three times more likely to develop MPNSTs than individuals without subcutaneous neurofibromas.[47, 63] Consistent with this finding is that 5 of the 6 patients with MPNSTs in our study also had subcutaneous neurofibromas. The frequency of patients with MPNSTs in our study was 21%, thereby confirming the observation originally made by De Raedt et al.[15] that patients with *NF1* deletions have a substantially higher risk for the development of MPNSTs as compared with *NF1* individuals lacking large *NF1* deletions. Thus, whereas the lifetime risk of an MPNST in all *NF1* individuals is 8–13% [64], *NF1* deletion patients have an estimated lifetime risk for an MPNST of 16–26%.[15]

The prevalence of plexiform neurofibromas in the 29 patients investigated here was also remarkably high (76%). Such a high prevalence has not been previously observed in studies of patients with large *NF1* deletions. According to our findings, the proportion of patients with type-1 *NF1* deletions manifesting plexiform neurofibromas is significantly higher ($p = 0.008$) than in the general *NF1* population. The high prevalence of plexiform neurofibromas reported here is eventually expected to translate into an increased risk of developing MPNSTs. Many plexiform neurofibromas are likely to be congenital lesions with the potential to undergo transformation into MPNSTs.[49] Indeed, many *NF1*-associated MPNSTs arise in pre-existing plexiform neurofibromas.[47, 65, 66]

Spinal neurofibromas were observed in 9 of 14 patients for whom spinal MRI data were available (64%). The high proportion of our patients manifesting spinal neurofibromas suggests that patients with *NF1* deletions may not only exhibit a high number of externally visible plexiform neurofibromas, but may also have a high internal tumour load.

In summary, our study clearly indicates that the clinical phenotype associated with type-1 *NF1* deletions is often severe and associated with additional complications which render special and more intensive clinical and psychological care necessary.

ACKNOWLEDGEMENTS

This work was funded by the Deutsche Forschungsgemeinschaft (DFG), grant FR1035/6-1, and the Deutsche Krebshilfe, grants 106982 and 108793. We would like to express our gratitude to the patients and their relatives who participated in this study.

Competing interests None

Ethics approval Obtained

Patient consent Patient or parental consent obtained

Provenance and peer review Not commissioned; externally peer reviewed

Licence for Publication statement: "The Corresponding Author has the right to grant on behalf of all authors and does grant on behalf of all authors, an exclusive licence (or non exclusive for government employees) on a worldwide basis to the BMJ Publishing Group Ltd to permit this article (if accepted) to be published in JMG and any other BMJ PGL products and sublicences such use and exploit all subsidiary rights, as set out in our licence (<http://group.bmj.com/products/journals/instructions-for-authors/licence-forms>)."

FIGURE LEGENDS:

Figure 1: Schematic representation of the *NF1* gene region in 17q11.2. The 1.4 Mb-spanning type-1 deletions encompass a total of 14 genes, which are indicated by horizontal bars. Red arrows specify the relative positions of the multiplex ligation-dependent probe amplification (MLPA) within the type-1 deletion interval. Green arrows represent MLPA probes that were not located within the type-1 deletion region. From the results generated with the MLPA-kit P122 C1, it was not possible to ascertain whether or not the genes marked in yellow were included within the deleted region. Thus, discrimination between type-1 deletions with breakpoints located in the *NF1*-REPs, and atypical deletions which encompass the genes marked in yellow is not possible using the currently available MLPA-kit P122 version C1.

Figure 2: Facial appearance of female patients with type-1 *NF1* deletions: patient 752 (A), patient 1454,1 (B), patient 450 (C), patient 1333 (D), patient 1143 (E), patient 801(F). Hypertelorism was the most common feature.

Figure 3: Facial appearance of male patients with type-1 *NF1* deletions: patient 3028 (A), patient 521 (B), patient 270 (C), patient 1178 (D), patient 1547 (E) and patient 2284 (F).

REFERENCES

1. **Kluwe L**, Siebert R, Gesk S, et al. Screening 500 unselected neurofibromatosis 1 patients for deletions of the NF1 gene. *Hum Mutat* 2004;**23**:111-6.
2. **Dorschner MO**, Sybert VP, Weaver M, et al. NF1 microdeletion breakpoints are clustered at flanking repetitive sequences. *Hum Mol Genet* 2000;**9**:35-46.
3. **Jenne DE**, Tinschert S, Reimann H, et al. Molecular characterization and gene content of breakpoint boundaries in patients with neurofibromatosis type 1 with 17q11.2 microdeletions. *Am J Hum Genet* 2001;**69**:516-27.
4. **López-Correa C**, Dorschner M, Brems H, et al. Recombination hotspot in NF1 microdeletion patients. *Hum Mol Genet* 2001;**10**:1387-92.
5. **Forbes SH**, Dorschner MO, Le R, Stephens K. Genomic context of paralogous recombination hotspots mediating recurrent NF1 region microdeletion. *Genes Chrom Cancer* 2004;**41**:12-25.
6. **De Raedt T**, Stephens M, Heyns I, et al. Conservation of hotspots for recombination in low-copy repeats associated with the NF1 microdeletion. *Nat Genet* 2006;**38**:1419-23.
7. **Kehrer-Sawatzki H**, Kluwe L, Sandig C, et al. High frequency of mosaicism among patients with neurofibromatosis type 1 (NF1) with microdeletions caused by somatic recombination of the *JJAZ1* gene. *Am J Hum Genet* 2004;**75**:410-23.

8. **Steinmann K**, Cooper DN, Kluwe L, et al. Type 2 NF1 deletions are highly unusual by virtue of the absence of nonallelic homologous recombination hotspots and an apparent preference for female mitotic recombination. *Am J Hum Genet* 2007;**81**:1201-20.

9. **Kehrer-Sawatzki H**, Cooper DN. Mosaicism in sporadic neurofibromatosis type 1: variations on a theme common to other hereditary cancer syndromes? *J Med Genet* 2008;**45**:622-31.

10. **Mantripragada KK**, Thuresson AC, Piotrowski A, et al. Identification of novel deletion breakpoints bordered by segmental duplications in the *NF1* locus using high resolution array-CGH. *J Med Genet* 2006;**43**:28-38.

11. **Kehrer-Sawatzki H**, Schmid E, Fünsterer C, et al. Absence of cutaneous neurofibromas in an NF1 patient with an atypical deletion partially overlapping the common 1.4 Mb microdeleted region. *Am J Med Genet A* 2008;**146A**:691-9.

12. **Pasmant E**, Sabbagh A, Masliah-Planchon J, et al. Detection and characterization of NF1 microdeletions by custom high resolution array CGH. *J Mol Diagn* 2009;**11**:524-9.

13. **Venturin M**, Guarnieri P, Natacci F, et al. Mental retardation and cardiovascular malformations in NF1 microdeleted patients point to candidate genes in 17q11.2. *J Med Genet* 2004;**41**:35-41.

14. **Mensink KA**, Ketterling RP, Flynn HC, et al. Connective tissue dysplasia in five new patients with NF1 microdeletions: further expansion of phenotype and review of the literature. *J Med Genet* 2006;**43**:e8.
15. **De Raedt T**, Brems H, Wolkenstein P, et al. Elevated risk for MPNST in NF1 microdeletion patients. *Am J Hum Genet* 2003;**72**:1288-92.
16. **Descheemaeker MJ**, Roelandts K, De Raedt T, et al. Intelligence in individuals with a neurofibromatosis type 1 microdeletion. *Am J Med Genet* 2004;**131A**:325-6.
17. **Spiegel M**, Oexle K, Horn D, et al. Childhood overgrowth in patients with common NF1 microdeletions. *Eur J Hum Genet* 2005;**13**:883-8.
18. **Tonsgard JH**, Yelavarthi KK, Cushner S, et al. Do *NF1* gene deletions result in a characteristic phenotype? *Am J Med Genet* 1997;**73**:80-6.
19. **Wimmer K**, Yao S, Claes K, et al. Spectrum of single- and multiexon *NF1* copy number changes in a cohort of 1,100 unselected NF1 patients. *Genes Chrom Cancer* 2006;**5**:265-76.
20. **De Luca A**, Bottillo I, Dasdia MC, et al. Deletions of *NF1* gene and exons detected by multiplex ligation-dependent probe amplification. *J Med Genet* 2007;**44**:800-8.
21. **Riccardi VM**. *Neurofibromatosis: Phenotype, Natural History and Pathogenesis*, 2nd edn. Baltimore: Johns Hopkins University Press, 1992: 142-53.

22. **Riccardi VM.** Skeletal System. In: Friedman J, Gutmann D, MacCollin M, Riccardi VM, eds. *Neurofibromatosis: Phenotype, Natural History and Pathogenesis*, 3rd edn. Baltimore: Johns Hopkins University Press, 1999:250-5.

23. **Huson SM,** Hughes RAC, eds. *The Neurofibromatoses – A Pathogenetic and Clinical Overview*. London: Chapman & Hall, 1994:169.

24. **Huson SM,** Harper PS, Compston DAS. Von Recklinghausen neurofibromatosis: A clinical and population study in South East Wales. *Brain* 1988;**111**:1355-81.

25. **North KN.** Neurofibromatosis type 1: review of the first 200 patients in an Australian clinic. *J Child Neurol* 1993;**8**:395-402.

26. **Riccardi VM.** *Neurofibromatosis: Phenotype, Natural History and Pathogenesis*, 2nd edn. Baltimore: Johns Hopkins University Press, 1992:165-6.

27. **Lewis RA,** Riccardi VM. Von Recklinghausen neurofibromatosis: prevalence of iris hamartoma. *Ophthalmology* 1981;**88**:348-55.

28. **Friedman JM.** Evaluation and Management. In: Friedman J, Gutmann D, MacCollin M, Riccardi VM, eds. *Neurofibromatosis: Phenotype, Natural History and Pathogenesis*. 3rd edn. Baltimore: Johns Hopkins University Press, 1999:90-1.

29. **Ferner RE,** Hughes RA, Weinman J. Intellectual impairment in neurofibromatosis 1. *J Neurol Sci* 1996;**138**:125-33.

30. **North KN**, Riccardi V, Samango-Sprouse C, et al. Cognitive function and academic performance in neurofibromatosis. 1: consensus statement from the NF1 Cognitive Disorders Task Force. *Neurology* 1997;**48**:1121-7.
31. **North KN**. Cognitive function and academic performance. In: Friedman J, Gutmann D, MacCollin M, Riccardi VM, eds. *Neurofibromatosis: Phenotype, Natural History and Pathogenesis*, 3rd edn. Baltimore: Johns Hopkins University Press, 1999:162-7.
32. **Ozonoff S**. Cognitive impairment in neurofibromatosis type 1. *Am J Med Genet* 1999;**89**:45-52.
33. **Rosser TL**, Packer RJ. Neurocognitive dysfunction in children with neurofibromatosis type 1. *Curr Neurol Neurosci Rep* 2003;**3**:129-36.
34. **Hyman SL**, Shores A, North KN. The nature and frequency of cognitive deficits in children with neurofibromatosis type 1. *Neurology* 2005;**65**:1037-44.
35. **Mautner VF**, Kluwe L, Thakker SD, Leark RA. Treatment of ADHD in neurofibromatosis type 1. *Dev Med Child Neurol* 2002;**44**:164-70.
36. **Riccardi VM**. Skeletal System. In: Friedman J, Gutmann D, MacCollin M, Riccardi VM, eds. *Neurofibromatosis: Phenotype, Natural History and Pathogenesis*, 3rd edn. Baltimore: Johns Hopkins University Press, 1999:262-3.

37. **North K.** Neurofibromatosis type 1. *Am J Med Genet* 2000;**97**:119-27.
38. **Castle B,** Baser ME, Huson SM, et al. Evaluation of genotype-phenotype correlations in neurofibromatosis type 1. *J Med Genet* 2003;**40**:e109.
39. **Riccardi VM.** Skeletal System. In: Friedman J, Gutmann D, MacCollin M, Riccardi VM, eds. *Neurofibromatosis: Phenotype, Natural History and Pathogenesis*, 3rd edn. Baltimore: Johns Hopkins University Press, 1999:260.
40. **Friedman JM.** Evaluation and Management. In: Friedman J, Gutmann D, MacCollin M, Riccardi VM, eds. *Neurofibromatosis: Phenotype, Natural History and Pathogenesis*. 3rd edn. Baltimore: Johns Hopkins University Press, 1999:277-82.
41. **Lin AE,** Birch PH, Korf BR, et al. Cardiovascular malformations and other cardiovascular abnormalities in neurofibromatosis 1. *Am J Med Genet* 2000;**95**:108-17.
42. **Friedman JM,** Arbiser J, Epstein JA, et al. Cardiovascular disease in neurofibromatosis 1: report of the NF1 Cardiovascular Task Force. *Genet Med* 2002;**4**:105-11.
43. **Tedesco MA,** Di Salvo G, Natale F, et al. Cardiac abnormalities detected by Doppler imaging in patients with neurofibromatosis type 1. *Am J Cardiol* 2001;**88**:1198-200.
44. **Alivuotila L,** Hakokari J, Visnapuu V, et al. Speech characteristics in neurofibromatosis type 1. *Am J Med Genet A* 2010;**152A**:42-51.

45. **Cosyns M**, Vandeweghe L, Mortier G, et al. Speech disorders in neurofibromatosis type 1: a sample survey. *Int J Lang Commun Disord* 2009 Nov 10. [Epub ahead of print]
46. **North KN**. Cognitive function and academic performance. In: Friedman J, Gutmann D, MacCollin M, Riccardi VM, eds. *Neurofibromatosis: Phenotype, Natural History and Pathogenesis*, 3rd edn. Baltimore: Johns Hopkins University Press, 1999:168.
47. **Tucker T**, Wolkenstein P, Revuz J, et al. Association between benign and malignant peripheral nerve sheath tumors in NF1. *Neurology* 2005;**65**:205–11.
48. **Tonsgard JH**, Kwak SM, Short MP, Dachman AH. CT imaging in adults with neurofibromatosis-1: frequent asymptomatic plexiform lesions. *Neurology* 1998;**50**:1755-60.
49. **Waggoner DJ**, Towbin J, Gottesman G, Gutmann DH. A clinic-based study of plexiform neurofibromas in neurofibromatosis 1. *Am J Med Genet* 2000;**92**:132-5.
50. **Ferner RE**, Huson SM, Thomas N, et al. Guidelines for the diagnosis and management of individuals with neurofibromatosis 1. *J Med Genet* 2007;**44**:81-8.
51. **Lewis RA**, Gerson LP, Axelson KA, et al. von Recklinghausen neurofibromatosis. II. Incidence of optic gliomata. *Ophthalmology* 1984;**91**:929-35.
52. **Listernick R**, Louis DN, Packer RJ, Gutmann DH. Optic pathway gliomas in children with neurofibromatosis 1: consensus statement from the NF1 Optic Pathway Glioma Task Force. *Ann Neurol* 1997;**41**:143-9.

53. **Korf BR**, Schneider G, Poussaint TY. Structural anomalies revealed by neuroimaging studies in the brains of patients with neurofibromatosis type 1 and large deletions. *Genet Med* 1999;**1**:136-40.
54. **DiPaolo DP**, Zimmerman RA, Rorke LB, et al. Neurofibromatosis type 1: pathologic substrate of high-signal-intensity foci in the brain. *Radiology* 1995;**195**:721-4.
55. **Ferner RE**, Chaudhuri R, Bingham J, et al. MRI in neurofibromatosis 1. The nature and evolution of increased intensity T2 weighted lesions and their relationship to intellectual impairment. *J Neurol Neurosurg Psychiatry* 1993;**56**:492-5.
56. **Itoh T**, Magnaldi S, White RM, et al. Neurofibromatosis type 1: the evolution of deep gray and white matter MR abnormalities. *AJNR Am J Neuroradiol* 1994;**15**:1513-9.
57. **Hyman SL**, Gill DS, Shores EA, et al. T2 hyperintensities in children with neurofibromatosis type 1 and their relationship to cognitive functioning. *J Neurol Neurosurg Psychiatry* 2007;**78**:1088-91.
58. **Hyman SL**, Gill DS, Shores EA, et al. Natural history of cognitive deficits and their relationship to MRI T2-hyperintensities in NF1. *Neurology* 2003;**60**:1139-4.
59. **Kulkantkorn K**, Geller TJ. Seizures in neurofibromatosis type 1. *Neurology* 1997;
48:A402.

60. **Ferner RE**, Gutmann DH. International consensus statement on malignant peripheral nerve sheath tumors in neurofibromatosis. *Cancer Res* 2002;**62**:1573-7.
61. **Kayes LM**, Riccardi VM, Burke W, et al. Large *de novo* DNA deletion in a patient with sporadic neurofibromatosis 1, mental retardation, and dysmorphism. *J Med Genet* 1992;**29**:686-90
62. **Khosrotehrani K**, Bastuji-Garin S, Riccardi VM, et al. Subcutaneous neurofibromas are associated with mortality in neurofibromatosis 1: a cohort study of 703 patients. *Am J Med Genet A* 2005;**132A**:49-53.
63. **Mautner VF**, Asuagbor FA, Dombi E, et al. Assessment of benign tumor burden by whole-body MRI in patients with neurofibromatosis 1. *Neuro-oncology* 2008;**10**:593-8.
64. **Evans DG**, Baser ME, McGaughran J, et al. Malignant peripheral nerve sheath tumours in neurofibromatosis 1. *J Med Genet* 2002;**39**:311-4.
65. **McGaughran JM**, Harris DI, Donnai D, et al. A clinical study of type 1 neurofibromatosis in North West England. *J Med Genet* 1999;**36**:197-203.
66. **Woodruff JM**. Pathology of tumors of the peripheral nerve sheath in type 1 neurofibromatosis. *Am J Med Genet* 1999;**89**:23-30.

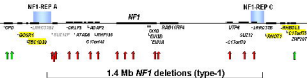


Figure 1

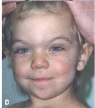
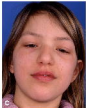
Figure 2

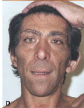



Figure 3