HAL
open science

Experimental microablation of choroidal tissue for autologous retinal pigmentepithelium-choroid translocation with the pulsed electron avalanche knife (PEAK-fc).

Felix Treumer, Benjamin Sattler, Arnd Bunse, Alexa Klettner, Jost Hillenkamp, Johann Roider

To cite this version:

Felix Treumer, Benjamin Sattler, Arnd Bunse, Alexa Klettner, Jost Hillenkamp, et al.. Experimental microablation of choroidal tissue for autologous retinal pigmentepithelium-choroid translocation with the pulsed electron avalanche knife (PEAK-fc).. British Journal of Ophthalmology, 2010, 94 (10), pp.1378. 10.1136/bjo.2009.175596 . hal-00557355

HAL Id: hal-00557355

https://hal.science/hal-00557355v1

Submitted on 19 Jan 2011

HAL is a multi-disciplinary open access archive for the deposit and dissemination of scientific research documents, whether they are published or not. The documents may come from teaching and research institutions in France or abroad, or from public or private research centers.

L'archive ouverte pluridisciplinaire **HAL**, est destinée au dépôt et à la diffusion de documents scientifiques de niveau recherche, publiés ou non, émanant des établissements d'enseignement et de recherche français ou étrangers, des laboratoires publics ou privés.

Experimental microablation of choroidal tissue for autologous retinal pigmentepithelium-choroid translocation with the pulsed electron avalanche knife (PEAK-fc).

Felix Treumer, MD, Benjamin Sattler, MD, Arnd Bunse, MD, Alexa Klettner, PhD, Jost Hillenkamp, MD, Johann Roider, MD

Department of Ophthalmology, University Medical Center Schleswig-Holstein, Campus Kiel, Germany

Key words: RPE transplantation, pulsed electron avalanche knife PEAK-fc, choroidal ablation, AMD

Corresponding author:
Felix Treumer, MD
Department of Ophthalmology, University Medical Center Schleswig-Holstein
Arnold-Heller Str. 3, Haus 25, D-24105 Kiel, Germany
Tel.: 0049-431-5972360 Fax: 0049-431-5972428
Email: ftreumer@auge.uni-kiel.de

Abstract

Aim: To test the microablation of excess graft choroidal tissue with the pulsed electron avalanche knife (PEAK-fc) in an in-vitro model of autologous retinal pigment epithelium (RPE)-choroid translocation.

Methods: Choroidal tissue of porcine RPE-choroid explants was ablated with the PEAK-fc. Tissue morphology was assessed by light microscopy (LM) and scanning electron microscopy (SEM). The amount of ablated choroidal tissue was analysed as a function of three PEAK-fc parameters: (1) amplitude of biphasic voltage (70-100%), (2) distance between choroidal tissue and tip of the PEAK-fc (0-300 µm), (3) exposure time (2-8 s).

Results: LM and SEM showed a smooth plain within the ablation area with well defined cutting edges and preserved adjacent tissue structure. The mean amount of ablated tissue correlated linearly with (1) applied voltage (range: 79 to 120 µm, r=0.34) and (2) distance between choroidal tissue and PEAK-fc tip (range: 10 to 100 µm, r=0.74). (3) The mean amount of ablated tissue increased with exposure time between 2 and 4 s (36 to 88 µm, r=0.4) and remained constant between 4 and 8 s.

Conclusion: The PEAK-fc accurately microablates choroidal tissue in-vitro. The adjacent choroidal tissue structure and Bruch`s membrane are preserved. Patient studies are required to test the PEAK-fc in RPE-choroid translocation surgery.

Introduction

The currently most widely applied treatment of exudative age related macular degeneration is based on anti-vascular endothelia growth factor (VEGF) agents. However, in certain cases of neovascular AMD treatment with anti-VEGF agents cannot be applied, e.g. massive subretinal hemorrhage or tears of the retinal pigment epithelium (RPE). Affected patients suffer severe loss of vision due to scarring of the subretinal tissue or degeneration of the photoreceptors secondary to the lack of support of an intact subfoveal RPE layer. One possibility to restore a functioning RPE layer is the surgical excision of the underlying choroidal neovascular membrane (CNV) followed by translocation of an autologous peripheral RPE-choroid patch to the subfoveal area.[1-6] Although retinal function was detected over these grafts visual outcome often remained unsatisfactory and the long-term survival of the graft is often limited.[7] This may in part be due to a co-translocation of large amounts of choroidal tissue together with Bruch's membrane and the RPE. As conventional RPE-choroid grafts contain more than 90% choroidal tissue in vertical dimension, the graft choroid may be expected to increase the path length of diffusion of oxygen and nutrients between what little is left of functionally intact macular choroid and the overlying outer retina.[8] However, the underlying premise of excess graft choroid as a barrier to the diffusion of nutrients is a reasonable hypothesis but the hypothesis has so far not been experimentally tested. Connections between macular and graft choroidal vessels with resulting graft perfusion have been demonstrated by angiography studies.[9] A second hypothesis is that in cases with insufficient revascularisation, fibrosing graft choroidal tissue may form a diffusion barrier between functionally intact choroid and translocated RPE resulting in graft failure and loss of visual function. The pulsed electron avalanche knife (PEAK-fc) is an electrosurgical device suitable for intraoperative tractionless preparation of intraocular structures such as epiretinal membranes, e.g. in proliferative vitreoretinopathy or proliferative diabetic retinopathy.[10-12] The PEAK-fc works by the induction of plasma in conductive medium generated by microsecond pulses of a high electric field leading to a dissection and ablation of tissue at close proximity of the 50 µm wire microelectrode. As the pulses do not exceed 100 µs in duration the heat diffuses to the surrounding tissue only up to 7 µm inducing only little collateral thermal damage.[13]

The aim of this study was to investigate in-vitro efficacy and safety of tissue ablation with the PEAK-fc knife to reduce the amount of graft choroidal tissue in RPE-choroid translocation surgery.

Materials and methods

Tissue ablation

The anterior segment and vitreous of freshly enucleated porcine eyes was removed. The sclera was carefully dissected from the RPE-choroid layer using microsurgical scissors and forceps. The retina was removed and the RPE-choroid explant was pinned with the RPE facing down on a microfibre cloth and was then fixed to a cork board in 0,9 % sodium chloride solution.The tissue was viewed under a surgical microscope and the PEAK-fc (Carl Zeiss Meditec, Jena, Germany) was fixed in a micromanipulator to precisely adjust the distance between the surface of the choroidal tissue and the PEAK probe during the ablation process. To identify the treated areas in the histological cross sections, these regions were marked with a marker pen (WAK-Chemistry, Bad Homburg, Germany). To simulate the intraoperative situation choroidal tissue was ablated handheld with smooth, sweeping movements in a second set of experiments.

We analysed the thickness of the ablated choroidal tissue (µm) as a function of the following PEAK-fc parameters: (1) amplitude of the biphasic voltage (displayed as percent of the maximum value of 600 V), (2) exposure time (2 – 8 s), and (3) distance between the surface of the choroidal tissue and the tip of the PEAK-fc (0 – 300 µm). In preliminary ablation experiments using porcine choroidal tissue we established standard values for the following parameters: voltage 90%, exposure time 8 seconds, distance 100 µm, repetition rate 100 Hz, and 20 pulses per burst. In the present study we altered either voltage, exposure time, or distance each experiment while the other four parameters were set to standard. Each parameter was tested 6 to 29 times. The same investigator ablated the tissue and measured ablation depth in the histological cross sections (BS).

Visual control of the ablation

To evaluate if the depth of the ablation can be visually assessed we developed a visual score system: 0 = no ablation assumed, 1 = change of tissue colour, 2 = light ablation, 3 = medium ablation, 4 = strong ablation assumed. Using this score system we estimated the depth of the ablation during the ablation procedure and compared these estimated values to the measured ablation depth in the paraffin sections.

Light microscopy (LM) and scanning electron microscopy (SEM)

For LM the RPE-choroid explants were fixed in 4% formaldehyde, dehydrated in a graded series of ethanol and embedded in paraffin. 3 µm sections were stained with hematoxylin-eosin and examined with light microscopy. Digital images were obtained with the AxioCamMRc5 (Zeiss, Jena, Germany) and the thickness of the ablated choroidal tissue was analysed by manual positioning of markers at the bottom of the ablation and at the edge of the ablation using the software AxioVisionAC, version 4.1 (Zeiss, Jena, Germany).

For SEM the tissue was fixed for 24 hours in 3% glutaraldehyde and rinsed with phosphate buffered saline over night. The tissue was postfixed in 1% osmium tetroxide for 90 min and dehydrated in a graded series of ethanol. The tissue was dried with CO_2 in the Critical Point Dryer (Blazer, Lichtenstein) and sputter-coated with gold followed by digital image acquisition.

Statistical methods

In the statistical analysis the type I error (alpha) was set at 0.05. The correlation between voltage (% of maximum), exposure time (s), and distance (µm) and the thickness of ablated choroidal tissue (µm) was assessed with the Spearman rho and Kendall tau b correlation coefficients. The results were statistically analysed using SPSS 15.0 software (SPSS Inc., Chicago, IL, USA).

Results

Tissue ablation

Parameter “voltage”:

The mean amount of ablated tissue increased linearly with the applied voltage. The application of 70% of the maximal voltage (n=10) produced a mean ablation of 79 µm (SD ±27). 80% of voltage (n=11) lead to a mean ablation of 98 µm (SD ±16), 90% of voltage (n=29) resulted in a mean ablation of 111 µm (SD ±48) and maximal voltage (100%, n=10) produced a mean ablation of 120 µm (SD ±24). The correlation coefficient Spearman rho was 0.34, p=0.007, Kendall tau was 0.26, p=0.01 (Fig. 1).

Parameter “distance”:

The greatest amount of choroidal tissue was ablated when the tip had direct contact to the choroidal tissue (mean ablation 100 µm (SD ±49), n=29). The amount of ablated tissue decreased linearly to 65 µm (SD ±25) at a distance of 100 µm (n=9), to 49 µm (SD ±33) at a distance of 200 µm (n=8) and to 9 µm (SD ±11) ablation depth at a distance of 300 µm (n=9). Spearman rho was calculated 0.74, p=0.01, Kendall tau was 0.6, p=0.01 (Fig. 2).

Parameter “exposure time”:

Increasing the exposure time from 2 (n=6) to 4 (n=11) seconds increased the mean tissue ablation from 36 µm (SD ±15) to 88 µm (SD ±33). Spearman rho 0.4, p=0.01, Kendall tau 0.3, p=0.01. Longer exposure time (6 s (n=10) and 8 s (n=19)) did not result in a significant increase of tissue ablation (Fig. 3).

Visual control of the ablation

The visually estimated ablation depth correlated linearly with the ablation depth determined by histology (Spearman rho = 0.69, p=0.01). When no tissue ablation (score = 0) was estimated, the mean histological ablation was 10 µm (SD ±11), score 1 revealed mean ablation of 38 µm (SD ±27), score 2 corresponded to mean ablation of 62 µm (SD ±25), score 3 corresponded to 91 µm (SD ±35) ablation and score 4 revealed 120 µm (SD ±41) mean ablation depth in the histological cross sections (Fig. 4).

LM and SEM

Both LM and SEM showed sharp cutting edges and preserved adjacent tissue structure. Tissue ablation resulted in a smooth plain within the entire ablation area (Fig. 5).

To simulate the intraoperative situation we performed tissue ablation in a second set of experiments with the PEAK-fc handheld. A smooth ablation was achieved with gentle, sweeping movements of the probe wire of the PEAK-fc over the choroidal surface of the explants. We found that careful bending of the probe wire prevented entanglement of the wire with the choroidal loose connective tissue.

Discussion

The results of this study show that the PEAK-fc accurately ablates choroidal tissue of porcine RPE-choroid explants. SEM revealed well demarcated areas of ablation and a smooth plain within the entire ablation area. Smooth ablation was achieved when the PEAK-fc was fixed and also when it was moved over the choroidal surface of the explants handheld with gentle, sweeping movements. Significant thermal collateral damage was neither detected by LM nor by SEM. We did not perform in-vivo experiments but we used freshly enucleated porcine eyes with a post-mortem time of less than 6 hours. Therefore, the histologic findings are likely to be similar to the in-vivo situation. The amount of ablated tissue increased linearly with the applied voltage and decreased linearly with the distance between the tip of the knife and the tissue. The visually estimated amount of ablated tissue correlated well with LM histological measurements. The PEAK-fc works by the induction of plasma close to the microelectrode. Theoretically, extended exposure time cannot result in damage to tissue further distant from the electrode. Indeed, we found that the amount of ablated tissue increased with the exposure time between 2 and 4 s but remained unchanged when the exposure time was further extended. Intraoperatively, this mechanism could prevent inadvertent damage to deeper tissue layers such as Bruch`s membrane.

Hu and Zhang et al. abraded graft choroidal tissue in an in-vivo rabbit model with a sharp spatula. They found intact retina on debrided grafts indicating good functional support of the overlying retina.[14] Further experiments confirmed that partial thickness RPE-choroid grafts support photoreceptor cell survival and also initiate early repair mechanisms as exhibited by photoreceptor outer segment regeneration.[15] However, to abrade the choroidal tissue with a spatula is a comparatively rough procedure with limited accuracy exposing the graft to tractional forces and mechanical stress. The PEAK-fc allows gentler and more controlled ablation of choroidal tissue avoiding mechanical stress with traction and distortion. Intraoperatively, the PEAK-fc could possibly also be used to cut out the RPE-choroid graft. The device has previously been shown to produce effective and reproducible cuts of retinal tissue.[12] In accordance with our findings the PEAK-fc produced sharp edges and collateral coagulation damage could be reduced to minimal changes using pulse parameters within a range of 350-380 V, pulse repetition rate 300 Hz, pulse duration 100 µs, and 30 pulses per burst.

The PEAK-fc for ablation of choroidal tissue could be further improved. We found that careful bending of the probe wire prevented entanglement of the wire with the choroidal loose connective tissue. To address this problem a modification of the plasma knife with a blade-like electrode could be helpful: Palanker et al. developed a 12 µm thin foil electrode with insulated sides and an exposed edge. Flat sides of the electrode are coated with glass, leaving only the semi-cylindrical edge of the foil with a radius of curvature of 6 µm exposed to

the conductive physiological medium. Dimensions of the blade electrodes can be adjusted for different applications, e.g. for intraocular use 1 mm in length and 0.6 mm in width.[16] This semi-cylindrical shape may facilitate the intraoperative ablation of choroidal tissue.

During surgery the PEAK-fc knife has to be used inside the eye because removal of the graft for ablation would most likely lead to loss of RPE-cells and include a risk of graft infection. In this regard a potential drawback of the PEAK-fc is the formation of small gas bubbles during the operation. However, Priglinger et al. used the PEAK-fc to cut retina during vitrectomy and the amount of gas bubble formation was comparable to conventional intraocular diathermy[13;17] In none of the performed procedures the development of gas impaired vision to such a degree as to render surgery unsafe or impossible.

As an alternative method of tissue thickness reduction of RPE-choroid patches Holz et al. tested a 308 nm UV-B excimer laser. The laser cleanly and accurately separated choroidal tissue borders without thermal collateral damage in human donor eyes. However, due to the interindividual differences in tissue properties, a broad spectrum of laser energies had to be applied.[18] Furthermore, the method may be obsolete for clinical application because the laser induced apoptosis in human ARPE-19 cells at energy levels below the choroidal ablation threshold.[19]

In summary, the PEAK-fc accurately and reproducibly microablates choroidal tissue without significant collateral damage of adjacent tissue. The ablation depth is well controlled and extended exposure times do not lead to inadvertent damage of deeper tissue layers such as Bruch`s membrane. The PEAK-fc knife is a prototype. To our knowledge, the results of the present investigation and the cited work of others represent the currently available data on safety. As this experimental data is preliminary, extra caution should be applied when using the PEAK-fc knife in RPE-choroid patch translocation surgery.

Legends

Figure 1. Mean (±SD) amount of ablated choroidal tissue (µm) as a function of the PEAK-fc parameter “voltage” (displayed as percent of maximum values).

Figure 2. Mean (±SD) amount of ablated choroidal tissue (µm) in relation to the PEAK-fc parameter “distance” of the PEAK-fc tip from the tissue surface (0-300 µm).

Figure 3. Mean (±SD) amount of ablated choroidal tissue (µm) in relation to the PEAK-fc parameter “exposure time” (2 to 8 seconds).

Figure 4. Correlation of visually estimated choroidal ablation depth (score 0-4) with the ablation depth (µm) determined by histology.

Figure 5. **a)** Photomicrograph of hematoxylin-eosin stained section of choroidal tissue ablated with the PEAK-fc (voltage 90%, distance 0 µm, time: 8 s). The adjacent tissue appears well preserved. **b, c)** Photomicrographs of scanning electron microscope sections of ablations with different parameters of the PEAK-fc: b) voltage: 90%, distance: 100 µm, time: 2 s. The ablation area is well demarcated with shallow and constant deepening without irregularities. c) voltage: 90%, distance: 0 µm, time: 8 s. The ablation is deeper as compared to b) with a smooth ablation surface and well preserved adjacent tissue.

Reference List

1. Binder S, Krebs I, Hilgers RD, Abri A, Stolba U, Assadoulina A et al. Outcome of transplantation of autologous retinal pigment epithelium in age-related macular degeneration: a prospective trial. *Invest Ophthalmol Vis Sci* 2004;**45**:4151-60.

2. MacLaren RE, Uppal GS, Balaggan KS, Tufail A, Munro PM, Milliken AB et al. Autologous transplantation of the retinal pigment epithelium and choroid in the treatment of neovascular age-related macular degeneration. *Ophthalmology* 2007;**114**:561-70.

3. van Meurs JC, van den Biesen PR. Autologous retinal pigment epithelium and choroid translocation in patients with exudative age-related macular degeneration: short-term follow-up. *Am J Ophthalmol* 2003;**136**:688-95.

4. Heussen FM, Fawzy NF, Joeres S, Lux A, Maaijwee K, Meurs JC et al. Autologous translocation of the choroid and RPE in age-related macular degeneration: 1-year follow-up in 30 patients and recommendations for patient selection. *Eye* 2008;**22**:799-807.

5. Treumer F, Bunse A, Klatt C, Roider J. Autologous retinal pigment epithelium-choroid sheet transplantation in age related macular degeneration: morphological and functional results. *Br J Ophthalmol* 2007;**91**:349-53.

6. Maaijwee K, Joussen AM, Kirchhof B, van Meurs JC. Retinal pigment epithelium (RPE)-choroid graft translocation in the treatment of an RPE tear: preliminary results. *Br J Ophthalmol* 2008;**92**:526-9.

7. MacLaren RE, Bird AC, Sathia PJ, Aylward GW. Long-term results of submacular surgery combined with macular translocation of the retinal pigment epithelium in neovascular age-related macular degeneration. *Ophthalmology* 2005;**112**:2081-7.

8. Ramrattan RS, van der Schaft TL, Mooy CM, de Bruijn WC, Mulder PG, de Jong PT. Morphometric analysis of Bruch's membrane, the choriocapillaris, and the choroid in aging. *Invest Ophthalmol Vis Sci* 1994;**35**:2857-64.

9. Maaijwee K, van den Biesen PR, Missotten T, van Meurs JC. Angiographic evidence for revascularization of an rpe-choroid graft in patients with age-related macular degeneration. *Retina* 2008;**28**:498-503.

10. Palanker DV, Miller JM, Marmor MF, Sanislo SR, Huie P, Blumenkranz MS. Pulsed electron avalanche knife (PEAK) for intraocular surgery. *Invest Ophthalmol Vis Sci* 2001;**42**:2673-8.

11. Palanker DV, Marmor MF, Branco A, Huie P, Miller JM, Sanislo SR et al. Effects of the pulsed electron avalanche knife on retinal tissue. *Arch Ophthalmol* 2002;**120**:636-40.

12. Priglinger SG, Haritoglou C, Palanker DV, Alge CS, Gandorfer A, Kampik A. Pulsed electron avalanche knife (PEAK-fc) for dissection of retinal tissue. *Arch Ophthalmol* 2005;**123**:1412-8.

13. Priglinger SG, Palanker D, Alge CS, Kreutzer TC, Haritoglou C, Grueterich M et al. Pulsed electron avalanche knife: new technology for cataract surgery. *Br J Ophthalmol* 2007;**91**:949-54.

14. Hu Y, Zhang T, Wu J, Li Y, Lu X, Qian F et al. Autologous transplantation of RPE with partial-thickness choroid after mechanical debridement of Bruch membrane in the rabbit. *Invest Ophthalmol Vis Sci* 2008;**49**:3185-92.

15. Zhang T, Hu Y, Li Y, Wu J, Zhao L, Wang C et al. Photoreceptors repair by autologous transplantation of retinal pigment epithelium and partial-thickness choroid graft in rabbits. *Invest Ophthalmol Vis Sci* 2009;**50**:2982-8.

16. Palanker DV, Vankov A, Huie P. Electrosurgery with cellular precision. *IEEE Trans Biomed Eng* 2008;**55**:838-41.

17. Priglinger SG, Haritoglou C, Mueller A, Grueterich M, Strauss RW, Alge CS et al. Pulsed electron avalanche knife in vitreoretinal surgery. *Retina* 2005;**25**:889-96.

18. Holz FG, Bindewald A, Schutt F, Specht H. Intraocular microablation of choroidal tissue by a 308 nm AIDA excimer laser for RPE-transplantation in patients with age-related macular degeneration. *Biomed Tech (Berl)* 2003;**48**:82-5.

19. Krohne TU, Hunt S, Holz FG. Effect of 308 nm excimer laser irradiation on retinal pigment epithelium cell viability in vitro. *Br J Ophthalmol* 2009;**93**:91-5.

The Corresponding Author has the right to grant on behalf of all authors and does grant on behalf of all authors, an exclusive licence (or non exclusive for government employees) on a worldwide basis to the BMJ Publishing group Ltd to permit this article (if accepted) to be published in BJO and any other BMJPGL products and sublicenses such use and exploit all subsidiary rights, as set out in our licence.

Competing interest: None declared.

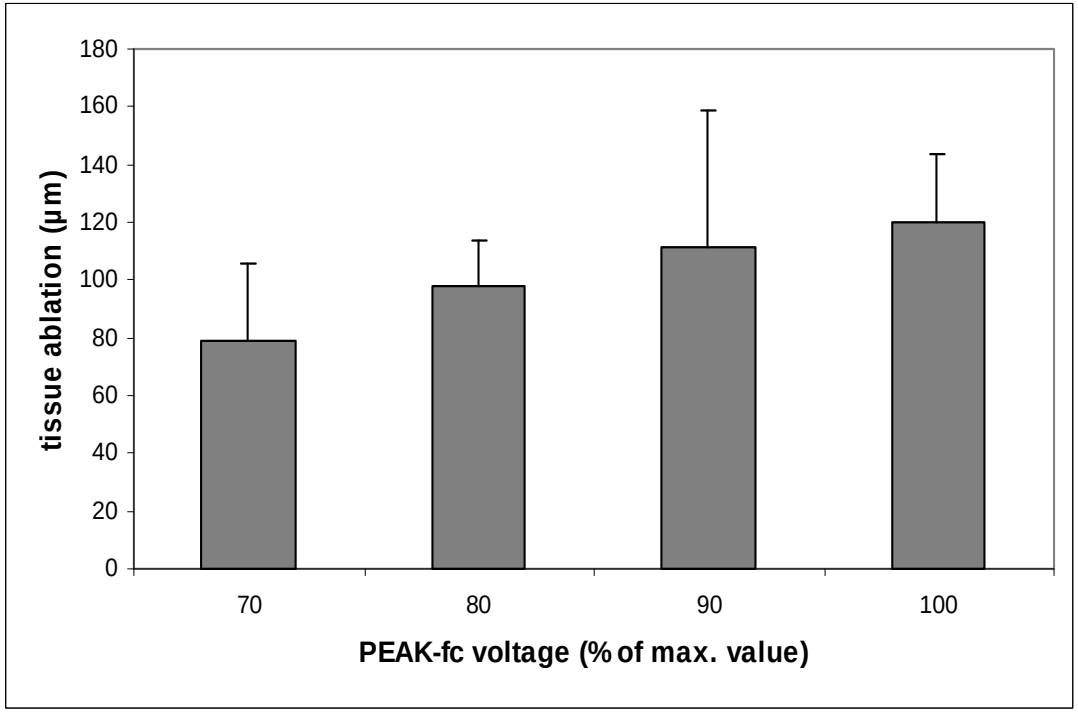
180
160
140
120
100
80
60
40
20
0
tissue ablation (µm)
70
80
90
100
PEAK-fc voltage (% of max. value)

Figure 1

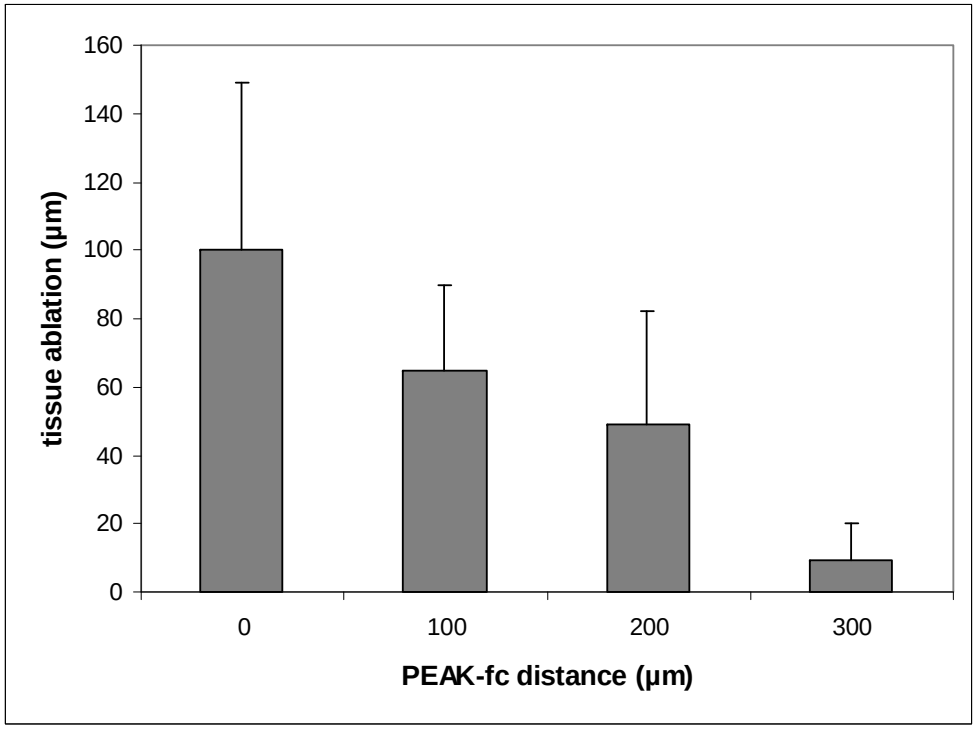
160
140
120
100
80
60
40
20
0
tissue ablation (µm)
0
100
200
300
PEAK-fc distance (µm)

Figure 2

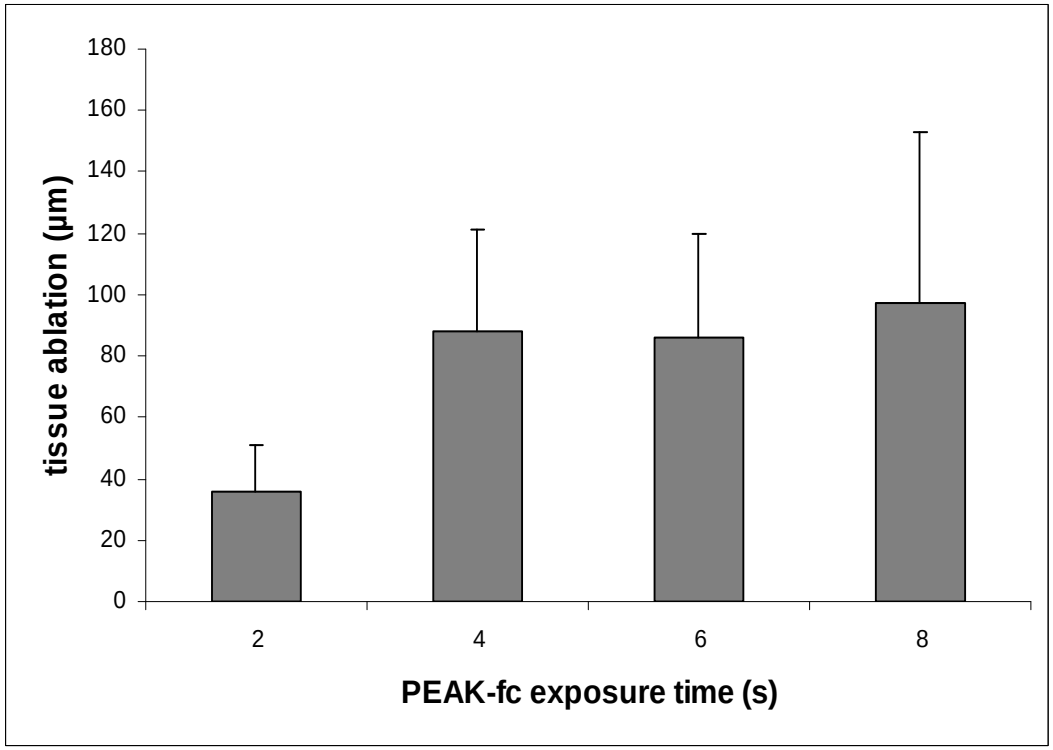
180
160
140
120
100
80
60
40
20
0
tissue ablation (µm)
2
4
6
8
PEAK-fc exposure time (s)

Figure 3

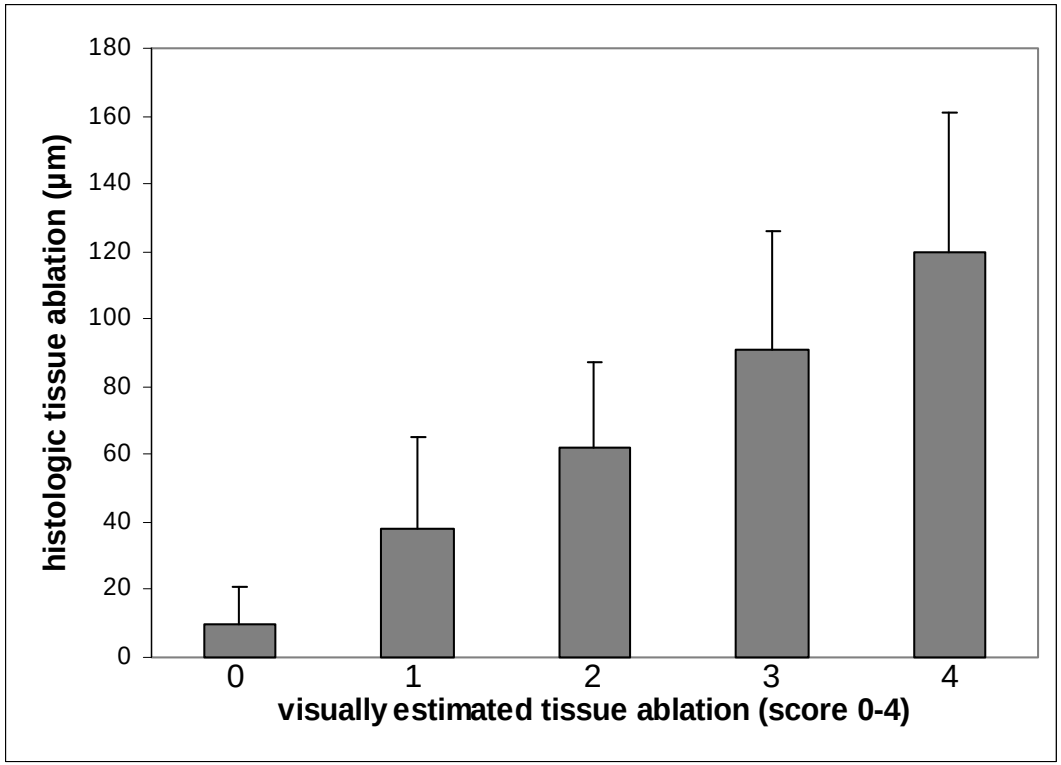
180
160
140
120
100
80
60
40
20
0
histologic tissue ablation (µm)
0
1
2
3
4
visually estimated tissue ablation (score 0-4)

Figure 4


a
117 µm
b
Acc.V Spot Magn WD 100 µm
15.0 kV 3.0 200x 8.7
c
Acc.V Spot Magn Det WD 100 µm
15.0 kV 4.0 200x SE 8.8

Figure 5