



HAL
open science

Ophthalmic, clinical and visual electrophysiological findings in children born to mothers prescribed substitute methadone in pregnancy

Ruth Hamilton, Laura Mcglone, Jane R Mackinnon, Heather C Russell,
Michael S Bradnam, Helen Mactier

► To cite this version:

Ruth Hamilton, Laura Mcglone, Jane R Mackinnon, Heather C Russell, Michael S Bradnam, et al.. Ophthalmic, clinical and visual electrophysiological findings in children born to mothers prescribed substitute methadone in pregnancy. *British Journal of Ophthalmology*, 2010, 94 (6), pp.696. 10.1136/bjo.2009.169284 . hal-00557336

HAL Id: hal-00557336

<https://hal.science/hal-00557336>

Submitted on 19 Jan 2011

HAL is a multi-disciplinary open access archive for the deposit and dissemination of scientific research documents, whether they are published or not. The documents may come from teaching and research institutions in France or abroad, or from public or private research centers.

L'archive ouverte pluridisciplinaire **HAL**, est destinée au dépôt et à la diffusion de documents scientifiques de niveau recherche, publiés ou non, émanant des établissements d'enseignement et de recherche français ou étrangers, des laboratoires publics ou privés.

Ophthalmic, clinical and visual electrophysiological findings in children born to mothers prescribed substitute methadone in pregnancy

Hamilton R¹, McGlone L², MacKinnon JR³, Russell HC³, Bradnam MS¹, Mactier H²

1. Clinical Physics, Royal Hospital for Sick Children, Dalnair Street, Glasgow, UK
2. Paediatrics, Princess Royal Maternity, Alexandra Parade, Glasgow, UK
3. Ophthalmology, Royal Hospital for Sick Children, Dalnair Street, Glasgow, UK

Keywords: electrophysiology; drug misuse; methadone; nystagmus

Word count: 2160

Abstract

Background and aims: There are growing concerns regarding visual outcome of infants exposed to opiates (including substitute methadone) and/or benzodiazepines *in utero*. We describe the combined ophthalmology and visual electrophysiology findings in 20 infants and children who had been exposed to substitute methadone and other drugs of misuse *in utero*.

Methods: This was a descriptive case series of 20 patients, all of whom had been referred to a paediatric visual electrophysiology service because of concerns regarding visual function, and all of whom had been exposed to methadone *in utero*. All children underwent a full ophthalmic and orthoptic examination as well as visual electrophysiology testing deemed appropriate on an individual basis. A review was undertaken of paediatric case notes and of maternal antenatal urine toxicology.

Results: Ophthalmic abnormalities included reduced acuity (95%), nystagmus (70%), delayed visual maturation (50%), strabismus (30%), refractive errors (30%), and cerebral visual impairment (25%). Visual electrophysiology was abnormal in 60%. A quarter of the children had associated neurodevelopmental abnormalities. The majority of children with nystagmus (79%) had been treated for neonatal abstinence syndrome (NAS).

Conclusion: Infants born to drug-misusing mothers prescribed methadone in pregnancy are at risk of a range of visual problems, the underlying causes of which are not clear. Those infants with NAS severe enough to receive pharmaceutical treatment may be at particular risk of developing nystagmus. The inclusion of visual electrophysiology in comprehensive visual assessment of children exposed to substance misuse *in utero* may help to clarify the underlying causes by differentiating abnormalities of retinal and cortical origin.

Introduction

Drug misuse in pregnancy is a significant problem which has both short and long term adverse consequences for the unborn child¹⁻⁴. Methadone, a synthetic opioid, has higher oral bio-availability than most opioids, long duration of action and less misuse potential⁵. It is commonly prescribed as a substitute for illicit opioids such as heroin, and is associated with more stable maternal lifestyle as well as reduced incidence of both intra-uterine growth restriction⁶ and preterm birth^{1;7} compared with non-treated heroin addicts. However, prescribed methadone is also associated with neonatal abstinence syndrome (NAS) in a majority of newborns, with symptoms severe enough to require pharmacological treatment in 45-80% of those^{2;8}.

The visual system is sensitive to adverse prenatal events, showing characteristic abnormalities after *in utero* exposure to alcohol and cocaine. A high incidence of strabismus has been associated with prenatal exposure to methadone⁴, and nystagmus in children born to drug-addicted mothers is being increasingly recognised^{3;4}. Delayed visual development has also been reported^{3;4}.

Visual evoked potentials (VEPs) from adults receiving methadone were delayed relative to controls⁹. Electrophysiological data available so far from infants following *in utero* exposure to methadone show abnormal, smaller or slower VEPs after exposure relative to controls^{10;11}. Three cases of older children (aged 4 years (N=2) and 12 years) reported normal flash VEPs⁴.

We describe clinical, ophthalmological and visual electrophysiological findings in 20 children exposed to methadone and other drugs of misuse *in utero*.

Methods

This was a retrospective descriptive case series of children referred to a national paediatric visual electrophysiology service because of concerns regarding visual function and who had also been exposed *in utero* to methadone. Appropriate electrophysiological investigations were undertaken depending on the age of the child and presenting symptoms. Pattern-reversal VEPs were recorded to a black-and-white checkerboard at 100% contrast, mean luminance 60cdm⁻², subtending 30°×24° and presented at 1.1Hz. Pattern-onset VEPs were recorded to a black-and-white checkerboard at 100% contrast, interleaved with an isoluminant grey screen, subtending 30°×24° and presented at 1.1Hz. Flash VEPs were recorded to a hand-held diffuse flash with a time-integrated luminance of 11.7 cd s m⁻². In order to estimate acuity, step VEPs were recorded to black-and-white reversing checks using real-time analysis and a successive approximation algorithm to find spatial thresholds¹².

All children also underwent ophthalmological and orthoptic review, often on several occasions, which included cover tests, ocular motility, cycloplegic refraction, and dilated fundoscopy. Visual acuity was assessed using age-appropriate tests; some subjects were unable to co-operate with behavioural acuity tests and step VEP acuity assessment was used instead. Delayed visual maturation was a retrospective diagnosis in babies with visual behaviour which was poorer than expected from their

postnatal age but which improved by six months of age. Structured history taking was used for older children to seek evidence of cerebral visual impairment (CVI)¹³.

Paediatric and neonatal case notes were reviewed, and details obtained regarding maternal antenatal urine toxicology when available. Subjects were excluded from the case series if they had been born before 32 weeks gestation or had another diagnosis which could potentially account for their visual abnormalities such as foetal alcohol syndrome or significant birth asphyxia.

Results Twenty children met the inclusion criteria. All children had been exposed to prescribed substitute methadone *in utero* and a majority had also been exposed to illicit drugs, most commonly benzodiazepines (11/20, 55%) and heroin (8/20, 40%). Drug exposure as determined from case notes and urine toxicology is shown in Table 1. Twelve infants (60%) received pharmacological treatment for NAS. Age at first electrophysiology assessment ranged from 3 months to 7 years.

Ocular and visual electrophysiological findings are shown in Table 2. The most common abnormalities demonstrated were reduced acuity (19/20, 95%), nystagmus (14/20, 70%), delayed visual maturation (10/20, 50%), strabismus (7/20, 35%) and refractive errors (6/20, 30%). Fundal examination was abnormal in two cases – one case had bilateral abnormal blood vessels crossing the macula which showed regression at five months of age, and the other had slight pallor of both optic discs. Five children (25%) had significant neurodevelopmental problems (developmental delay in four, cerebral palsy in one): three of these five (patients 2, 13 and 19) had CVI and one (patient 12) had a delayed flash VEP. CVI was found in a further two cases, giving an overall incidence of CVI of 5/20 (25%).

Eleven of those 12 infants (92%) who had received pharmacological treatment for NAS demonstrated nystagmus, whilst only three of the eight infants (38%) who had not developed NAS severe enough to require treatment had nystagmus. This represents a significant difference (Fisher exact test, $P=0.018$) which was not evident for any of the other abnormalities. Nystagmus was horizontal in nature with the majority having a pendular wave-form although one patient exhibited a jerk type pattern. The observed characteristics of the nystagmus varied in being manifest, latent, or manifest with a latent component. Interestingly, patient 13 initially had manifest latent nystagmus which developed with time into latent nystagmus alone.

Twelve patients (60%) had abnormal visual electrophysiology. One of these (patient 11) had a reduced amplitude cone and flicker ERG, but normal fundus and normal pattern-onset VEP to 60' checks. All other ERGs recorded were normal ($N=13$). Flash VEPs were recorded from 11 patients, and were normal in eight (73%) and delayed in three cases (patients 5, 10 and 12 (Figure 1A)). An abnormal flash VEP was associated with a history of NAS and with nystagmus. Pattern-reversal VEPs were recorded from six patients and were normal in two cases but delayed or absent in four cases (patients 5, 9 (Figure 1B), 17 (Figure 1C) and 20). Pattern-onset VEPs were recorded in six cases, and were normal in five (e.g. Figure 1D, patient 17) but delayed in one (patient 5). Eleven subjects had their visual acuity estimated using the step VEP; in nine cases (82%), acuity was abnormal for

age. These acuity estimates agreed with contemporary behavioural acuity assessments in all nine cases where both were available.

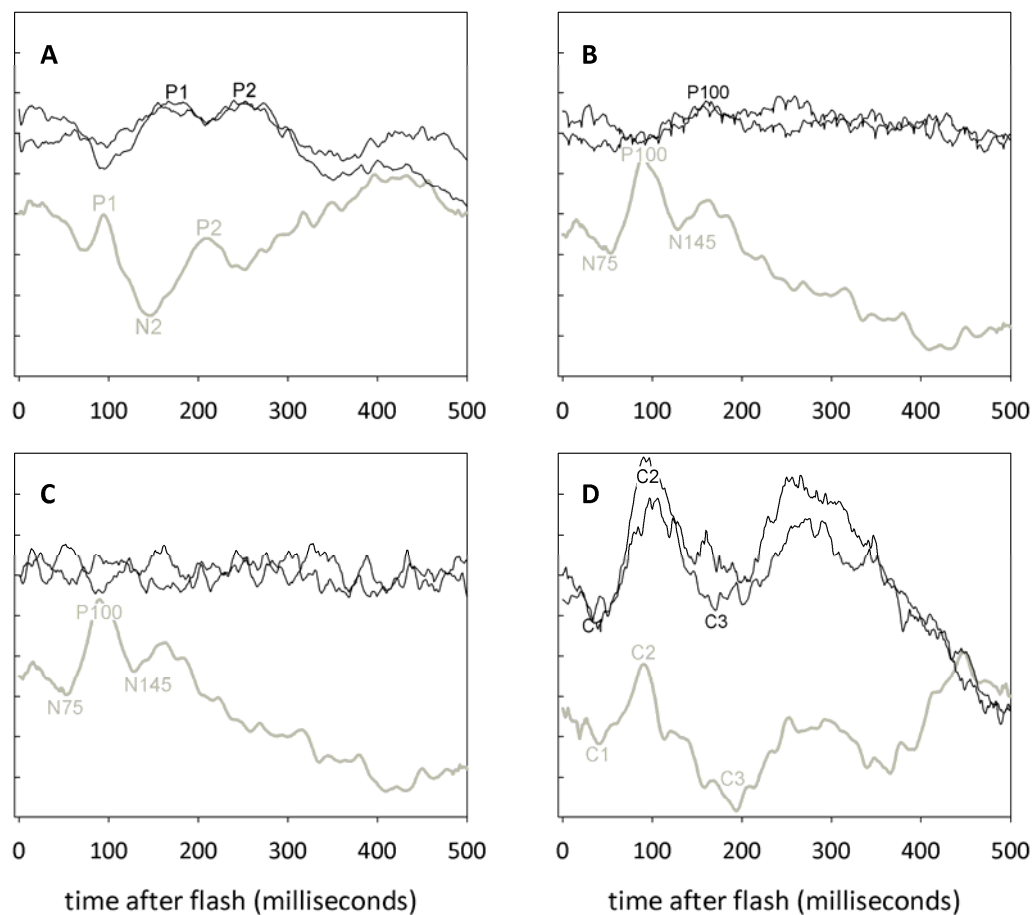


Figure 1: Examples of VEPs from three patients. A: flash VEP from subject 12, showing small, delayed peaks. B: Pattern reversal VEP (60' checks) from subject 9, showing small, delayed peak. C: absent pattern reversal VEP (60' checks) from subject 17; in contrast, D shows normal pattern-onset (60' checks) from the same subject. In all frames, control recordings from age-matched normal infants or children are shown in grey below the patients' trace.

Discussion Despite increasing awareness of risks to the unborn child from substance misuse in pregnancy, the incidence of maternal drug misuse is rising: anonymous screening in a UK clinic suggested that 11–16% of expectant women use at least one illicit substance during pregnancy¹⁴. The most commonly misused substances in the UK are opiates, although the use of cocaine is increasing. There are an estimated 250,000 to 350,000 children of problem drug users in the UK alone¹⁵, who represent a substantial burden to health, social and educational services². As with Mulvihill *et al* (2007)⁴, our report was prompted by an awareness of a history of *in utero* methadone exposure in an increasing number of patients referred because of visual problems.

A high proportion (11/14, 79%) of the children who presented with nystagmus in this case series had significant NAS. This is higher than reported elsewhere (7/14 (50%)⁴), but supports the overall

picture of an association of nystagmus with NAS. Nystagmus has a higher incidence (3/72 (4%))³ in the general drug-exposed population (i.e. not children referred because of eye problems) than in the population at large (24 per 10,000)¹⁶.

It has been proposed that infantile nystagmus could be caused by visual deprivation, resulting in oculomotor development outpacing sensory development¹⁷, and it is certainly possible that the children reported here may have experienced sensory delay or deficit as infants. An alternative explanation is abnormal μ -opioid receptor binding in the developing brainstem⁴. Steadiness of horizontal gaze is governed by a neural integrator which depends heavily on the nucleus prepositus hypoglossi and medial vestibular nucleus (MVN)¹⁸. The MVN contains μ -opioid receptors¹⁹, which are activated by opiates and by methadone. During development, opioid receptor activation inhibits proliferation and neuronal differentiation²⁰ while exposure to morphine *in utero* restricts cell proliferation and maturation²¹. It is possible that abnormal receptor binding in the developing neural integrator could provide a mechanism for nystagmus to develop. An association has been suggested between additional benzodiazepine exposure *in utero* and nystagmus⁴, but this was not found in our case series (Fisher exact test, $p=0.62$).

Disruption of coordinated binocular vision early in life leads to strabismus and varying degrees of amblyopia, with the extent of impairment dependent on the onset time, duration and type of visual deprivation²². One third of children in the current study had strabismus, much higher than in a similarly-aged general population (1.3%)²³. The proportions of children in the current study with strabismus who had significant NAS and who had no NAS are not statistically different (4/12 (33%) versus 3/8 (37%), Fisher exact test, $p=1$).

Abnormal visual electrophysiology was a frequent finding. Reduced step VEP acuity was consistent with reduced acuity from contemporary behavioural acuity assessments. The VEP is a cortically generated response to stimulation of the central visual field; prolonged latencies and reduced amplitudes are associated with neural demyelination and axonal loss respectively. Delayed or absent peaks of flash and pattern VEPs were noted in this study, consistent with findings noted in the neonatal period¹⁰; the latter study suggests a pre-natal cause. Pattern-reversal VEPs were abnormal in 4/6 cases while pattern-onset VEPs were abnormal in only 1/6 cases, consistent with the presence of nystagmus. However, one patient (5) had delayed pattern-reversal VEPs despite absence of nystagmus. It is possible that the pattern VEP delay is related to methadone exposure¹¹: both acute and maintenance methadone treatment delay the pattern-reversal VEP in adults^{9;11;24}. Opioid signalling plays a role in myelination and axonal growth, which could affect VEP latency²⁵.

There were very few abnormal fundi findings suggesting that posterior visual pathway dysfunction is important. Cerebral visual impairment was diagnosed in 25% of these children, but this is likely to be a substantial underestimate as CVI is commonly diagnosed around school entry age.

This entire cohort had been exposed to methadone *in utero*, but also to the many associated adversities, including physical and mental ill health, poor nutritional status¹ and excessive alcohol consumption¹. We cannot be certain whether the visual abnormalities described are secondary to

substitute methadone, ongoing illicit maternal opiate and/or benzodiazepine misuse, pharmacological agents (including oral morphine solution and/or phenobarbitone) used to treat NAS, or other as yet unidentified factors. The difficulties inherent in following children of vulnerable families means that it is likely that this group of infants is representative of a larger population of methadone-exposed children who have similar but undiagnosed ophthalmic problems.

Conclusion Infants born to drug-misusing mothers prescribed methadone in pregnancy are at risk of a range of visual problems, the underlying causes of which are not clear. Those infants who receive treatment for NAS may be at particular risk of developing nystagmus. Abnormalities occur at all stages of the visual pathway, and the inclusion of visual electrophysiology in comprehensive visual assessment of children exposed to substance misuse *in utero* may help to clarify the underlying causes by differentiating abnormalities of retinal and cortical origin. Controlled studies are necessary to delineate the effects of *in utero* drug exposure on visual outcomes.

Acknowledgements: We thank Professor Gordon Dutton for helpful comments on the manuscript. LMcG was funded by the Yorkhill Children's Foundation.

Competing interest: none declared.

The Corresponding Author has the right to grant on behalf of all authors and does grant on behalf of all authors, an exclusive licence (or non-exclusive for government employees) on a worldwide basis to the BMJ Publishing Group Ltd and its Licensees to permit this article (if accepted) to be published in BJO and any other BMJ PGL products to exploit all subsidiary rights, as set out in our licence.

Table 1: Drug exposure and systemic findings

patient no.	gestation (weeks)	methadone	heroin	BDZ	other drugs	alcohol	treatment for NAS	other diagnoses	brain scans
1	38	✓							
2	32	✓				✓		preterm, developmental delay	
3	39	✓		✓					
4	40	✓		✓	cannabis				
5	38	✓					✓		MRI: abnormal white matter
6	39	✓	✓				✓		
7	40	✓	✓	✓		✓	✓	mild cerebral palsy	
8	38	✓			cocaine		✓		CT normal
9	36	✓	✓	✓	cocaine		✓		MRI normal
10	34	✓		✓	cannabis		✓	preterm	
11	40	✓		✓	cannabis		✓		
12	35	✓	✓	✓	cannabis		✓	developmental delay, dysmorphic	
13	40	✓	✓				✓	developmental delay	
14	38	✓				✓			
15	36	✓		✓			✓		MRI normal
16	38	✓			antidepressants (not specified)				
17	41	✓	✓	✓			✓		
18	40	✓	✓	✓	cannabis		✓		
19	37	✓						developmental delay	MRI normal
20	39	✓	✓	✓	dihydrocodeine				

BDZ: benzodiazepines, NAS: neonatal abstinence syndrome, MRI: magnetic resonance imaging, CT computerised tomography.

Table 2: Ocular and electrophysiology findings

patient no.	VA at presentation (age, months)	most recent VA (age, months)	DVM	nystagmus	strabismus	refractive error	fundus	CVI	ERG	flash VEP	pattern reversal VEP	pattern onset VEP	step VEP acuity
1	momentary eye contact (3)	6/19, 6/19 (20)	✓		XT		normal		normal	normal			raised
2	6/12 BEO (14)	6/19, 6/15 (28)	✓				normal	✓			normal		raised
3	6/76 BEO (13)			✓			normal			normal			
4	6/48 BEO (6)	6/9.5 BEO (11)	✓				normal					normal	raised
5	6/38 BEO (7)	6/24 * BEO (25)		✓			normal		normal	delayed & small	abnormal	abnormal	
6	6/130 BEO (7)	6/9.5 BEO (20)	✓				normal		normal	normal			normal
7	6/19, 6/12 (63)			✓	ET		normal		normal			normal	
8		6/18 *, 6/15 * (48)		✓			normal		normal	normal			raised
9	6/76 BEO (6)	5/6, 5/6 (51)	✓	✓		HA	normal		normal	normal	absent		raised
10	6/30 by VEP (7)			✓	NK		normal			delayed		normal	raised
11	6/24 BEO (13)	6/24 BEO (18)		✓			normal		small			normal	
12	6/500 BEO (3)	6/120, 6/9.5 (35)	✓	✓	XT	MA (right eye only)	vessels across macula		normal	delayed			raised
13	Not f & f (2)	6/6, 6/6 (68)	✓	✓	possible MT		normal	✓			normal		
14	6/500 BEO (3)	6/9.5, 6/15 (46)	✓		XT	H	normal						raised
15	f & f (5)	6/12 *, 6/12 * (60)	✓	✓			normal	✓	normal	normal			
16	6/120 BEO (8)	3/18, 3/18, 3/12 BEO (45)		✓		HA	normal		normal	normal			raised
17	f but not f (3)	6/12 BEO (22)	✓	✓			normal		normal		absent	normal	
18	6/19, 6/15 * (71)			✓			normal	✓	normal				
19	6/24 BEO (27)	6/36 BEO (37)		✓	ET	HA	slight disc pallor	✓	normal	normal			
20	6/60, 6/13 (77)					A	normal		normal		delayed		raised

VA: visual acuity, f & f: fixing and following, BEO: both eyes open, DVM: delayed visual maturation, ET: esotropia, XT: exotropia, MT: microtropia, M: myopia, H: hypermetropia, A: astigmatism, CVI: cerebral visual impairment, ERG: electroretinogram, VEP: visual evoked potential. *VA in Snellen equivalent. For visual acuity, the age at test in months is given in brackets next to test findings.

1. Burns L, Mattick RP, Lim K, Wallace C. Methadone in pregnancy: treatment retention and neonatal outcomes. *Addiction* 2006;**102**:264-70.
2. Dryden C, Young D, Hepburn M, Mactier H. Maternal methadone use in pregnancy: factors associated with the development of neonatal abstinence syndrome and implications for healthcare resources. *British Journal of Obstetrics and Gynaecology* 2009;**116**:665-71.
3. Lloyd DJ and Myerscough EJ. Substance misuse research - neonatal abstinence syndrome. A new intervention: A community based, structured health visitor assessment. 2006. Scottish Executive Social Research Substance Misuse Research Programme.

Ref Type: Report

4. Mulvihill AO, Cackett PD, George ND, Fleck BW. Nystagmus secondary to drug exposure in utero. *British Journal of Ophthalmology* 2007;**91**:613-5.
5. Farid WO, Dunlop SA, Tait RJ, Hulse GK. The effects of maternally administered methadone, buprenorphine and naltrexone on offspring: review of human and animal data. *Current Neuropharmacology* 2008;**6**:125-50.
6. Hagopian GS, Wolfe HM, Sokol RJ, Ager JW, Wardell JN, Cepeda EE. Neonatal outcome following following methadone exposure in utero. *Journal of Maternal and Fetal Medicine* 1996;**5**:348-54.
7. Giles W, Patterson T, Sanders F, Batey R, Thomas D, Collins J. Outpatient methadone programme for pregnant heroin using women. *Australian and New Zealand Journal of Obstetrics and Gynaecology* 1989;**29**:225-9.
8. Farid WO, Dunlop SA, Tait RJ, Hulse GK. The effects of maternally administered methadone, buprenorphine and naltrexone on offspring: review of human and animal data. *Current Neuropharmacology* 2008;**6**:125-50.
9. Bauer LO. Effects of chronic opioid dependence and HIV-1 infection on pattern shift visual evoked potentials. *Drug and Alcohol Dependence* 1998;**50**:147-55.
10. McGlone L, Mactier H, Hamilton R, Bradnam MS, Boulton R, Borland W et al. Visual evoked potentials in infants exposed to methadone in utero. *Archives of Disease in Childhood* 2008;**93**:784-6.
11. Whitham JN, Spurrier N, Sawyer M, Baghurst PA, Taplin JE, White JM et al. The effects of prenatal exposure to buprenorphine or methadone on infant visual evoked potentials. *Neurotoxicology and Teratology* 2009;**doi:10.10.1016/j.ntt.2009.09.001**.
12. Mackay AM, Bradnam MS, Hamilton R, Dutton GN. Real time rapid acuity assessment using VEPs: development and validation of the 'step VEP' technique. *Investigative Ophthalmology and Visual Science* 2008;**49**:438-41.
13. Dutton GN. 'Dorsal stream dysfunction' and 'dorsal stream dysfunction plus': a potential classification for perceptual visual impairment in the context of cerebral visual impairment. *Developmental Medicine and Child Neurology* 2009;**51**:168-72.
14. Sherwood RA, Keating J, Kavvadia V, Greenough A, Peters TJ. Substance misuse in early pregnancy and relationship to fetal outcome. *European Journal of Pediatrics* 1999;**158**:488-92.
15. Hidden Harm. The report of the Inquiry by the Advisory Council on the Misuse of Drugs. 2003. London, UK Home Office.

Ref Type: Conference Proceeding

16. Sarvanathan N, Surendran M, Roberts E, Jain S, Thomas S, Shah N et al. The prevalence of nystagmus: The Leicestershire nystagmus survey. *Investigative Ophthalmology and Visual Science* 2009.
17. Harris C, Berry D. A developmental model of nystagmus. *Seminars in Ophthalmology* 2006;**21**:63-9.
18. Cannon SC, Robinson DA. Loss of the neural integrator of the oculomotor system from brain stem lesions in monkey. *J Neurophysiol* 1987;**57**:1383-409.
19. Lin Y, Carpenter DO. Direct excitatory opiate effects mediated by non-synaptic actions on rat medial vestibular neurons. *European Journal of Pharmacology* 1994;**262**:99-106.
20. Hauser KF, Houdi AA, Turbek CS, Elde RP, Maxson W. Opioids intrinsically inhibit the genesis of mouse cerebellar granule neuron precursors in vitro: differential impact of mu and delta receptor activation on proliferation and neurite elongation. *European Journal of Neuroscience* 2000;**12**:1281-93.
21. Seatriz JV, Hammer RP. Effects of opiates on neuronal development in the rat cerebral cortex. *Brain Research Bulletin* 1993;**30**:523-7.
22. Mustari MJ, Ono S, Vitorello KC. How disturbed visual processing early in life leads to disorders of gaze-holding and smooth pursuit. *Progress in Brain Research* 2008;**171**:487-95.
23. Friedman Z, Neumann E, Hyams SW, Peleg B. Ophthalmic screening of 38,000 children, age 1 to 2 1/2 years, in child welfare clinics. *Journal of Pediatric Ophthalmology & Strabismus*.17(4):261-7, 1980;-Aug.
24. Rothenberg S, Peck EA, Schottenfeld S, Betley GE, Altman JL. Methadone depression of visual signal detection performance. *Pharmacology, Biochemistry and Behavior* 1979;**11**:521-7.
25. Sanchez ES, Bigbee JW, Fobbs W, Robinson SE, Sato-Bigbee C. Opioid addiction and pregnancy: perinatal exposure to buprenorphine affects myelination in the developing brain. *Glia* 2008;**56**:1017-27.