



**HAL**  
open science

**Epistaxis or Epiphora as sign for extension of a conjunctival melanoma. A series of six patients with nasolacrimal recurrence.**

Guy S Missotten, Joel Gambrelle, Didi de Wolff-Rouendaal, Rob de Keizer

► **To cite this version:**

Guy S Missotten, Joel Gambrelle, Didi de Wolff-Rouendaal, Rob de Keizer. Epistaxis or Epiphora as sign for extension of a conjunctival melanoma. A series of six patients with nasolacrimal recurrence.. British Journal of Ophthalmology, 2010, 94 (10), pp.1328. 10.1136/bjo.2009.168823 . hal-00557335

**HAL Id: hal-00557335**

**<https://hal.science/hal-00557335>**

Submitted on 19 Jan 2011

**HAL** is a multi-disciplinary open access archive for the deposit and dissemination of scientific research documents, whether they are published or not. The documents may come from teaching and research institutions in France or abroad, or from public or private research centers.

L'archive ouverte pluridisciplinaire **HAL**, est destinée au dépôt et à la diffusion de documents scientifiques de niveau recherche, publiés ou non, émanant des établissements d'enseignement et de recherche français ou étrangers, des laboratoires publics ou privés.

# **Epistaxis or Epiphora as sign for extension of a conjunctival melanoma. A series of six patients with nasolacrimal recurrence.**

G.S. Missotten<sup>1,2,3</sup>, MD, PhD, FEBO, J. Gambrelle<sup>4</sup>, MD, D. de Wolff-Rouendaal<sup>1</sup>, MD, PhD, R.J.W. de Keizer<sup>1,5</sup>, MD, PhD.

1. Dept Ophthalmology, Leiden University Medical Center, Leiden, The Netherlands
2. Dept Ophthalmology, Amsterdam Medical Center, Amsterdam, The Netherlands
3. Dept Ophthalmology, Catholic University Leuven, Leuven, Belgium
4. Dept Ophthalmology, Lyon University Hospital, Croix-Rouge, Lyon, France
5. Dept Ophthalmology, Antwerp University Hospital, Antwerp, Belgium

Support: Funds for Research in Ophthalmology and BrailleligaStichting Prize 2008 (G.S. Missotten)

Corresponding author:

Prof. Dr. R.J.W. de Keizer, MD, PhD

Ocular Oncology Unit, Dept. Ophthalmology, Leiden University Medical Center,

Albinusdreef 2, 2300 RC Leiden, The Netherlands.

Tel: +0031 71 526 3938

Fax: +0031 71 524 8222

Key words: Conjunctival melanoma, primary acquired melanoma, nasolacrimal tumor, nasal extension, melanoma recurrence

The corresponding author, Guy Missotten, grants on behalf of all authors, an exclusive licence (or non-exclusive for government employees) on a worldwide basis to the BMJ Publishing Group Ltd and its licensees to permit this article (if accepted) to be published in British Journal of Ophthalmology and any other BMJPGl products to exploit all subsidiary rights, as set out in our licence.

There are no competing interests in this research.

There is no specific ethical committee approval necessary for this retrospective study.

## **ABSTRACT**

**Purpose:** To characterize malignant conjunctival melanomas with extension and recurrence in the nasolacrimal system.

**Methods:** Localization of the primary tumor and recurrences of 210 conjunctival melanomas treated in the Netherlands were reviewed for orbital and nasal tumors (1978-2008). On the basis of these cases and literature data, characteristics for nasolacrimal system extension and metastasis were reviewed.

**Results:** Six patients (3%) showed a recurrence of the primary conjunctival melanoma in the nasolacrimal system. Two of the six primary tumors were limbal tumors, the other four were diffuse tumors involving the fornix. In all six patients, the primary conjunctival melanomas were associated with primary acquired melanosis (PAM). During the follow-up period (mean  $11.6 \pm 3$  years; median 8.7 years) two patients developed metastases, and died.

**Conclusions:** Patients should be advised to contact their treating ophthalmologist in the case of symptoms of epiphora, nose obstructions and epistaxis, especially non-bulbar and diffuse cases associated with PAM.

### ***Introduction:***

Conjunctival melanoma, with an incidence of 0.02 to 0.08/100 000/year<sup>1</sup>, is a rare tumor of the ocular surface with a survival of 62-78% after 10 years<sup>2-4</sup>. Recent reports indicate an increasing incidence for conjunctival melanomas in the last decades<sup>3,5,6</sup>. Conjunctival melanomas have a better survival than uveal melanomas<sup>7</sup>. The main risk factors for local recurrence in conjunctival melanoma are the nonbulbar localization of the tumor and the absence of adjuvant treatment (cryo- or brachytherapy) of the primary tumor<sup>2-4,8</sup>. Local brachytherapy can be performed with Strontium90<sup>9</sup>, Iodine125<sup>10</sup> or Ruthenium106<sup>11</sup> plaques on the bulbar conjunctiva, and Iridium192 irradiation on the tarsal conjunctiva and in the caruncle<sup>12</sup>. In addition, Mitomycin C can be used to treat extended areas of the premalignant PAM<sup>13</sup>. Some authors have reported that up to five percent of conjunctival melanomas recur to the ipsilateral nose or nasolacrimal sinuses<sup>14</sup>.

### ***Patients and methods:***

Of 210 patients with conjunctival melanoma in the Netherlands between 1978 and 2008 (inclusion criteria as previously described<sup>2</sup>, including all reported conjunctival melanomas in The Netherlands), 6 patients developed an extension in the lacrimal drainage system<sup>2,15</sup>. Complete clinical and follow-up data for these patients were found through the Leiden Oncology Registry, the different charts of hospitals and pathology laboratories. On the basis of patient charts, clinical photographs and histopathologic specimens, patients were identified with primary and recurrent conjunctival melanoma to the nasolacrimal system, nose and adjacent sinuses.

The study was approved by the institutional review board.

## ***Results***

The prevalence of invasive melanoma recurrence in the nasolacrimal system and the nose was  $3 \pm 2.25\%$  (mean  $\pm$  95% CI) in our series of 210 patients. Extension to the nose was not present at the time of treatment of the primary tumor in any of the six presented patients. The follow-up period between first pathology-confirmed diagnosis of the primary tumor and nasolacrimal extension was 73 months; within this period, half of the patients had two recurrences, the other three recurrences in other locations on the eye. Two patients died of metastatic disease six and ten months after the diagnosis and treatment of the nasolacrimal recurrence. One patient had a survival of 17 years. Two patients had only an extension to the nasolacrimal duct, the four others had also a melanoma in the nose. In two patients there was also a recurrence in the lacrimal canaliculi. The mean age at diagnosis of the primary tumor was 61 years (Table 1). Short case histories for each patient follow. To investigate whether patients with a conjunctival melanoma and PAM with or without nasolacrimal recurrence had a different prognosis, a Kaplan Meier analysis was performed: There was no significant difference in survival between these two groups ( $P=0.811$ ).

### **Patient 1**

At 30 years old, this female patient developed a temporal limbal tumor surrounded with fields of PAM on the right eye. The following year, the tumor was excised with pathological confirmation of a malignant melanoma. Two years later a recurrence was excised (pathology confirmed the diagnosis of melanoma) in the lower bulbar

conjunctiva, and one year later again a limbal tumor was seen and excised at the same area, that proved to be a junctional nevus and PAM. In the following years PAM was seen on the lower tarsal conjunctiva. Twelve years after the primary tumor, the patient complained of recurrent epistaxis for three months. Under the right concha inferior, a necrotic mass was found, pathologically proven to be a malignant melanoma. A resection including the right part of the palate and the lateral nose wall was performed by an ENT specialist. Now 17 years later, the patient still has no recurrence or metastases.

### **Patient 2**

A 74 year old lady was referred with a red left eye and was six months previously treated for three bulbar scarcely pigmented lesions that proved to be amelanotic melanoma on pathology. At the time of referral the patient had a grey tumor and melanosis in the lower fornix which was excised. Four years later the patient developed a bleeding tumor from under the upper eyelid. After excision with amnion transplantation, Iridium-192 irradiation (60Gy) was given. Twenty-nine months later, the patient complained of recurrent nose obstructions and nose bleedings; a tumor was diagnosed under the left middle and lower concha. Radical excision of the nose and left sinus was performed and external irradiation. Six years later the patient is still alive, without recurrence.

### **Patient 3**

A 60 year old female patient presented with a conjunctival tumor at the temporal limbus that was excised and proved to be a malignant melanoma. A year later a recurrence at the same localization surrounded by PAM was excised and treated with cryotherapy (Figure 1.1). Eleven months later the patient returned with recurrent epistaxis, and a tumor in the left nose, sinus maxillaris, orbit and fossa pterygopalatina was found. Due to the

extent of the lesion, curative excision was impossible and a palliative external irradiation was given. Two months later the patient developed distal metastases and she died eight months later.

#### **Patient 4**

A 70 yearold female patient was referred after incomplete excision of a conjunctival melanoma of the tarsal conjunctiva of the upper eyelid, with a pigmented tumor on the skin of the nose. Four years earlier a large bulbar and upper fornix melanoma with PAM was excised with adjunctive Ruthenium brachytherapy of the temporal conjunctiva. The new tumor was re-excised from the tarsal conjunctiva and irradiated afterwards with Iridium-192 needles in the upper eyelid (60 Gy). MRI showed no orbital extension. One year later the tumor recurred in the canaliculi with extension to the lacrimal sac (Figure 1.2), and a wide orbital exenteration was performed. Seven years later the patient is still alive, without recurrences.

#### **Patient 5**

A 57 year old female patient was referred to the ocular oncology clinic with melanosis in the temporal canthus and a pigmented lesion in the upper bulbar and tarsal conjunctiva of the right eye. Twenty six years earlier a conjunctival nevus was excised (Figure 1.3). The pathology specimens confirmed a junction nevus and mild primary acquired melanosis (PAM) at that time; the report contained a warning of possible recurrence or development of conjunctival melanoma. Reevaluation of the original specimens confirmed the presence of atypical conjunctival nevus and PAM with atypia.

MRI showed no ingrowth in the orbit, but due to the extension of the conjunctival lesions into the upper eyelid and the outer canthus an anterior exenteration was done in another



major oncological eye center with sparing of the optic nerve and extraocular muscles, the lacrimal sac and the N V,2 (Figure 1.4). External irradiation (50 Gray in 25 fractions) of the orbit was performed.

Six years later the patient complained of irritation on the nasal side of the orbital cavity and nose eczema. MRI and CT showed a mass in the area of the nasolacrimal duct located within the irradiated area; differentiation between scar-tissue and melanoma was impossible. Fine needle biopsy showed malignant melanoma cells. Wide excision of the tumor was performed by the ENT specialist and orbital surgeon. Figure 1.5 shows melanoma in the lacrimal sac. A reconstruction with a vascularised skin transplant graft from the forehead was performed to close the nasal orbital defect. As the recurrent tumor was in the field of the first irradiation, no adjuvant irradiation was given. More than three years later there is no recurrence.

### **Patient 6**

A 79 year old male patient was referred with a pigmented conjunctival lesion in the medial tarsal fornix, caruncle, and skin of the right eye. Radical excision with removal of the caruncle, lacrimal sac and nasolacrimal duct was performed and pathology confirmed the diagnosis of melanoma and extensive PAM. Three Iridium-192 needles were used in the nasal canthus. Forty months later the patient developed hemorrhagic lesions in the inferior fornix and a swollen eyelid (Figure 1.6). Biopsy of the lesions was performed and pathology mentioned that the borders of the specimen were not tumor-free. The patient also mentioned at that time recurrent epistaxis, and an MRI was performed. As the MRI showed an extension of the tumor into the orbit and nose, an orbital exenteration with

excision of the medial eyewall and the nasolacrimal duct was performed. Six months later the patient developed brain metastases and died.

### *Discussion*

Conjunctival melanoma is known to have a high percentage of local recurrences, but the extension to or recurrence in the nasolacrimal system and nose is less known. Previously, Robertson et al. estimated the incidence of recurrence of conjunctival melanoma in the nose or nasolacrimal system and paranasal sinuses at five percent, and this corresponds to our data (6/210 pts)<sup>14</sup>. The nasal extensions occurred some six years after the treatment of the primary tumor (range, 35-144 months), with one patient with a nasal recurrence after more than 12 years. Even a nasal tumor 21 years after the primary tumor has been described<sup>16</sup>.

A major risk factor for recurrence is non-bulbar localization of the tumor; in this study four of six patients had a non-bulbar component of the primary tumor, and all had involvement of the fornix at some point before the extension to the nose (Table 1)<sup>2</sup>. Similar findings were found for conjunctival melanomas invading the orbit<sup>17</sup>. In our study of 210 patients, 22 patients had a tumor in the caruncle and two of these tumors developed a nasal recurrence. This confirms the poor prognosis and the risks of conjunctival melanomas of the caruncle<sup>11,15</sup>, and warrants close follow-up of these patients.

As soon as a nasal recurrence is suspected high resolution imaging techniques like MRI and CT-scans should be used to location the extension of the new tumour in order to consider curative live saving treatment like exenteration or wide extension and radiotherapy. One may consider the removal of the nasolacrimal system when exenteration is necessary in these patients. Patient 5 shows that an anterior exenteration without removal of the nasolacrimal sac was not sufficient. But exenteration is not always necessary as shown by 3 of the 6 patients, that did not undergo an exenteration and are still alive, without recurrence until the end of the follow-up time.

A melanoma recurrence in the lacrimal drainage system could theoretically be explained firstly by implantation of melanoma cells breaking loose from the conjunctival melanoma surface and floating in the tear fluid (patient 1 and 2), secondly by invasion of the invasive melanoma from the fornix , tarsal conjunctiva or caruncula into the deeper layers into or around the lacrimal drainage system, occluding the passageway (patient 3, 4 and 6), thirdly a new local melanoma arising in PAM of the drainage system itself (patient 5). This may be hard to verify on imaging or even on histology (*see Figure 5*).

The effect of MitomycinC, a local chemotherapeutic drop widely used in the treatment of conjunctival PAM, to prevent floating melanoma cells to anchor in the lacrimal drainage system or treating PAM in the passageway is speculative. Some authors describe occlusion of the lacrimal punctum during Mitomycin treatment <sup>18</sup> , others (<sup>13</sup>; Kivelä, personal communication) report no occlusion. Khong and Muecke report 14% of 100 patients treated with MMC of which some needed dilatation and syringing of the punctum <sup>19</sup>.

Theoretically, MMC may treat PAM in the nasolacrimal system after instillation in the conjunctival sac, but has the tendency to occlude the lacrimal puncti. Therefore routinely little tubes in the lacrimal puncti might prevent occlusion, and permit treatment in the nasolacrimal sac and duct. MitomycinC does not have a role in the treatment of solid melanoma.

During the follow-up, two patients died of melanoma metastasis and both were cases with extensive local invasive disease at the time of nasolacrimal recurrence. Appropriate local treatment of the nasal extension can also give a long survival, which is illustrated by one patient who is still alive 17 years after the partial nose excision and irradiation (patient 1). Besides the fact that involvement of the canthus is a risk factor, another important factor is the presence of PAM in all patients described. McNab previously described a patient with PAM and melanoma involvement of the lacrimal drainage apparatus and the nose<sup>20</sup>. The mechanism seems similar to the hypothesis of spread of a so-called 'corneal melanoma'<sup>21</sup> where loose melanoma cells spread from the conjunctival melanosis to the corneal epithelium and give rise to a corneal melanoma. Circulating conjunctival melanoma cells have been demonstrated in the tear film of conjunctival melanoma patients<sup>22</sup>. Surprisingly, in the group of conjunctival melanoma patients associated with PAM, there was no difference in survival between patients with or without nasolacrimal recurrence (Figure 2).

We can learn from this series of patients, that patients especially with non-bulbar conjunctival melanomas should be advised to contact the ophthalmology department immediately when nose bleedings and recurrent signs of nose obstruction occur, as patients normally do not report this spontaneously and this may cause a treatment delay.

Radical treatment proved to be life saving in four of our six patients. As soon as the diagnosis of a melanoma recurrence in the lacrimal drainage system or nose are diagnosed, the absence of local regional and distant metastasis and the extension of the melanoma should be evaluated carefully. In a multidiscipline approach with orbital surgeons and ENT-surgeons the operation and possibly irradiation should be carried out.

## References

1. Seregard S. Conjunctival melanoma: major review. *Surv Ophthalmol* 1998; 42: 321-350
2. Missotten GS, Keijser S, de Keizer RJW, de Wolff-Rouendaal D. Conjunctival melanoma in the Netherlands: a nationwide study. *Invest Ophthalmol Vis Sci* 2005; 46: 75-82
3. Tuomaala S, Eskelin S, Tarkkanen A, Kivelä T. Population-based assessment of clinical characteristics predicting outcome of conjunctival melanoma in whites. *Invest Ophthalmol Vis Sci* 2002; 43: 3399-3408
4. Werschnik C, Lommatzsch PK. Long-term follow-up of patients with conjunctival melanoma. *Am J Clin Oncol* 2002; 25: 248-255
5. Inskip PD, Devesa SS, Fraumeni JF. Trends in the incidence of ocular melanoma in the United States, 1974-1998. *Cancer Causes Control* 2003; 14: 251-257
6. Triay E, Bergman L, Nilsson B, All-Ericsson C, Seregard S. Time trends in the incidence of conjunctival melanoma in Sweden. *Br J Ophthalmol* 2009 (epub ahead of print)
7. Kujala E, Tuomaala S, Eskelin S, Kivelä T. Mortality after uveal and conjunctival melanoma: which tumour is more deadly? *Acta Ophthalmol* 2009; 87: 149-153
8. Shields CL. Conjunctival melanoma: risk factors for recurrence, exenteration, metastasis, and death in 150 consecutive patients. *Trans Am Ophthalmol Soc* 2000; 98: 471-492
9. Lommatzsch PK. Beta-Ray treatment of malignant epibulbar melanoma. *Graefes Arch Klin Exp Ophthalmol* 1978; 15: 111-124

10. Shields JA, Shields CL, Freire JE, Brady LW, Komarnicky L. Plaque radiotherapy for selected orbital malignancies: preliminary observations: the 2002 Montgomery Lecture, part 2. *Ophthal Plast Reconstr Surg* 2003; 19: 91-95
11. Damato B, Coupland SE. An audit of conjunctival melanoma treatment in Liverpool. *Eye* 2009; 23: 801-809
12. De Keizer RJW, Schimmel EC. Iridium-192 brachytherapy of eyelid, conjunctiva and orbital malignancies. Abstracts of the International Society of Ocular Oncology meeting Amsterdam 2001: 46
13. Pe'er J, Frucht-Pery J. The treatment of primary acquired melanosis (PAM) with atypia by topical Mitomycin C. *Am J Ophthalmol* 2005; 139: 331-332
14. Robertson DM, Hungerford JL, McCartney A. Malignant melanomas of the conjunctiva, nasal cavity, and paranasal sinuses. *Am J Ophthalmol* 1989; 108: 440-442
15. D. de Wolff-Rouendaal. Conjunctival melanoma in The Netherlands: a clinic-pathological and follow-up study. Thesis. All In BV; Katwijk 1990
16. Paridaens ADA, McCartney ACE, Lavelle RJ, Hungerford JL. Nasal and orbital recurrence of conjunctival melanoma 21 years after exenteration. *Br J Ophthalmol* 1992; 76: 369-371
17. Gökmen SH, Ardic F. Malignant conjunctival tumors invading the orbit. *Ophthalmologica* 2008; 222: 338-343
18. McNab AA, McKelvie P. Malignant melanoma of the lacrimal sac complicating primary acquired melanosis of the conjunctiva. *Ophthalmic Surg Lasers* 1997; 28: 501-504

19. Kurli M, Finger PT. Topical mitomycin chemotherapy for conjunctival acquired melanosis with atypia: 12 years' experience. *Graefe's Arch Clin Exp Ophthalmol* 2005; 243: 1108-1114
20. Khong JJ, Muecke J. Complications of mitomycin C therapy in 100 eyes with ocular surface neoplasia. *Br J Ophthalmol* 2006; 90: 819-822
21. Tuomaala S, Aine E, Saari M, Kivela T. Corneally displaced malignant conjunctival melanomas. *Ophthalmology* 2002; 109: 914-919
22. Weiss JS, Perusse P, Reale F. Tear cytology in conjunctival melanoma. *Am J Ophthalmol* 1991; 111: 648-692



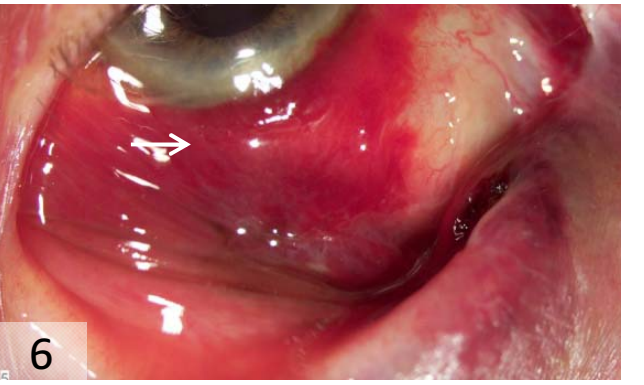
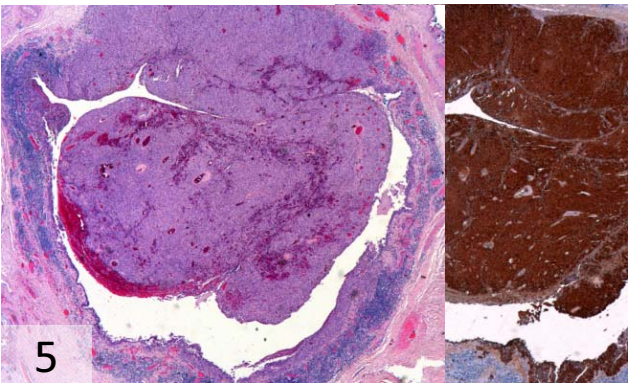
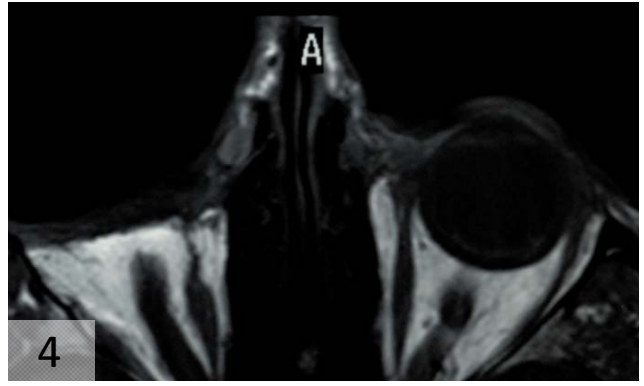
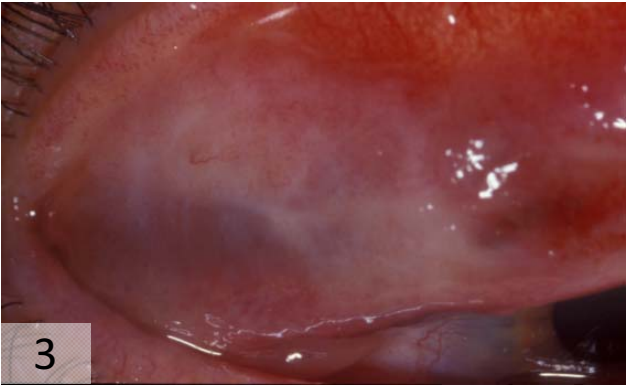
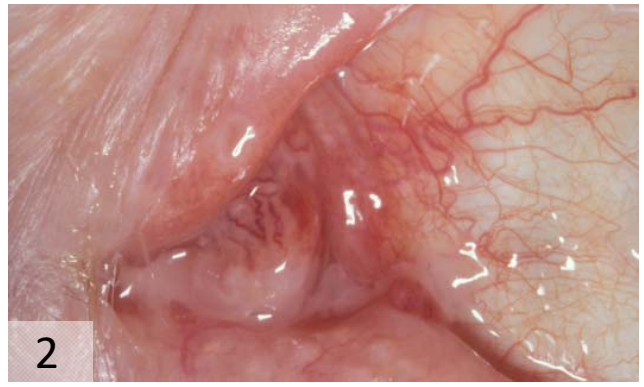
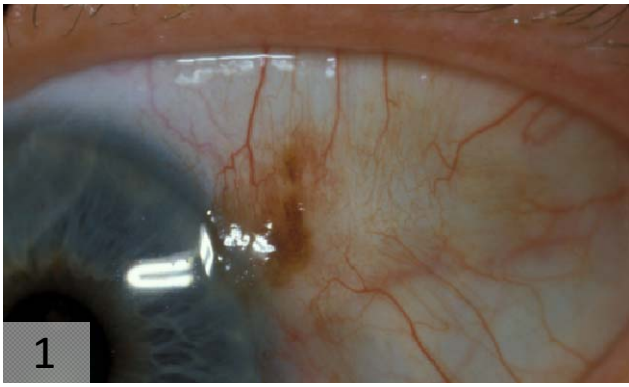
Pt	Age	Sex	Primary Tumor	Recurrences	PAM	Breslow	Time until nasal recurrence	Follow-up time	Death	Epiphora	Epistaxis
1	31	F	limbal (temporal quadrant)	3	+	N.A.	144	198		-	+
2	74	F	bulbar and lower fornix	2	+	2.8	83	73		+	+
3	58	F	limbal (temporal quadrant)	2	+	2.0	46	10	Melanoma	-	+
4	65	F	superior fornix	3	+	N.A.	59	84		+	-
5	57	F	superior fornix	3	+	3.0	70	35		+	-
6	80	M	superior fornix	2	+	1.0	35	6	Melanoma	-	+

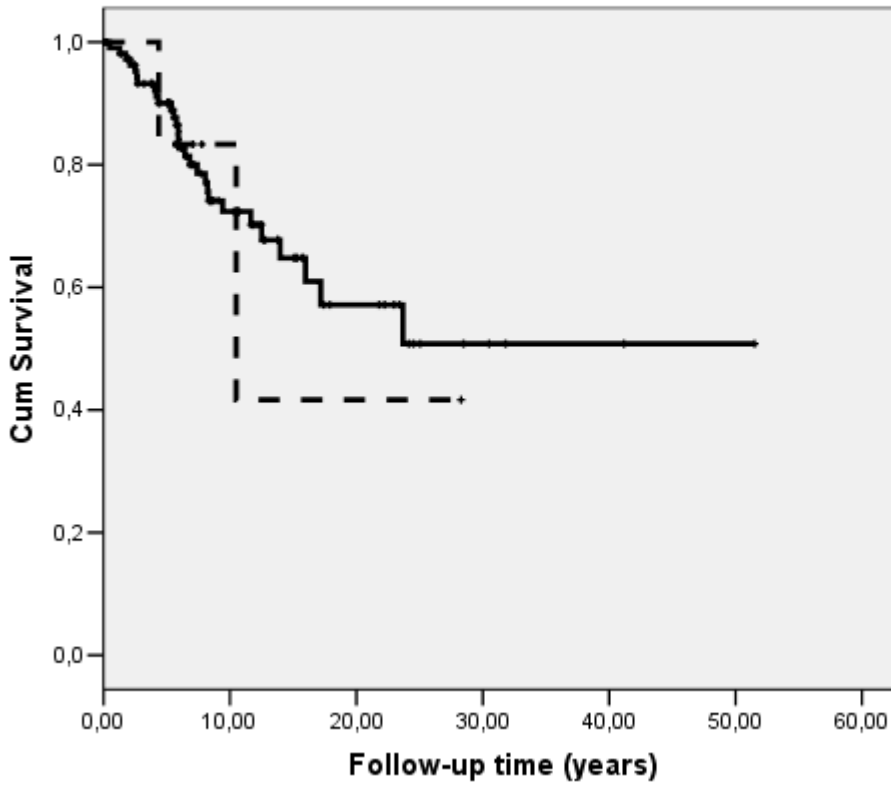
Table 1. General characteristics of six patients with a conjunctival melanoma with nasolacrimal extension. ‘Age’ is the age of the first pathology diagnosis of conjunctival melanoma. Recurrences include the nasal extension. ‘Time until nasal recurrence’ is the time from the first diagnosis until the time of diagnosis of recurrence in the nose (in months). Follow-up time is the time from the treatment of the nasal recurrence until the last visit (in months). PAM= primary acquired melanosis. N.A.=not available.

Legend Figure 1: Panel:

1. Patient 3. Small bulbar conjunctival melanoma with PAM. Eleven months after excision of this tumor the patient had a recurrence in the nose.
2. Patient 4. Recurrence of the conjunctival melanoma at the caruncle.
3. Patient 5. Conjunctival melanoma recurrence on the upper tarsal conjunctiva.
4. Patient 5. T2 weighted MRI showing the nasal recurrence of the conjunctival melanoma (indicated by an arrow). Six years earlier an anterior exenteration was performed.
5. Patient 5. Haematoxylin-Eosin staining of a section of the nasolacrimal sac. The melanoma in the wall of the sac occludes the lumen. The epithelium is totally replaced by melanoma cells, obstruction the duct. A staining with S100 shows clearly the delineation.
6. Patient 6. Recurrence in the nasal canthus.

Figure 2. Kaplan Meier survival curve showing no significant difference in conjunctival melanoma with primary acquired melanoma patients with (N=6; - - -) or without (N=122; —) nasolacrimal recurrence (P=0.811).





- - - PAM+ with nasolacrimal extension
- PAM+ without nasolacrimal extension