



HAL
open science

Microvascular reconstructions after extensive soft tissue sarcoma resections in the upper limb

I. Barner-Rasmussen, P. Popov, T. Böhling, C. Blomqvist, E. Tukiainen

► **To cite this version:**

I. Barner-Rasmussen, P. Popov, T. Böhling, C. Blomqvist, E. Tukiainen. Microvascular reconstructions after extensive soft tissue sarcoma resections in the upper limb. *EJSO - European Journal of Surgical Oncology*, 2010, 36 (1), pp.78. <10.1016/j.ejso.2009.08.003>. <hal-00556320>

HAL Id: hal-00556320

<https://hal.science/hal-00556320v1>

Submitted on 16 Jan 2011

HAL is a multi-disciplinary open access archive for the deposit and dissemination of scientific research documents, whether they are published or not. The documents may come from teaching and research institutions in France or abroad, or from public or private research centers.

L'archive ouverte pluridisciplinaire **HAL**, est destinée au dépôt et à la diffusion de documents scientifiques de niveau recherche, publiés ou non, émanant des établissements d'enseignement et de recherche français ou étrangers, des laboratoires publics ou privés.




HAL Authorization

Accepted Manuscript

Title: Microvascular reconstructions after extensive soft tissue sarcoma resections in the upper limb

Authors: I. Barner-Rasmussen, P. Popov, T. Böhling, C. Blomqvist, E. Tukiainen



PII: S0748-7983(09)00435-1

DOI: [10.1016/j.ejso.2009.08.003](https://doi.org/10.1016/j.ejso.2009.08.003)

Reference: YEJSO 2878

To appear in: *European Journal of Surgical Oncology*

Accepted Date: 6 August 2009

Please cite this article as: Barner-Rasmussen I, Popov P, Böhling T, Blomqvist C, Tukiainen E. Microvascular reconstructions after extensive soft tissue sarcoma resections in the upper limb, *European Journal of Surgical Oncology* (2009), doi: 10.1016/j.ejso.2009.08.003

This is a PDF file of an unedited manuscript that has been accepted for publication. As a service to our customers we are providing this early version of the manuscript. The manuscript will undergo copyediting, typesetting, and review of the resulting proof before it is published in its final form. Please note that during the production process errors may be discovered which could affect the content, and all legal disclaimers that apply to the journal pertain.

Microvascular reconstructions after extensive soft tissue sarcoma resections in the upper limb

Original article

Running head: Free flap reconstruction for sarcoma

I. Barner-Rasmussen^{a*}, P. Popov^a, T. Böhling^b, C. Blomqvist^c, E. Tukiainen^a

^aDepartment of Plastic Surgery, Töölö Hospital, Helsinki University Central Hospital, PO 266, 00029 HUS, Finland

^bDepartment of Pathology, Peijas Hospital, University of Helsinki and HUSLAB, PO 900, 00029 HUS, Finland

^cDepartment of Oncology, Helsinki University Central Hospital, PO 180, 00029 HUS, Finland

*Corresponding author at

Department of Plastic Surgery, P.O. Box 266, 00029 HUS, Finland

Tel: +358 400 420404; fax: +358 947187570

E-mail adress: ian.barner-rasmussen@helsinki.fi

Abstract

Aims: Limb-sparing surgery combined with radiotherapy (RT) is the basis of extremity soft tissue sarcoma (STS) treatment. The aim of this study was to evaluate the results of microvascular reconstruction after extensive tumour resections in the upper extremity.

Methods: 20 patients with STS of the upper extremity were treated with excision and microvascular reconstruction. RT was administered if surgical margins were less than 25mm. Results were evaluated retrospectively.

Results: 20 free flaps were performed and no flaps were lost. There was no operative mortality, and wound complication rate was 15%. Median follow-up length was 74 months. Five-year local recurrence-free survival was 57%, metastasis-free survival 67%, disease-free survival 45% and disease-specific overall survival 80%. Ten patients had no or only mild impairment of upper extremity function, seven had impaired function affecting daily life, and three patients underwent amputation. For patients treated with curative intent, limb salvage rate was 94%.

Conclusions: Free flaps are useful and reliable in the treatment of patients with STS of the upper extremity. Without microvascular reconstruction limb salvage would have been impossible in these patients. Oncological outcome is comparable to other extremity STS patients and upper extremity function is acceptable.

Keywords: Sarcoma; Reconstructive surgery; Surgical flaps; Upper extremity; Microsurgery; Replantation

Introduction

Soft tissue sarcomas (STS) are a rare, heterogeneous group of tumours. In 2000-2005 the mean age-adjusted incidence rate of STS in Finland was 2.0/100 000, accounting for less than one per cent of adult malignancies [1]. 12 to 15 per cent of STS are located in the upper extremity [2,3].

In the past, extremity STS was often treated with amputation due to high rates of local recurrence after simple resection [4,5]. Today, using a combination of surgery and radiotherapy (RT), better functional results are achieved with equal rates of local control [6,7]. Modern treatment consists of a multidisciplinary team approach, and limb-sparing surgery combined with oncological treatment [8].

The required surgical margins of 2-3cm [9] of tumour-free tissue frequently cause large defects, and local or free flaps are often required to achieve tension-free wound closure or to reconstruct tissue defects. Free flap reconstruction is needed in 11-18% of patients undergoing limb-sparing surgery for upper extremity STS [10-12].

Limb salvage is not always possible, and sometimes amputation is unavoidable [13]. For selected cases of proximal upper extremity or shoulder girdle tumours, even forequarter-amputation is used for curation or for palliative treatment [14]. When simultaneous chest wall reconstruction is necessary, fillet flaps from the amputated extremity are useful for reconstruction [15,16]. For tumours requiring segmental resection of an extremity, heterotopic replantation has been used [17].

The aim of this study was to evaluate the results of a single institution in using microvascular reconstruction for extensive bone and soft tissue defects after tumour resections in the upper extremity.

Patients and methods

Patients treated by the Helsinki University Central Hospital (HUCH) soft tissue sarcoma group who had undergone microsurgical reconstruction after upper limb soft tissue tumour surgery in 1990-2006 were identified, and their medical records retrospectively reviewed. Data concerning patient demographics, tumour characteristics, surgical treatment and oncologic and functional outcome were collected from hospital records

Sarcoma group protocol

Preoperatively, diagnosis is confirmed by fine or core-needle biopsies, and radiological examinations (CT, MRI) performed to define local and systemic status of the disease. Before sample fixation the pathologist measures tumour size and final histopathological examination is then carried out. STS malignancy grading is based on a four-tiered grading system used by the Scandinavian Sarcoma Group. Grades 1-2 are considered low malignancy grade, and 3-4 are considered high grade. Based on the work of Broders, the system considers cellularity, cell and nuclear polymorphism, differentiation, necrosis, haemorrhage, mitotic activity, and growth pattern for tumour grading [18,19].

Wide microscopical margins are defined as ≥ 25 mm of healthy tissue or an intact fascial barrier separating the tumour from the excision margin. When margins are less than wide but no tumour cells are found at the edges of the specimen, excision is defined as marginal. Intralesional margins should lead to re-excision in patients treated with curative intent. After marginal excision, external beam radiotherapy (EBRT) is delivered to the operative field with a dose of 50 Gy during 5 weeks. Selected patients receive adjuvant chemotherapy.

Follow-up time was five years for STS patients provided there were no recurrences. Patients with high-grade disease were examined every second month for the first two years, and then every six months. Follow-up protocol for low-grade disease was clinical examination

two to three times annually. A chest X-ray was taken at each visit. A CT or MRI scan of the operative area was performed annually, beginning at six months postoperatively.

Patient material

In 1987-2006 the HUCH soft tissue sarcoma group treated 1314 STS patients, of which 204 had upper extremity tumours. 24 of upper extremity STS patients were treated with primary amputation, and direct closure after tumour excision was done in 82 patients. Reconstructive procedures were skin graft in 28, pedicled skin flap in 15 and pedicled muscle flap in 33 patients. 20 patients required microvascular reconstruction after soft-tissue tumour excision, and they were included in this study (Table 1). Two patients had palliative procedures for metastasized STS, and they were excluded from oncologic analyses, but included in analyses for surgical endpoints and functional outcome. Two patients, one with dermatofibrosarcoma protuberans (DFSP) and the other with desmoid tumour, were also excluded from oncologic analyses but included in surgical endpoint and functional outcome analyses. 16 patients thus remained for analysis of oncologic endpoints.

In all, there were 20 patients (4 male, 16 female) with a median age of 61 years. Seven patients were referred for virgin primary tumours and six for primary tumours after intralesional operation. Seven patients were admitted for recurrent tumours.

Tumour characteristics

Median tumour size was 5.0 cm (range 1.8-29.0). Excluding the two patients treated with palliative intent, all tumours were less than 10.0 cm in diameter. 16 soft tissue sarcomas were of high malignancy grade and two were of low grade. 17 tumours were extracompartmental and three were intracompartmental; all of the intracompartmental tumours were subcutaneous.

16 tumours were located distal to the elbow joint. In one patient the joint was affected and in three cases the tumour was located above elbow level. Malignant fibrous histiocytoma (MFH) was the most common histological STS subtype, present in ten cases. Other diagnoses were two fibrosarcomas, two synovial sarcomas, and one sarcoma NOS, extraskeletal chondrosarcoma, epitheloid sarcoma and malignant peripheral nerve sheath tumour (MPNST).

Reconstructive procedures

All operations were performed as single-stage procedures. Simple tumour excision and microvascular reconstruction of the defect was done for 17 patients. The free flap contained bone in three of these. Two forequarter-amputations with fillet flaps from the amputated extremity were performed. In one of these, the fillet flap was also used for chest wall reconstruction. In addition, a patient with synovial sarcoma affecting the elbow joint had replantation of the distal forearm to the upper arm after segmental resection of the elbow area.

Tendon reconstruction was performed in eight cases, and nerve reconstruction in six cases. In addition one latissimus dorsi flap was used as an innervated functional flap, the motor nerve of the flap sutured to the radial nerve at the recipient site. Recipient site skin grafting was necessary in two cases.

Median duration of operation was 310 minutes (range 195-575) and median flap ischemia time was 64 minutes (range 31-216). Median perioperative bleeding was 650 ml (range 150-8000).

Surgical margins

For curatively treated STS patients, wide microscopical margins were achieved in seven patients, and marginal excision in eight patients. In one patient, final histopathological examination showed intralesional margins, and humeral amputation was performed.

Oncological treatment

Five patients with wide surgical margins had no oncological treatment. Eight STS patients with marginal excision underwent postoperative external beam radiotherapy (EBRT). In addition, two patients with wide excision received postoperative EBRT. Preoperative radiotherapy was given to one patient with a large, high-grade tumour. This patient was also the only one to receive chemotherapy, which was given both as neoadjuvant and adjuvant treatment. In three cases, including the two palliatively treated patients, EBRT could not be used because of earlier radiotherapy.

Statistical analysis

SPSS for Windows (v 15.0, SPSS Inc., Chicago, Illinois) was used for statistical analysis. Oncologic endpoints were: local recurrence-free survival (LRFS), metastasis-free survival (MFS), disease-free survival (DFS) and disease-specific overall survival (DSOS), calculated by the Kaplan-Meier method. Values refer to outcome at five years. Prognostic factors for surgical complications were analyzed with chi-square- and Fisher's exact test. P-values of ≤ 0.05 were considered significant.

Results

Flap survival and complications

There was no postoperative mortality and no free flaps were lost. One patient required immediate reoperation for reanastomosis of the flap vein (Patient 17). Another patient underwent donor site haematoma evacuation on the first postoperative day (Patient 7). In one case, reosteosynthesis of the fibula flap was performed the day after the initial operation (Patient 5). Wound revision was necessary in two patients for minor wound complications (Patients 17 and 20). In all, three patients had wound complications requiring one or more operative procedures, giving a wound complication rate of 15%.

One patient with osteoradionecrosis and subsequent fistula at nine months was treated with repeated wound revisions. Successful closure was achieved at 14 months after coverage with a pedicled flap. Later remodelling of the flap was carried out in three cases to achieve a more satisfactory aesthetic or functional result. The patient that had undergone humeroantibrachial replantation had surgery at four months to adjust the position of the replant for better function. No significant prognostic factors predicting surgical complications were identified in statistical analysis.

Oncologic outcome

Oncologic outcome was analyzed in 16 soft-tissue sarcoma patients treated with curative intention. Median length of follow-up was 74 months (range 19-187). Five-year estimated local recurrence-free survival (LRFS) was 57%, metastasis-free survival (MFS) 67% and disease-free survival (DFS) 45%. Disease-specific overall survival (DSOS) was 80% at five years (Figure 1).

Seven patients developed a local recurrence at a median of 37 months (range 6-61). Patients with >5.0 cm tumours were significantly more likely to have a local recurrence than

those with 5.0 cm or smaller tumours (LRFS 20% vs. 78%, $P=0.004$). Local recurrence was also more likely for higher-grade tumours; LRFS for grade 2 tumours was 100%, for grade 3 tumours 67%, and for grade 4 tumours 29% ($P=0.021$). Metastasis developed in seven patients. Median time to metastasis was 33 months (range 4-117). Seven out of 16 patients have died of disease, at a median of 72 months (range 21-187) after surgery. Tumour size over 5.0 cm was a significant predictor of disease death (DSOS 60% vs. 91% for patients with 0-5.0 cm tumours, $P=0.028$)

The two patients who underwent palliative surgery for advanced STS both died from disease, at two and 13 months. The two patients operated for DFSP and desmoid tumour are both disease free at a 112 and 133 months, respectively.

Functional outcome

Eight patients experienced no impairment of function in the upper extremity during follow-up. Two patients experienced some impairment of function not affecting daily activities. Seven patients had impaired upper extremity function significantly affecting daily activities. Two patients underwent planned primary forequarter amputation, and humeral amputation was performed in one patient due to intralesional surgical margins.

Because of local recurrences at one, two and four years after free flap sarcoma surgery, late amputations were necessary in three patients. Excluding the two planned forequarter amputations this gives an early limb salvage rate of 94%, and 78% limb salvage rate at five years. In all, five amputations were performed in curatively treated patients.

Discussion

Soft tissue sarcoma of the upper extremity is rare; only few cases are encountered annually in Finland with 5.3 million inhabitants [1]. Microvascular reconstructive surgery after sarcoma resection is required in a significant proportion of these patients, but remains a procedure that few surgeons become familiar with. This is, to our knowledge, the largest series to date on upper extremity STS focusing on limb salvage and free flap reconstruction.

Limb salvage and upper extremity reconstruction

Oncologically safe surgical margins, preserving a functional limb and a good aesthetic result are the goals of limb salvage surgery for STS. Limb salvage does not adversely affect oncological outcome [6,7], and the functional benefits of limb salvage with soft tissue reconstruction in sarcoma surgery have been established [20]. Free flaps provide well-vascularised tissue facilitating wound healing, and also tolerate radiotherapy well. In addition, no further morbidity is caused to the extremity. A wide array of free flaps is available for reconstruction following upper extremity tumour resection, and the choice of flap is based on defect size, types of tissue required, postoperative functional goal, and surgeon preference. For reconstruction of long segments of bone, the free fibular flap is preferred [21,22].

Disease recurrence and survival

Follow-up in this series was long, with a median follow-up of 74 months, attributable to the centralized care of these patients. Oncological results were comparable to studies with similar patient material [9]. Other works on upper extremity STS have reported rates of local recurrence of 17-25% with variable lengths of follow up [11,12,23]. In a study including 80 patients with STS of the upper extremity treated at the authors' institution between 1987 and 1999, local recurrence was less common (LRFS 79%), but MFS and DSOS were comparable to the present study [12]. Only 19% of patients in the earlier study presented with recurrent tumour compared to 35% in this series, which may explain our higher rate of local recurrence;

local recurrence at presentation has been shown to predict further local recurrences [24]. Kim et al reported their results in treating 17 patients with limb salvage and microvascular reconstruction [10]. We have reported very similar outcomes, the slightly lower LRFS and DSOS (50.0 and 61.3%, respectively) of Kim et al likely explained by their more challenging patient material with mostly high-grade, recurrent sarcomas.

Functional outcome

A variety of scoring systems have been used for functional evaluation after upper extremity tumour surgery [25,26]. Limb salvage and microvascular reconstruction did not adversely affect functional outcome in a previous study after upper extremity STS resection [27]. Due to the retrospective nature of this study, quantitative tools for assessment of functional outcome were unavailable, but the majority of our patients experienced normal or only mildly impaired upper extremity function.

Further treatment options

In the future, techniques like composite tissue allotransplantation, or advanced myoelectric prostheses, combined with targeted reinnervation surgery, or dielectric elastomers [28-30] could provide us with readily available, easy-to-use components for reconstruction of the upper extremity. At present these remain, however, experimental techniques, and locally available tissue, or of pedicled or free flaps must be used for reconstruction.

Conclusions

When tension-free wound closure and cavity filling after STS surgery cannot be achieved using locally available soft tissues, microvascular reconstruction is needed. Free flaps provide well-vascularised tissue to the site, promoting wound healing and thus facilitating early administration of oncological treatment. Microvascular reconstruction is safe and reliable for defects after soft tissue sarcoma resection, and functional outcome is generally good. Due to the rarity of these procedures, treatment should be planned and carried out in centres with the necessary multidisciplinary resources.

ACCEPTED MANUSCRIPT

Acknowledgements

The first author was supported by a research grant from The Luise and Henrik Kuningas Foundation while working on this article. The funding source had no role in the preparation of the manuscript.

ACCEPTED MANUSCRIPT

Figure captions:

Figure 1. Outcome for 16 soft tissue sarcoma patients treated with limb salvage and microvascular reconstruction with curative intent. DSOS = disease-specific overall survival, MFS = metastasis-free survival, LRFS = local recurrence-free survival.

ACCEPTED MANUSCRIPT

- ¹ Finnish Cancer Registry. Cancer in Finland 2004 and 2005. Cancer Society of Finland, Publication No. 72. Helsinki, 2007.
- ² Nijhuis PH, Schaapveld M, Otter R, Molenaar WM, van der Graaf WT, Hoekstra HJ. Epidemiological aspects of soft-tissue sarcomas (STS) – consequences for the design of clinical STS trials. *Eur J Cancer* 1999; **35**: 1705-10.
- ³ Pollock RE, Karnell LH, Menck HR, Winchester DP. The National Cancer Data Base report on soft tissue sarcoma. *Cancer* 1996; **78**: 2247-57.
- ⁴ Cantin J, McNeer GP, Chu FC, Booher RJ. The problem of local recurrence after treatment of soft tissue sarcoma. *Ann Surg* 1968; **168**: 47-53.
- ⁵ Hoekstra HJ, Thijssens K, van Ginkel RJ. Role of surgery as primary treatment and as intervention in the multidisciplinary treatment of soft tissue sarcoma. *Ann Oncol* 2004; **15**: 181-6.
- ⁶ Rosenberg SA, Tepper J, Glatstein E, Costa J, Baker A, Brennan M *et al*. The treatment of soft-tissue sarcomas of the extremities: prospective randomized evaluations of (1) limb-sparing surgery plus radiation therapy compared with amputation and (2) the role of adjuvant chemotherapy. *Ann Surg* 1982; **196**: 305-15.
- ⁷ Yang JC, Chang AE, Baker AR, Sindelar WF, Danforth DN, Topalian SL *et al*. Randomized prospective study of the benefit of adjuvant radiotherapy in the treatment of soft tissue sarcomas of the extremity. *J Clin Oncol* 1998; **16**: 197-203.
- ⁸ Clark MA, Fisher C, Judson I, Thomas JM. Soft-tissue sarcomas in adults. *N Engl J Med* 2005; **353**: 701-11.
- ⁹ Sampo M, Tarkkanen M, Huuhtanen R, Tukiainen E, Böhling T, Blomqvist C. Impact of the smallest surgical margin on local control in soft-tissue sarcoma. *Br J Surg* 2008; **95**: 237-43.
- ¹⁰ Kim JY, Subramanian V, Yousef A, Rogers BA, Robb GL, Chang DW. Upper extremity limb salvage with microvascular reconstruction in patients with advanced sarcoma. *Plast Reconstr Surg* 2004; **114**: 400-8.
- ¹¹ Lohman RF, Nabawi AS, Reece GP, Pollock RE, Evans GR. Soft tissue sarcoma of the upper extremity: a 5-year experience at two institutions emphasizing the role of soft tissue flap reconstruction. *Cancer* 2002; **94**: 2256-64.

- ¹² Popov P, Tukiainen E, Asko-Seljavaara S, Huuhtanen R, Virolainen M, Virkkunen P *et al.* Soft tissue sarcomas of the lower extremity: surgical treatment and outcome. *Eur J Surg Oncol* 2000; **7**: 679-85.
- ¹³ Clark MA, Thomas JM. Amputation for soft-tissue sarcoma. *Lancet Oncol* 2003; **4**: 335-42.
- ¹⁴ Clark MA, Thomas JM. Major amputation for soft-tissue sarcoma. *Br J Surg* 2003; **90**: 102-7.
- ¹⁵ Tran NV, Evans GR, Kroll SS, Reece GP, Ainslie N, Robb GL. Free fillet extremity flap: indications and options for reconstruction. *Plast Reconstr Surg* 2000; **105**: 99-104.
- ¹⁶ Cordeiro PG, Santamaria E, Hidalgo D. The role of microsurgery in reconstruction of oncologic chest wall defects. *Plast Reconstr Surg* 2001; **108**: 1924-30.
- ¹⁷ Windhager R, Millesi H, Kotz R. Resection-replantation for primary malignant tumours of the arm. An alternative to fore-quarter amputation. *J Bone Joint Surg Br* 1995; **77**: 176-84.
- ¹⁸ Angervall L, Kindblom LG. Principles for pathologic-anatomic diagnosis and classification of soft-tissue sarcomas. *Clin Orthop* 1993; **289**: 9-18.
- ¹⁹ Broders AC, Hargrave R, Meyerding HW. Pathologic features of soft tissue fibrosarcoma with special reference to the grading of its malignancy. *Surg Gynaecol Obstet* 1939; **69**: 267-280.
- ²⁰ Serletti JM, Carras AJ, O'Keefe RJ, Rosier RN. Functional outcome after soft-tissue reconstruction for limb salvage after sarcoma surgery. *Plast Reconstr Surg* 1998; **102**: 1576-83.
- ²¹ Saint-Cyr M, Langstein HN. Reconstruction of the hand and upper extremity after tumor resection. *J Surg Oncol* 2006; **94**: 490-503.
- ²² Pederson WC. Upper extremity microsurgery. *Plast Reconstr Surg* 2001; **107**: 1524-36.
- ²³ Herbert SH, Corn BW, Solin LJ, Lanciano RM, Schultz DJ, McKenna WG, Coia LR. Limb-preserving treatment for soft-tissue sarcomas of the extremities. The significance of surgical margins. *Cancer* 1993; **72**: 1230-8.
- ²⁴ Pisters PW, Leung DH, Woodruff J, Shi W, Brennan MF. Analysis of prognostic factors in 1,041 patients with localized soft tissue sarcomas of the extremities. *J Clin Oncol* 1996; **14**: 1679-89.
- ²⁵ Wright EH, Gwilym S, Gibbons CL, Critchley P, Giele HP. Functional and Oncological outcomes after limb-salvage surgery for primary sarcomas of the upper limb. *J Plast Reconstr Aesthet Surg* 2008; **61**: 382-7.
- ²⁶ Hoy E, Granick M, Benevenia J, Patterson F, Datiashvili R, Bille B. Reconstruction of musculoskeletal defects following oncologic resection in 76 patients. *Ann Plast Surg* 2006; **57**: 190-4.

- ²⁷ Kim JY, Youssef A, Subramanian V, Rogers BA, Pollock RE, Robb GL, Chang DW. Upper extremity reconstruction following reconstruction of soft tissue sarcomas: a functional outcomes analysis. *Ann Surg Oncol* 2004; **11**: 921-7.
- ²⁸ Swearingen B, Ravindra K, Xu H, Wu S, Breidenbach WC, Ildstad ST. Science of composite tissue allotransplantation. *Transplantation* 2008; **86**: 627-35.
- ²⁹ Miller LA, Stubblefield KA, Lipschutz RD, Lock BA, Kuiken TA. Improved myoelectric prosthesis control using targeted reinnervation surgery: a case series. *IEEE Trans Neural Syst Rehabil Eng* 2008; **16**: 46-50.
- ³⁰ Biddiss E, Chau T. Dielectric elastomers as actuators for upper limb prosthetics: challenges and opportunities. *Med Eng Phys* 2008; **30**: 403-18.

ACCEPTED MANUSCRIPT

Conflict of interest statement

The authors declare that they have no conflict of interest.

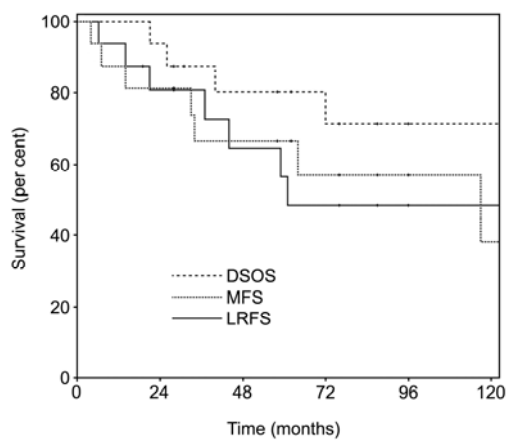
ACCEPTED MANUSCRIPT

Table 1
Patient and tumour characteristics

Patient	Tumour histology	Grade	Size	Free flap	DSOS (months)	Status
1 ^a	MFH	4	20.0	latissimus dorsi	2	DOD
2 ^a	extraskelatal chondrosarcoma	3	29.0	fillet (antebrachium) ^b	13	DOD
3	MFH	4	8.0	fillet (antebrachium) ^b	26	DOD
4	MFH	4	4.5	tensor fascia latae	31	DUC
5	MFH	4	7.0	fibula	40	DOD
6	sarcoma NOS	2	1.8	scapular	87	NED
7	MFH	4	6.0	latissimus dorsi	58	NED
8	synovial sarcoma	3	5.0	antebrachial replantation	21	DOD
9	fibrosarcoma	3	6.0	radial forearm	72	DOD
10	MFH	4	9.0	tensor fascia latae	62	DUC
11	MFH (myxoid)	2	5.0	radial forearm	76	NED
12	MPNST	4	2.5	anterolateral thigh	31	NED
13	epitheloid sarcoma	3	3.0	latissimus dorsi	187	DOD
14	synovial sarcoma	3	3.0	fibula	165	NED
15	desmoid tumor ^c	-	5.8	scapular	112	NED
16	MFH	3	2.5	radial forearm	96	NED
17	MFH	4	4.5	latissimus dorsi	155	NED
18	MFH	3	4.5	tensor fascia latae + crista iliaca	145	DOD
19	DFSP ^c	1	3.0	radial forearm	133	NED
20	fibrosarcoma	3	5.0	latissimus dorsi	130	DOD

MFH: malignant fibrous histiocytoma, NOS: not otherwise specified, MPNST: malignant peripheral nerve sheath tumour, DFSP: dermatofibrosarcoma protuberans. DSOS: disease-specific overall survival. DOD: dead of disease, DUC: dead of unrelated cause, NED: no evidence of disease.

^aPalliative treatment intent. ^bPrimary amputation. ^cNon-sarcoma, excluded from oncological endpoint analyses.



ACCEPTED MANUSCRIPT