



HAL
open science

Dermatofibrosarcoma protuberans: recurrence is related to the adequacy of surgical margins

S. Ten Heuvel, A. Suurmeijer, E. Pras, R.J. van Ginkel, H. Hoekstra

► **To cite this version:**

S. Ten Heuvel, A. Suurmeijer, E. Pras, R.J. van Ginkel, H. Hoekstra. Dermatofibrosarcoma protuberans: recurrence is related to the adequacy of surgical margins. *EJSO - European Journal of Surgical Oncology*, 2010, 36 (1), pp.89. 10.1016/j.ejso.2009.07.006 . hal-00556317

HAL Id: hal-00556317

<https://hal.science/hal-00556317>

Submitted on 16 Jan 2011


HAL is a multi-disciplinary open access archive for the deposit and dissemination of scientific research documents, whether they are published or not. The documents may come from teaching and research institutions in France or abroad, or from public or private research centers.

L'archive ouverte pluridisciplinaire **HAL**, est destinée au dépôt et à la diffusion de documents scientifiques de niveau recherche, publiés ou non, émanant des établissements d'enseignement et de recherche français ou étrangers, des laboratoires publics ou privés.

Accepted Manuscript

Title: Dermatofibrosarcoma protuberans: recurrence is related to the adequacy of surgical margins

Authors: S. Ten Heuvel, A. Suurmeijer, E. Pras, R.J. Van Ginkel, H. Hoekstra



PII: S0748-7983(09)00228-5

DOI: [10.1016/j.ejso.2009.07.006](https://doi.org/10.1016/j.ejso.2009.07.006)

Reference: YEJSO 2860

To appear in: *European Journal of Surgical Oncology*

Accepted Date: 6 July 2009

Please cite this article as: Heuvel S.T, Suurmeijer A, Pras E, Van Ginkel RJ, Hoekstra H. Dermatofibrosarcoma protuberans: recurrence is related to the adequacy of surgical margins, *European Journal of Surgical Oncology* (2009), doi: [10.1016/j.ejso.2009.07.006](https://doi.org/10.1016/j.ejso.2009.07.006)

This is a PDF file of an unedited manuscript that has been accepted for publication. As a service to our customers we are providing this early version of the manuscript. The manuscript will undergo copyediting, typesetting, and review of the resulting proof before it is published in its final form. Please note that during the production process errors may be discovered which could affect the content, and all legal disclaimers that apply to the journal pertain.

Dermatofibrosarcoma protuberans: recurrence is related to the adequacy of surgical margins

S. Ten Heuvel, MD¹, A. Suurmeijer, MD, PhD², E. Pras, MD, PhD³, R.J. Van Ginkel, MD, PhD¹, H. Hoekstra, MD, PhD¹

1 Department of Surgical Oncology, University Medical Center Groningen, University of Groningen, Groningen, The Netherlands

2 Department of Pathology, University Medical Center Groningen, University of Groningen, Groningen, The Netherlands

3 Department of Radiotherapy, University Medical Center Groningen, University of Groningen, Groningen, The Netherlands

Key words: dermatofibrosarcoma protuberans, , pathology, surgery, radiation, imatinib, prognosis

Running head: Surgical treatment of dermatofibrosarcoma protuberans

Presented at the Esso 2008 – 14th Congress of the European Society of Surgical Oncology 10 – 12 september 2008. The Hague. The Netherlands.

Address for correspondence:

H.J. Hoekstra, MD, PhD

Department of Surgical Oncology

University Medical Center Groningen

University of Groningen

P. O. Box 30.001

9700 RB Groningen

The Netherlands

Tel: +31-50-3612317

Fax: +31-50-3614873

E-mail: h.j.hoekstra@chir.umcg.nl

Abstract

Introduction. The aim of the study was to investigate the results of surgical treatment in primary and recurrent dermatofibrosarcoma protuberans (DFSP), with respect to local tumor control.

Patients and Methods. Thirty-eight patients were treated between 1971-2005 at the University Medical Center Groningen (UMCG). Thirty patients presented with primary disease (79%) and 8 patients with locally recurrent disease (21%). The treatment consisted of surgical resection and in case of marginal or positive resection margins (R1 resection) adjuvant radiotherapy.

Results. Adequate surgical margins as a single modality was associated with 100% local control in all primary DFSPs. Two patients whose resection specimens had microscopically positive resection margins had withdrawn from adjuvant radiotherapy and developed local recurrence (LF rate 7%). Two of the 8 patients referred with a local recurrence developed a second recurrence (LF rate 25%); one of these patients developed distant disease and ultimately died of systemic disease. Non of the five patients with DFSP-FS developed LF after treatment at the UMCG.

After a median follow-up of 89 (12-271) months, the 10-year disease-free survival was 85% and the 10-year disease specific survival was 100%.

Conclusion. After wide surgical resection of a DFSP or DFSP-FS, or an R1 resection combined with adjuvant radiotherapy the risk of local recurrence is extremely low.

Introduction

Dermatofibrosarcoma protuberans (DFSP) is a locally aggressive sarcoma arising from the skin. DFSP is relatively rare and accounts for approximately 4% of all soft tissue sarcomas (STS). The tumor presents as an indolent growing plaque, usually localized on the trunk, the proximal extremities, or the head-neck region (Figure 1). DFSP is most often diagnosed in young or middle-aged adults, but it has been described in infants and the elderly as well. Most tumors are less than 5 cm, but untreated DFSP can attain massive dimensions.^{[1], [2] and [3]}

Histologically, DFSP is composed of spindle cells arranged in an irregularly whorled or storiform pattern. The histological diagnosis DFSP can be confirmed reliably with immunohistochemical staining for CD34, which is especially helpful in the differential diagnosis from dermatofibroma, also called benign fibrous histiocytoma (BFH).^{[4] and [5]} Approximately 10- 15 % of tumors contain a high-grade fibro-sarcomatous component (DFSP-FS), which is associated with a higher risk of recurrence.^{[6] and [7]} Most DFSP bear a specific chromosomal translocation, t(17;22)(q22;q13), that leads to a fusion between the collagen type 1 α 1 (COL1A1) on chromosome 17 and the platelet-derived growth factor B-chain gene (PDGFB) on chromosome 22. The COL1A1-PDGFB fusion product is detectable by RT-PCR.^[8]

DFSP is especially feared for the high tendency to recur, due to its infiltrative asymmetric growth pattern. The histologic tumor margins occasionally extend far beyond the macroscopic boundaries with asymmetric tentacle like projections. Metastases are rare in DFSP and are usually preceded by multiple local recurrences.^{[1], [9] and [10]}

DFSP is not particularly chemosensitive, but imatinib mesylate seems to emerge as an effective new targeted therapy for locally advanced or uncontrollable DFSP.^[11]

There are still many issues to resolve regarding the optimal local treatment of DFSP. In this study we evaluated the outcome of surgical treatment of primary and recurrent DFSP treated at the University Medical Center Groningen over a three decade period.

ACCEPTED MANUSCRIPT

Patients and Methods

Patients

This study includes 38 patients treated for a primary or recurrent DFSP at the University Medical Center Groningen (UMCG) between 1971 and 2005. The group consisted of 25 males and 13 females with a median age of 38 (range 8-77) years. Clinical and pathologic features were retrieved from the Groningen Sarcoma Database, patient files and the pathology database. Thirty patients presented with a primary tumor, and 8 patients were referred with a local recurrence after previous surgery. Patient and tumor characteristics are listed in Table 1 and 2.

Treatment

Wide local skin excision that includes the underlying subcutaneous tissue and the fascia, with histologic confirmed free margins (R0 resection) was the preferred surgical approach. If anatomical structures allowed it, we tried to resect the tumor with a margin of at least 2-3 cm normal tissue to improve local control.

Of the 20 patients who were primarily treated at the UMCG 13 underwent a single primary excision and 7 patients had to have a re-excision because of inadequate margins. Of the 10 patients that were referred for re-excision at the UMCG 3 patients had to be operated on twice at our center.

Postoperative radiotherapy (50-70 Gy) was administered in case of microscopic involved resection margins (R1 resection), or a narrow excision with no opportunity for further surgical management due to anatomic constraints. In all patients, surgical management was with curative intent.

One patient who had a 15 cm large, primarily irresectable DFSP on the proximal arm, was treated with hyperthermic isolated limb perfusion (HILP) with tumor necrosis factor α (TNF α) and Melphalan.^[12] After six weeks the tumor had successfully reduced in volume and a radical resection was performed. The wound was closed with a split skin graft.

The resection wound was closed primarily in 21 patients, a split skin graft was applied in 13 patients and a plastic surgical reconstruction with a rotation flap was performed in 3 patients .

Histopathology and resection margins

Histopathology of the resected DFSPs was performed in a standard version, including CD34 immunohistochemistry. Grossly specimens were bread-loafed after inking of the resection margins. The resection margin status was examined in multiple tissue sections taken perpendicular to the nearest margin with at least 1 section per cm. Overall a radical excision of the primary tumor was documented in 27 patients (R0). Marginal or microscopically involved resection margins (R1) were documented in 7 patients. In 4 cases of which 3 patients were primarily treated elsewhere, the resection margins of the primary tumor were not documented in the pathology report. The tumors of the three patients that were treated elsewhere were initially not recognized to be malignant and unfortunately not all the tumor tissue material was preserved to allow review of the resection margins retrospectively.

Adjuvant radiotherapy

Adjuvant radiation (50-70 Gy). was applied in 8 (5 primary and 3 recurrent) patients One patient with a primary tumor received radiation because of microscopically involved margins with no opportunity for further resection. The two other patients with microscopically involved margins refused adjuvant radiotherapy. Three patients with negative but marginal resection margins also

received radiation. The patient who underwent a radical resection after a HILP treatment was treated with adjuvant radiotherapy as well, according to the institutional perfusion protocol.^[12]

Patient 6 in Tabel 2 was referred after repeated recurrences that were treated surgically elsewhere. We were able to resect the recurrence marginally and adjuvant radiotherapy was administered.

Results

Patient treated for a primary tumor

Two of the 30 patients who were treated for a primary tumor at our institute developed a local recurrence. These were the two before mentioned patients who had an R1 resection and choose to withdraw from adjuvant radiotherapy. The first patient, who had an R1 resection of a DFSP on the trunk, presented again with a local recurrence 81 months after resection of the primary tumor. The local recurrence was resected with microscopically free margins and at last follow-up the patient was disease free (NED 271 months). The second patient, who had had an R1 resection of a primary tumor in the gluteal region and refused adjuvant radiotherapy, presented with a large local recurrence near the anal sphincter 11 months after resection of the primary tumor. The local recurrence was primarily irresectable and the patient was treated with Imatinib for two months with a dosage of 400 mg twice a day orally.^[11] This resulted in a significant decrease of the tumor volume and after two months a complete resection was performed with preservation of the anal sphincter. Pathologic examination of the resection specimen revealed a small residual tumor of 0.6 cm that was resected with free margins. At last follow-up the patient was disease free (NED 35 months).

Patients referred with a local recurrence

Two of the 8 patients that were referred with a local recurrence developed a second recurrence. The recurrences of these two patients showed histologic progression to DFSP-FS. As mentioned above one of these two patients had been treated for several local recurrences before referral to the UMCG. Despite adjuvant radiotherapy to the site of the local recurrence the patient developed a new recurrence and also a lung metastasis after 26 months follow-up, which was removed by thoracotomy. Pathologic review revealed a 3.5 cm large metastasis that had progressed into DFSP-FS. The tumor was removed completely and adjuvant radiotherapy was administered. Although the lung metastasis was removed completely, the patient later on developed new and extensive pulmonary and soft tissue metastases which were from then on treated palliatively with radiotherapy. This patient eventually died of disseminated disease 15 years after the initial treatment of the primary tumor. None of the other 37 patients developed metastasis.

Local control rate

None of the patients with negative surgical margins, as a single modality, developed a local recurrence, resulting in a 100% local control rate after adequate resection. Of the 8 patients who received adjuvant radiation, only the patient that had been referred after treatment of repeated local recurrence developed a local recurrence resulting in a 82.5% local control rate.

Survival

At last follow-up 9 of 10 patients that were treated for a local recurrence were disease free. The median follow-up of the entire group was 89 (12-271) months. Ten-years disease free survival (DFS) was 85% and 10-years disease specific survival (DSS) was 100%.

ACCEPTED MANUSCRIPT

Discussion

Local recurrence

DFSP is known for its high tendency to recur locally after surgical resection. Recurrence rates reported in literature range from 0-60%.^{[13], [14], [15],[16], [17], [18] and [19]} The chance however of developing a local recurrence was 7% in the UMCG series, which is comparable to low numbers reported by DuBay et al and Fiore et al.^{[17] and [18]} Although local recurrences usually occur within three years after surgical resection of the primary tumor, late relapses may occur.^{[20] and [21]}

Wide local excision (WLE) with histologically confirmed free margins (R0 resection) is the mainstay of surgical treatment of DFSP.^{[1],[14], [15], [18] and [22]} In this series adequate surgical margins as a single modality was associated with 100% local control in all primary DFSPs.

Resection margins

The precise adequate resection margins to achieve local control remain unclear, since the level of evidence is low. Prospective randomized trials assessing resection margins of healthy tissue cannot be performed, due to the rarity of the disease. Kimmel et al investigated resection margins in DFSP and concluded that the clinically apparent size of a DFSP was a poor indicator of the true histologic tumor extent.^[23] In a recently published review by Lemm et al it is reported that studies in which DFSP was excised with undefined or narrow margins, show local failure rates ranged from 26-26%. When a wide local excision (>2cm) was performed, the local failure rate varied from 0-41%, with a total local failure rate of 8.8%.^[19]

In our experience some patients presented with long-existing lesions that were resected several times before. In some cases the patient was initially treated without recognition of the correct

diagnosis.^[14] Patients that presented in our hospital with recurrent lesions had a higher chance of developing another local recurrence and one of these patients eventually developed metastasis.

Sometimes the clinical assessment of optimal surgical margins is restricted by anatomical structures. DFSP may arise in the head and neck area, for example, where it is not always possible to perform a wide local excision with 3-cm free margins. In case of a marginal or positive resection and no opportunity for further surgical treatment due to anatomical limitation, postoperative radiotherapy is indicated.^{[24], [25], [26] and [27]} All patients that had positive or marginal resection margins of a primary tumor and received adjuvant radiotherapy remained disease free during follow-up. Strikingly the two patients that had chosen to withdraw from the indicated adjuvant radiotherapy both developed local relapse.

Mohs micrographic surgery versus WLE

Some professionals advocate Mohs micrographic surgery as an appropriate alternative surgical method in particular for DFSP in anatomically challenging areas.^[28] In Mohs surgery the tissue layers are sequentially removed and examined microscopically during the operation to determine the extend of tumor invasion. Sequential layers are excised until the malignancy has been removed completely.^[28] Mohs surgery is a time-consuming technique though, and for DFSP it is sometimes difficult to differentiate scattered malignant spindle cells from normal fibroblasts in cryostat frozen tissue sections.^{[19] and [29]} Although CD34 immunostaining is positive in 90% of DFSP can be negative in nodular areas of the tumor and it is therefore not a 100% reliable tool to detect residual tumor.^{[29] and [30]} Our results show that DFSP and recurrent DFSP can usually be well managed with WLE as a single modality or if indicated combined with radiotherapy.

Surgical reconstruction

In case of extended resection, split skin grafts or plastic surgical reconstruction can be applied to cover the surgical defect. If a reconstruction is required, it is important that there be no doubt about the resection margin, since the (rotation) flap may prevent early detection of a local recurrence. In our series a plastic surgical reconstruction with a rotation flap was employed in three patients and all three were performed in one tempi. In case of initially doubtful resection margins however, extensive reconstructions should be delayed until appropriate surgical margins are confirmed by pathologic examination.^{[31] and [32]}

Metastasis

Only one patient in our series developed pulmonary metastasis, which was from a locally recurred tumor on the shoulder that had histologically progressed to DFSP-FS. Metastasis is rare in DFSP and is usually preceded by multiple local recurrences.^[3] DFSP-FS progressed tumors are associated with a more aggressive clinical course, and a significantly higher chance of metastasis than classic DFSP.^{[6] and [7]} The four patients that were initially diagnosed with DFSP-FS in our series remained disease free though, with relatively long-term follow-up.

Imatinib

Imatinib mesylate has recently become available as a targeted therapy for primarily irresectable or metastatic DPFS. Unfortunately the patient that had developed pulmonary metastasis in our series had died before Imatinib had been developed and recognized for DFSP. Later on another patient in our series who had developed a large irresectable local recurrence in the gluteal region was successfully treated with Imatinib prior to resection. The Imatinib treatment had effectively reduced the tumor mass and an R0-resection could be performed with preservation of the anal sphincter. Few similar case studies have been reported and preliminary trial results seem

promising. There is no role for Imatinib in the adjuvant treatment of DFSP though, as the use of Imatinib is still experimentally and no prospective data are currently available to prove a benefit in terms of progression free and overall survival and theoretically adjuvant use of imatinib may even facilitate the growth of resistant clones. The precise role of Imatinib in a limited subgroup of locally advanced or uncontrollable DFSP is currently under intensive investigation in clinical trials.^{[11], [33], [34] and [35]}

Conclusion

Clinicians often have to deal with unfavourable presentations of DFSP, due to patient delay, initial misdiagnosis and unfavourable anatomic localisation. The mainstay in treatment of DFSP is resection with a wide surgical margin (> 2 cm). If adequate surgical margins cannot be obtained without severe functional or cosmetic impairments postoperative radiotherapy should be applied.

Conflict of interest statement

All authors declare that there are no financial or personal relationships with other people or organisations that could have inappropriately influenced our work.

ACCEPTED MANUSCRIPT

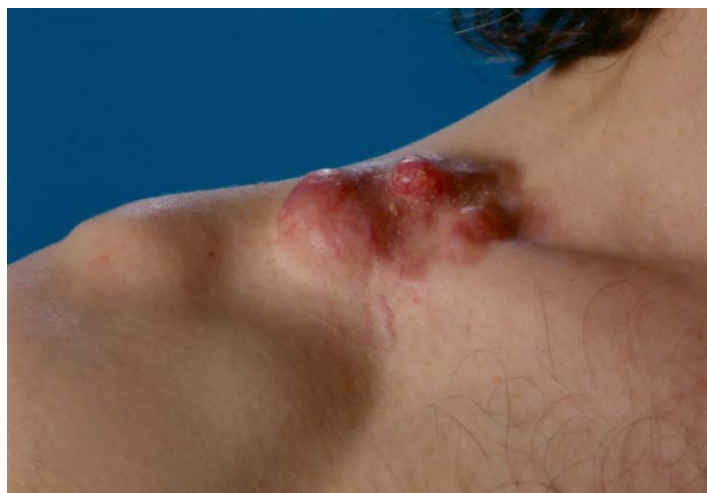Literature

- 1 Kleihues P, Sobin L, Dermatofibrosarcoma protuberans. In: LeBoit PE, Burg G, Weedon D, Sarasin A. World Health Organization Classification of Tumours: pathology and Genetics of Skin Tumors. Lyon: IARC Press; 2007;259-261.
- 2 Toro JR, Travis LB, Wu HJ, Zhu K, Fletcher CD, Devesa SS. Incidence patterns of soft tissue sarcomas, regardless of primary site, in the surveillance, epidemiology and end results program, 1978-2001: An analysis of 26,758 cases. *Int J Cancer*. 2006;19:2922-30.
- 3 Mendenhall WM, Zlotecki RA, Scarborough MT. Dermatofibrosarcoma protuberans. *Cancer*. 2004;101:2503-8.
- 4 Kutzner H. Expression of the human progenitor cell antigen CD34 (HPCA-1) distinguishes dermatofibrosarcoma protuberans from fibrous histiocytoma in formalin-fixed, paraffin-embedded tissue. *J Am Acad Dermatol*. 1993;28:613-7.
- 5 Abenoza P, Lillemoe T. CD34 and factor XIIIa in the differential diagnosis of dermatofibroma and dermatofibrosarcoma protuberans. *Am J Dermatopathol*. 1993;15:429-34.
- 6 Abbott JJ, Oliveira AM, Nascimento AG. The prognostic significance of fibrosarcomatous transformation in dermatofibrosarcoma protuberans. *Am J Surg Pathol*. 2006;30:436-43.
- 7 Mentzel T, Beham A, Katenkamp D, Dei Tos AP, Fletcher CD. Fibrosarcomatous ("high-grade") dermatofibrosarcoma protuberans: clinicopathologic and immunohistochemical study of a series of 41 cases with emphasis on prognostic significance. *Am J Surg Pathol*. 1998;22:576-87.
- 8 Sandberg AA, Bridge JA. Updates on the cytogenetics and molecular genetics of bone and soft tissue tumors. Dermatofibrosarcoma protuberans and giant cell fibroblastoma. *Cancer Genet Cytogenet*. 2003;140:1-12.
- 9 Rutgers EJ, Kroon BB, Albus-Lutter CE, Gortzak E. Dermatofibrosarcoma protuberans: treatment and prognosis. *Eur J Surg Oncol*. 1992;18:241-8.
- 10 Häfner HM, Moehrle M, Eder S, Trilling B, Röcken M, Breuninger H. 3D-Histological evaluation of surgery in dermatofibrosarcoma protuberans and malignant fibrous histiocytoma: differences in growth patterns and outcome. *Eur J Surg Oncol*. 2008;34:680-6.
- 11 McArthur GA, Demetri GD, van Oosterom A, Heinrich MC, Debiec-Rychter M, Corless CL, et al. Molecular and clinical analysis of locally advanced dermatofibrosarcoma protuberans treated with imatinib: Imatinib Target Exploration Consortium Study B225. *J Clin Oncol* 2005; 23:866–73

- 12 Van Ginkel RJ, Thijssens KM, Pras E, Van Der Graaf WT, Suurmeijer AJ, Hoekstra HJ. Isolated limb perfusion with tumor necrosis factor alpha and melphalan for locally advanced soft tissue sarcoma: three time periods at risk for amputation. *Ann Surg Oncol*. 2007;14:1499-506.
- 13 Monnier D, Vidal C, Martin L, Danzon A, Pelletier F, Puzenat E, et al. Dermatofibrosarcoma protuberans: a population-based cancer registry descriptive study of 66 consecutive cases diagnosed between 1982 and 2002. *J Eur Acad Dermatol Venereol*. 2006;20:1237-42.
- 14 Lindner NJ, Scarborough MT, Powell GJ, Spanier S, Enneking WF. Revision surgery in dermatofibrosarcoma protuberans of the trunk and extremities. *Eur J Surg Oncol*. 1999;25:392-7.
- 15 Bowne WB, Antonescu CR, Leung DH, Katz SC, Hawkins WG, Woodruff JM, et al. Dermatofibrosarcoma protuberans: A clinicopathologic analysis of patients treated and followed at a single institution. *Cancer*. 2000;88:2711-20.
- 16 Chang CK, Jacobs IA, Salti GI. Outcomes of surgery for dermatofibrosarcoma protuberans. *Eur J Surg Oncol*. 2004;30:341-5.
- 17 DuBay D, Cimmino V, Lowe L, Johnson TM, Sondak VK. Low recurrence rate after surgery for dermatofibrosarcoma protuberans: a multidisciplinary approach from a single institution. *Cancer*. 2004;100:1008-16.
- 18 Fiore M, Miceli R, Mussi C, Lo VS, Mariani L, Lozza L, et al. Dermatofibrosarcoma protuberans treated at a single institution: a surgical disease with a high cure rate. *J Clin Oncol*. 2005;23:7669-75.
- 19 Lemm D, Mügge LO, Mentzel T, Höffken K. Current treatment options in dermatofibrosarcoma protuberans. *J Cancer Res Clin Oncol*. 2009;135:653-65
- 20 Swan MC, Banwell PE, Hollowood K, Goodacre TE. Late recurrence of dermatofibrosarcoma protuberans in the female breast: a case report. *Br J Plast Surg*. 2005;58:84-7.
- 21 Orlando R, Lumachi F, Lirussi F. Recurrent dermatofibrosarcoma protuberans sixteen years after radical excision. A case report. *Anticancer Res*. 2003;23:4233-4.
- 22 Khatri VP, Galante JM, Bold RJ, Schneider PD, Ramsamooj R, Goodnight JE, Jr. Dermatofibrosarcoma protuberans: reappraisal of wide local excision and impact of inadequate initial treatment. *Ann Surg Oncol* 2003;10:1118-22
- 23 Kimmel Z, Ratner D, Kim JY, Wayne JD, Rademaker AW, Alam M. Peripheral excision margins for dermatofibrosarcoma protuberans: a meta-analysis of spatial data. *Ann Surg Oncol* 2007;14:2113-20

- 24 Ballo MT, Zagars GK, Pisters P, Pollack A. The role of radiation therapy in the management of dermatofibrosarcoma protuberans. *Int J Radiat Oncol Biol Phys.* 1998;40:823-7.
- 25 Suit H, Spiro I, Mankin HJ, Efird J, Rosenberg AE. Radiation in management of patients with dermatofibrosarcoma protuberans. *J Clin Oncol.* 1996;14:2365-9.
- 26 Dagan R, Morris CG, Zlotecki RA, Scarborough MT, Mendenhall WM. Radiotherapy in the treatment of dermatofibrosarcoma protuberans. *Am J Clin Oncol.* 2005;28:537-9.
- 27 Haas RL, Keus RB, Loftus BM, Rutgers EJ, Coevorden F van, Bartelink H. The role of radiotherapy in the local management of dermatofibrosarcoma protuberans. Soft Tissue Tumours Working Group. *Eur J Cancer.* 1997;33:1055-60.
- 28 Snow SN; Gordon EM; Larson PO; Bagheri MM; Bentz ML; Sable DB Dermatofibrosarcoma protuberans: a report on 29 patients treated by Mohs micrographic surgery with long-term follow-up and review of the literature. *Cancer* 2004 Jul 1;101(1):28-38
- 29 Massey RA, Tok J, Strippoli BA, Szabolcs MJ, Silvers DN, Eliezri YD. A comparison of frozen and paraffin sections in dermatofibrosarcoma protuberans. *Dermatol Surg* 1998;24:995-8
- 30 Garcia C, Viehman G, Hitchcock M, Clark RE. Dermatofibrosarcoma protuberans treated with Mohs surgery. A case with CD34 immunostaining variability. *Dermatol Surg* 1996;22:177-9
- 31 Brabant B, Revol M, Vergote T, Servant JM, Banzet P. Dermatofibrosarcoma protuberans of the chest and the shoulder: Wide and deep excision with immediate reconstruction. *Plast. Reconstr. Surg.* 1993;92:459-62
- 32 Arnaud EJ, Perrault M, Revol M, Servant JM, Banzet P. Surgical treatment of dermatofibrosarcoma protuberans. *Plast Reconstr Surg.* 1997;100:884-95.
- 33 Mehrany K, Swanson NA, Heinrich MC, Weenig RH, Lee KK, White CR, Jr., et al. Dermatofibrosarcoma protuberans: a partial response to imatinib therapy. *Dermatol Surg.* 2006;32:456-9.
- 34 Sirvent N, Maire G, Pedoutour F. Genetics of dermatofibrosarcoma protuberans family of tumors: from ring chromosomes to tyrosine kinase inhibitor treatment. *Genes Chromosomes Cancer.* 2003;37:1-19.
- 35 Labropoulos SV, Fletcher JA, Oliveira AM, Papadopoulos S, Razis ED. Sustained complete remission of metastatic dermatofibrosarcoma protuberans with imatinib mesylate. *Anticancer Drugs.* 2005;16:461-6.

Figure 1. Dermatofibrosarcoma protuberans manifesting as an irregular red plaque on the right shoulder.



ACCEPTED MANUSCRIPT

Table 1. *Clinical and pathological features of the 30 patients treated for primary dermatofibrosarcoma protuberans at the UMCG*

	No.
Sex	
Male	19
Female	11
Median age (range)	38 (8-77)
Median tumor size (cm) (range)	3 (0.5-22)
Histo-type	
DFSP	26
DFSP-FS	4
Localization	
Trunk	9
Shoulder	7
Upper arm	5
Head-neck	5
Buttock	2
Groin	2
Reason Referral	
Diagnosis and treatment primary tumor	11
Treatment primary tumor	9
Re-excision primary tumor	10
Treatment	
Resection	30
Times operated on at the UMCG	
Once	20
Twice	10
Resection margins	
Negative	24
Negative, but marginal	3
Positive	3
Adjuvant radiotherapy	5
Survival	
Median follow-up (range)	80 (12-261)
LF	2
LF, local failure	

Table 2. *Clinical and pathological features of the 8 patients that were referred with recurrent dermatofibrosarcoma protuberans*

Patient No.	Reason Referral	Age (yr) at diagnosis primary tumor/ sex	Histo-type primary tumor	Localization primary tumor (size (cm))	Treatment primary tumor (margins)	Treatment LF (times operated on at the UMCG) (resection margin) (mo)	Recurrence after treatment UMCG (mo)	Metastasis (mo)	Survival (mo)
1	LF	38/M	DFSP	trunk (≤ 5)	resection (neg)	resection (1) (neg) (50)			NED (70)
2	LF	29/M	DFSP	abdomen (≤ 5)	resection (pos)	resection (1) (neg) (6)			NED (112)
3	LF	35/M	DFSP-FS	upper arm (5)	resection (pos)	resection (1) (pos), RT (6)			NED (118)
4	LF	38/M	DFSP	shoulder (N.A.)	resection (pos),	resection (1) (neg) (53)			NED (156)
5	LF	23/F	DFSP	trunk (8)	resection (n.a.)	resection (1) (neg) (144)	LF (81)		NED (261)
6	LF	38/F	DFSP	shoulder (N.A.)	resection (pos)	resection (1) (neg, marg), RT (53)	LF (3)	Pulmonary (26)	DOD (182)
7	LF	8/M	DFSP	trunk (1)	resection (n.a.)	resection (1) (n.a.) (163)			NED (269)
8	LF	55/M	DFSP	head (9)	resection (n.a.),	resection (1) (pos), RT (26)			NED (251)

DOD, death of disease; F, female; LF, local failure; M, male; marg, resection margins marginal; mo, months; NED, no evidence of disease; N.A., not available; neg, resection margins negative; pos, resection margins positive; Rx, resection margin unknown; RT, radiotherapy; yr, year;