HAL
open science

The preoperative stratification of patients with colorectal liver metastases: computed tomography arterial portography (CTAP) has no added value

S.T.P. Kouwenhoven, G.J. Liefers, A.R. van Erkel

To cite this version:

S.T.P. Kouwenhoven, G.J. Liefers, A.R. van Erkel. The preoperative stratification of patients with colorectal liver metastases: computed tomography arterial portography (CTAP) has no added value. EJSO - European Journal of Surgical Oncology, 2010, 36 (1), pp.36. 10.1016/j.ejso.2009.05.011 . hal-00556312

HAL Id: hal-00556312

https://hal.science/hal-00556312v1

Submitted on 16 Jan 2011

HAL is a multi-disciplinary open access archive for the deposit and dissemination of scientific research documents, whether they are published or not. The documents may come from teaching and research institutions in France or abroad, or from public or private research centers.

L'archive ouverte pluridisciplinaire **HAL**, est destinée au dépôt et à la diffusion de documents scientifiques de niveau recherche, publiés ou non, émanant des établissements d'enseignement et de recherche français ou étrangers, des laboratoires publics ou privés.

Accepted Manuscript



Title: The preoperative stratification of patients with colorectal liver metastases: computed tomography arterial portography (CTAP) has no added value

Authors: S.T.P. Kouwenhoven, G.J. Liefers, A.R. van Erkel

PII: S0748-7983(09)00176-0

DOI: 10.1016/j.ejso.2009.05.011

Reference: YEJSO 2843

To appear in: *European Journal of Surgical Oncology*

Received Date: 8 September 2008

Revised Date: 24 May 2009

Accepted Date: 28 May 2009

Please cite this article as: Kouwenhoven STP, Liefers GJ, van Erkel AR. The preoperative stratification of patients with colorectal liver metastases: computed tomography arterial portography (CTAP) has no added value, European Journal of Surgical Oncology (2009), doi: 10.1016/j.ejso.2009.05.011

This is a PDF file of an unedited manuscript that has been accepted for publication. As a service to our customers we are providing this early version of the manuscript. The manuscript will undergo copyediting, typesetting, and review of the resulting proof before it is published in its final form. Please note that during the production process errors may be discovered which could affect the content, and all legal disclaimers that apply to the journal pertain.

ARTICLE IN PRESS

The preoperative stratification of patients with colorectal liver metastases: computed tomography arterial portography (CTAP) has no added value.

S.T.P. Kouwenhoven [a,b*], G.J. Liefers [b], A.R. van Erkel [a]

[a] Department of Radiology, Leiden University Medical Centre, Albinusdreef 2, PO Box 9600 2300 RC Leiden, the Netherlands.
[b] Department of Oncological Surgery, Leiden University Medical Centre, Albinusdreef 2, PO Box 9600 2300 RC Leiden, the Netherlands.

*Corresponding author:
S.T.P. Kouwenhoven
Leiden University Medical Centre
Albinusdreef 2
Department op Radiology, C3-Q
PO Box 9600
2300 RC Leiden
The Netherlands
Tel. +31715264367
Fax. +31715248256
s.t.p.kouwenhoven@umail.leidenuniv.nl

G.J. Liefers
Leiden University Medical Centre
Albinusdreef 2
Department of Surgical Oncology, K6-R
PO Box 9600
2300 RC, Leiden
Tel. +31 71 526 2309
Fax. +31 71 526 6750
G.J.Liefers@lumc.nl

A.R. van Erkel
Leiden University Medical Centre
Albinusdreef 2
Department of Radiology, C3-Q
PO Box 9600
2300 RC Leiden
The Netherlands
Tel. +31715264367
Fax. +31715248256
A.R.van_Erkel@lumc.nl

ACCEPTED MANUSCRIPT

ARTICLE IN PRESS

Abstract

AIMS. The purpose of this study was to determine if Computed Tomography Arterial Portography (CTAP) has additional value to Contrast Enhanced helical CT (CE-CT) in selecting patients for hepatic surgery or Isolated Hepatic Perfusion / systemic chemotherapy.
MATERIALS AND METHODS. Forty-one patients were included. All CT's were performed in the normal pre-operative work-up of patients with liver metastases in our regular clinical setting and reviewed blinded by a radiologist. For CE-CT and CTAP the number, size (largest diameter) and location of all suspected malignant liver lesions were recorded. The favourable treatment option was determined based on the results of CE-CT and CTAP independently. The therapeutic decision based on CE-CT and CTAP was compared with the definite treatment. For all patients with recorded findings during surgery, consisting of intra-operative ultrasound, liver palpation and histology a standard of reference for lesion detection was available. For these patients detection rates and the fraction of false positive lesions were calculated.
RESULTS. Twenty-seven patients were treated with hepatic resection and/or RFA. Fourteen patients were treated with chemotherapy, 4 with Isolated Hepatic Perfusion (IHP) and 10 with systemic therapy. Based on the findings on CE-CT 31 patients were classified as surgical candidates and 10 as non-surgical patients. Based on the findings on CTAP, surgery should be the treatment of choice in 29 patients and 12 patients were classified non-surgical. CE-CT and CTAP disagreed in two cases (4.9%). Seventy-four metastases were identified at surgery and pathologically proved. CE-CT and CTAP showed 53 (.72) and 66 (.89) metastases, respectively.
CONCLUSION. Despite a significantly higher detection rate for hepatic metastases, CTAP has no added value in the therapeutic stratification in candidates for resection of hepatic metastases of colorectal cancer.

Keywords:

computed tomography, arterial portography, liver, metastases, stratification, colorectal cancer

ACCEPTED MANUSCRIPT

Introduction

For tailored treatment choices in patients with liver metastases of colorectal cancer, imaging of the liver is crucial with successful diagnosis primarily depending on liver-to-lesion contrast and spatial resolution. Despite MRI (gadolinium- and SPIO-enhanced or MnDPDP) or F18-FDG-PET scanning are being recognised as more sensitive imaging modalities for detecting metastases and becoming a pre-operative standard in this patient population [1-3], dynamic Contrast Enhanced helical CT (CE-CT), is still the most frequently used imaging technique in these patients with reported overall sensitivity ranging from 63% to 85% and false positive findings in 4% [4-6].

In CE-CT with arterial portography (CTAP) contrast is delivered to the liver through the portal vein after catheterising the superior mesenteric artery. Hepatic colorectal metastases do not drain blood from the portal venules and are visualised on CTAP as low-density areas. CTAP has higher accuracy compared to helical CE-CT with reported sensitivities of CTAP for detection of hepatic metastases from colorectal cancer up to 94% [6,7]. Higher sensitivity of CTAP compared to CE-CT comes at a price. CTAP is costly and invasive, and perfusion defects result in false positive findings up to 17% [6,7]. As a result of a false positive finding surgical treatment may be denied in potential surgical candidates.

Better accuracy does not necessarily mean better treatment choice or better prognosis. Several studies have compared the sensitivity and specificity of helical CE-CT and CTAP, the purpose of this study was to determine if CTAP has additional clinical value to CE-CT in selecting patients for hepatic surgery or isolated hepatic perfusion (IHP)/systemic chemotherapy.

ACCEPTED MANUSCRIPT

Materials and methods

Patient selection

A review of the computerized radiology database at our centre revealed that between January 1, 2000 and December 31, 2005, 96 patients with a primary colorectal tumor and suspected liver metastases underwent CTAP. Only patients who had a CE-CT examination of chest and abdomen followed by a CTAP examination within 6 weeks were selected.

If the CE-CT examination was performed in another hospital prior to referral, the imaging data were requested and obtained for analysis. Forty-one patients were included. In 4 patients the CTAP was performed inadvertently because of extra-hepatic disease on the CE-CT. Fourteen patients were excluded because the imaging data of CE-CT examinations received from other hospitals were too rough for comparison with the CTAP studies. In 20 patients the data from CE-CT or CTAP imaging could not be retrieved from the archive. One patient had a liver abscess instead of malignancy and was excluded (Figure 1). All CT's were performed in the normal pre-operative work-up of patients with liver metastases in our regular clinical setting and retrospectively analysed and no approval of the local medical ethics committee was necessary.

----Fig1.tiff----

Imaging protocols

For CE-CT imaging, 16 Patients were examined on a single detector row scanner (SR, Philips, Netherlands, collimation: 3mm, table movement: 5mm, reconstructed slice thickness: 3mm), 10 on a four detector row spiral CT scanner (Aquilion 4, Toshiba, Japan, collimation: 2mm, detector pitch: 5.5, reconstructed slice thickness: 5mm, interval index: 4mm), 9 on a 16 detector row spiral CT scanner (Aquilion 16, Toshiba, Japan, collimation: 1mm, detector pitch: 15, reconstructed slice thickness: 5mm, interval index: 4mm) and 6 examinations on a 64 detector row spiral CT scanner (Aquilion 64, Toshiba, Japan, collimation: 0.5mm, detector pitch: 53, reconstructed slice thickness: 5mm, interval index: 5mm). In 29 of the selected patients the CE-CT prior to CTAP was performed in our centre. Of the 12 cases imaged elsewhere 9 were performed on a SR single detector row scanner and 3 on an Aquilion 4 multislice.

At our centre a CE-CT of the liver is performed after 1000ml of oral contrast (Telebrix

ACCEPTED MANUSCRIPT

350/gastro 3% solution). After a non-contrast enhanced scan a maximum amount of 150ml Xenetix 300 (max. 2ml/kg bodyweight) was injected intravenously at a flow rate of 3ml/sec. and a portal venous phase scan was performed using a sure start (threshold +100HU + 50sec.). For the CE-CT examinations that were performed outside our hospital, the specific imaging parameters were not known.

All for the CTAP examinations were performed in our centre; 13 on a single detector row CT scanner (SR, Philips, Netherlands), 5 on a 4 detector row spiral CT scanner (Aquilion 4, Toshiba, Japan), 15 on 16 detector row spiral CT scanner (Aquilion 16, Toshiba, Japan) and 8 on a 64 slice spiral CT scanner (Aquilion 64, Toshiba, Japan), as described above. For CTAP, a catheter was placed into the superior mesenteric artery. After catheter placement a total amount of 100ml Hexabrix 200 was injected at a rate of 2ml/sec for multislice scanners and 3ml/sec for single slice scanners. A portal phase scan of the liver was performed with a sure start for multislice (+50HU + 10sec.) and without sure start after 40sec. for single slice and a delayed phase scan of the abdomen was performed after delay of 120sec.

No scanning protocols of scans that were performed in other hospitals could be obtained.

Data Collection

CE-CT and CTAP data of examinations before September 1, 2003 were retrieved from optical disc and transferred to the online digital database (Hyperarchiver, Rogan, Netherlands). Imaging data from September 1, 2003 to December 31, 2005 was already stored on the online database. All imaging data were uploaded on the workstation (Vitrea 2003, Vital images, USA) for analysis.

A radiologist (A.R.E) experienced in evaluating pre-operative liver images, retrospectively reviewed the diagnostic data. The CTAP examinations were reviewed after the CE-CT examinations to resemble the clinical setting. The radiologist was blinded for the result and the final therapeutic intervention and clinical outcome. For CE-CT and CTAP the number, size (largest diameter) and location of all suspected malignant liver lesions were recorded. The anatomy of the hepatic arteries was determined and the favourable treatment option was determined based on the results of CE-CT and CTAP independently. Three treatment options were available: surgical resection and/or ablation therapy, isolated hepatic perfusion (IHP) and systemic chemotherapy. All patients with resectable disease underwent surgery. Patients with diffuse, multiple, and bilobar disease (usually >5 metastases) and patients where adequate resection margins could not be reached (metastases centrally located) were considered candidates for IHP [8]. Patients with extra-hepatic disease were not considered

ACCEPTED MANUSCRIPT

candidates for locoregional treatment of their liver metastases. Typically, these patients were offered palliative systemic treatment.

Data Analysis

Except for patients that were treated with systemic chemotherapy, the definite treatment decision was made during laparatomy, based on the findings of intra-operative ultrasound by a radiologist and palpation of the liver by a liver surgeon. The therapeutic decision based on CE-CT and CTAP was compared with the definite treatment, which was used as standard of reference. Because the main purpose of this study was to investigate how successful CE-CT and CTAP can identify potential surgical candidates, IHP and systemic therapy were computed together as 'non-surgical option' and resection and/or RFA as 'surgical option'. The kappa measure of agreement was used to correlate the outcomes.

All pre- and intraoperative findings and results were imported in Microsoft Excel 2000 where lesions found on CE-CT, CTAP and reference standard were numbered, in a way that the lesions found on CE-CT matched the exact same lesions on CTAP and intra-operative findings. In this manner the choice for a certain treatment option or discrepancies between CTAP en CE-CT could be reviewed and explained.

For all patients with recorded findings during surgery a standard of reference for lesion detection was available, consisting of intra operative ultrasound, liver palpation and histology. For these patients detection rates and the number of false positive lesions were calculated. A chi-square test was used to analyse the difference in the detection rate of metastases in CE-CT and CTAP compared with the standard of reference (after regression analysis to rule out extreme single case values). The significance level was set at $p < .05$. The statistical calculations were performed with SPSS for windows (12.0.1).

ACCEPTED MANUSCRIPT

Results

Patients

The study group composed of 25 men (61%) and 16 women (39%). The mean patient age was 61.98 years (SD: 9.67, range 26-80 years). Five patients had undergone prior surgical treatment (2) or ablation therapy (3) for liver metastases.

Twenty-seven patients were treated with hepatic resection and/or RFA. Fourteen patients were treated with chemotherapy, 4 with IHP and 10 with systemic therapy.

Measure of agreement

Based on the findings on CE-CT alone, 31 patients were classified as surgical candidates and 10 as non-surgical patients, 4 to be treated with IHP and 6 patients to receive systemic therapy Based on the findings on CTAP, surgery should be the treatment of choice in 29 patients and 12 patients were classified non-surgical, 6 patients for IHP and 6 patients to receive systemic For both CE-CT and CTAP the correlation with the definite treatment was very high; measure of agreement kappa: 0.767 for CE-CT (standard error: 0.108) and 0.888 for CTAP (standard error: 0.079). The difference in the kappa values was not statistically significant. Correlation between CE-CT and CTAP was very high (kappa: 0.876) and can be interpreted as excellent. In only 2 cases (4,9%) CE-CT and CTAP disagreed. In both patients the treatment option that was given based on the CTAP corresponded with the actual treatment.

First case

The first patient is a female of 57 years with a history of low anterior resection for adenocarcinoma of the recto-sigmoid in 1997 and metastasectomy of lesions in segments II and VI in 1998. A local recurrence in the mesocolon was resected successfully in 2003. In May 2005 a newly detected lesion in segment VIII of the liver was treated with RFA.

In September 2005 new liver metastases were detected on routine follow-up CE-CT and a CTAP was performed. Reviewing that CE-CT, 6 liver metastases were suspected in segments IVb (1) and VIII (5) and surgery and/or RFA was considered feasible. The CTAP showed 12 lesions in segments III (1), IVa (1), IVb (1), VII (2) and VIII (7) and IHP was proposed (Figure 2). At the time of clinical presentation not all 12 lesions were considered metastases and surgical resection was considered feasible. During surgery, IOUS and palpation

ACCEPTED MANUSCRIPT

determined that resection was technically impossible and the patient was treated with systemic chemotherapy.

----Fig2a.tiff---- ----Fig2b.tiff----

----Fig2c.tiff---- ----Fig2d.tiff----

Second case

The second patient is a 67-year-old female with suspected liver metastases after resection of adenocarcinoma of the colon in September 1999. On a CE-CT in June 2000 new liver lesions were detected and within 14 days a CTAP was performed. Reviewing the CE-CT study two suspected metastases were found in segments VI (90mm) and VII (75mm). Resection and/or RFA was proposed based on the CE-CT. Reviewing the CTAP study four suspected lesions in segments VI (100 mm), VII (82 mm), IVa (14 mm) and I (11 mm) were found and a close relationship with vital structures was present (Figure 3). Based on these findings chemotherapy was proposed. During follow up lesions responded to systemic chemotherapy and were reduced in size.

----Fig3a.tiff---- ----Fig3b.tiff----

----Fig3c.tiff----

Detection of lesions

For 30 patients a standard of reference for lesion detection was available, consisting of intra-operative ultrasound, liver palpation and histology. In these patients a total of 74 hepatic metastases was present. Twelve metastases were smaller than 10mm, 33 were ranging from 10mm to 20mm and 29 were greater than 20mm. The detection rate for CE-CT was .72 (53/74) and for CTAP .89 (66/74). The fraction of false positive lesions for CE-CT was .19 (13/66) and .29 (27/93) for CTAP (Table 1).

Evaluation of the rate of detected lesions between CTAP and CECT referred to standard of reference (findings during surgery, PA and follow-up) with the chi-square test demonstrated that the detection rate between CTAP and the detection rate of CE-CT differed significantly

ACCEPTED MANUSCRIPT

($p < 0.01$). The difference in the fraction of false positive lesions (.10) was calculated the same way and was not statistically different ($p= 0.15$). The 95% CI's for the difference in detection rate (.17) and fraction of false positive lesions (.10) were .05 - .29 and -.04 - .23 respectively.

ACCEPTED MANUSCRIPT

ARTICLE IN PRESS

Discussion

Detection rate and false positive lesions

The clinical work-up in our hospital for patients with hepatic metastasis of colorectal cancer until recently consisted of a CE-CT of chest and abdomen, followed by a CTAP in potential surgical candidates. It is well known from the literature that the detection rate for liver metastases of CTAP is high compared to CE-CT [6,9,10]. In this study the detection rate of CTAP was .89, significantly higher than the detection rate of CE-CT of .72. In addition our study shows that this improvement of detection rates did not lead to a significant change in therapeutic strategies.

This study also confirms the results from literature that perfusion defects in CTAP studies will lead to a relatively high number of false positive results [5,7,11]. In this particular patient group, a false positive finding can result in a situation where surgical treatment can inadvertedly be denied in surgical candidates. In this study the fraction of false positive findings was .19 for CE-CT and .29 for CE-CT.

Discrepancy

With CTAP in the diagnostic work-up for liver surgery, a costly and invasive test is introduced causing additional delay in the final treatment of the patient. In this study, 16 of 96 patients were excluded because the time between CE-CT and CTAP exceeded 6 weeks.

In 41 patients the correlation of CE-CT and CTAP, with regards to the treatment decision, was very high (kappa: 0.876). In only 2 patients (4.9%) there was disagreement between CE-CT and CTAP. In both patients adding CTAP to the work-up would alter the treatment choice from surgical to chemotherapy, thus avoiding unnecessary surgery. In the first patient, the correct diagnosis of CTAP was confirmed at surgery. In the second patient, however, no surgery was performed and the detected liver metastases were not verified with intra-operative ultrasound and liver palpation. Response of the lesions on the chemotherapy during follow-up indicated the true malignant nature of the lesions.

MTA

The medical technology assessment (MTA) of imaging modalities classically consists of six levels of efficacy: technical efficacy, diagnostic accuracy efficacy, and diagnostic thinking

ACCEPTED MANUSCRIPT

efficacy, therapeutic thinking efficacy, patient outcome efficacy and societal efficacy [12]. Most studies in this field focus on the detection of liver metastases (diagnostic accuracy efficacy), but a higher detection rate does not necessarily mean a better treatment decision. The purpose of this study was to determine if CTAP has additional value to CE-CT, on the level of therapeutic thinking efficacy, in selecting patients for hepatic surgery or IHP/systemic chemotherapy.

A study comparing and correlating CE-CT and CTAP in selecting patients for surgical treatment and chemotherapy in the preoperative assessment of patients with colorectal liver metastases was to our knowledge not previously performed. Soyer et al. compare CE-CT and CTAP in determination of resection type in surgically treated patients. In this particular study involving 28 patients CTAP resulted in changed surgical decision in five patients [13]. In a study of Small et al. findings on CTAP prevented needless surgery in 64% of patients with hepatic tumors, but were compared with either sonograms or CT scans from referring hospitals and no elapsed time between the CTAP study and prior investigation was noted. Only 49% of the patients in the study population had hepatic metastases from colorectal carcinoma [14].

Limitations

A potential bias in the study is caused by the fact that a large number of patients was excluded. Only patients with a CTAP investigation within 6 weeks after CE-CT were included in our study. Before September 1, 2003 mostly hardcopy images were available or data could not be retrieved, but it was important to be strict in the inclusion criteria and necessary to observe all the images the same way, quality and medium accounted for.

All CT images were assessed by only one blinded observer and forms another limitation of this study. A multi observer design with inter-observer correlation would be ideal for this type of research.

Another limitation is caused by the rapid development in CT scanners over the past years. From January 1, 2000 to December 31, 2005 patients were scanned on a single slice to a 64slice scanner, but with no particular advantages to either CE-CT or CTAP. The improvements in CT technique will result in higher liver-to-lesion contrast and spatial resolution and have their impact on therapeutic decision [15].

ACCEPTED MANUSCRIPT

Conclusion

The field of liver imaging is rapidly developing and several newer techniques such as gadolinium- and SPIO enhanced MRI as well as F18-FDG-PET are significantly more accurate than CT [1-3]. In this study we have demonstrated that higher accuracy does not mean better treatment. Therefore the question is raised if the better accuracy of MR techniques or PET will result in better treatment strategies in patients with hepatic metastases of colorectal cancer. Despite a significantly higher detection rate for hepatic metastases, CTAP has no added value in the therapeutic stratification of candidates for surgical treatment of hepatic metastases from colorectal cancer. All studies of imaging techniques for colorectal metastases should also be viewed in the light of therapeutic benefit. Maybe for the treatment choices of patients with liver metastases: less is more.

Conflict of Interest

All authors declare that there are no conflicts of interest.

ACCEPTED MANUSCRIPT

References

1. Koh DM, Brown G, Riddell AM, et al. Detection of colorectal metstases using MnDPDP MR imaging and diffusion-weighted imaging (DWI) alone and in combination. Eur Radiol. 2008;18:903-10.
2. Ward J, Robinson PJ, Guthrie JA, Downing S, et al. Liver metastases in candidates for hepatic resection: comparison of helical and gadolinium and SPIO enhanced MR imaging. Radiology. 2005;237:170-80.
3. Huguet EL, Old S, Praseedom, RK, Balan KK, Gibbs P, Jamieson NV. F18-FDG-PET evaluation of patients for resection of colorectal liver metastases. Hepatogastroenterology. 2007;54:1667-71.
4. Valls C, Andia E, Sanchez A, Guma A, Figueras J, Torras J, Serrano T. Hepatic metastases from colorectal cancer: Preoperative detection and assessment of respectability with helical CT. Radiology 2001;218:55-60.
5. Kuszyk BS, Bluemke DA, Urban BA, Choti MA, Hruban RH, Sitzmann JV, Fishman EK. Portal phase contrast enhanced helical CT for the detection of malignant hepatic tumors: sensitivity based on comparison with intraoperative and pathologic findings. AJR 1996;166:91-5
6. Schwartz et al. Prospective, blinded comparison of helical CT and CT arterial portography in the assessment of hepatic metastasis from colorectal carcinoma. World J Surg. 2006;30:1892-9
7. Soyer P, Bluemke DA, Hruban RH, Sitzmann JV, Fishman EK. Hepatic metastases from colorectal cancer: detection and false-positive findings with helical CT during arterial portography. Radiology 1994;193:71-4.
8. Rothbart J, Pijl ME, Vahrmeijer AL, Hartgrink HH, Tijl FG, Kuppe PJ, Tollenaar RA, Van de Velde CJ. Isolated hepatic perfusion with high-dose melphalan for the treatment of colorectal metastasis confined to the liver. Br J Surg. 2003;90:1391-7.
9. Lencioni R, Donati F, Cioni D, Paolicchi A, Cicorelli A, Bartolozzi C. Detection of colorectal liver metastases: prospective comparison of unenhanced magnetic resonance imaging at 1.5 T, dual phase spiral CT and spiral CT during arterial portography. MAGMA 1998;7:76-87.
10. Strotzer M, Gmeinwiese J, Schmidt J, et al. Diagnosis of liver metastases with intravenous contrast enhanced spiral-CT and SPIO enhanced MR combined with plain MR imaging. Acta Radiol 1997;38:986-992.
11. Soyer P, Lacheheb D, Levesque M. False-positive diagnosis based on CT portography: correlation with pathologic findings. AJR 1992; 160:285-9.
12. Frybeck DG, Thornbury JR. The efficacy of diagnostic imaging. Med Decis Making 1991;11:88-94
13. Soyer P, Levesque M, Elias D, Zeitoun G, Roche A. Preoperative assessment of Resectability of hepatic metastases from Colonic carcinoma: CT Portography vs Sonography and Dynamic CT. 1992;159:741-4.
14. Small WC, Mehard WB, Langmo LS, Dagher AP, Fishman EK, Heiken JP, Bernardino ME. Preoperative Determination of the Resectability of Hepatic Tumors. AJR 1993;161:319-322.
15. Dawson P, Lees WR. Multi-slice technology in computed tomography. Clin. Radiology 2001;56:302-9.

ACCEPTED MANUSCRIPT

Captions for **figures**:

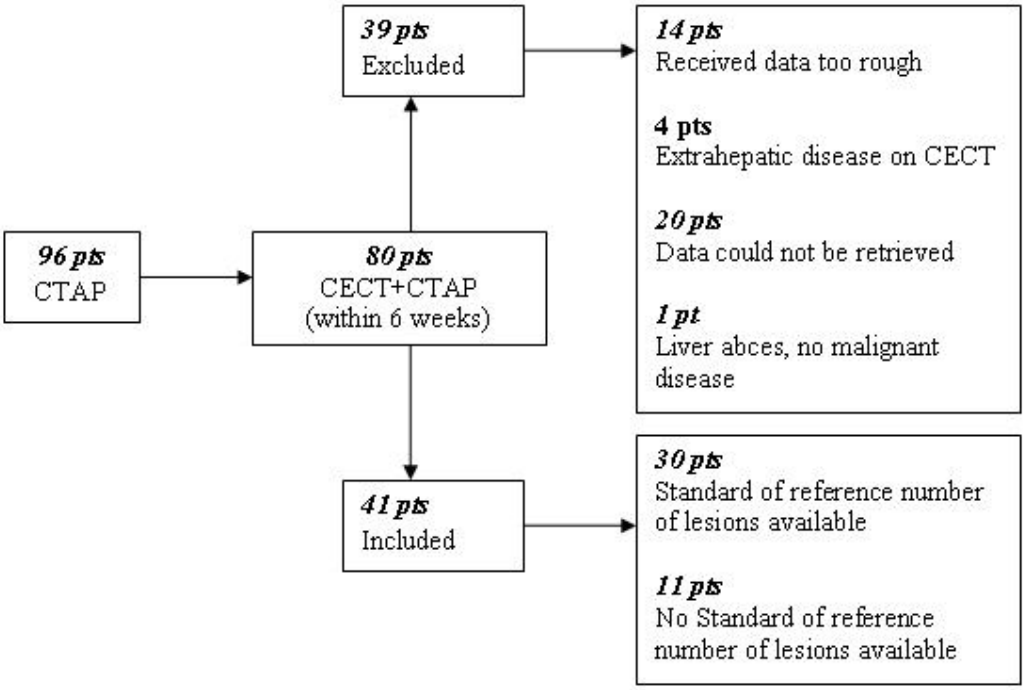

Fig1.tiff: Figure 1: Flow-chart number of patients included. Findings at surgery and pathology records were available in 30 of the 41 patients eventually included.

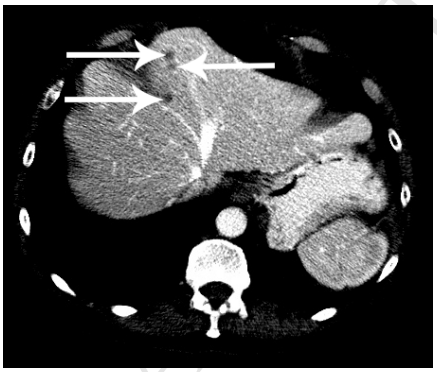

Fig2a.tiff: **a**

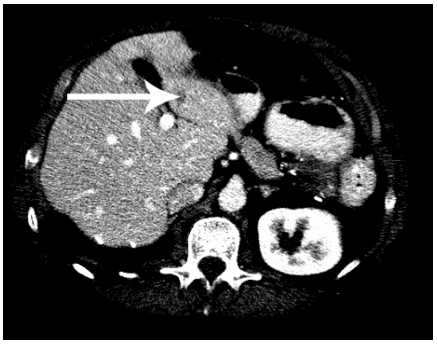

Fig2b.tiff: **b**

Fig2c.tiff: **c**

Fig2d.tiff: **d**

= Figure 2: Hepatic metastases in 57-year-old woman with history of metastasectomy segments II and VI and RFA segment VIII. In September 2005 six new liver metastases were detected on routine follow-up CE-CT. Arrows indicate three metastases in segment VIII (**a**) and one in segment IVb (**b**). Surgery and/or RFA was considered to be the feasible treatment (**a + b**). Two weeks later the CTAP investigation showed 12 metastases. Arrows indicate four metastases that were not previously detected with CE-CT in segments III (**c**), VII and VIII (**d**) and IHP was proposed. (* = Perfusion defect).

ACCEPTED MANUSCRIPT

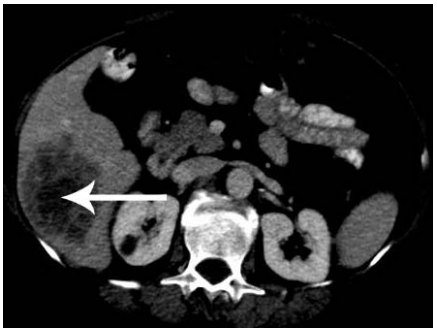

Fig3a.tiff: **a**

Fig3b.tiff: **b**

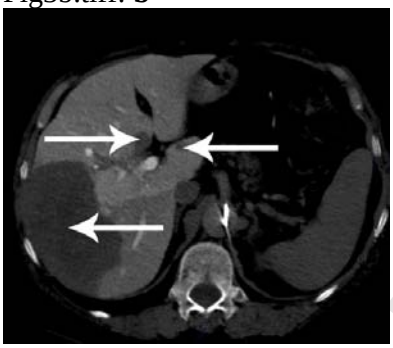

Fig3c.tiff: **c**

= Figure 3:
Hepatic metastases in a 67-year-old woman.. On a CE-CT in June 2000 new liver lesions were detected and within 14 days a CTAP was performed. Reviewing the CE-CT study 2 suspected metastases (arrows) were found in segments VI and VII (**a,b**). Resection and/or RFA was proposed. Reviewing the CTAP study 4 suspected lesions were detected. Arrows indicate a lesion in segment VI that appeared to be larger than with CE-CT and new lesions in segments IVa and I (**c**). Based on these findings chemotherapy was proposed.

ACCEPTED MANUSCRIPT

Tables

Table 1: Detection rate and fraction of false positive lesions

	Seen on CE-CT	Seen on CTAP	Standard of reference
Total number of lesions	66	93	74
Number of matching lesions	53	66	74
Number of false positive lesions	13	27	0
Detection rate	.72	.89	1.0
Fraction false positive lesions	.19	.29	0.0

detection and false positive findings on CE-CT, CTAP and standard of reference in 30 patients, whom findings at surgery and Pathology records were available.

ACCEPTED MANUSCRIPT