



HAL
open science

The Significance of Immunohistochemistry Positivity in Sentinel Nodes which are Negative on Haematoxylin and Eosin in Breast Cancer

S Mac Giobuin, Do Kavanagh, E Myers, Ao Doherty, Cm Quinn, T Crotty, D Evoy, E Mcdermott

► **To cite this version:**

S Mac Giobuin, Do Kavanagh, E Myers, Ao Doherty, Cm Quinn, et al.. The Significance of Immunohistochemistry Positivity in Sentinel Nodes which are Negative on Haematoxylin and Eosin in Breast Cancer. *EJSO - European Journal of Surgical Oncology*, 2009, 35 (12), pp.1257. 10.1016/j.ejso.2009.04.004 . hal-00556299

HAL Id: hal-00556299

<https://hal.science/hal-00556299>

Submitted on 16 Jan 2011


HAL is a multi-disciplinary open access archive for the deposit and dissemination of scientific research documents, whether they are published or not. The documents may come from teaching and research institutions in France or abroad, or from public or private research centers.

L'archive ouverte pluridisciplinaire **HAL**, est destinée au dépôt et à la diffusion de documents scientifiques de niveau recherche, publiés ou non, émanant des établissements d'enseignement et de recherche français ou étrangers, des laboratoires publics ou privés.

Accepted Manuscript

Title: The Significance of Immunohistochemistry Positivity in Sentinel Nodes which are Negative on Haematoxylin and Eosin in Breast Cancer

Authors: S Mac Giobuin, DO Kavanagh, E Myers, AO Doherty, CM Quinn, T Crotty, D Evoy, E McDermott



PII: S0748-7983(09)00118-8

DOI: [10.1016/j.ejso.2009.04.004](https://doi.org/10.1016/j.ejso.2009.04.004)

Reference: YEJSO 2821

To appear in: *European Journal of Surgical Oncology*

Received Date: 18 October 2008

Revised Date: 30 March 2009

Accepted Date: 1 April 2009

Please cite this article as: Mac Giobuin S, Kavanagh DO, Myers E, Doherty AO, Quinn CM, Crotty T, Evoy D, McDermott E. The Significance of Immunohistochemistry Positivity in Sentinel Nodes which are Negative on Haematoxylin and Eosin in Breast Cancer, *European Journal of Surgical Oncology* (2009), doi: 10.1016/j.ejso.2009.04.004

This is a PDF file of an unedited manuscript that has been accepted for publication. As a service to our customers we are providing this early version of the manuscript. The manuscript will undergo copyediting, typesetting, and review of the resulting proof before it is published in its final form. Please note that during the production process errors may be discovered which could affect the content, and all legal disclaimers that apply to the journal pertain.

Title: THE SIGNIFICANCE OF IMMUNOHISTOCHEMISTRY
POSITIVITY IN SENTINEL NODES WHICH ARE NEGATIVE ON
HAEMATOXYLIN AND EOSIN IN BREAST CANCER

Authors: S Mac Giobuin¹, DO Kavanagh¹, E Myers¹, A O Doherty², CM
Quinn³, T Crotty³, D Evoy¹, E McDermott¹

Institution: Departments of Breast & Endocrine Surgery¹, Radiology² and
Histopathology³, St Vincents University Hospital, Elm Park, Dublin 4

Corresponding author;

Dr Sean MacGiobuin,
Dept of Breast & Endocrine Surgery,
St Vincents University Hospital,
Elm Park,
Dublin 4.

Tel no: 00353 (1) 2094925

Fax no: 00353 (1) 2693479

e-mail: dara_kav@hotmail.com

Article type: Original article

ABSTRACT**Introduction**

Sentinel lymph node (SLN) biopsy allows a more detailed examination of a smaller number of lymph nodes in patients with clinically node negative breast cancer. Immunohistochemistry detects small tumour burden not routinely seen on haematoxylin and eosin (H & E). The significance of such findings remains to be fully elucidated.

Aim

To assess the axillary disease burden of patients in whom the sentinel lymph node biopsy was positive on immunohistochemistry and negative on H and E.

Methods

An analysis of patients who underwent SLN mapping for breast cancer at St Vincent's University Hospital from January 1st 2000 to December 31st 2006 was conducted. All SLNs were assessed by serial H & E and IHC sections.

Patients with micrometastases (0.2 – 2 mms) underwent a completion axillary lymph node dissections (CLND). Patients with ITC (<0.2 mms) were individually discussed and a CLND was performed selectively based on additional clinicopathological criteria and patient preference. Analysis of the additional nodes from CLND was performed. Patients were followed for a median of 27 months (Range 12 – 72 months).

Results

1076 patients who underwent SLN were included for analysis. 211 (20%) had a positive SLN biopsy using H & E. Forty nine patients (5%) had a negative SLN on H & E which was positive on IHC. Of these, 15 had micrometastases and underwent a CLND. Two had further axillary nodal disease. ITC were found in the remaining 34 patients. 16 of these patients underwent a CLND. Five of this group had further nodal disease.

Conclusion

Micrometastases and isolated tumour cells, detected only by immunohistochemical analysis of sentinel lymph nodes, are associated with further positive nodes in the axilla in up to 15% of patients. This upstaging of disease may impact upon patient outcome.

Keywords: sentinel node biopsy, breast cancer, immunohistochemistry, lymph node metastasis

Introduction

The axillary lymph node status is the most powerful predictor of longterm survival in patients with breast cancer [1]. It provides important information for determining adjuvant therapies. [2] Sentinel lymph node (SLN) biopsy allows accurate staging of the axilla with less morbidity than axillary clearance [3]. Acquisition of a single representative node allows disease upstaging as one can employ a variety of techniques to study these lymph nodes with more scrutiny. It has previously been demonstrated that re-analysis of historical CLND specimens with serial sectioning, immunohistochemistry (IHC) and polymerase chain reaction (PCR) can upstage disease by 30 % [4]. The use of immunohistochemistry and serial sectioning helps to reduce the false negative rate. However, the significance of upstaging remains to be elucidated with conflicting published data. Hansen et al did not demonstrate any difference in disease-free or overall between patients who had IHC-detected micrometastases and those who had no lymph node involvement [5]. Conversely, Wilkinson et al demonstrated occult disease detected by IHC as an independent predictor of disease recurrence [6]. It is unclear whether IHC positivity represents early metastases or is a result of displacement due to the diagnostic procedures [7]. There is evidence that in selected patients who have positive SLNs, the locoregional failure rate is low even in the absence of further axillary surgery (0.25%) [8].

The significance of IHC positive SLNs remains ill-defined. The aim of the current study was to determine the incidence of residual disease burden in the CLND of patients with SLN biopsies positive on IHC only and determine if IHC positivity predicted locoregional recurrence.

Methods

Patient selection

The medical records of patients who underwent SLN biopsy at St Vincent's University Hospital between January 1st 2000 and December 31st 2006 were reviewed. Patients who had no clinical, radiological or cytological evidence of axillary lymph node disease or distant metastases were deemed appropriate for SLN biopsy. In total, 1076 consecutive patient records were included in the study.

Sentinel Lymph Node Procedure.

Lymphatic mapping and SLN biopsies were performed using a combined injection technique of isosulphan blue dye and radioisotope as previously described [9]. On the morning of surgery, rhenium sulfur colloid was injected either into the parenchyma (intraparenchymal) of the tumor or into four separate areas in the periareolar region of the breast (intradermal). Lymphoscintigraphy was performed one hour following injection.

Five minutes prior to the incision, isosulfan blue dye was injected intraparenchymally and the area was massaged. SLNs were identified as lymph nodes with uptake of blue dye and/or radiotracer.

Pathological Analysis.

The nodes were submitted for pathological analysis and fixed in formalin for 24 hours. Institution guidelines regarding the handling of specimens containing radioisotope were followed. The sentinel node was bisected and sections were retrieved at three levels from each hemisection. Haematoxylin and eosin (H & E) staining was performed on the first and third section of each hemisection of the supplied SLN. Immunohistochemical staining for cytokeratin (CAM 5.2) was then performed on the central or second section of each hemisected SLN. All patients

whose SLN was positive on H & E underwent a CLND. All additional nodes were sectioned and stained using H & E. Patients whose SLN contained IHC positive cells with no corresponding malignant cells on H & E stained sections were classified on IHC as (i) isolated tumor cells (ITC) - <0.2 mms (ii) Micrometastases – 0.2 – 2 mms and (iii) Macrometastases - > 2 mm. These comprise the basis of the current study. All patients with micrometastases underwent CLND. Prior to the issuing of the AJCC 2006 guidelines patients with ITC identified underwent a CLND based on clinicopathological features of the primary and patient preferences. Currently, the unit policy for ITC is that one should not undergo a CLND.

Data Analysis

The medical records of the study group were analysed. Patients with a positive sentinel node were categorized as H&E positive and IHC positive only. IHC positive patients were further subdivided into those with micrometastasis and those with isolated tumor cells. Further axillary disease burden was assessed in patients who underwent CLND. The pathological features of the primary tumor and the impact of the axilla nodal status on adjuvant therapies was examined. Patients were followed for a median of 27 months (Range 12 – 72 months). Data was analysed using SPSS software where data was considered significant when $P < 0.05$.

Results

Figure 1

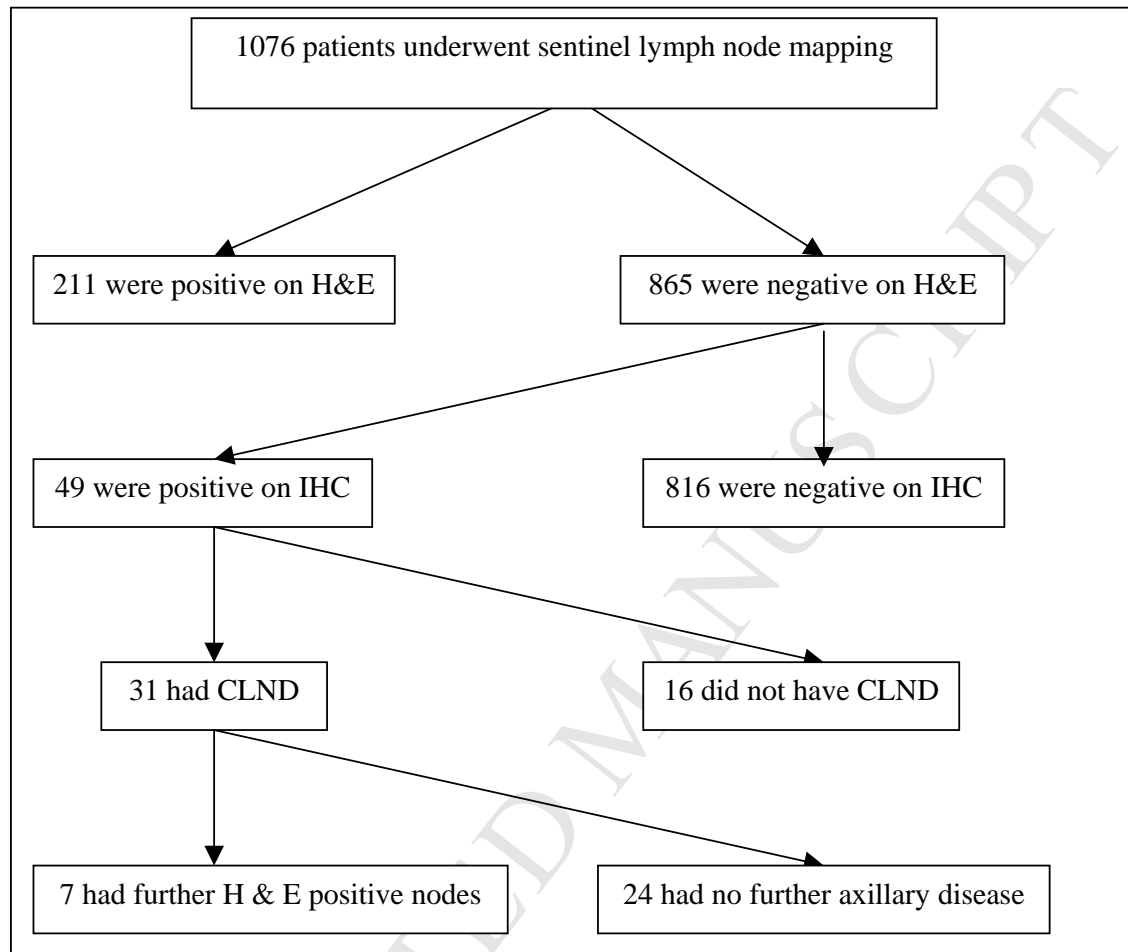


Figure 1. Results of sentinel node analysis in Breast Cancer patients operated on at St Vincent's University hospital (CLND = completion axillary lymph node dissection; H & E = haematoxylin and eosin; IHC = immunohistochemistry)

A total of 1076 patients underwent SLN biopsy for invasive carcinoma and select cases with DCIS on core biopsy (grade 3 ± comedo necrosis). In total, 211 (20%) patients had a positive node on H & E staining. An additional 49 (5%) cases had positive immunostaining only with no evidence of malignant cells on H & E. These were characterized according to international guidelines as (number): micrometastases (15) and isolated tumor cells (34). Thirty-one of these patients underwent CLND in a

non-randomised manner. All patients with micrometastases underwent CLND while 16 of the patients with ITCs had a CLND on an individualized policy until the AJCC 2006 guidelines were issued. These no longer recommend CLND. Seven of these 49 patients had axillary metastases in the CLND identified on routine histology. The clinicopathological features of these 49 tumors are illustrated in Table 1. There was no correlation between specific pathological parameters and tumor burden in the SLN ($p=0.8$). There was a single axillary recurrence in a patient with a positive SLN on H & E. There were no cancer-related deaths in the series of 49 patients.

Discussion

The introduction of more detailed analysis of the sentinel lymph node in breast cancer through serial sectioning and use of immunohistochemistry has identified previously undetected tumor cells in 4-29% of patients in the published series. The current study reveals occult metastases in 5% of cases. This in turn leads to a reduction in the false negative rate of the technique [10]. This upstaging of disease may confer a worse prognosis. In the earlier years of the current study patients with ITCs were treated with adjuvant therapies and/or CLND based on clinicopathological features of the primary. The current AJCC guidelines classify patients with ITCs as lymph-node negative. Five of the 16 patients who underwent CLND prior to the alteration of unit policy had axillary nodal metastases in the CLND. This subgroup would have been offered chemotherapy based on the features of the primary in the absence of CLND [11]. The National Institute of Health consensus guidelines recommended that patients with a tumor measuring > 1 cm should be offered chemotherapy. The mean tumor size in the patients cohort (n=49) was 1.8 cms. Apart from offering patients CLND or observation in the setting of sentinel lymph node positivity current evidence supports a role for adjuvant axillary radiotherapy [12].

Chagpar et al identified micrometastases in 18% (15 cases) of patients who underwent SLN biopsy at the MD Anderson Cancer Center. At a median follow-up of 40.2 months the presence of IHC-positivity in the SLN did not significantly affect outcome [13]. Similarly, Hansen et al evaluated the experience at the John Wayne Cancer Centre [5]. They found a significant survival difference between patients with macrometastases (on H&E) and those with micrometastases in the SLN. They could not identify any difference in disease-free or overall survival between patients who had micrometastases on IHC analysis and those with no lymph node involvement.

It is worth noting that if the CLND nodes were subjected to the same rigorous analysis that the SLN undergoes a further upstaging is inevitable. Tan et al identified an upstaging in 23% of patients to node positive [14]. This degree of analysis is practically untenable but is it necessary? Tan et al demonstrated that this correlated with disease-free and overall survival using multivariate analysis. The likelihood of local recurrence in the axilla is unclear but in 5 of 34 patients in the current study who were designated 'node-negative' based on the AJCC guidelines a CLND identified axillary metastases. The additional disease was evident in the CLND on H&E. Eighteen of these 34 patients did not undergo a CLND. These patients all received chemotherapy based on the size of the primary but perhaps they would have received a more aggressive regimen if they were known to have axillary disease. Furthermore, they may have received axillary radiotherapy.

The data presented demonstrates that patients with IHC positive sentinel nodes contained additional axillary disease in their CLND. While the debate continues as to the impact of micrometastasis on survival it is clear that patients who have residual axillary disease are likely to develop local and systemic recurrence. Clearly, further data is needed on the relevance of micrometastasis. In the interim, we must treat each case individually in the setting of a multidisciplinary forum.

Conclusion

Immunohistochemical analysis of the SLN theoretically reduces the false negative rate of the technique. In our experience 14% of patients were upstaged to N₁ based on a CLND. These consisted predominantly of patients with ITCs. Pending the results of ongoing trials our treatment of immunohistochemical positivity remains a matter of clinical judgement balancing proven evidence, uncertain evidence and patient preferences.

Conflict of interest

The authors state that they have no conflict of interest.

References

1. Donegan WL. Tumor-related prognostic factors for breast cancer. *Ca Cancer Clin J.* 1997;47:28-51
2. Lin PP, Alison DC, Wainstock J et al. Impact of axillary lymph node dissection on the therapy of breast cancer patients. *J Clin Oncol.* 1993;11:1536-44
3. Giuliano AE. Sentinel lymphadenectomy in primary breast carcinoma: an alternative to routine axillary dissection. *J Surg Oncol.* 1996; 62:75-6
4. Turner RR, Giuliano AE, Hoon DS et al. Pathological examination of sentinel lymph node for breast carcinoma. *World J Surg* 2001;25:798-805
5. Hansen NW, Grube BJ, TE W et al. Clinical significance of axillary metastases in breast cancer: how small is too small? *Proc Am Soc Clin Oncol.* 2001;20:91a
6. Wilkinson EJ, Hause LL, Hoffman RG et al. Occult axillary lymph node metastases in invasive breast carcinoma: characteristics of the primary tumor and significance of metastases. *Pathol Ann.* 1982; 17:67-91
7. Moore KH, Thaler HT, Tan LK, Borgen PI, Cody HS III. Immunohistochemically detected tumour cells in the sentinel nodes of patients with breast carcinoma. Biologic metastasis or procedural artefact? *Cancer* 2004; 100(5): 929-935
8. Van der Ploeg IM, Kroon BB, Antonini N, Valdés Olmos RA, Rutgers EJ, Nieweg OE. Axillary and extra-axillary lymph node recurrences after a tumor-negative sentinel node biopsy for breast cancer using intralesional tracer administration. *Ann Surg Oncol.* 2008;15(4):1025-31

9. Dowling CM, Hill AD. Sentinel lymph node biopsy in breast cancer. *The Surgeon*. 2004;2(5):273-6
10. Jakub JW, DIAZ nm, Ebert MD, cantor A, Reintgen DS, Dupont EL, Shons AR, Cox CE. Completion axillary lymph node dissection minimises the likelihood of false negatives for patients with invasive breast carcinoma and cytokeratin positive only sentinel lymph nodes. *Am J Surg* 2002; 184: 302-306
11. Eifel A, Axelson JA, Costa JA. National institute of health consensus development conference statement: adjuvant therapy for breast cancer. *J Natl Canc Instit* 2001;93:979-989
12. Gadd M, harris J, taghian A et al. Prospective study of axillary radiation without axillary dissection for breast cancer patients with a positive sentinel lymph node. Presented at the Annual San Antonio Breast Cancer Symposium, San Antonio, Texas, December 8-11, 2005, Abstract 22
13. Hwang RF, Gonzalez-Angulo AM, Yi M, Buchholz TA, Meric-Bernstam F, Kuerer HM. Low locoregional failure rates in selected breast cancer patients with tumor positive sentinel lymph nodes who do not undergo completion axillary dissection. *Cancer* 2007; 110(4):725-31
14. Tan LK, Giri D, Hummer AJ, Panageas KS, Brogi E, Norton L, Hudis C, Borgen PI, Cody HS 3rd. Occult axillary node metastases in breast cancer are prognostically significant: results in 368 node-negative patients with 20-year follow-up. *J Clin Oncol*. 2008 ;26(11):1803-9.

Table 1 Subdivision of those with IHC positivity and correlation with pathological parameters

	Micromets*	ITCs (+CLND)	ITCs (-CLND)
Number of patients (n)	15	16	18
Mean tumor size (mm)	19	32	18
Grade of primary			
1	3	2	2
2	9	8	13
3	3	6	3
LVI (% positive)	47	56	33
Sentinel nodes (n)	3.4	3.1	3.2
Positive non-sentinel nodes (n)	2	5	-

*All patients with Micromets had a CLND

+ CLND underwent a completion axillary dissection