



HAL
open science

Surgical management of liver metastases from uveal melanoma:16 years'experience at the Institut Curie

P. Mariani, S. Piperno-Neumann, V. Servois, M.G. Berry, T. Dorval, C. Plancher, J. Couturier, C. Levy-Gabriel, L. Lumbroso-Le Rouic, L. Desjardins, et al.

► **To cite this version:**

P. Mariani, S. Piperno-Neumann, V. Servois, M.G. Berry, T. Dorval, et al.. Surgical management of liver metastases from uveal melanoma:16 years'experience at the Institut Curie. *EJSO - European Journal of Surgical Oncology*, 2009, 35 (11), pp.1192. <10.1016/j.ejso.2009.02.016>. <hal-00556287>

HAL Id: hal-00556287

<https://hal.science/hal-00556287v1>

Submitted on 16 Jan 2011

HAL is a multi-disciplinary open access archive for the deposit and dissemination of scientific research documents, whether they are published or not. The documents may come from teaching and research institutions in France or abroad, or from public or private research centers.

L'archive ouverte pluridisciplinaire **HAL**, est destinée au dépôt et à la diffusion de documents scientifiques de niveau recherche, publiés ou non, émanant des établissements d'enseignement et de recherche français ou étrangers, des laboratoires publics ou privés.




HAL Authorization

Accepted Manuscript

Title: Surgical management of liver metastases from uveal melanoma: 16 years' experience at the Institut Curie

Authors: P. Mariani, S. Piperno-Neumann, V. Servois, M.G. Berry, T. Dorval, C. Plancher, J. Couturier, C. Levy-Gabriel, L. Lumbroso-Le Rouic, L. Desjardins, R.J. Salmon



PII: S0748-7983(09)00078-X

DOI: [10.1016/j.ejsso.2009.02.016](https://doi.org/10.1016/j.ejsso.2009.02.016)

Reference: YEJSO 2808

To appear in: *European Journal of Surgical Oncology*

Received Date: 4 June 2008

Revised Date: 24 February 2009

Accepted Date: 26 February 2009

Please cite this article as: Mariani P., Piperno-Neumann S., Servois V., Berry M.G., Dorval T., Plancher C., Couturier J., Levy-Gabriel C., Lumbroso-Le Rouic L., Desjardins L., Salmon R.J. Surgical management of liver metastases from uveal melanoma: 16 years' experience at the Institut Curie., *European Journal of Surgical Oncology* (2009), doi: [10.1016/j.ejsso.2009.02.016](https://doi.org/10.1016/j.ejsso.2009.02.016)

This is a PDF file of an unedited manuscript that has been accepted for publication. As a service to our customers we are providing this early version of the manuscript. The manuscript will undergo copyediting, typesetting, and review of the resulting proof before it is published in its final form. Please note that during the production process errors may be discovered which could affect the content, and all legal disclaimers that apply to the journal pertain.

**SURGICAL MANAGEMENT OF LIVER METASTASES FROM
UVEAL MELANOMA: 16 YEARS' EXPERIENCE AT THE
INSTITUT CURIE**

P. Mariani ^{a*}, S. Piperno-Neumann ^b, V. Servois ^c, M.G. Berry ^a, T. Dorval ^b, C. Plancher ^d, J. Couturier ^e, C. Levy-Gabriel ^a, L. Lumbroso-Le Rouic ^a, L. Desjardins ^a, R.J.Salmon ^a

^a Departments of Surgery, Institut Curie, 26 rue d'Ulm, 75248 Paris Cedex 05, France

^b Department of Medical Oncology, Institut Curie, Paris, France

^c Department of Radiology, Institut Curie, Paris, France

^d Department of Statistics, Institut Curie, Paris, France

^e Department of Genetics, Institut Curie, Paris, France

*Corresponding author and reprints: P. Mariani

Tel : +1 44 32 46 45

Fax : +1 53 10 40 37

e-mail: pascale.mariani@curie.net

ABSTRACT

Background: uveal melanoma is characterised by a high prevalence of liver metastases and a poor prognosis.

Aim: to review the evolving surgical management of this challenging condition at a single institution over a 16 year period.

Patients and Methods: between January 1991 and June 2007, among 3873 patients with uveal melanoma, 798 patients had liver metastases. We undertook a detailed retrospective review of their clinical records and surgical procedures. The data was evaluated with both uni- and multi-variate statistical analysis for predictive survival indicators.

Results: 255 patients underwent surgical resection. The median interval between ocular tumour diagnosis and liver surgery was 68 months (range 19-81). Liver surgery was either microscopically complete (R0; n = 76), microscopically incomplete (R1; n = 22) or macroscopically incomplete (R2; n = 157). The median overall post-operative survival was 14 months, but increased to 27 months when R0 resection was possible.

With multivariate analysis, four variables were found to independently correlate with prolonged survival: an interval from primary tumour diagnosis to liver metastases > 24 months, comprehensiveness of surgical resection (R0), number of metastases resected (≤ 4) and absence of miliary disease.

Conclusions: surgical resection, when possible, is able to almost double the survival and appears at present the optimal way of improving the prognosis in metastatic uveal melanoma. Advances in medical treatments will be required to further improve survival.

Key words: uveal melanoma; liver metastases; surgery; prognosis

INTRODUCTION

Uveal melanoma is the most common primary ocular malignancy in the adult caucasian population and once metastases occurs the liver is the sole organ involved in 60 – 80 % of cases.¹⁻³ When liver metastases develop, the prognosis is poor and life expectancy reduces to less than 6 months in the absence of treatment.⁴ No adjuvant therapy has proven efficacy for the prevention of metastases following ocular treatment and only minimal improvements in disease-free survival have been observed with intra-arterial chemotherapy.⁵

The best survival rates with established liver metastases have been obtained with maximal tumour reduction, where technically possible.^{6,7} Disseminated, or ‘miliary’, metastases are a very poor prognostic factor, frequently diagnosed only at the time of operation as current imaging methods (abdominal ultrasonography, computed tomography) are insufficiently sensitive to reliably exclude their presence pre-operatively.

The aim of this study was a long-term (16-years) review of the surgical management of liver metastases from uveal melanoma in a single institution with regard to survival and the determination of predictive factors for the optimal surgical candidate.

ACCEPTED MANUSCRIPT

PATIENTS AND METHODS

Patient selection

After primary ocular treatment, surveillance combined clinical ophthalmologic examination and abdominal ultrasonography (US) every 6 months. If metastases were suspected, hepatic computed tomography (CT) and/or magnetic resonance imaging (MRI) scanning was performed to both confirm the diagnosis and evaluate the feasibility of resection. The presence of lung metastases was evaluated pre-operatively initially by chest X-ray and more recently by CT. Pre-operative liver biopsy was performed, where technically possible, for histopathological confirmation of metastatic disease, however, we worked on the assumption that any hepatic nodule not present at initial evaluation and appearing during follow up was metastatic until proven otherwise. All patients with documented liver metastases were reviewed by the multidisciplinary team to assess the indication and suitability for surgical resection. When screening demonstrated disseminated metastatic disease, contraindicating liver resection or precluding safe surgery, patients received either intravenous chemotherapy or best supportive care only. Patients medically unsuitable for hepatic surgery were excluded from this study.

Initially all patients underwent surgical exploration, with the intent of resection, and/or insertion of an intra-arterial catheter for post-operative chemotherapy. As our experience increased, surgery was only performed if complete resection was likely following pre-operative evaluation to reduce unnecessary morbidity. More recently, the initiation of a randomised trial, comparing intravenous with intra-arterial chemotherapy in patients with unresectable metastases limited to the liver, further reduced our indications for surgical exploration.

Population

Between January 1991 and June 2007, 3873 patients with uveal melanoma were treated at our institution. Of these, 798 developed liver metastases and 255 underwent hepatic surgery.

Method of treatment

The 543 non-surgical patients were treated with either chemotherapy (dacarbazine or fotemustine), were included in phase I or II clinical trials or received optimal supportive care only.

For the 255 that underwent surgical intervention, the standard criteria for hepatic surgery were respected (age, performance status [WHO criteria], preservation of 30 – 40 % normal parenchyma following complete metastasectomy). The surgical objective was microscopically complete resection using either single or multiple resections. Surgery included intraoperative liver ultrasonography and frozen-section examination when pre-operative biopsy had not been obtained. The presence of ‘miliary’ metastases (multiple, diffuse, millimetre-sized, dark punctuate lesions) at laparotomy contraindicated major liver resection. Liver resections were classified ‘R0’ (microscopically complete), ‘R1’ (microscopically incomplete) or ‘R2’ (macroscopically incomplete). In R2 resections cannulation of the proper hepatic artery, via the gastro-duodenal artery with ligation of any additional left and/or right hepatic branches, for post-operative chemotherapy was mandated in every patient during the first years of our experience, but since 2005 has been reserved for randomised patients in the intra-arterial arm of the European trial. The injection port was routinely implanted at the left costal margin to avoid interference with subsequent imaging. The quality of hepatic perfusion was verified by operative fluorescein injection and controlled post-operatively by port-catheter arteriography. Chemotherapy consisted of intra-arterial infusions of dacarbazine and more recently of Fotemustine commenced within a month of surgery. With secondary catheter dysfunction, peripheral intravenous chemotherapy was substituted. Those with no intra-arterial catheter placement received intravenous dacarbazine or fotemustine. Six-monthly post-operative follow-up included clinical examination, laboratory investigations and hepatic CT.

Recording and statistics

Medical records were reviewed to determine significant factors for survival following the diagnosis of liver metastases and the following information was collected: gender, age at diagnosis of metastases, intra-ocular tumour location, thickness and diameter, primary management, interval between primary tumour treatment and diagnosis of metastases, management and number of liver metastases, morbidity and mortality related to treatment, and overall survival.

Patient survival was calculated from the date of surgery to the date of last follow-up or death. Survival and time-to-event rates, with standard error, were calculated with Kaplan-Meier analysis and compared with the log-rank test. Statistical tests with a p value <0.05 were considered statistically significant.

A multivariate Cox proportional hazards analysis was built using those variables that suggested a significant prognosis value by univariate analysis. Variables included in the multi-variate model were those with an univariate significance of $\leq 20\%$: these were age at diagnosis (< 60 years, ≥ 60 years), time to liver metastases (≤ 24 months, > 24 months), comprehensiveness of liver resection (R0, R1,R2), number of liver metastases resected (≤ 4 lesions, > 4 lesions), miliary disease (no, yes) and topography of liver metastases (unilobar, multilobar).

ACCEPTED MANUSCRIPT

RESULTS

During the study period 255 patients underwent hepatic surgery with a mean age of 56 years (range 19 – 81) and 133 were male. The median time between primary tumour diagnosis and hepatic surgery was 68 months (1-96). Only 13 patients had synchronous liver metastases.

Primary uveal tumour characteristics

Mean tumour thickness was 7.45 mm (2.1 – 1.7) and mean tumour diameter was 15.7 mm (8 – 35). Primary management of the uveal tumour included enucleation in 57 patients and non-surgical treatment in 198 patients, including proton beam therapy in 110.

Liver metastases and surgery

Prior to surgery, all 255 patients had abdominal US, 177 hepatic CT and 73 liver MRI. During surgery, liver metastases were found to be solitary (n = 25), 2-4 (n = 51) and >4 (n = 179). Among the 255 liver resections, there were 77 major liver resections (≥ 3 segments), 128 unisegmentectomies or metastasectomies and 50 liver biopsies. We performed 8 local radio frequency ablations (RFA) during laparotomy to attain R0 resection.

Liver surgical resection was R0 in 76, R1 in 22 and R2 in 157.

154 patients underwent intra-arterial catheter placement in R2 resection.

The presence of > 4 macroscopic lesions during surgery was a strong predictor of miliary disease (p = 0.001) (Table 1).

The pre-operative classification of patients (macroscopic lesions ≤ 4 versus > 4) by imaging was found, by comparison to operative findings, to have a sensitivity of 60%, a specificity of 90.6%, a negative predictive value of 50.75% and a positive predictive value of 93.4%.

The 30-day mortality rate was 3%: death being caused by acute hepatic insufficiency (5 patients), haemorrhagic complications (2 patients), subphrenic collection (1 patient). The overall morbidity was 16.4 % of which there were 10 infections, 8 haemorrhagic and 4 thrombo-embolic complications.

Survival after surgical treatment of liver metastases

The median overall survival following hepatic surgery was 14 months as compared to 8 months in those who had no surgery. The survival rate was 56.7% (± 3.1 SD) at 1 year, and 7.0% (± 2.0) at 5 years.

The median overall survival was 27 months after R0 resection, 17 months after R1 resection and 11 months after R2 resection (Figure 1).

Four patients with a slowly progressive disease and limited number of metastases underwent secondary resection and two had a third resection.

Univariate survival analysis

Gender, age, tumour thickness and diameter, intra-ocular location of the primary melanoma and initial treatment were not predictive of outcome (Table 2).

A disease-free interval between primary tumour and liver metastases of more than 24 months was a significant prognostic factor of survival at 2 years ($p < 0.0001$).

Patient outcome was strongly correlated to the quality of liver resection: 2-year overall survival being 54.4 % after R0 resection, 30.7 % after R1 and 14.4 % after R2 ($p < 0.0001$).

The number of liver metastases (≤ 4), their hepatic topography and the presence of miliary disease were all correlated with prolonged overall survival ($p < 0.0001$).

Multivariate survival analysis

We identified four variables (Table 3) that correlated independently with prolonged survival: time to liver metastases (> 24 months), comprehensiveness of liver resection (R0), number of liver metastases resected (≤ 4 lesions,) and absence of miliary disease. Although significant by univariate analysis, the topography of liver metastases was not significant by multivariate analysis.

DISCUSSION

At our institution we developed an aggressive surgical approach to hepatic metastases of uveal melanoma. Initially, we undertook surgical exploration in all patients, but laparoscopic evaluation was not available and, due to the dissemination of the disease in the majority of patients, survival was almost uniformly poor. With increasing experience and improvements in hepatic imaging, we felt that the selection of patients for liver resection could be optimised by the prognostic features outlined below. It also became clear that significant survival information could be provided by the following factors: i) time to development of liver metastases, ii) comprehensiveness of hepatic resection, iii) number of metastases resected, and iv) the presence of miliary disease. These factors now influence our surgical management in selecting patients most likely to benefit and avoiding surgical morbidity in the patients with little or nothing to gain from surgery.

Survival rate without liver resection

This retrospective study confirms the significant prognostic implications of liver metastases from uveal melanoma. Of our initial cohort of 3873 patients only 798 (20%), were known to have metastases, which compares with a previous rate of 10% by Rivoire.⁷ With optimal supportive care, assessed in our previous study, the median overall survival for metastatic patients was 4 months and chemotherapy, in the absence of curative surgical resection, improved survival to 8 months.⁶ A somewhat improved overall survival of 14 months was suggested by Leyvraz ten years ago⁸ and confirmed in a retrospective study in 2006 (15 months) in 101 patients after intra-arterial chemotherapy with Fotemustine without surgical resection.⁵

Survival rate after liver resection

Hepatic resection should be considered for liver metastases of uveal melanoma because the liver is the first metastatic site and single organ involved in 60 – 80 % of cases.¹⁻³ In our series overall survival increased with surgery, irrespective of adequacy of resection, to 14 months. Having confirmed the positive benefits of surgery, deeper analysis elucidated further prognostic indicators including the comprehensiveness of resection, number of resected metastases, topography of lesions (uni- or multi-lobular), time to development of metastases and the absence of miliary lesions. All variables, except unilobular lesion distribution, statistically significant in univariate analysis, were confirmed in multivariate analysis.

Our results clearly demonstrate the benefit of complete tumour removal with 2-year survival being 54.4% after R0 resection, 30.7% after R1 resection and 14.4% after R2 resection. These figures compare with those of much smaller series: Aoyama⁹ reported R0 resection in 9 patients (7 with liver metastases only and 2 with liver metastases and other sites). After R0 resection, the median recurrence-free and overall survival was 19 months and 27 months respectively. In a series of 24 patients Hsueh¹⁰ showed that the surgical cohort had a significant longer median survival (38 months) than the non surgical cohort (9 months). Of these only 5, however, underwent liver resection, the remainder having other, non-defined metastasectomies. The R0 resection rate in our series, 76 of 255 (approximately 30%), was a little lower than Rivoire's 50% (14 of 28) with similar semi-annual abdominal US screening. The quality of surgery (R0 vs. R2) was the strongest indicator of improved outcome with 28 months median survival for R0, being higher than the 25 months published previously.⁷

R0 resections limited by miliary disease

As would be expected, with the number of metastases corresponding to disease 'load', fewer correlated with improved survival. Specifically, less than 4 metastases was strongly significant ($p < 0.0001$) as was the absence of miliary disease ($p < 0.001$). Similarly, a unilobular was much better than a multi-lobular distribution. Others, with much smaller series, have shown the significance cut-off to be 10 metastases or less.⁷ One very important finding in our series was that more than 4 metastases were strongly predictive for miliary disease in 82 % of cases.). Because miliary disease renders R0 resection impossible, this finding has changed our practice and we now perform diagnostic laparoscopy whenever more than 4 metastases are demonstrated or suspected on pre-operative imaging. In this way, those with miliary disease can be spared an unnecessary, and futile, laparotomy. The disease-free interval between primary uveal melanoma and diagnosis of metastases was a positive prognostic factor if greater than 24 months on univariate and multivariate analysis.

Early Detection of patients at high risk of hepatic metastases

We appreciate the potential critique of this study involving an evolutionary plan of management as guided by our previous experience, but are confident that such will be offset by the valuable prognostic information and strength of statistical analysis. With respect to screening, liver function tests have been suggested to improve early diagnosis of liver metastases.^{11, 12} Rietschel, however, noted that blood test were extremely inefficient for the

detection of asymptomatic metastases.³ Only one patient in Rivoire's study had liver function disruption with small metastases and, in our experience, liver function modification occurred only with massive, and therefore late, involvement.⁷

Naturally, it would be far better to be able to predict those patients who are likely to go on and develop liver metastases before they actually occur, but none of the following approached any degree of statistical significance: gender, ocular location of primary tumour, thickness or diameter of primary and the presence or absence of retinal detachment. It appears to be of importance to detect liver metastases as early as possible. At the Institut Curie, we have implemented a programme of intensive radiological follow-up with liver MRI, since 2004, for patients with known poor prognostic indicators (primary tumour size and thickness) and, for enucleated patients, those whose tumour has a monosomy 3 detected by FISH (fluorescent in situ hybridisation)¹³, a strong predictor of metastatic disease.^{14,15} We opted for MRI imaging because, apart from the specific characteristic of hyperintensity on T1-weighting due to melanin, optimal contrast between the liver and the metastases appeared to allow an improved sensitivity of detection of small lesions.

As to future developments, intra-arterial chemotherapy works on the premise of a greatly increased concentration at the metastatic site along with reduced side effects. The almost exclusive development of liver metastases is a further indication for this route. A randomised trial, coordinated by the EORTC (18021), is presently open to inclusion for the comparison of intra-arterial versus intra-venous delivery for fotemustine. With incompletely resectable disease, we actually prefer to randomise our patients in this trial. Vaccinotherapy with antigenic-specific peptides in non-operable and/or recurrent tumours has been proposed in HLA A2 patients, which represents about 50% of the caucasian population. Early results, however, have not been encouraging with neither tumour response nor improvements in survival having been shown in an ongoing study [data not shown]. Thus surgical resection remains the best option available to us at present and, as in any malignant disease, with optimal screening to determine operable disease. One matter of continued concern, as demonstrated by Figure 2, remains the lack of adequate pre-operative diagnosis of miliary disease. We had expected to see an increase in R0 resection, but have seen the reverse of late. Clearly pre-operative identification remains inadequately sensitive in a large number of cases and we are hopeful that DLS used routinely in cases with > 4 metastases will allow us to increase the rate of R0 resection.

Conclusion

Our results strongly support the notion that hepatic resection for liver metastases from uveal melanoma offers a greatly improved long term survival in carefully selected patients.

Important survival indicators include the time to metastases, the number and comprehensiveness of resected metastases, and the presence or absence of miliary disease.

Conflict of interest

The authors state that they have no conflict of interest.

Acknowledgements

We are grateful to Professor J. Belghiti for his scientific advice.

ACCEPTED MANUSCRIPT

REFERENCES

1. Rajpal S, Moore R, Karakousis CP. Survival in metastatic ocular melanoma. *Cancer* 1983; 52: 334-6.
2. Seregard S, Kock E. Prognostic indicators following enucleation for posterior uveal melanoma. A multivariate analysis of long-term survival with minimized loss to follow-up. *Acta Ophthalmol Scand* 1995; 73: 340-4.
3. Rietschel P, Panageas KS, Hanlon C, Patel A, Abramson DH, Chapman PB. Variates of survival in metastatic uveal melanoma. *J Clin Oncol* 2005; 23: 8076-80.
4. Gradoudas ES, Egan KM, Seddon JM, Glynn RJ, Walsh SM, Fin SM et al. Survival of patients with metastases from uveal melanoma. *Ophthalmology* 1991; 98: 383-90.
5. Peters S, Voelter V, Zografos L, Pampallona S, Popescu R, Gillet M et al. Intra-arterial hepatic fotemustine for the treatment of liver metastases from uveal melanoma: experience in 101 patients. *Ann Oncol* 2006; 17: 578-83.
6. Salmon RJ, Levy C, Plancher C, Dorval T, Desjardins L, Leyvraz S et al. Treatment of liver metastases from uveal melanoma by combined surgery-chemotherapy. *Eur J Surg Oncol* 1998; 24:127-30.
7. Rivoire M, Kodjikian L, Baldo S, Kaemmerlen P, Négrier S, Grange JD. Treatment of liver metastases from uveal melanoma. *Ann Surg Oncol* 2005; 12: 422-8.
8. Leyvraz S, Sparato V, Bauer J, Pampallona S, Salmon RJ, Dorval T et al. Treatment of ocular melanoma metastatic to the liver by hepatic arterial chemotherapy. *J Clin Oncol* 1997;15: 2589-95.
9. Aoyama T, Mastrangelo MJ, Berd D, Nathan FE, Shields CL, Shields JA et al. Protracted survival after resection of metastatic uveal melanoma. *Cancer* 2000; 89: 1561-8.

10. Hsueh EC, Essner R, Foshag LJ, Ye X, Wang He-Jing, Morton DL. Prolonged survival after complete resection of metastases from intra-ocular melanoma. *Cancer* 2004; 100: 122-9.
11. Diener-West M, Reynolds SM, Agugliaro DJ, Caldwell R, Cumming K, Earle JD et al. Screening for metastases from choroidal melanoma : the collaborative ocular melanoma study group report 23. *J clin Oncol* 2004;22:2438-44.
12. Sato T, Babazono A, Shields JA, Shields CL, De Potter P, Mastrangelo MJ. Time to systemic metastases in patients with posterior uveal melanoma. *Cancer Invest* 1997; 15: 98-105.
13. Desjardins L, Levy-Gabriel C, Lumbroso-Lerouic L, Sastre X, Dendale R, Couturier J et al. Prognostic factors for malignant uveal melanoma. Retrospective study on 2241 patients and recent contribution of monosomy -3 research. *J Fr Ophtalmol* 2006; 29: 741-9.
14. Prescher G, Bornfeld N, Hirche H, Horsthemke B, Jöckel KH, Becher R. Prognostic implications of monosomy 3 in uveal melanoma. *Lancet* 1996; 347:1222-5.
15. Onken MD, Worley LA, Ehlers JP, Harbour JW. Gene expression profiling in uveal melanoma reveals two molecular classes and predicts metastatic death. *Cancer Res* 2004; 64: 7205-9.

	no miliary	miliary
≤ 4 lesions	59 (37%)	17 (18 %)
≥ 4 lesions	100 (63 %)	77 (82 %)
* missing data = 2	159 (100%)	94 (100%)

p = 0.001

Table 1: Presence or absence of miliary disease and number of macroscopic metastases

ACCEPTED MANUSCRIPT

Table 2 Predictors of overall survival after liver surgery (univariate analysis)

Prognostic factors	No. Of patients	2-y survival (%)	P value
	255		
Gender			
Male	133	27.3 ± 04.0	0.56
Female	122	27.5 ± 04.2	
Age at diagnosis of metastases (year)			
< 60	140	32.8 ± 04.2	0.17
≥ 60	115	20.5 ± 04.0	
Primary tumor location			
Anterior to equator	16	27.0 ± 11.5	
On equator	140	24.6 ± 03.9	0.34
Posterior to equator	71	31.1 ± 05.8	
NA*	28		
Primary tumor thickness (mm)			
≤ 7.5	122	31.1 ± 04.7	0.20
> 7.5	107	22.6 ± 04.2	
NA*	26		
Retinal Detachment			
No	114	28.4 ± 04.5	0.59
Yes	100	25.7 ± 04.7	
NA*	41		
Primary tumor diameter (mm)			
≤ 15	102	22.9 ± 04.3	0.64
> 15	113	29.9 ± 04.6	
NA*	40		
Primary tumor treatment			
No enucleation	198	27.1 ± 03.4	0.45
Enucleation	57	28.0 ± 06.0	
Time to liver metastases (months)			
≤ 24	104	11.0 ± 03.2	<0.0001
> 24	151	39.0 ± 04.2	
Quality of liver resection			
R0	76	54.4 ± 06.2	
R1	22	30.7 ± 10.0	<0.0001
R2	157	14.4 ± 02.9	
Number of resected liver metastases			
≤ 4 lesions	76	54.3 ± 06.1	<0.0001
> 4 lesions	179	16.5 ± 02.9	
Topography of liver metastases			
Unilobar	64	54.4 ± 06.7	<0.0001
Multilobar	191	18.4 ± 03.0	
Miliary disease			
No	159	36.9 ± 04.0	<0.0001
Yes	94	09.4 ± 03.3	
NA*	2		
Type of resection and complementary treatment			
R0 + follow-up	86	53.2 ± 06.0	
R1-R2 + postoperative treatment.	149	17.5 ± 03.2	<0.0001
R2 + Best supportive care	20	05.0 ± 04.8	

* Non applicable

univariate analysis : Kaplan-Meier method with log-rank test

Table 3 Multivariable Cox proportional hazards analysis for overall survival to adjust the risk associated with therapy for various factor*

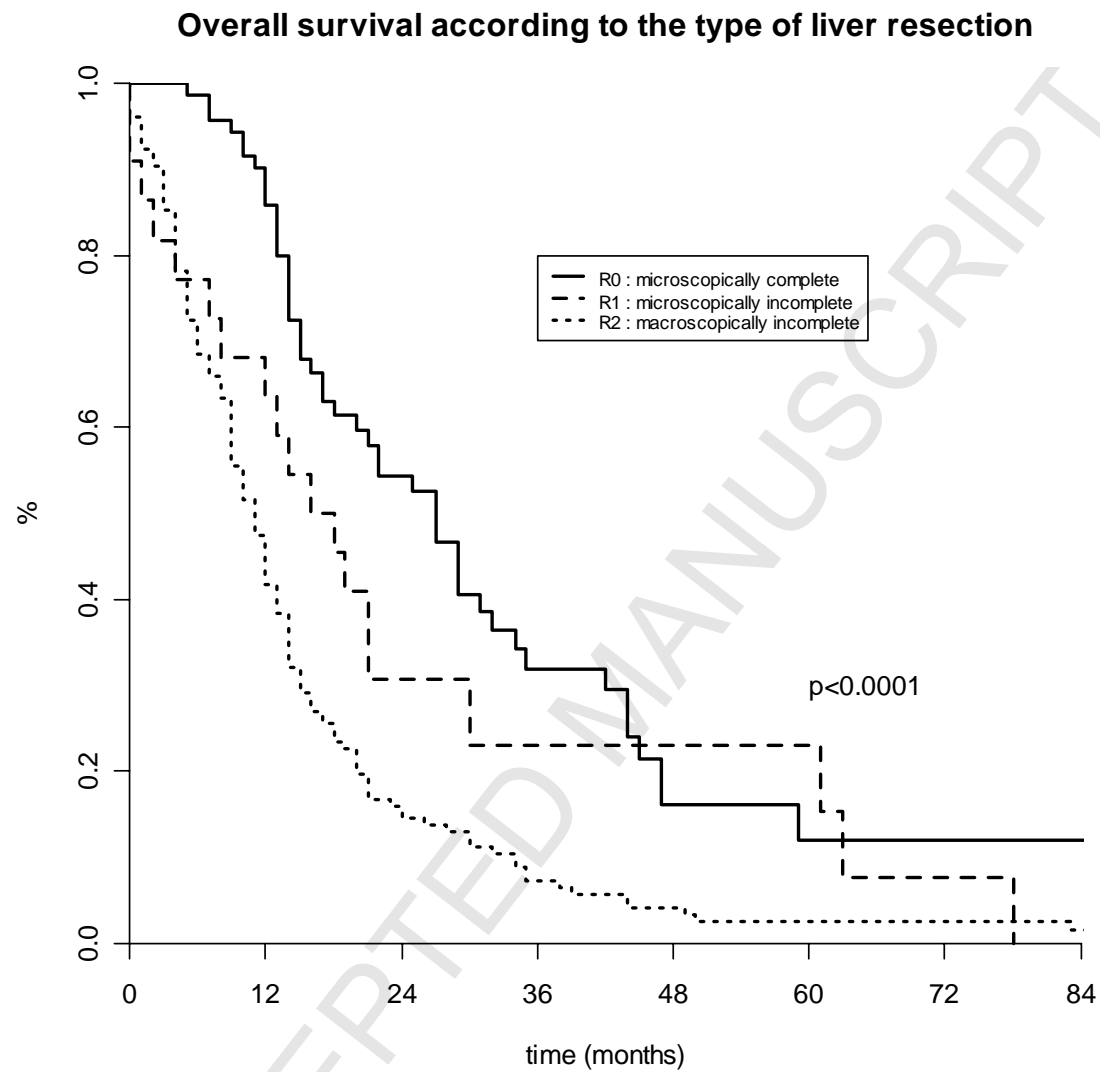
Prognostic factors included :

Age at diagnosis (< 60 years, ≥ 60 years), **time to liver metastases** (< = 24 months, > 24 months), **quality of liver resection** (R0, R1,R2), **number of resected liver metastases** (≤ 4 lesions, > 4 lesions), **miliary disease** (no, yes) and **lesion distribution** (unilobar, multilobar).

Prognostic factors		HR*	CI*	P value
Time to liver metastases	> 24 months	1	[1.47 ; 2.63]	P<0.0001
	≤ 24 months	1.94		
Quality of liver resection	R0	1	[0.95 ; 2.83] [1.15 ; 2.49]	P=0.01
	R1	1.64		
	R2	1.70		
Number of resected liver metastases	≤ 4 lesions	1	[1.19 ; 2.48]	P=0.004
	> 4 lesions	1.72		
Miliary disease	No	1	[1.05 ; 1.97]	P=0.02
	Yes	1.44		

*HR = hazard ratio, CI = confidence interval

Figure 1

**Patients at Risk**

	12	24	36	months
R0	62	29	14	
R1	15	6	3	
R2	68	21	9	

Figure 2

