



**HAL**  
open science

## Clinical outcomes of extrathoracic solitary fibrous tumours

Im. Cranshaw, Pd. Gikas, C. Fisher, K. Thway, Jm. Thomas, Aj. Hayes

► **To cite this version:**

Im. Cranshaw, Pd. Gikas, C. Fisher, K. Thway, Jm. Thomas, et al.. Clinical outcomes of extrathoracic solitary fibrous tumours. *EJSO - European Journal of Surgical Oncology*, 2009, 35 (9), pp.994. 10.1016/j.ejso.2009.02.015 . hal-00556286

**HAL Id: hal-00556286**

**<https://hal.science/hal-00556286>**

Submitted on 16 Jan 2011

**HAL** is a multi-disciplinary open access archive for the deposit and dissemination of scientific research documents, whether they are published or not. The documents may come from teaching and research institutions in France or abroad, or from public or private research centers.

L'archive ouverte pluridisciplinaire **HAL**, est destinée au dépôt et à la diffusion de documents scientifiques de niveau recherche, publiés ou non, émanant des établissements d'enseignement et de recherche français ou étrangers, des laboratoires publics ou privés.

# Accepted Manuscript

Title: Clinical outcomes of extrathoracic solitary fibrous tumours

Authors: IM. Cranshaw, PD. Gikas, C. Fisher, K. Thway, JM. Thomas, AJ. Hayes

PII: S0748-7983(09)00076-6

DOI: [10.1016/j.ejso.2009.02.015](https://doi.org/10.1016/j.ejso.2009.02.015)

Reference: YEJSO 2806

To appear in: *European Journal of Surgical Oncology*

Received Date: 12 June 2007

Revised Date: 23 February 2009

Accepted Date: 24 February 2009

Please cite this article as: Cranshaw IM, Gikas PD, Fisher C, Thway K, Thomas JM, Hayes AJ. Clinical outcomes of extrathoracic solitary fibrous tumours, *European Journal of Surgical Oncology* (2009), doi: 10.1016/j.ejso.2009.0

This is a PDF file of an unedited manuscript that has been accepted for publication. As a service to our customers we are providing this early version of the manuscript. The manuscript will undergo copyediting, typesetting, and review of the resulting proof before it is published in its final form. Please note that during the proof process errors may be discovered which could affect the content, and all legal disclaimers that apply to the journal pertain.



**Clinical outcomes of extrathoracic solitary fibrous tumours.****Cranshaw IM<sup>1</sup>, Gikas PD<sup>1</sup>, Fisher C<sup>2</sup>, Thway K<sup>2</sup>, Thomas JM<sup>1</sup>, Hayes AJ<sup>1</sup>**<sup>1</sup>Sarcoma and Melanoma Unit, Royal Marsden Hospital<sup>2</sup>Department of Pathology, Royal Marsden Hospital

**Correspondance: Mr AJ Hayes  
Sarcoma and Melanoma Unit  
Royal Marsden Hospital  
London SW3 6JJ  
UK  
Ph  
Fax. +442078082232  
[andrew.hayes@rmh.nhs.uk](mailto:andrew.hayes@rmh.nhs.uk)**

ACCEPTED MANUSCRIPT

## Abstract

**Background:** Extra-thoracic solitary fibrous tumours (ESFT) have traditionally been regarded as indolent neoplasms similar to their intra-thoracic counterparts. However there has been some evidence that a subset of more aggressively malignant tumours exist. We examined our experience with these rare tumours in an effort to clarify their clinicopathological behaviour and relate this to their histopathological findings.

**Patients/Methods:** All patients with a histopathological diagnosis of solitary fibrous tumour (SFT) who presented to the Royal Marsden Hospital between 1994 and 2006 were reviewed. Clinicopathological data were recorded for all cases and subset analysis performed to compare rates of locoregional recurrence, distant metastases and death.

**Results:** There were 33 cases included in the study. 18 cases had malignant features on histological examination. Locoregional recurrent disease was more common in those with malignant histopathological findings compared to those with benign histopathology (6/18 vs 0/15 p 0.021). Distant metastatic disease was more common in those with malignant histopathological findings (7/18 vs 1/15 p 0.046) and these patients were at increased risk of death (10/18 vs 0/15 p < 0.01). The presence of malignant histopathology was the only factor to affect survival with no benign cases dying of disease and malignant cases having a median survival of 59 months (p 0.003)

**Conclusion:** In our experience ESFT have a higher rate of malignant behaviour than that classically described. Those tumours with atypical or malignant features on histological examination have poor prognosis and should be managed and followed up in the same manner as other high grade soft tissue tumours.

**Key Words:** *Solitary fibrous tumour, extrathoracic, prognosis, malignant*

## Introduction

Solitary fibrous tumours (SFT) are rare spindle cell neoplasms that were initially regarded as occurring exclusively within the thoracic cavity with a pleural origin.<sup>(1)</sup> These pleurally based neoplasms are predominantly benign with malignant pathology and behaviour described in 10% to 36% of cases.<sup>(2,3,4,5)</sup>

More recently SFT have been described in a wide variety of extra-thoracic locations including the head and neck,<sup>(6,7,8,9,10)</sup> abdominal and retroperitoneal sites<sup>(9,11,12,13,14)</sup> and soft tissues.<sup>(9,15,16)</sup> Most of these early series of ESFT reported primary pathological data but gave little analysis of the correlation between pathological findings and clinical course, they predominantly represent descriptive pathological series with short clinical follow-up.

These extra-thoracic solitary fibrous tumours (ESFT) have been considered separately to their intra-thoracic counterparts and are less common making up only a third of combined series.<sup>(17)</sup> Initial series of ESFT reported lower rates of malignancy compared to their intra-thoracic counterparts and as a group were considered to usually behave in a benign fashion. However a more in depth investigation by Vallat-Decouvelaere et al identified a subgroup of atypical and malignant tumours that behaved in a more aggressive fashion or had atypical histology and represented 11% of their series.<sup>(18)</sup> These findings suggested that ESFT behaviour was more in line with that of their intra-thoracic counterparts. A more recent single large series of SFT in all locations showed no difference between intra-thoracic SFT and ESFT with regards to rates of malignant pathological diagnosis (20.4% vs 20%) but ESFT had a small but significantly higher rate of locoregional recurrence suggesting more aggressive clinical behaviour.<sup>(17)</sup>

Our impression was that the ESFT seen in our tertiary referral soft tissue sarcoma unit included a significant proportion of aggressive tumours and we are lucky to have a complete electronic record of these cases along with dedicated long clinical follow-up for the majority of our cases performed at our institution. We collected our experience of ESFT to assess the tumour characteristics and histopathological findings and correlate these with the clinical outcomes for these patients.

## Patients and methods

### *Patient population*

A review of all patients with a pathological diagnosis of SFT occurring outside the thoracic cavity between 1998 and 2006 was performed. Thirty-three patients were identified. Data was obtained from the hospitals electronic patient records and where necessary from contact with the patient's family doctor.

Clinical data was recorded including patient demographic information, histopathological data and follow-up data including episodes of local recurrence, metastatic disease and patient death.

### *Statistical analysis*

Student t-test was used to determine differences between continuous variables and a two-sided Fisher's exact test for categorical variables. Survival curves were constructed using the Kaplan-Meier method with death as the endpoint. Time to endpoint was calculated from the date of initial surgery. Statistical analysis for survival curves was based on the log rank test with Pearson chi-square analysis.

### *Pathological evaluation*

Pathological assessment was performed by an expert soft tissue pathologist in all cases. The criteria for histopathological diagnosis were for circumscribed spindle cell lesions, in which nuclear atypia was absent, with a 'patternless' architecture and a combination of both hypercellular and hypocellular areas, separated by thick bands of hyalinized collagen and with interspersed, branching vessels. Mitotic figures are generally scant. Tumour cells are characteristically immunohistochemically positive for the CD34 antibody, and may also show positivity for bcl-2, CD99 and smooth muscle antigen. A histopathological diagnosis of malignant SFT was made for lesions with the above features, but with areas also demonstrating hypercellularity, at least focal cytological atypia, a mitotic index of  $\geq 4 / 10$  high power microscopic fields, tumour necrosis and / or infiltrative margins. Rarely, cases showed an abrupt transition from conventional SFT to high-grade sarcoma.

## **Results**

Thirty-three patients were diagnosed with ESFT at the Royal Marsden Hospital (RMH) during the eight year study period from 1998 to 2006. There were 18 men and 15 women. Their age ranged from 30 to 85 years with a mean age of 54 years. Patients had either their primary surgery or secondary wide excision performed at RMH and follow-up was performed in all cases by our unit. 18 tumours were classified as malignant ESFT and 15 tumours were benign. We collected data on both patient and tumour characteristics and these are presented in Table 1.

### *Anatomical distribution*

Our group of ESFT were widely distributed in terms of anatomical location. Tumours more commonly occurred in the lower limb or in an intra-abdominal site. The full breakdown of anatomical location is presented in Table 2. This distribution differs from our experience with other soft tissue tumours with a greater percentage of ESFT occurring within the abdominal and retroperitoneal compartments.

### *Treatment and follow-up*

Complete resection was achieved in 32 cases and one patient died prior to any surgical intervention from an acute cardiovascular cause. This patient's tumour had been diagnosed on core biopsy and was subsequently removed at autopsy and sent for

histopathological examination. The majority of patients treated at The Royal Marsden had surgical resection without any adjuvant therapy. In four cases of malignant extremity ESFT adjuvant radiotherapy was used. No patients were treated with adjuvant chemotherapy but four had palliative chemotherapy for metastatic disease. One patient had doxorubicin alone and the others had doxorubicin and ifosfamide regimes sequentially.

Mean follow-up was 43 months (range 4-103 months). Assessing patients who died, mean time to death was 33 months.

### *Prognostic factors*

The clinical and pathological features in Tables 1 and 2 were analysed for their relationship to local recurrence, metastatic disease and survival. The most significant prognostic factor was whether the tumour was classified as benign or malignant on definitive histopathology. Those patients with a malignant tumour had significantly higher rates of local recurrence (Odds ratio 16.21, p 0.021), higher rates of subsequent metastatic disease (Odds ratio 8.91, p 0.046) and much higher rates of death (Odds ratio 38.29, p 0.0005) than their benign counterparts.

Of the 18 cases with malignant ESFT 6 developed a local recurrence and 7 metastatic disease. The five-year survival rate for malignant tumours was 40% and the mean survival following development of metastases was only 18 months. Survival curves for malignant versus benign tumours were significantly different (p 0.003) and are presented in Figure 1.

The 15 benign cases had a five-year survival rate of 100%. However one patient who had a tumour classified as benign on initial histopathology developed metastatic disease 100 months following his initial surgery. His primary tumour was in the right groin and he developed a new mass in the left groin which was removed and found to be a further soft tissue deposit of SFT. Staging investigations then discovered that he had a new liver lesion consistent with metastatic disease which has not been removed. He remains alive with disease 103 months following his original surgery. His histology was reviewed and both the original tumour and the metastatic disease were confirmed as benign by pathological criteria.

We also found that when compared to tumours outside the abdominal cavity or retroperitoneum, retroperitoneal or intraabdominal tumours had a significantly higher rate of local recurrence (Odds ratio 21.67 p <0.01). All these tumours were “completely excised” however as with other retroperitoneal sarcomas local recurrence is a problem due to the inability to perform a radical resection of adjacent vital structures. Although we were able to demonstrate an increased rate of death from disease for those with intraabdominal or retroperitoneal tumours (Odds ratio 5.83, p 0.057) this just failed to reach significance. A summary of the significant characteristics is shown in Table 3. None of the other characteristics were associated with a significantly increased rate of local recurrence, metastatic disease or death.

## **Discussion**

Originally solitary fibrous tumours were thought to occur only within the thoracic cavity and these tumours had low rates of local recurrence and metastases after surgical treatment. Series of intra-thoracic tumours reported low rates of local recurrence and distant metastatic disease. However it has become apparent that solitary fibrous tumours can more rarely occur in a wide variety of anatomical locations outside the thoracic cavity. These tumours were initially reported as case reports with local recurrence rates as low as 6% and a mortality rate of around 1%.<sup>(18)</sup> Therefore initial results suggested that ESFT were a predominantly benign entity with less risk of recurrent disease than that of their intra-thoracic counterparts. However these early observations were based on short clinical follow-up of cases described predominantly in the pathology literature.

#### *Previous clinico-pathological reports*

In Vallat-Decouvelaere's subsequent large retrospective series of 92 cases of ESFT the investigators identified 10 cases with malignant pathological features and 8 of these cases went on to develop local recurrence or distant metastases. Median follow-up was only 24 months in this series but they recorded no deaths within this time.<sup>(18)</sup> This series and other smaller series have reported rates of malignant or atypical histology of between 11% and 33% for ESFT.<sup>(11,16,18,19)</sup> However many of these studies again were primarily focused on the pathological features of ESFT and made little assessment of clinical outcome data or had mean clinical follow-up of less than 12 months. These papers did however indicate that ESFT were probably not the predominantly benign entity that had originally been described and that their pathological behaviour seemed much more similar to their intra-thoracic counterparts. The observation was also made that occasionally benign SFT behaved in a clinically malignant fashion particularly after a long period of time from the original tumour.<sup>(18)</sup>

Following on a more recent paper investigating the clinico-pathological correlates of SFT, extra-thoracic location was identified as an adverse prognostic factor for local recurrence (but not metastatic disease) within the bounds of a median follow-up of 28 months.<sup>(17)</sup> In the most recent report on ESFT, of 9 cases identified, 2 cases had atypical features histologically but no patient died of their disease within a relatively short mean follow-up of 26 months.<sup>(20)</sup> Together these findings suggest a subgroup of pathologically atypical/malignant ESFT that may have more aggressive clinical behaviour.

#### *Histopathological result defines outcome*

Our results differ from previous studies in that our proportion of malignant tumours is higher at 55% and our clinical follow-up is for a longer period of time, (median 43 months). We believe this is due to the large referral base for soft tissue sarcoma to our unit and may be in part due to a bias towards referring cases with atypical histopathology. Our clinical experience with these tumours is that the malignant sub-group have a poor prognosis with relatively high rates of local recurrence and metastatic disease. This is particularly evident due to the extended follow-up that we are able to provide at our unit.

Our results indicate that those cases with malignant histopathological characteristics behave clinically in a manner similar to high grade soft tissue sarcoma and should be



treated and followed up accordingly. Initial experience suggesting that these tumours are usually clinically indolent appears incorrect in light of these results and rates of recurrence may have been underestimated by previous clinicopathological studies with short follow-up periods. The presence of metastatic disease in one case with benign tumour characteristics serves to corroborate previous reports of occasional malignant behaviour for tumours with initially benign histopathological appearances.

### **Conclusion**

In conclusion, our experience would suggest that ESFT are often aggressively malignant tumours with a poor prognosis (5-year survival 40%) and that even in the presence of benign histopathological features there is a risk of malignant behaviour with long follow-up. Presence of malignant histopathological features remains the best indicator of poor clinical outcome for these cases and extended follow-up is necessary to identify and manage the relatively high rate of recurrent disease. Large tumours within the abdominal cavity or retroperitoneum have a propensity to recur locally as is the case with other large retroperitoneal tumours and are probably associated with a poorer outcome than other sites. It is important to manage ESFT with atypical histopathological features in the same manner as other high grade soft tissue tumours.

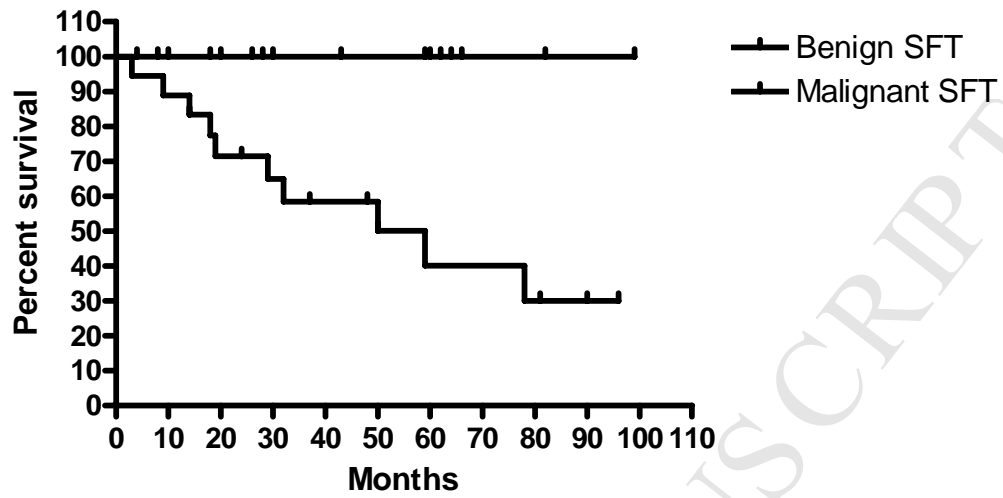
**Table 1. Patient and tumour characteristics of 33 extrathoracic solitary fibrous tumours.**

<b>Characteristic</b>	<b>Number</b>
Median Age (range)	54yrs (30-85yrs)
Gender	
• Male	18
• Female	15
Tumour Size (range)	13cm (5-24cm)
• ≤ 5cm	3
• 5-10cm	9
• >10cm	21
Tumour weight (range)	819g (125-3395g)
Pathological classification	
• Benign	15
• Malignant	18
Tumour Depth	
• Superficial	6
• Deep	27

**Table 2: Anatomical location of extrathoracic solitary fibrous tumours.**

<b>SITE</b>	<b>Number</b>	<b>%</b>
Limbs – upper	3	10
- lower	10	30
Intraabdominal/Pelvis	10	30
Retroperitoneal	5	15
Trunk	5	15

### Survival Benign SFT vs Malignant SFT



**Table 3: Significant prognostic factors for extra-thoracic solitary fibrous tumours.**

<b>Prognostic factor</b>	<b>Local Recurrence</b> <i>Odds ratio (p value)</i>	<b>Metastases</b> <i>Odds ratio (p value)</i>	<b>Death</b> <i>Odds ratio (p value)</i>
Site is Intrabdominal, Retroperitoneal or Pelvic	<b>21.67 (p &lt; 0.01)</b>	2.33 (p 0.654)	5.83 (p 0.057)
Malignant histopathology	<b>16.21 (p 0.021)</b>	<b>8.91 (p 0.046)</b>	<b>38.29 (p &lt; 0.01)</b>

### Conflict of interest

The authors state that they have no conflict of interest.

### References:

1. Klemperer P, Rabin CB. Primary neoplasms of the pleura: a report of five cases. *Arch Pathol* 1931; 11:385-412.
2. Dalton WT, Zolliker AS, McCaughey WT, Jaques J, Kannerstein M. Localized primary tumors of the pleura: an analysis of 40 cases. *Cancer*. 1979 Oct; 44(4): 1465-75.
3. England DM, Hochholzer L, McCarthy MJ. Localized benign and malignant fibrous tumors of the pleura. A clinicopathologic review of 223 cases. *Am J Surg Pathol*. 1989 Aug;13(8):640-58.
4. Briselli M, Mark EJ, Dickersin GR. Solitary fibrous tumors of the pleura: eight new cases and review of 360 cases in the literature. *Cancer*. 1981 Jun 1; 47(11): 2678-89.
5. Witkin GB, Rosai J. Solitary fibrous tumor of the mediastinum: A report of 14 cases. *Am J Surg Pathol* 1989;13:547-557.
6. Carneiro SS, Scheithauer BW, Nascimento AG, Hirose T, Davis DH. Solitary fibrous tumor of the meninges: A lesion distinct from fibrous meningioma. *Am J Clin Pathol* 1996;106:217-224.
7. DeBacker CM, Bodker F, Putterman AM, Beckmann E. Solitary fibrous tumor of the orbit. *Am J Ophthalmol* 1996;121:447-449.
8. Kie JH, Kim JY, Park YN, et al. Solitary fibrous tumour of the thyroid. *Histopathology* 1997;30:365-368.
9. Mentzel T, Bainbridge TC, Katenkamp D. Solitary fibrous tumour: clinicopathological, immunohistochemical, and ultrastructural analysis of 12 cases arising in soft tissues, nasal cavity and nasopharynx, urinary bladder and prostate. *Virchows Arch* 1997;430:445-453.
10. Gangopadhyay K, Taibah K, Manohar MB, Kfoury H. Solitary fibrous tumor of the parapharyngeal space: A case report and review of the literature. *Ear Nose Throat J* 1996;75:681-684.
11. Fukunaga M, Naganuma H, Ushigome S, Endo Y, Ishikawa E. Malignant solitary fibrous tumor of the peritoneum. *Histopathology* 1996;28:463-466.
12. Levine TS, Rose DSC. Solitary fibrous tumour of the liver. *Histopathology* 1997;30:393-398.
13. Young RH, Clement PB, McCaughey WTE. Solitary fibrous tumors ('fibrous mesotheliomas') of the peritoneum: A report of three cases and a review of the literature. *Arch Pathol Lab Med* 1990;114:493-495.
14. Gelb AB, Simmons ML, Weidner N. Solitary fibrous tumor involving the renal capsule. *Am J Surg Pathol* 1996;20:1288-1295.
15. Hasegawa T, Hirose T, Seki K, Yang P, Sano T. Solitary fibrous tumor of the soft tissue. *Am J Clin Pathol* 1996;106:325-331.

16. Nielsen GP, O'Connell JX, Dickersin GR, Rosenberg AE. Solitary fibrous tumor of soft tissue: A report of 15 cases, including 5 malignant examples with light microscopic, immunohistochemical, and ultrastructural data. *Mod Pathol* 1997;10:1028-1037.
17. Gold JS, Antonescu CR, Hadju C, Ferrone CR, Hussain M, Lewis JL, Brennan MF, Coit DG. Clinicopathologic correlates of solitary fibrous tumors. *Cancer*. 2002 Feb 15;94(4):1057-68.
18. Vallat-Decouvelaere AV, Dry SM, Fletcher CD. Atypical and Malignant Solitary Fibrous Tumors in Extrathoracic Locations: Evidence of Their Comparability to Intra-Thoracic Tumors. *Am J Surg Pathol*. 1998; 22(12):1501-1511.
19. Fukunaga M, Nickaido T. Solitary fibrous tumour of the renal peripelvis. *Histopathology* 1997;30:451-456.
20. Daigeler A, Lehnhardt M, Langer S, Steinstraesser L, Steinau H, Mentzel T, Kuhnen C. Clinicopathological findings in a case series of extrathoracic solitary fibrous tumors of soft tissues. *BMC Surgery* 2006;6(10):