



HAL
open science

Staging chest radiography is not useful in patients with colorectal cancer

C. Gielen, I. Sanli, L. Stroeken, A. Botterweck, K. Hulsewé, A. Hoofwijk

► To cite this version:

C. Gielen, I. Sanli, L. Stroeken, A. Botterweck, K. Hulsewé, et al.. Staging chest radiography is not useful in patients with colorectal cancer. *EJSO - European Journal of Surgical Oncology*, 2009, 35 (11), pp.1174. 10.1016/j.ejso.2009.02.012 . hal-00556284

HAL Id: hal-00556284

<https://hal.science/hal-00556284>

Submitted on 16 Jan 2011


HAL is a multi-disciplinary open access archive for the deposit and dissemination of scientific research documents, whether they are published or not. The documents may come from teaching and research institutions in France or abroad, or from public or private research centers.

L'archive ouverte pluridisciplinaire **HAL**, est destinée au dépôt et à la diffusion de documents scientifiques de niveau recherche, publiés ou non, émanant des établissements d'enseignement et de recherche français ou étrangers, des laboratoires publics ou privés.

Accepted Manuscript

Title: Staging chest radiography is not useful in patients with colorectal cancer

Authors: C. Gielen, I. Sanli, L. Stroeken, A. Botterweck, K. Hulsewé, A. Hoofwijk



PII: S0748-7983(09)00069-9

DOI: [10.1016/j.ejsso.2009.02.012](https://doi.org/10.1016/j.ejsso.2009.02.012)

Reference: YEJSO 2803

To appear in: *European Journal of Surgical Oncology*

Received Date: 21 September 2008

Revised Date: 22 December 2008

Accepted Date: 17 February 2009

Please cite this article as: Gielen C, Sanli I, Stroeken L, Botterweck A, Hulsewé K, Hoofwijk A. Staging chest radiography is not useful in patients with colorectal cancer, *European Journal of Surgical Oncology* (2009), doi: [10.1016/j.ejsso.2009.02.012](https://doi.org/10.1016/j.ejsso.2009.02.012)

This is a PDF file of an unedited manuscript that has been accepted for publication. As a service to our customers we are providing this early version of the manuscript. The manuscript will undergo copyediting, typesetting, and review of the resulting proof before it is published in its final form. Please note that during the production process errors may be discovered which could affect the content, and all legal disclaimers that apply to the journal pertain.

Title**Staging chest radiography is not useful in patients with colorectal cancer.**

Gielen C^a, Sanli I^a, Stroeken L^a, Botterweck A^b, Hulsewé K^a, Hoofwijk A^a

^a Department of Surgery, Maasland Hospital Sittard, PO.Box 5500, 6130MB Sittard, The Netherlands.

^b Maastricht Cancer Registry, Comprehensive Cancer Centre Limburg, P.B. 2208, 6201HA Maastricht, The Netherlands.

C.Gielen:	ConstantGielen@yahoo.com
I.Sanli:	ilknursanli@hotmail.com
L.P.G. Stroeken:	Lukas.st@gmail.com
A.A.M. Botterweck:	A.botterweck@ikl.nl
K.W. Hulsewé:	K.Hulsewe@orbisconcern.nl
A.G.M. Hoofwijk:	T.Hoofwijk@orbisconcern.nl

Corresponding Author:

Name:	I. Sanli
Postal address:	Polanenweg 11
Area Code:	5616 EH
Town:	Eindhoven
Country:	The Netherlands
Telephone Number:	06-49244918
Fax Number:	-
E-mail address:	ilknursanli@hotmail.com

Abstract

Introduction

International guidelines recommend a staging chest x-ray (SCXR) in patients with colorectal cancer to exclude pulmonary metastases. The SCXR is controversial, because evidence to support its use is insufficient. The aim of this study was to assess determine the value of the SCXR in patients with colorectal cancer.

Patients and Methods

Between January 1992 and August 2006, data from all patients with colorectal cancer, who presented to the surgical clinic of the Maasland Hospital, were prospectively collected and analysed. The main outcome was the rate of pulmonary metastases on SCXR. The secondary outcome was the influence of SCXR on patient management.

Results

Out of 1410 patients, 1057 had a chest x-ray before their operation. Median follow-up time was 4 years and 6 months (25th percentile 1 year and 7 months, 75th percentile 6 years and 11 months). Eight patients were excluded because follow-up data were incomplete. In 24 patients the chest x-ray was suggestive of malignancy; 9 of these patients actually had pulmonary metastases. Patient management was changed in 5 of them. Four patients were identified to have primary lung cancer. These data indicate a 0.86% detection rate of pulmonary metastases (confidence interval, 0.3% to 1.4%).

Discussion

Our results show that SCXR has a low detection rate of pulmonary metastases and a small influence on patient management. In accordance with previous studies our data do not support the routine use of the SCXR in patients with colorectal cancer.

Keywords

Radiography, thoracic; neoplasm staging; colorectal neoplasms

Introduction

Colorectal cancer is the second most commonly diagnosed cancer in the The Netherlands.^[1] In 2005 there were 10 851 patients diagnosed with colorectal cancer in The Netherlands only, this accounts for 13% of all cancers.^[1] 15 to 20% will have metastatic disease at the moment of diagnosis^[2, 3]

Accurate preoperative staging is essential, as the presence of metastases can change management in several ways.^[4] Chemotherapy increases survival in patients with inoperable metastatic disease.^[5] Moreover, patients may be spared unnecessary surgical procedures, although surgery for relief of obstructive symptoms may still be indicated.^[6] However surgery for colorectal cancer often remains necessary due to obstructive symptoms. The detection of potential resectable metastases has the greatest impact on survival.^[4] While patients with metastatic disease have a median survival of 10 months; patients who will have a curative resection of metastases in the liver or lungs have a 5-years survival rate of respectively 30 to 40% and 30 to 60%.^[4, 5]

Optimal staging strategies have yet to be defined, as current guidelines show a great variety and are based on small series of patients.^[4] The European Society for Medical Oncology and the Dutch Working group Gastrointestinal Tumours recommend in their guidelines the use of a routine staging chest x-ray (SCXR) to exclude pulmonary metastases in patients with colorectal cancer.^[7, 8] The lungs are, after the liver, the second most common place of metastases.⁹ However evidence to support the use of the SCXR is scarce.

The detection rate of pulmonary metastases is low and the greatest value of the SCXR might be the additional information on cardio-respiratory disease prior to surgery.^[10] A chest x-ray will only identify 1.8 to 12.0% of resectable metastases in patients with pulmonary metastases.^[11] We found no data describing the influence of the SCXR on patient management.

Based on our clinical experience and the available literature, we formed the hypothesis that the routine use of a SCXR has no added value in the preoperative staging of patients with colorectal cancer. We performed a prospective cohort study to determine the value of the SCXR in patients with newly diagnosed colorectal cancer.

Patients and Methods

Study population and data collection

All patients with colorectal cancer who were admitted to the surgical department of the Maasland Hospital situated in the South-east of The Netherlands, between January 1992 and August 2006 were included. Since 1992 basic characteristics of all patients admitted at our surgical department are prospectively gathered in a 'diagnosis and complication registry'. This database consists of detailed information about diagnosis, treatment, complications and pathological data. All patients with newly diagnosed histological proven colorectal malignancies were included in our study.

Follow-up data on survival, the development of metastases and recurrent disease were retrospectively drawn from patient charts and electronic patient files until January 1st 2008. Missing data were retrieved from the Maastricht Cancer registry database of the Comprehensive Cancer Centre Limburg or through contact with the general practitioners.

Chest x-rays were included when they were made within 6 months prior to operative treatment. These included SCXR that were made to exclude pulmonary metastases, but also chest x-rays that were made for a variety of other reasons. These chest x-rays were defined as suspicious or unsuspecting, based on the report of the radiologist. A suspicious chest x-ray had an abnormality or sign that was suggestive of pulmonary metastases or was inconclusive and needed further diagnostic work-up. We considered chest x-rays false positive if no pulmonary metastases were detected during prolonged follow-up. Patients who had a suggestive x-ray all received additional investigations to exclude pulmonary metastases. These investigations included additional chest x-rays, bronchoscopy with bronchoalveolar, CT scans, PET-CT scans and/or image guided punctions for pathological examination. A non-suspicious chest x-ray was described as normal or pathological, but not suggestive for pulmonary metastases.

Patients who had received a chest x-ray, but who had no or incomplete follow-up data within the first 6 months were excluded from analysis.

Outcome values

The primary outcome was the rate of true-positive chest x-rays. A true positive chest x-ray was reported as suspicious and was confirmed by subsequent additional diagnostics. A true negative chest x-ray was reported as unsuspecting, and the patient did not develop pulmonary metastases on follow-up within the next 6 months. Secondly we evaluated whether these chest x-rays changed the TNM classification, the surgical or medical management.

Statistical analyses

For descriptive analysis, data were recorded in a Microsoft Access 2003® database. SPSS 15.0® computer package was used for all statistical analyses. Data are expressed as mean and percentiles. Patient characteristics between the group that had received a chest x-ray before their operation and the group that did not receive one were compared. The detection rate was calculated by using the number of patients with a chest x-ray as a denominator.

Results

A total of 1410 patients with colorectal cancer presented to our surgical clinic between January 1992 and August 2006 (Figure 1). 1057 patients had a SCXR or a chest x-ray in the 6 months prior to their operation. The mean time a chest x-ray was taken prior to operative treatment was 35 days (SD 11 days). Eight patients were excluded from the analysis as follow-up data were incomplete (lost to follow-up); none of these patients had a SCXR that was suggestive of pulmonary metastases.

Table 1 shows patient characteristics of the group of patients with and without a chest x-ray. There was no significant difference between these groups regarding age, sex, tumour location, differentiation grade and AJCC-classification. Median follow-up time was 4 years and 6 months (25th percentile 1 year and 7 months, 75th percentile 6 years and 11 months). 110 patients developed pulmonary metastases during follow-up.

Description of the suggestive SCXR

Out of 1057 patients, 9 patients (0.86%; confidence interval, 0.3% to 1.4%) had pulmonary metastases on chest x-ray. In one case a chest x-ray was taken before the diagnosis of colorectal cancer was made, as this patient presented with pain during respiration.

Four patients were already known to have metastatic disease at other sites: for these patients the surgical and medical management did not change. In the remaining 5 patients the TNM classification was upstaged. In all of these patients the TNM classification was upstaged from stage 2 to 4 disease. In 2 of these patients the surgical management changed from curative to palliative. One of these 5 patients was deemed fit to receive chemotherapy. None of these patients received pulmonary metastasectomy because of frailty. Out of the 15 chest x-rays that were false positive, 4 patients were diagnosed to have primary lung cancer. In these 4 patients surgical management of the colorectal cancer did not change.

Ten patients had a chest x-ray that was false negative as they were diagnosed having pulmonary metastases within the 6 month following the first preoperative chest x-ray.

Discussion

In our study only 0.86% of the chest x-rays showed pulmonary metastases, which is lower than the 2.9% Griffiths et al. reported in a prospective study of 208 patients.^[10] In only 5 out of 9 patients with pulmonary metastases final management changed due to the SCXR.

Limitations

One of the limitations of our study concerns selection bias. Only patients who presented to the surgical department of the Maasland Hospital were analysed. It is possible that some patients were not referred to our surgical clinic. A second bias is caused by the fact that 25 % of the patients did not receive a chest x-ray. This is a violation of protocol and might have been caused by the long standing belief in our department that the SCXR is not useful. However, the influence this may have had seems to be small as there is no significant difference in baseline characteristics, the development of pulmonary metastasis and the five year survival rates between the group of patients with a chest x-ray and the group without one. Also the rate of patients with pulmonary metastases during follow-up (7.8%) is in line with other studies. Up to 10% of patients will develop pulmonary metastases that are clinically detected.^[12] In a 5 year follow-up study Staib et al. reported that 4.6% of 2400 patients developed metastases to the lungs.^[13]

Due to incomplete follow-up data, 8 patients were excluded. None of these patients had chest x-rays that were suggestive of pulmonary metastases. Therefore, this probably does not significantly affect our data.

Arguments to support the use of SCXR

The literature that supports the use of a SCXR addresses several arguments. Chest radiography is inexpensive, widely available and has low associated risks. Besides the detection of pulmonary metastases, a SCXR also provides information on cardio-respiratory disease prior to surgery and may detect primary lung cancer.^[10] Furthermore, a SCXR may serve as a baseline investigation to evaluate abnormalities on chest x-rays that are taken during follow-up.

These arguments are not convincing in our opinion. Our results confirm a low incidence of synchronous pulmonary metastases in colorectal cancer patients. Furthermore, the detection rate of the SCXR was low: 10/19 patients with pulmonary metastases were not identified with SCXR.

Naturally, patients should not be withheld a preoperative chest x-ray whenever a good indication exists to exclude cardiopulmonary disease. But the value of additional information on cardio-respiratory morbidity is small, and current evidence does not support the routine use of preoperative chest x-rays in patients undergoing general anaesthesia.^[14]

Screening for lung cancer with chest radiography in a high risk population is not supported by current evidence.^[15] The incidence of primary lung cancer in patients with colorectal cancer is reported to be 0.6%.^[16] This percentage is lower than the percentage of 0.83% that was

reported in a high-risk population.^[17] For that reason, it is unlikely that patients with colorectal cancer will benefit of this form of screening.

The value of a baseline image to evaluate abnormalities on chest x-rays that are taken during follow-up seems to be limited, as studies have shown that the routine use of chest x-rays during follow-up are not useful.

With regard to the value of the SCXR as a baseline for follow up studies a recently published clinical review concerning perioperative imaging did not find data to support its use.^[18] Furthermore, the low preoperative sensitivity of the SCXR also applies in the postoperative setting. Therefore other modalities such as (PET-) CT may be more appropriate than chest X-rays for follow up purposes thereby undermining value of the SCXR as a baseline image.

Other diagnostic modalities

Several studies have evaluated other preoperative diagnostic tests to exclude pulmonary metastases. The American guidelines recommend a CT-scan instead of a SCXR.^[18] CT has a higher sensitivity than a chest x-ray, however the low specificity results in many false positive findings.^[19, 20] The use of multi-detector CT does not significantly improve the detection rates of extra-hepatic metastases.^[21]

The PET/CT has shown to be very accurate for the detection of metastases.^[22] Compared to CT, PET/CT is superior in the detection of extra-hepatic metastases. Sensitivity of 89% for the PET/CT compared to a sensitivity of 61% for the CT.^[23] Excellent results can be expected for pulmonary metastases.^[24] PET/CT may replace the diagnostic CT in the preoperative staging of colorectal cancer.^[23] Increased carcinoembryonic antigen levels during follow-up are useful to selectively use PET/CT.^[22]

Our results indicate that the detection rate of pulmonary metastases on SCXR in patients with colorectal cancer is low, partly due to a low sensitivity but primarily due to a low incidence rate. Given the existing literature and the results of our study, it is unlikely that the routine use of the SCXR is useful or cost-effective. In the preoperative workup a chest x-ray may be useful to provide information on co-existent cardio-respiratory disease, but it should only be applied in a selected group of patients. We suggest on basis of our data that a SCXR is not indicated as a routine preoperative staging modality in patients with colorectal cancer.

Conflict of interest statement

The authors state that they have no conflict of interest.

Literature

1. www.ikcnet.nl [homepage on the Internet]. Utrecht: Comprehensive Cancer Centres; [cited 2008 Sept 2]. Available from:
http://www.ikcnet.nl/cijfers/index.php?taal=nl&frequentiemaat=1®io=Landelijk&soort_kanker=
2. Jessup JM, McGinnis LS, Steele GD Jr, Menck HR, Winchester DP. The National Cancer Data Base. Report on colon cancer. *Cancer*. 1996 Aug 15;78(4):918-26.
3. Jessup JM, Stewart AK, Menck HR. The National Cancer Data Base report on patterns of care for adenocarcinoma of the rectum, 1985-95. *Cancer*. 1998 Dec 1;83(11):2408-18.
4. Kosmider S, Stella DL, Field K, Moore M, Ananda S, Oakman C, Singh M, Gibbs P. Preoperative Investigations for Metastatic Staging of Colon and Rectal Cancer across Multiple Centres- What is Current Practice? *Colorectal Dis*. 2008 Jul 4.
5. Simmonds PC. Palliative chemotherapy for advanced colorectal cancer: systematic review and meta-analysis. *Colorectal Cancer Collaborative Group. BMJ* 2000;321(7260):531-5.
6. Scoggins CR, Meszoely IM, Blanke CD, Beauchamp RD, Leach SD. Nonoperative management of primary colorectal cancer in patients with stage IV disease. *Ann Surg Oncol*. 1999 Oct-Nov;6(7):629-30.
7. Van Cutsem EJ, Oliveira J; ESMO Guidelines Working Group. Colon cancer: ESMO clinical recommendations for diagnosis, adjuvant treatment and follow-up. *Ann Oncol*. 2008 May;19 Suppl 2:29-30.
8. Oncoline [homepage on the internet]. Utrecht: Nationwide workinggroup gastro intestinal tumours [updated 2008 Jan 09; 2008 Aug 15]. Richtlijn coloncarcinoom Version 2.0; [about 1 screen]. Available from: http://www.oncoline.nl/index.php?pagina=/richtlijn/item/pagina.php&richtlijn_id=562
9. Okumura S, Kondo H, Tsuboi M, Nakayama H, Asamura H, Tsuchiya R, Naruke T. Pulmonary resection for metastatic colorectal cancer: experiences with 159 patients. *J Thorac Cardiovasc Surg*. 1996 Oct;112(4):867-74.
10. Griffiths E A, Browell DA, Cunliffe WJ. Evaluation of a pre-operative staging protocol in the management of colorectal carcinoma. *Colorectal Disease* 2005 Jan 7(1):35-42.
11. Anthony T, Simmang C, Hyman N, et al. Practice parameters for the surveillance and follow-up of patients with colon and rectal cancer. *Dis Colon Rectum*. 2004; 47:807-17.
12. Asbun HJ, Hughes KS. Management of recurrent and metastatic colorectal carcinoma. *Surg Clin North Am*. 1993 Feb;73(1):145-66.
13. Staib L, Link KH, Blatz A, Beger HG. Surgery of colorectal cancer: surgical morbidity and five- and ten-year results in 2400 patients--monoinstitutional experience. *World J Surg*. 2002 Jan;26(1):59-66. Epub 2001 Nov 26.
14. Joo HS, Wong J, Naik VN, Savoldelli GL. The value of screening preoperative chest x-rays: a systematic review. *Can J Anaesth*. 2005 Jun-Jul;52(6):568-74.
15. Manser RL, Irving LB, Stone C, Byrnes G, Abramson M, Campbell D. Screening for lung cancer. *Cochrane Database Syst Rev*. 2004;(1):CD001991.
16. Evans HS, Moller H, Robinson D, Lewis CM, Bell CM, Hodgson SV. The risk of subsequent primary cancers after colorectal cancer in southeast England. *Gut* 2002; 50: 647-652

17. Fontana RS, Sanderson DR, Taylor WF, Woolner LB, Miller WE, Muhm JR, Uhlenhopp MA. Early lung cancer detection: results of the initial (prevalence) radiologic and cytologic screening in the Mayo Clinic study. *Am Rev Respir Dis.* 1984 Oct;130(4):561-5.
18. Low G, Tho LM, Leen E, Wiebe E, Kakumanu S, McDonald AC, Poon FW. The role of imaging in the pre-operative staging and post-operative follow-up of rectal cancer. *Surgeon.* 2008 Aug;6(4):222-31.
19. Benson AB 3rd, Choti MA, Cohen AM, Doroshow JH, Fuchs C, Kiel K, Martin EW Jr, McGinn C, Petrelli NJ, Posey JA, Skibber JM, Venook A, Yeatman TJ; National Comprehensive Cancer Network. NCCN Practice Guidelines for Colorectal Cancer. *Oncology (Williston Park).* 2000 Nov;14(11A):203-12.
20. Kronawitter U, Kemeny NE, Heelan R, Fata F, Fong Y. Evaluation of chest computed tomography in the staging of patients with potentially resectable liver metastases from colorectal carcinoma. *Cancer.* 1999 Jul 15;86(2):229-35.
21. McIntosh J, Sylvester PA, Virjee J, Callaway M, Thomas MG. Pulmonary staging in colorectal cancer--is computerised tomography the answer? *Ann R Coll Surg Engl.* 2005 Sep;87(5):331-3.
22. Jin KN, Lee JM, Kim SH, Shin KS, Lee JY, Han JK, Choi BI. The diagnostic value of multiplanar reconstruction on MDCT colonography for the preoperative staging of colorectal cancer. *Eur Radiol.* 2006 Oct; 16:2284-2291.
23. Chen LB, Tong JL, Song HZ, Zhu H, Wang YC. (18)F-DG PET/CT in detection of recurrence and metastasis of colorectal cancer. *World J Gastroenterol.* 2007 Oct 7;13(37):5025-9.
24. Shin SS, Jeong YY, Min JJ, Kim HR, Chung TW, Kang HK. Preoperative staging of colorectal cancer: CT vs. integrated FDG PET/CT. *Abdom Imaging.* 2008 May-Jun;33(3):270-7.
25. Lardinois D, Weder W, Hany TF, et al. (2003) Staging of nonsmall-cell lung cancer with integrated positron-emission tomography and computed tomography. *N Engl J Med.* 2003 Jun; 348:2500-2507.

Table 1.

Baseline characteristics of patients with colorectal cancer, Maasland Hospital, 1992-2006

		Patients with CXR N=1057	Patients without CXR N= 353	P-Value
Age median (range)		69 (20-94)	69 (25-94)	0.51 ^a
Gender	Male	581	195	0.93 ^b
	Female	476	158	
Location	Colon	662	236	0.15 ^b
	Rectum	395	117	
Differentiation grade	High	140	57	0.72 ^c
	Moderate	738	228	
	Low	146	52	
AJCC classification	0	37	12	0.86 ^c
	1	181	70	
	2	387	116	
	3	287	87	
	4	165	68	
Pulmonary metastases during FU		83	19	0.12 ^c
5-year survival ^d (N%)		686 (61)	216 (65)	0.21 ^a

Percentages are rounded off and may not add up to 100%

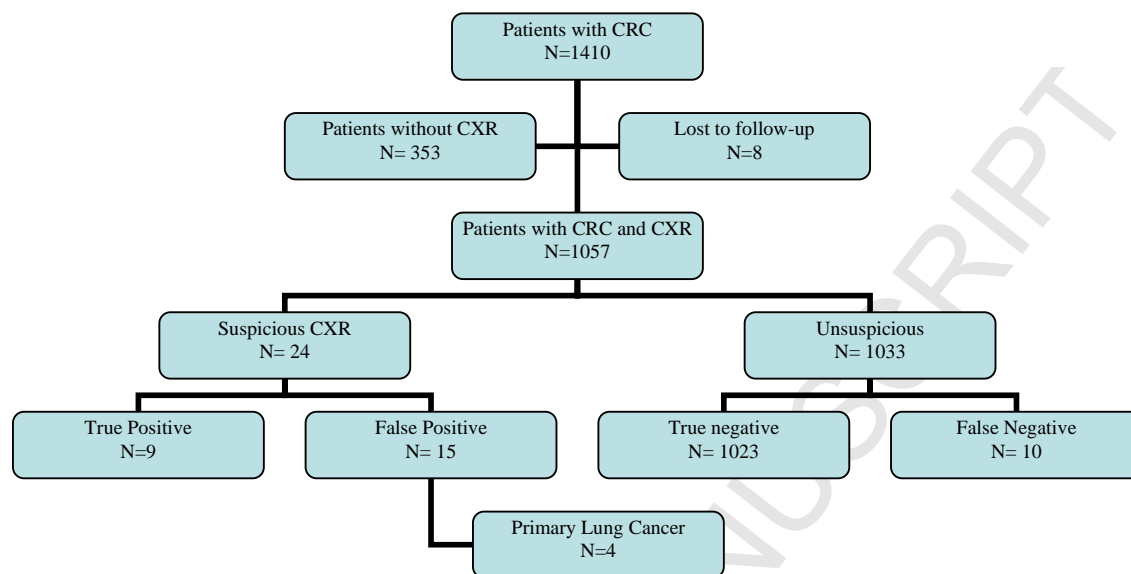
Data are number (percent) unless otherwise indicated, ¹ n=1024; ² n=337

^aIndependent-Samples T test; ^b Chi-Square test; ^c Mann-Whitney U test, ^d

CXR: Chest x-ray; AJCC: American Joint Committee on Cancer classification; FU: Follow-up

Figure 1.

Outcome of chest x-rays



CRC: Colorectal cancer; CXR: Chest x-ray