



**HAL**  
open science

## Pilot study: Rapamycin in advanced hepatocellular carcinoma

Maximilian Schöniger-Hekele, Christian Müller

► **To cite this version:**

Maximilian Schöniger-Hekele, Christian Müller. Pilot study: Rapamycin in advanced hepatocellular carcinoma. *Alimentary Pharmacology and Therapeutics*, 2010, 32 (6), pp.763. 10.1111/j.1365-2036.2010.04404.x . hal-00555326

**HAL Id: hal-00555326**

**<https://hal.science/hal-00555326>**

Submitted on 13 Jan 2011

**HAL** is a multi-disciplinary open access archive for the deposit and dissemination of scientific research documents, whether they are published or not. The documents may come from teaching and research institutions in France or abroad, or from public or private research centers.

L'archive ouverte pluridisciplinaire **HAL**, est destinée au dépôt et à la diffusion de documents scientifiques de niveau recherche, publiés ou non, émanant des établissements d'enseignement et de recherche français ou étrangers, des laboratoires publics ou privés.

**Pilot study: Rapamycin in advanced hepatocellular carcinoma**

Journal:	<i>Alimentary Pharmacology &amp; Therapeutics</i>
Manuscript ID:	APT-0285-2010.R2
Wiley - Manuscript type:	Original Scientific Paper
Date Submitted by the Author:	15-Jun-2010
Complete List of Authors:	Schöniger-Hekele, Maximilian; Medical University of Vienna, Klinik Innere Medizin III, Gastroenterology and Hepatology Müller, Christian; Medical University of Vienna, Klinik Innere Medizin III, Gastroenterology and Hepatology
Keywords:	Hepatocellular carcinoma < Hepatology, Liver < Organ-based, Cancer - chemotherapy < Topics, Oncology - chemotherapy < Topics

**Formatted:** Left: 70.85 pt, Right: 70.85 pt, Top: 70.85 pt, Bottom: 56.7 pt, Width: 595.3 pt, Height: 841.9 pt, Header distance from edge: 35.4 pt, Footer distance from edge: 35.4 pt

**Deleted:** Effects of the mTOR inhibitor rapamycin in patients with hepatocellular carcinoma: a phase IIa trial

1  
2  
3  
4  
5  
6  
7  
8  
9  
10  
11  
12  
13  
14  
15  
16  
17  
18  
19  
20  
21  
22  
23  
24  
25  
26  
27  
28  
29  
30  
31  
32  
33  
34  
35  
36  
37  
38  
39  
40  
41  
42  
43  
44  
45  
46  
47  
48  
49  
50  
51  
52  
53  
54  
55  
56  
57  
58  
59  
60

**Pilot study: Rapamycin in advanced hepatocellular carcinoma**

Maximilian Schöniger-Hekele, Christian Müller

Klinik Innere Medizin III, Abteilung für Gastroenterologie und Hepatologie, Medizinische  
Universität Wien

Key words: Hepatocellular carcinoma (HCC), rapamycin

Correspondence addresses:

Prof. Dr. Christian Müller MD. and  
Prof. Dr. Maximilian Schöniger-Hekele MD.,

Department of Internal Medicine III  
Division of Gastroenterology and Hepatology  
Medical University of Vienna

Währinger Gürtel 18 - 20,  
A-1090 Wien,  
Vienna, Austria

Tel.: +43 (1) 40400-4741  
Fax.: +43 (1) 40400-4735  
e-mail: christian.j.mueller@meduniwien.ac.at  
e-mail: maximilian.schoeniger-hekele@meduniwien.ac.at

**Abstract**

Introduction: The PI3K/Akt/mTOR signal pathway is involved in hepatocarcinogenesis.

Rapamycin (= Sirolimus), a specific mTOR inhibitor, leads to G(1) arrest of many malignant cell lines, and currently analogs of rapamycin are being investigated as a cancer chemotherapeutic adjuvant.

Aim: To study the toxicity and tolerability of rapamycin therapy in patients with advanced hepatocellular carcinoma (HCC).

Methods: Between June 2005 and February 2007 patients with advanced HCC, not eligible for any established therapy, were included in the study.

Results: 18 patients (f/m: 5/13) with compensated liver cirrhosis (Child A n= 11, Child B n= 5, Child C n=2) and histologically proven HCC were included in this study. According to the BCLC staging system most of the patients enrolled had an advanced HCC: BCLC stage B: n=2, BCLC stage C: n=14, BCLC stage D: n=2. Overall, therapy with rapamycin was well tolerated. Most common toxicities were thrombocytopenia and anemia. We did not observe any partial or complete tumor response. At 3 months two patients had stable disease, at 6 months all patients had progressed. The median overall survival was 5.27 months, median time to progression was 3 months. Conclusion: Rapamycin is well tolerated in patients with advanced HCC but only minimally effective.

## Introduction

Hepatocellular carcinoma (HCC) is a tumor of high prevalence worldwide and shows an increasing incidence in the western world. More than 90% of all Hepatocellular carcinoma develop in a cirrhotic liver. Known major risk factors for the development of liver cirrhosis and Hepatocellular carcinoma are chronic hepatitis B or hepatitis C, alcoholic liver cirrhosis or genetic hemochromatosis. The incidence rate of HCC in patients with underlying liver cirrhosis is approximately 3 to 4%[1].

Therapeutic options depend on the stage of underlying liver cirrhosis, on the number and diameter of tumor nodules and the performance status; these factors are combined in the BCLC [2] staging system. Liver transplantation and liver resection are potentially curative treatment options which were offered patients in BCLC stage A (Child-Pugh stage A, 1 nodule <5cm or 3 nodules < 3cm). Also local ablative treatment options (PEI, RFA) are potentially curative treatment options which were used in this group of patients. However, many HCC patients present with a BCLC stage B (Child-Pugh stage A or B, multinodular) or BCLC stage C (Child-Pugh stage A or B, multinodular, portal invasion, N1, M1; without potential curative treatment options). Transarterial chemoembolisation (TACE) for BCLC stage B or treatment with the vascular endothelial growth factor inhibitor Sorafenib for BCLC stage C are offered to these groups of patients and have been shown to prolong survival [3 4 5 6 7 8]. Sorafenib, a multikinase inhibitor, represents a breakthrough in the management of advanced hepatocellular carcinoma and shows a significantly better survival compared to placebo. Nevertheless, there is need for new therapeutic agents for those patients

1  
2 A recently discussed new treatment option is Rapamycin (= Sirolimus), a specific mTOR  
3  
4 inhibitor („mammalian target of rapamycin“). Rapamycin is inhibiting the PI3K/Akt/mTOR  
5  
6 signal pathway which is involved in multiple cellular functions including proliferation,  
7  
8 differentiation, tumorigenesis, and apoptosis. Rapamycin, the naturally occurring inhibitor of  
9  
10 mTOR and a number of recently developed rapamycin analogues inhibit the growth of cell  
11  
12 lines derived from multiple tumor types in vitro, and tumor models in vivo., This specific  
13  
14 mTOR inhibitor could lead to G(1) arrest of many malignant cell lines, and currently analogs  
15  
16 of rapamycin are being investigated as a cancer chemotherapeutic adjuvant [9 10 11].  
17  
18 Rapamycin, isolated from *Streptomyces hygroscopicus*, is a Macrolid-antibiotic with  
19  
20 antibacteriel, antifungal and immunosuppressive effects [12 13 14] and can inhibit mTOR  
21  
22 through association with its intracellular receptor FKBP12. The FKBP12-rapamycin complex  
23  
24 binds directly to the FKBP12-Rapamycin Binding (FRB) domain of mTOR. The inhibition of  
25  
26 mTOR by Rapamycin causes a dephosphorylation and inactivation of some ribosomal  
27  
28 proteins and leads to a reduction of synthesis of components of the translation process  
29  
30 [15 16]. This is followed by an arrest of the G1-phase of cell cycle which causes  
31  
32 immunosuppression but also antitumoral effects.  
33  
34  
35 Proteins regulating the mammalian target of rapamycin (mTOR) are overexpressed or  
36  
37 mutated in cancer. Results from clinical trials indicate that rapamycin and its analogues may  
38  
39 be useful for the treatment of subsets of certain types of cancer [17 18]. Therefore, in this  
40  
41 pilot study we studied the toxicity and tolerability of rapamycin in patients with liver  
42  
43 cirrhosis and hepatocellular carcinoma.  
44  
45  
46  
47  
48  
49  
50  
51  
52  
53  
54  
55  
56  
57  
58  
59  
60

## METHODS

### PATIENTS

A total of 18 patients were included into the study between June 2005 and February 2007.

All patients were recruited at the Department of Gastroenterology and Hepatology at the Medical University of Vienna. Most of our patients were in Child B, only two were in Child C stage. Liver cirrhosis and its complications were managed according to state of the art protocols. The demographic data and baseline clinical characteristics are given in Table 1.

Liver cirrhosis was diagnosed either by histology or by the typical combination of laboratory tests, clinical and gastroscopic findings and typical signs of liver cirrhosis in CT or ultrasound.

Diagnosis of hepatocellular carcinoma was done according to the criteria of EASL [19] and AASLD [20].

Patients with histologically confirmed HCC were eligible if they were 19-85 years of age and were no candidates for liver transplantation, tumor resection, a local ablative therapy (kryotherapy, ethanol instillation, radio frequency ablation) or chemoembolization (TACE).

One patient was switched due to progression of the HCC from TACE to Rapamycin. To be eligible for the study the estimated life expectancy had to be more than 3 months. Tumors had to be measurable objectively with CT-scan.

### DEFINITION OF TUMOR PROGRESSION

1  
2 Tumor progression was judged during the study by comparing tumor diameters during  
3  
4 follow up examinations against the measurements obtained at baseline. We used the RECIST  
5  
6 [21 22] and EASL [19] response criteria for evaluation of progression free survival  
7  
8  
9

Formatted: Endnote Reference,  
Font: 12 pt, Complex Script Font: 12  
pt, English U.S.

Deleted: 19

#### 10 FOLLOW UP

11  
12 Routine multislice CT and ultrasound were performed every three months until death of the  
13  
14 patient. Physical examination, serum chemistry, blood cell counts and AFP determinations  
15  
16 and Rapamycin plasma levels were done monthly.  
17  
18

#### 19 TREATMENT MODALITIES

20  
21 Rapamycin was administered orally twice daily. The target plasma level was 4 to 8 ng/ml.  
22  
23  
24 The planned duration of the study was 6 months. Toxicity assessments were based on  
25  
26 reports of adverse events and results of scheduled physical examinations, vital sign  
27  
28 measurements and clinical laboratory tests.  
29  
30  
31

#### 32 STATISTICAL ANALYSIS

33  
34  
35 Chi<sup>2</sup> test was used to compare proportions and Mann Whitney U tests to compare median  
36  
37 values between groups. Survival times and progression free survival were estimated using  
38  
39 the Kaplan-Meier method and the differences were tested with the log-rank test. Analysis  
40  
41 was performed with Statistica (StatSoft, Inc. (2004). STATISTICA (data analysis software  
42  
43 system), version 6. [www.statsoft.com](http://www.statsoft.com)).  
44  
45  
46  
47  
48  
49  
50  
51  
52



## Results

### *PATIENT CHARACTERISTICS*

18 patients (female: 5, male: 13) with compensated liver cirrhosis (Child A n= 11, Child B n= 5, Child C n=2) and histologically proven HCC (G1 n=1, G2 n=14, G3 n=3) were included in this study. (Table 1)

According to the BCLC staging system most of the patients enrolled had advanced hepatocellular carcinoma: BCLC stage B: n=2, BCLC stage C: n=14, BCLC stage D: n=2.

### *TREATMENT TOXICITY AND TOLERABILITY*

Overall, therapy with rapamycin was well tolerated. We did not observe severe infectious complications. Only 2 spontaneous bacterial peritonitis (SBP) were seen in the 18 patients. Most common laboratory abnormalities were thrombocytopenia and anemia, most often already present at baseline. Neither dose reduction nor termination of treatment was necessary due to severe toxicity.

### *TUMOR RESPONSE*

We did not observe any partial or complete tumor response. At 3 months two patients had stable disease, at 6 months all patients had progressed.

### *TIME TO PROGRESSION*

The median time to progression was 3.0 months. (Figure 2) The shortest time to progression was 1.2 months, the longest time to progression was 6.7 months.

*SURVIVAL*

The median overall survival was 5.27 months. 6 patients died before the first assessment of tumor progression at 3 months, 5 further patients between the first CT assessment at 3 months and the end of the study at 6 months. 7 patients lived longer than 6 months. However, 3 of those died within one month after end of the study due to progression of disease. The remaining 4 patients, all having progressive disease, were switched to other treatments (3 patients to Sandostatin LAR, 1 patient to Sorafenib). They lived for 12, 16, 19 and 28 months respectively.

## Discussion

In this pilot study 18 patients with compensated liver cirrhosis and histologically proven advanced HCC were treated with Rapamycin, a specific mTOR inhibitor. At 3 months two patients had stable disease, at 6 months all patients had progressed. Our results showed that Rapamycin was well tolerated but was only minimally effective in patients with liver cirrhosis and advanced stage hepatocellular carcinoma.

Although all our patients had liver cirrhosis treatment with Rapamycin resulted in few side effects. No dose reduction due to intolerable side effects was necessary even in patients with Child B liver cirrhosis. We observed only two cases of SBP which were successfully treated with antibiotics despite continuous treatment with Rapamycin. No clear connection to Rapamycin treatment was evident in those patients. In general, in patients with liver cirrhosis and advanced HCC Rapamycin was well tolerated.

We treated our patients between 2005 and 2007 before Sorafenib was registered for treatment of HCC. At present Sorafenib is recommended in patients with advanced HCC and any new treatment should be evaluated against that standard. Sorafenib, a drug which has been proven to prolong survival of patients with advanced HCC in the SHARP trial [6], did not induce complete response in a single patient and only 2% of all patients had a partial response. We saw a similar picture: although we did not observe any partial or complete tumor response at 3 months two patients had stable disease. In the SHARP trial the median time to radiologic progression was only 5.5 months in the sorafenib group. Similarly, under

**Formatted:** Endnote Reference,  
Font: 12 pt, Complex Script Font: 12  
pt, English U.S.

**Deleted:** 6

1  
2 Rapamycin treatment all patients had progressed at 6.7 months, the median time to  
3  
4 progression was 3.0 months. In general, the limited tumor response and the progression of  
5  
6 tumor size do not indicate ineffectiveness of the treatment with Rapamycin, there is  
7  
8 considerable discussion whether the EASL and RECIST criteria used to document tumor  
9  
10 progression are the best tools to judge the effectiveness of an anti-tumor drug. Focusing on  
11  
12 objective tumor shrinkage does not take into account the possibility of other potential  
13  
14 beneficial effects of a drug on survival. Median overall survival time was 10.7 months in the  
15  
16 sorafenib group in the SHARP trial but only 5.27 months in our patients treated with  
17  
18 Rapamycin. Our one year survival rate was 22%. The expected one year survival rate of  
19  
20 patients with BCLC stage C without therapy according to BCLC staging classification would  
21  
22 have been 29% [2] which is not different from our patients actively treated with Rapamycin.

**Formatted:** Endnote Reference,  
Font: 12 pt, Complex Script Font: 12  
pt, English U.S.

**Deleted:** 2

23  
24 However, 97% of the patients with advanced hepatocellular carcinoma included in the  
25  
26 SHARP trial were rated as Child stage A at baseline, reflecting a well-preserved liver function.  
27  
28 On the other hand 38.9% of our patients treated with Rapamycin were classified as Child  
29  
30 stages B or C. Therefore patients included in our trial had worse baseline characteristics and  
31  
32 were not directly comparable to the patients included in the SHARP trial. Therefore the  
33  
34 effectiveness of Rapamycin can only be evaluated in comparison to a placebo group. New,  
35  
36 randomized controlled studies are needed to investigate the effectiveness of Rapamycin or  
37  
38 other mTOR inhibitors in patients with hepatocellular carcinoma.  
39  
40  
41

42  
43 Rapamycin provokes antineoplastic and immunosuppressive effects. Organ transplant  
44  
45 recipients treated with mTOR inhibitors have a reduced incidence of de novo posttransplant  
46  
47 malignancies. Therefore, the use of Rapamycin in recipients with a high cancer risk like older  
48  
49 patients, recipients with a personal history of cancer or high familial cancer risk, could be  
50  
51 claimed. Immunosuppressive therapy after liver transplantation might contribute to

1  
2 recurrence and metastasis of hepatocellular carcinoma. mTOR inhibitors as  
3  
4 immunosuppressive agents are an excellent treatment alternative in that situation with data  
5  
6 showing an excellent survival and disease free intervals in those patients [23 24 25]. A  
7  
8 recently published study based on the Scientific Registry of Transplant Recipients (SRTR)  
9  
10 including 2,491 adult recipients of isolated liver transplantation for HCC and 12,167 for non-  
11  
12 HCC diagnoses revealed that sirolimus based immunosuppression compared to calcineurin  
13  
14 inhibitors has unique posttransplant effects on patients with HCC that lead to improved  
15  
16 survival<sup>26</sup>.  
17

18  
19  
20  
21  
22 The primary usage of mTOR inhibitors as an anti tumor agent in patients with a malignancy  
23  
24 but without organ transplantation is controversially discussed [27]. However, recent studies  
25  
26 show that the mTOR pathway has an important role in the pathogenesis of HCC. Villanueva  
27  
28 et al. demonstrated that an aberrant mTOR signaling was present in half of the cases [17].

Formatted: Endnote Reference,  
English U.S.

Deleted: 17

29  
30 The authors showed that the blockage of mTOR signaling with Rapamycin in vitro and in  
31  
32 xenograft models decelerated tumor growth and increased survival. These findings are the  
33  
34 rationale for targeting the mTOR pathway in clinical trials in patients with HCC.  
35

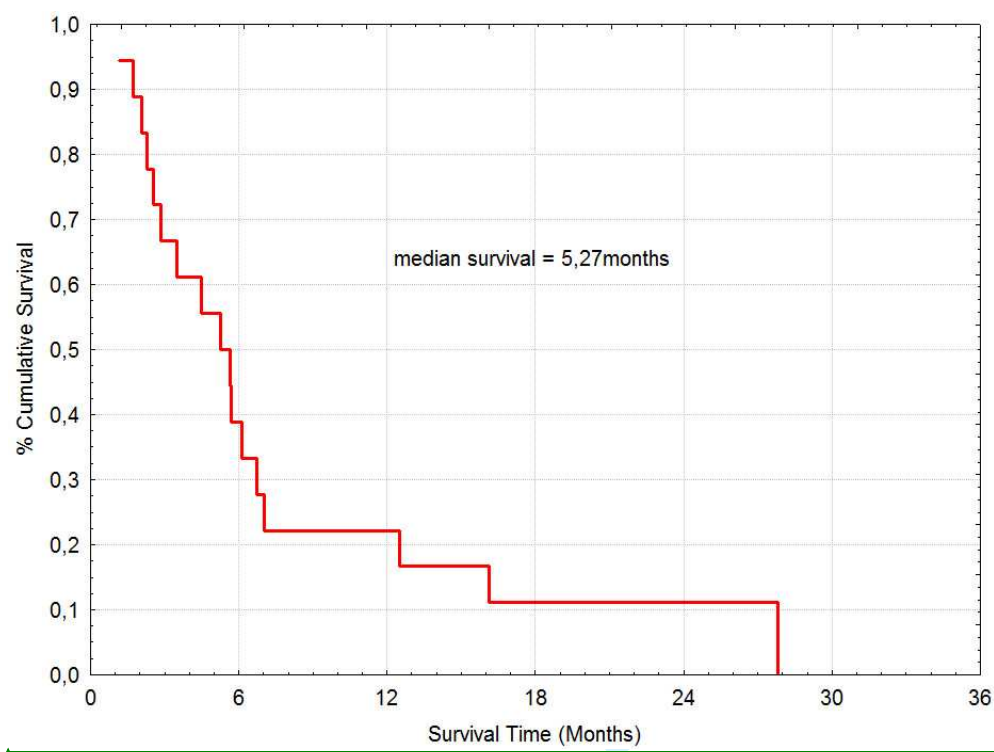
36  
37 In summary, Rapamycin is well tolerated in patients with advanced hepatocellular carcinoma  
38  
39 but only minimally effective.  
40  
41  
42  
43  
44  
45

#### 46 STATEMENT OF INTERESTS:

47  
48 No financial support was received for this study.  
49  
50  
51  
52

1  
2  
3  
4  
5  
6  
7  
8  
9  
10  
11  
12  
13  
14  
15  
16  
17  
18  
19  
20  
21  
22  
23  
24  
25  
26  
27  
28  
29  
30  
31  
32  
33  
34  
35  
36  
37  
38  
39  
40  
41  
42  
43  
44  
45  
46  
47  
48  
49  
50  
51  
52  
53  
54  
55  
56  
57  
58  
59  
60

Figure 1

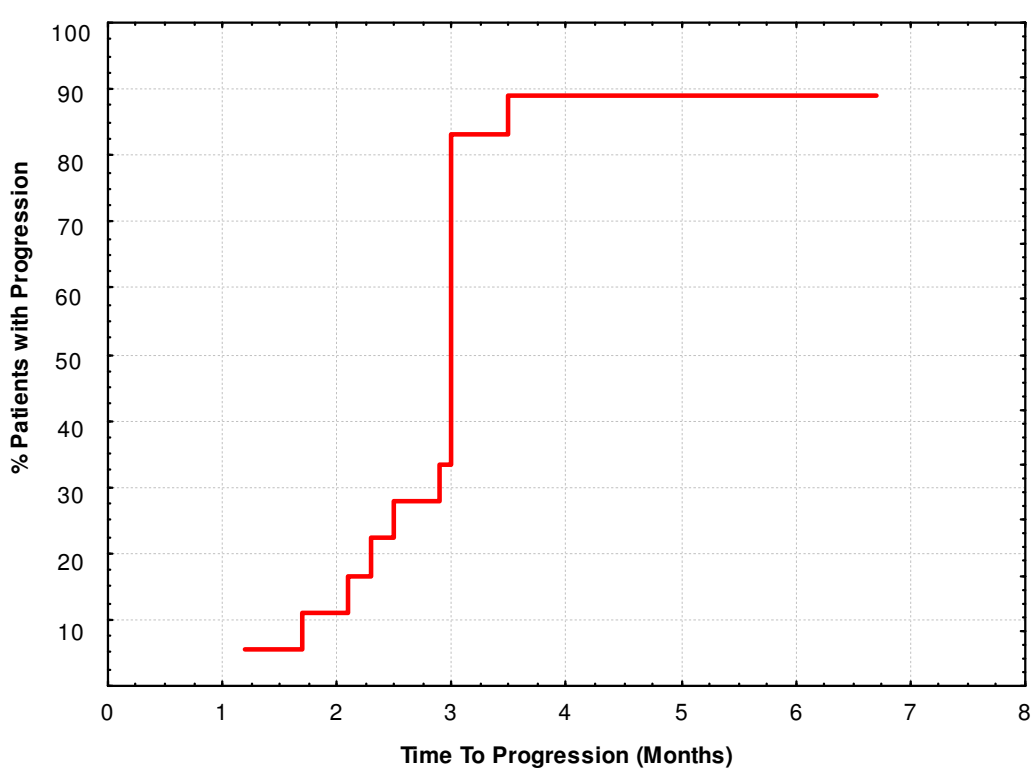


Formatted: English U.S., Do not check spelling or grammar

Review

1  
2  
3  
4  
5  
6  
7  
8  
9  
10  
11  
12  
13  
14  
15  
16  
17  
18  
19  
20  
21  
22  
23  
24  
25  
26  
27  
28  
29  
30  
31  
32  
33  
34  
35  
36  
37  
38  
39  
40  
41  
42  
43  
44  
45  
46  
47  
48  
49  
50  
51  
52  
53  
54  
55  
56  
57  
58  
59  
60

Figure 2



er Review

**Table 1, Patient characteristics, baseline parameters**

	overall
	<i>number (percentage)</i>
Number	18
Sex	
male	13 (72.2%)
female	5 (27.8%)
Median age (range)	64.2 (46.5 - 80.9)
Liver cirrhosis	
Child A	11 (61.1%)
Child B	5 (27.8%)
Child C	2 (11.1%)
BCLC	
Stage A	0
Stage B	2
Stage C	14
Stage D	2
Etiology	
alcohol	9 (50.0%)
HCV-antibodies pos.	5 (27.8%)
cryptogen	1 (5.5%)
HBsAg positive	3 (16.7%)
	<i>median (min-max)</i>
Creatinin	0.93 (0.69-2.21)
BUN	14.0 (6.0-69.0)
Bilirubin	1.3 (0.67-4.53)
Protein	73.5 (60.7-92.9)
Albumin	35.2 (24.1-52.7)
Cholinesterase	3.33 (1.00-7.29)
AP	186.5 (109.0-1018.0)
AST	81 (41-453)
ALT	64 (25-192)
GGT	234 (61-818)
CRP	1.26 (0.11-10.78)
AFP	163.4 (2.70-50,000.00)
CA 19-9	89 (1-638)
Erythrocytes	4.0 (3.1-5.2)
Haemoglobin	12.95 (10.4-16.1)
Haematocrit	38.5 (30.6-47.5)
Thrombocytes	135 (52-511)
Leucocytes	7.15 (3.74-10.69)
MCV	92.95 (76.70-105.00)
PT	74 (33-131)



**Table 2, Adverse events/symptoms**

<i>Adverse event</i>	<i>Number (percentage)</i>
Anaemia	5 (27.8%)
Thrombocytopenia	9 (50.0%)
Hypokalemia	0
urinary tract infection	0
Other infections (SBP)	2
Hyperlipidemia	0
Diarrhoea	3 (17%)
Edema	9 (50%)

For Peer Review

1  
2  
3  
4  
5  
6  
7 | <sup>1</sup> El-Serag HB, Rudolph KL. Hepatocellular carcinoma: epidemiology and molecular  
8  
9 | carcinogenesis. *Gastroenterology*. 2007; 132(7):2557-76. Review.

10  
11  
12  
13 | <sup>2</sup> Llovet J.M., Bru C., Bruix J. Prognosis of hepatocellular carcinoma: the BCLC staging  
14  
15 | classification. *Semin.Liver Dis*. 1999; 19: 329-338.

16  
17  
18  
19 | <sup>3</sup> Giannini EG, Bodini G, Corbo M, Savarino V, Risso D, Di Nolfo MA, Del Poggio P, Benvegnù L,  
20  
21 | Farinati F, Zoli M, Borzio F, Caturelli E, Chiaramonte M, Trevisani F; ITALIAN LIVER CANCER  
22  
23 | (ITA.LI.CA.) GROUP. Impact of evidence-based medicine on the treatment of patients with  
24  
25 | unresectable hepatocellular carcinoma. *Aliment Pharmacol Ther*. 2010 Feb 15;31(4):493-  
26  
27 | 501. Epub 2009 Nov 14.

28  
29  
30  
31 | <sup>4</sup> Cammà C, Schepis F, Orlando A, Albanese M, Shahied L, Trevisani F, Andreone P, Craxì A,  
32  
33 | Cottone M. Transarterial chemoembolization for unresectable hepatocellular carcinoma:  
34  
35 | meta-analysis of randomized controlled trials. *Radiology*. 2002 Jul;224(1):47-54. Review.

36  
37  
38  
39 | <sup>5</sup> Myers RP. Meta-analysis of transarterial embolization in patients with unresectable  
40  
41 | hepatocellular carcinoma. *Radiology*. 2003 May;227(2):611-2; author reply 612-3.

42  
43  
44  
45 | <sup>6</sup> Llovet JM, Ricci S, Mazzaferro V, Hilgard P, Gane E, Blanc JF, de Oliveira AC, Santoro A,  
46  
47 | Raoul JL, Forner A, Schwartz M, Porta C, Zeuzem S, Bolondi L, Greten TF, Galle PR, Seitz JF,  
48  
49 | Borbath I, Häussinger D, Giannaris T, Shan M, Moscovici M, Voliotis D, Bruix J; SHARP

50  
51  
52  
53  
54  
55  
56  
57  
58  
59  
60

1  
2  
3 Investigators Study Group. Sorafenib in advanced hepatocellular carcinoma. N Engl J Med.  
4  
5 2008 24;359(4):378-90.  
6  
7

8  
9 | <sup>7</sup> Chaparro M, González Moreno L, Trapero-Marugán M, Medina J, Moreno-Otero R. Review  
10 | article: pharmacological therapy for hepatocellular carcinoma with sorafenib and other oral  
11 | agents. Aliment Pharmacol Ther. 2008 Dec 1;28(11-12):1269-77. Epub 2008 Sep 20. Review  
12 |  
13 |  
14 |  
15 |

16  
17  
18 | <sup>8</sup> Cabrera R, Nelson DR. Review article: the management of hepatocellular carcinoma.  
19 | Aliment Pharmacol Ther. 2010 Feb 15;31(4):461-76. Epub 2009 Nov 19  
20 |  
21 |  
22 |

23  
24 | <sup>9</sup> Sehgal S.N., Molnar-Kimber K., Ocain T.D et al. Rapamycin: a novel immunosuppressive  
25 | macrolide. Med.Res.Rev. 1994; 14: 1-22.  
26 |  
27 |  
28 |

29  
30 | <sup>10</sup> Huang S., Houghton P.J. Inhibitors of mammalian target of rapamycin as novel antitumor  
31 | agents: from bench to clinic. Curr. Opin.Invest.Drugs 2002; 3: 295-304.  
32 |  
33 |

34  
35 | <sup>11</sup> Huang S. Houghton P.J. Resistance to rapamycine: a novel anti-cancer drug. Cancer  
36 | Metastasis Rev. 2001; 20: 69-78.  
37 |  
38 |

39  
40 | <sup>12</sup> Morelon E., Kreis H. Sirolimus therapy without calcineurin inhibitors: Necker Hospital 5-  
41 | year experience. Transplant Proc. 2003; 35: 52S- 57S.  
42 |  
43 |  
44 |  
45 |  
46 |  
47 |  
48 |  
49 |  
50 |  
51 |  
52 |

1  
2  
3 | <sup>13</sup> Radovancevic B., Vrtovec B. Sirolimus therapy in cardiac transplantation. *Transplant Proc.*  
4 |  
5 | 2003; 35: 171S - 176S.  
6 |

7  
8  
9 | <sup>14</sup> Trotter J.F. Sirolimus in liver transplantation. *Transplant Proc.* 2003; 35: 193S – 200S.  
10 |

11  
12  
13 | <sup>15</sup> Jefferies H.B., Fumagalli S., Dennis B.P., Reinhard C., Pearson R.B., Thomas G. Rapamycin  
14 |  
15 | suppresses 5'TOP mRNA translation through inhibition of p70s6k *EMBO J.* 1997; 16: 3693-  
16 |  
17 | 3704.  
18 |

19  
20  
21 | <sup>16</sup> Terada n., Patel H.R., Takase K., Kohno K., Nairn A.C., Gelfand E.W. Rapamycin selectively  
22 |  
23 | inhibits translation of mRNAs encoding elongation factors and ribosomal proteins.  
24 |  
25 | *Proc.Natl.Acad.Sci.USA* 1994; 91: 11477-11481.  
26 |

27  
28  
29  
30 | <sup>17</sup> Villanueva A, Chiang DY, Newell P, Peix J, Thung S, Alsinet C, Tovar V, Roayaie S, Minguez  
31 |  
32 | B, Sole M, Battiston C, Van Laarhoven S, Fiel MI, Di Feo A, Hoshida Y, Yea S, Toffanin S,  
33 |  
34 | Ramos A, Martignetti JA, Mazzaferro V, Bruix J, Waxman S, Schwartz M, Meyerson M,  
35 |  
36 | Friedman SL, Llovet JM. Pivotal role of mTOR signaling in hepatocellular carcinoma.  
37 |  
38 | *Gastroenterology.* 2008 Dec; 135(6):1972-83, 1983.e1-11. Epub 2008 Aug 20.

39 | <sup>18</sup> Newell P, Toffanin S, Villanueva A, Chiang DY, Minguez B, Cabellos L, Savic R, Hoshida Y,  
40 |  
41 | Lim KH, Melgar-Lesmes P, Yea S, Peix J, Deniz K, Fiel MI, Thung S, Alsinet C, Tovar V,  
42 |  
43 | Mazzaferro V, Bruix J, Roayaie S, Schwartz M, Friedman SL, Llovet JM. Ras pathway activation  
44 |  
45 | in hepatocellular carcinoma and anti-tumoral effect of combined sorafenib and rapamycin in  
46 |  
47 | vivo. *J Hepatol.* 2009 Oct;51(4):725-33. Epub 2009 Jun 12  
48 |  
49 |  
50 |  
51 |  
52 |

1  
2  
3 | <sup>19</sup> Bruix J, Sherman M, Llovet JM, Beaugrand M, Lencioni R, Burroughs AK, Christensen E,  
4 |  
5 | Pagliaro L, Colombo M, Rodés J; EASL Panel of Experts on HCC. Clinical management of  
6 |  
7 | hepatocellular carcinoma. Conclusions of the Barcelona-2000 EASL conference. European  
8 |  
9 | Association for the Study of the Liver. J Hepatol. 2001 Sep;35(3):421-30  
10 |

11  
12  
13 | <sup>20</sup> Bruix J, Sherman M; Practice Guidelines Committee, American Association for the Study of  
14 |  
15 | Liver Diseases. Management of hepatocellular carcinoma. Hepatology. 2005 Nov;42(5):1208-  
16 |  
17 | 36  
18 |

19  
20  
21 | <sup>21</sup> Therasse P, Arbuck SG, Eisenhauer EA, Wanders J, Kaplan RS, Rubinstein L et al. (2000)  
22 |  
23 | New guidelines to evaluate the response to treatment in solid tumors. European  
24 |  
25 | Organization for Research and Treatment of Cancer, National Cancer Institute of the United  
26 |  
27 | States, National Cancer Institute of Canada. J Natl Cancer Inst 92: 205-216.  
28 |

29  
30  
31  
32  
33 | <sup>22</sup> Llovet JM, Di Bisceglie AM, Bruix J, Kramer BS, Lencioni R, Zhu AX, Sherman M, Schwartz  
34 |  
35 | M, Lotze M, Talwalkar J, Gores GJ; Panel of Experts in HCC-Design Clinical Trials. Design and  
36 |  
37 | endpoints of clinical trials in hepatocellular carcinoma. J Natl Cancer Inst. 2008 May  
38 |  
39 | 21;100(10):698-711. Epub 2008 May 13. Review  
40 |

41  
42  
43 | <sup>23</sup> Kneteman NM, Oberholzer J, Al Saghier M, Meeberg GA, Blitz M, Ma MM, Wong WW,  
44 |  
45 | Gutfreund K, Mason AL, Jewell LD, Shapiro AM, Bain VG, Bigam DL. Sirolimus-based  
46 |  
47 | immunosuppression for liver transplantation in the presence of extended criteria for  
48 |  
49 | hepatocellular carcinoma. Liver Transpl. 2004 Oct;10(10):1301-11.  
50 |

1  
2  
3  
4  
5 | <sup>24</sup> Zhou J, Fan J, Wang Z, Wu ZQ, Qiu SJ, Huang XW, Yu Y, Sun J, Xiao YS, He YF, Wang YQ,  
6 |  
7 | Tang ZY. Conversion to sirolimus immunosuppression in liver transplantation recipients with  
8 |  
9 | hepatocellular carcinoma: Report of an initial experience. World J Gastroenterol. 2006 May  
10 |  
11 | 21;12(19):3114-8.  
12 |

13  
14  
15 | <sup>25</sup> Elsharkawi M, Staib L, Henne-Bruns D, Mayer J. Complete remission of postransplant lung  
16 |  
17 | metastases from hepatocellular carcinoma under therapy with sirolimus and mycophenolate  
18 |  
19 | mofetil. Transplantation. 2005 Apr 15;79(7):855-7.  
20 |

21  
22  
23 | <sup>26</sup> Toso C, Merani S, Bigam DL, Shapiro AM, Kneteman NM. Sirolimus-based  
24 |  
25 | immunosuppression is associated with increased survival after liver transplantation for  
26 |  
27 | hepatocellular carcinoma. Hepatology. 2010 Apr;51(4):1237-43  
28 |

29  
30  
31  
32 | <sup>27</sup> Andrassy J, Graeb C, Rentsch M, Jauch KW, Guba M. mTOR inhibition and its effect on  
33 |  
34 | cancer in transplantation. Transplantation. 2005 Sep 27;80(1 Suppl):S171-4. Review.  
35 |