



HAL
open science

Presence of Foxp3 expression in tumor cells predicts better survival in HER2-overexpressing breast cancer patients treated with neoadjuvant chemotherapy

Sylvain Ladoire, Laurent Arnould, Grégoire Mignot, Bruno Coudert, Cédric Rébé, Fanny Chalmin, Julie Vincent, Mélanie Bruchard, Bruno Chauffert, François Martin, et al.

► To cite this version:

Sylvain Ladoire, Laurent Arnould, Grégoire Mignot, Bruno Coudert, Cédric Rébé, et al.. Presence of Foxp3 expression in tumor cells predicts better survival in HER2-overexpressing breast cancer patients treated with neoadjuvant chemotherapy. *Breast Cancer Research and Treatment*, 2010, 125 (1), pp.65-72. 10.1007/s10549-010-0831-1 . hal-00554998

HAL Id: hal-00554998

<https://hal.science/hal-00554998>

Submitted on 12 Jan 2011

HAL is a multi-disciplinary open access archive for the deposit and dissemination of scientific research documents, whether they are published or not. The documents may come from teaching and research institutions in France or abroad, or from public or private research centers.

L'archive ouverte pluridisciplinaire **HAL**, est destinée au dépôt et à la diffusion de documents scientifiques de niveau recherche, publiés ou non, émanant des établissements d'enseignement et de recherche français ou étrangers, des laboratoires publics ou privés.

Presence of Foxp3 Expression in Tumor Cells Predicts Better Survival in HER2-Overexpressing Breast Cancer Patients treated with Neoadjuvant Chemotherapy

Sylvain Ladoire^{1,2,3}, Laurent Arnould³, Grégoire Mignot², Bruno Coudert¹, Cédric Rébé^{2,3}, Fanny Chalmin², Julie Vincent², Mélanie Bruchard², Bruno Chauffert^{1,2}, François Martin², Pierre Fumoleau¹, François Ghiringhelli^{1,2,3}.

1. Department of Medical Oncology, Centre Regional de Lutte Contre le Cancer Georges François Leclerc, Dijon, France.
2. Institut National de la Santé et de la Recherche Médicale. Avenir Team INSERM. CRI-866 University of Dijon, France.
3. Department of Pathology and Molecular Biology, Centre Regional de Lutte Contre le Cancer Georges François Leclerc, Dijon, France.

Key words: Foxp3, HER2, Breast cancer, Tumor cells, Neoadjuvant Chemotherapy.

Corresponding author, Requests for reprints: Francois Ghiringhelli. Centre Georges François Leclerc, Centre de Recherche INSERM 866. Faculté de Médecine, 7 Boulevard Jeanne d'Arc 21000 DIJON. Phone : 33-3-80-39-33-53 ; Fax : 33-3-80-39-34-34. Email : fgiringhelli@dijon.fnclcc.fr

Abstract

Purpose: The Forkhead Box Protein 3 is highly expressed in regulatory T cells, but also in tumor cells, acting as a transcriptional repressor of breast oncogenes including *HER2*. We investigated the prognostic significance of Foxp3 expression in cancer cells in a large cohort of patients with HER2-overexpressing breast carcinoma treated with neoadjuvant chemotherapy.

Methods: Foxp3-positive tumor cells were detected by immunohistochemistry in 103 patients with primary invasive HER2-overexpressing breast carcinoma, and treated with neoadjuvant chemotherapy, with or without trastuzumab. Kaplan-Meier analysis and Cox regression model were used to assess relapse-free and overall survival, according to the presence or absence of Foxp3 expression in tumor cells.

Results: Breast cancer cells were Foxp3+ in 57% of tumors. Foxp3 expression in breast cancer cells was associated with better relapse-free ($P = 0.005$), and overall survival ($P = 0.03$). By multivariate analysis, presence of Foxp3+ tumor cells resulted an independent prognostic factor both for better relapse-free ($P = 0.006$), and overall survival ($P = 0.03$).

Conclusions: These findings indicate that the presence of Foxp3+ tumor cells represents a new independent prognostic factor of improved outcome in HER2-overexpressing breast carcinoma, which could help to select high risk patients for additional therapies after neoadjuvant chemotherapy.

Introduction

Forkhead Box Protein 3 (Foxp3) is a transcription factor involved in regulating immune system development [1, 2], notably in the generation of immunosuppressive regulatory T cells (Treg). These cells play a central role in preventing autoimmunity and pathologies inflicted by uncontrolled immune responses after infection [3]. Moreover, there is increasing evidence that Treg also play an important role in immune evasion mechanisms promoted by cancers, enabling tumor cells to elude the host antitumor immune response [4-9]. Initially, Foxp3 expression was thought to be restricted to hematopoietic tissues. However, although data are scant, Foxp3 expression by other tissues has also been observed, including in human tumor cells [10]. Importantly, biological functions of Foxp3 in tumor cells, and its significance, presently remain unclear. Recent data suggest that Foxp3 expression in tumor cells could be a poor prognostic factor in breast cancer [11], but in contrast with these data, Foxp3 was also recently demonstrated to be a tumor suppressor gene, acting as a transcriptional repressor of *SKP2* and *HER2*, two breast cancer oncogenes [12, 13]. These two biological studies suggested that HER2-overexpressing breast cancer subtype may be differently driven by Foxp3. This led us to hypothesize that Foxp3 expression may have antitumor functions in HER2-overexpressing molecular subtype of breast cancer, and therefore a different prognostic significance.

The present study examined the prognostic relevance of tumor cell Foxp3 expression in archival material of a cohort of 103 consecutive patients treated with neoadjuvant chemotherapy for HER2-overexpressing breast cancer.

Importantly, this study revealed that, in this molecular subtype, presence of Foxp3 expression in tumor cells independently predicts a better survival after neoadjuvant chemotherapy.

Patients and methods

Patients and tissue sampling: Our series included 103 consecutive patients treated with neoadjuvant chemotherapy in our institution (Centre Regional de Lutte Contre le Cancer de Dijon, Dijon, France) between 1976 and 2007 for localized breast carcinoma overexpressing HER2. All patients underwent neoadjuvant chemotherapy followed by definitive surgery and radiotherapy. This retrospective study was approved by our institutional review board and all data were anonymized. Written informed consent was obtained from all patients. All patients were diagnosed with invasive breast carcinoma by core needle biopsy and a sample was collected in association with anonymized clinical data.

Histologic type was defined according to the WHO classification. Histologic grading was carried out using the Nottingham-combined histologic grade (Elston–Ellis modification of Scarff–Bloom–Richardson (SBR) grading system) [14]. The steroid hormone receptor estrogen, and progesterone receptor status was determined using enzyme-immunoassays (Abbott Diagnostics, Abbott Park, Illinois, USA), or by immunohistochemistry (ER, clone SP1, PR clone 1E2, Ventana, Tucson USA). The Herceptest scoring method was used for the determination of HER2 status, considering only a score of 3+, or 2+ with FISH amplification, as determining HER2 overexpressing tumors (clone 4B5, Ventana, Tucson USA).

Chemotherapy was performed using an anthracycline-based regimen (without trastuzumab) in 48 patients treated before 2001: FEC 100, (5-fluorouracil 500 mg/m², epirubicin 100 mg/m², cyclophosphamide 500 mg/m²), or ACVFM (adriamycin 50 mg/m², cyclophosphamide 400 mg/m², vincristine 0.6 mg/m², methotrexate 20 mg/m², 5-fluorouracil 600 mg/m²). Patients treated after 2001 received trastuzumab (6 mg/kg) associated with chemotherapy by docetaxel 100 mg/m² or by docetaxel 75 mg/m² + carboplatin AUC 6. Surgery was performed 3-4 weeks after the last cycle of chemotherapy. Histological response was determined on surgical specimens according to the Chevallier classification [15]. Breast tissue without residual malignant epithelial invasive tumor, and associated with no microscopic evidence of tumor cell in axillary specimens, was considered as pathological complete response (pCR).

Foxp3 Immunohistochemical staining: Foxp3 expression was analyzed immunohistochemically on formalin-fixed, paraffin-embedded tumor sections using Antihuman Foxp3 monoclonal antibody clone ab20034 (Abcam, Cambridge, United Kingdom) at 1/100 dilution, and the iVIEW system (Ventana, Tucson USA). Labeling was detected using the Ventana Benchmark XT automat (Ventana, Tucson USA). The stained arrays were counterstained with hematoxylin and mounted in Aquamount (Dako, Glostrup, Denmark). Positive and negative staining controls were carried out with paraffin tonsil sections using Foxp3 monoclonal antibody and an isotype-matched negative control antibody. Presence or absence of Foxp3-positive (Foxp3+) tumor cells, and quantification of Foxp3+ regulatory T cells (Treg) were evaluated independently by two of the authors (S.L and F.G), both blinded to clinical data. Discrepancies between the 2 observers were reviewed jointly, and a consensus was reached. To evaluate the extent of Foxp3+ Treg cells infiltration, a grading system for semiquantitative scoring based on the system established by Black [16], and previously described and validated to assess Treg infiltration [17] was used. Briefly, at least 10 fields were assessed: grade 0 corresponds to absence of Foxp3+ Treg cells, grade 1 corresponds to presence of 1 to 3 Foxp3+ Treg cells in less than three fields, grade

2 corresponds to presence of 1 to 3 Foxp3+ Treg cells in more than three fields, and grade 3 corresponds to the presence of more than 3 Foxp3+ Treg cells in more than three fields. Grades 0 and 1 were considered as low infiltration, whereas grades 2 and 3 were considered as strong Treg infiltration.

Statistical analysis: The association between presence of Foxp3+ tumor cells / or Foxp3+ Treg cells infiltration and clinicopathological/biological variables was examined using the Chi2 test and Fisher's exact probability test if required. Relapse free survival (RFS) was defined as the time elapsed from the date of diagnosis to the date of the first event (locoregional recurrence and /or a distant recurrence, whichever came first). Overall survival (OS) was defined as the time from date of diagnosis until death. The Kaplan-Meier method was used for calculation of survival probabilities and the log-rank test for comparison of survival curves. Cox's proportional hazards regression was used for univariate and multivariate analysis of RFS and OS. All predictors with *P* values lower than 0.10 in univariate analysis were used in multivariate analysis, carried out by the backward elimination procedure. Foxp3 and treatment interaction terms were included in the models with significance testing by the likelihood ratio test.

All analyses were conducted using Medcalc software (Medcalc Software, Mariakerke, Belgium). Two-sided *P* values less than 0.05 were considered statistically significant.

Results

Patient characteristics: In total, 103 patients were included in this analysis. Patient and tumor characteristics are reported in Table 1. Half of all patients presented with stage T3 or T4 tumor and 72% had clinically detectable axillary lymph node involvement at diagnosis. Half the patients presented with high tumor grade (SBR III) and/or negative estrogen receptor. Neoadjuvant chemotherapy was given every 3 weeks for a total of 6 cycles, and consisted of an anthracycline-based regimen in 48 cases (47%), and trastuzumab + taxane-based regimen in 55 cases (53%). Classic histological analysis of surgical specimens revealed a pCR in 27 cases (25%) (19/55 (33%) in the group treated by trastuzumab + taxane and 8/48 (16%) in the group treated by anthracycline-based regimen). Median follow-up period was 40 months (range 7 - 144).

Foxp3 expression in breast cancer tumor cells: Of the 103 tumor specimens, 59 (57%) were found to express Foxp3 in tumor cells. Foxp3 staining was always localized in the cytoplasm of breast cancer cells (figure 1A and 1D), by contrast with the nuclear staining of Treg cells (Figure 1D and 1E). Table 2 lists the frequency of prognostic clinicopathologic characteristics, according to the presence or absence of Foxp3 immunostaining. No

significant association was found between expression of Foxp3 in tumor cells and prognostic parameters (tumor size, estrogen receptor status, lymph node status, type of chemotherapy, histological response after neoadjuvant chemotherapy), except for tumor grade ($P=0.046$). Frequency of Foxp3+ tumor cells was not significantly different between patients treated or not with trastuzumab ($P= 0.69$).

Prognostic significance of Foxp3 expression in breast cancer cells overexpressing HER2: Univariate analysis of clinical and pathological characteristics (Table 3) indicated that neither age > 50, tumor stage \geq T3, axillary nodal involvement, high tumor grade, or negative estrogen receptor was associated with an increased risk of relapse (RFS) or death (OS). Only the presence of pathologic complete response on surgical specimen ($P= 0.01$; HR 0.31 95%CI 0.11-0.88 and $P= 0.038$; HR 0.53 95%IC 0.15-0.82 respectively), chemotherapy with trastuzumab ($P= 0.001$; HR 0.32 95%IC 0.15-0.69 and $P= 0.002$; HR 0.05 95%IC 0.006-0.35 respectively), and presence of Foxp3+ tumor cells ($P= 0.007$; HR 0.40 95%IC 0.21-0.78 and $P= 0.040$; HR 0.46 95%IC 0.22-0.95 respectively) were significantly associated with lower risk of relapse (RFS) or death (OS). Presence of Foxp3+ tumor cells confers significantly better RFS (log-rank test $P= 0.005$) and OS (log-rank test $P= 0.03$) (Figure 2A and 2B). Of note, the probability of 10-year survival was 73% for patients with Foxp3+ tumor cells, and only 42% in the Foxp3- tumor cells group. We then performed a subgroup analysis in anthracycline and trastuzumab group. In the anthracycline group, the presence of Foxp3+ tumor cells was significantly associated with lower risk of RFS ($P=0.0045$; HR 0.3195%IC 0.14-0.69). In the trastuzumab group the presence of Foxp3+ tumor cells was also associated with trend toward lower risk of RFS ($P=0.11$; HR 0.32%IC 0.08-1.25). By interaction testing there was evidence that the effect of Foxp3+ tumor cells did not differ in both treatment arms (anthracycline versus trastuzumab) (interaction test = 0.6)

Cox proportional multivariate analysis using all predictors with P values lower than 0.1 in the univariate analysis (Table 4) revealed that only the presence of Foxp3 expression in tumor cells ($P= 0.006$; HR 0.39 95%IC 0.19-0.76 and $P= 0.03$; HR 0.42 95%IC 0.19-0.90 respectively), and chemotherapy with trastuzumab ($P= 0.002$; HR 0.30 95%IC 0.14-0.64 and $P= 0.002$; HR 0.04 95%IC 0.006-0.33 respectively) were significant independent prognostic factors for better RFS and OS.

Prognostic significance of Foxp3+ Treg cells infiltration in breast cancer overexpressing HER2: There was no significant correlation between the presence of Foxp3+ breast cancer cells and high tumor infiltrates in Foxp3+ Treg cells ($P=0.1$; χ^2 test). Sixty-one percent of patients had high Foxp3+ Treg cell infiltrate (grade 2-3). By

univariate analysis, high Foxp3+ Treg infiltration was not significantly associated with an increased risk of relapse (RFS) or death (OS), whatever treatment received (eg: anthracyclines or trastuzumab-based chemotherapy) (Table 5).

Discussion

Foxp3 is a member of the forkhead family of transcription factors critically involved in the development and functions of Treg cells, and is, thus far, the most specific marker of this cell subtype [18]. Increased numbers of tumor-infiltrating Treg cells have been demonstrated in various types of cancer [5, 19, 20], and their presence in elevated numbers among T cells infiltrating tumors is associated with poor prognosis in breast [21] and ovarian cancer [5]. Until recently, Foxp3 expression was thought to occur mainly in Treg cells and some populations of activated T cells. However, recent studies have provided clear evidence that various types of human cancer cells expressed the transcript of Foxp3, as well as the mature protein [10, 22, 23].

Merlo et al [11] recently reported that Foxp3 was expressed in 57% of 183 patients bearing a localized breast cancer; a rate similar to that found in our study. Interestingly, the authors identified tumor cell Foxp3 expression as a new independent factor of poor prognosis for relapse-free and overall survival. However, the potential function of Foxp3 in tumor cells, and the mechanism by which Foxp3 expression in breast cancer cells could affect prognosis remains unclear. In apparent contradiction with Merlo's data, Zuo et al recently reported that Foxp3 acts as a transcriptional repressor for the breast cancer oncogenes *SKP2* and *HER2*, suppressing breast tumor cell growth [12, 13]. Moreover, induction of Foxp3 expression in breast cancer cell lines could induce apoptosis, and abrogate tumor growth in murine models [12, 13, 24]. These biological data suggested that the function of Foxp3 in cancer cells may depend on the nature of the breast tumor, especially concerning oncogenic pathways involved in tumor growth. Interestingly, in our series of HER2-overexpressing breast patients, Foxp3 expression in breast cancer cells was associated with better long term prognosis and constituted an independent prognostic factor for better relapse-free and overall survival.

These contradictory results with Merlo's study are probably explained by differences in the studied populations. First, we limited our study to patients with HER2-overexpressing breast cancer. In Merlo's study, only 15% of the patients harboured HER2-overexpressing carcinomas. Moreover, no prognostic stratification upon breast cancer histological subtypes was performed. Another important difference with our study is that all our patients received neoadjuvant chemotherapy before surgical resection, and then radiotherapy, whereas only a limited number of patients reported by Merlo et al received postsurgical chemotherapy.

A nuclear localization of Foxp3 is observed in regulatory T cells but also in the epithelial cells of mouse [25] and human [13] normal mammary glands. Our study reveals that, in HER2-overexpressing breast cancer cells, Foxp3 staining was only observed in the cytoplasm. These results are in accordance with those from Zuo et al, who demonstrated that Foxp3 could be expressed in the nucleus of normal or tumoral epithelial breast cells. Importantly this nuclear expression seemed to be restricted to HER negative tumors. However, Foxp3 cytoplasmic expression was not tested in this work [13]. In a recent paper about Foxp3 expression in prostate cancer cells [26], the same team of investigators demonstrated that genetic Foxp3 mutation could be detected in cancer cells and restrained its expression in the cytoplasm as in our series of HER overexpressing patients. Nonetheless, the prognostic role of the cytoplasmic expression of Foxp3 was not tested in this work. A cytoplasmic localization of Foxp3 was observed in cancer cells from various human carcinomas [10, 22], including human breast carcinoma. Cytoplasmic rather than nuclear localization of Foxp3 could result from somatic mutations. Foxp3 molecule contains a winged-helix/forkhead (FKH) domain that includes a putative nuclear localization signal. Mutations of this domain can be observed in the *Scurfy* mouse and in the corresponding human IPEX syndrome, leading to a Foxp3 localization restricted to the cytoplasm [27]. Similar mutations were observed in human breast carcinoma [13] and, as well as other transcriptional or post-transcriptional modifications, could induce its cytoplasmic rather than nuclear localisation in cancer cells. However, the exact biological function of cytoplasmic Foxp3 is presently undetermined, but our data suggest that, even in this cellular localization, Foxp3 seems to influence HER2 overexpressing breast cancer natural history. As we adhere to the REMARK criteria for tumor marker studies [28], we analyzed our data according to systemic therapy groups. Interestingly, in subgroup analysis, the role of Foxp3 was found significant in the anthracycline group and with a trend toward significance in the trastuzumab group in univariate Cox proportional analysis. The absence of significance was probably due to the few rate of event in this group. Importantly the multivariate analysis and the interaction testing found that the effect of Foxp3 cell on RFS is independent of the treatment. In sum, these data suggest that the prognostic relevance of tumor cell Foxp3 expression in HER2-overexpressing breast carcinoma is probably not influenced by modulation of the HER2 pathway induced by trastuzumab. However, we think that additional studies have to be performed to validate this result. Some papers demonstrated that Treg infiltrates in tumor bed may have a poor prognostic significance in early breast cancer [21,29], but in the both series, this prognostic role of Foxp3 regulatory T cells was not tested in HER2 overexpressing tumors. In this series of HER2 overexpressing breast carcinoma, Foxp3 expression in cancer cells is relevant for patient's prognostic while the presence of Foxp3+ Treg in tumor bed have no

prognostic behavior. In addition these two informations are not statistically correlated. These data strongly enforce our results and suggest to Fcpx3 expression is a really new and independent prognostic factor in HER2 overexpressing early breast cancer.

In conclusion, Fcpx3 expression and function can no longer be considered to be restricted to the T-cell lineage, but may instead play a wider role in breast cancer cell biology. Our results suggest that Fcpx3 expression in regulatory T cells and in tumor cells could have opposite prognostic values, at least in certain breast cancer varieties. This is a strong argument against using biomolecular methods such as mRNA expression by real-time polymerase chain reaction instead of immunohistochemistry for determining tumor infiltration by Fcpx3+ regulatory T cells. However, determination of Fcpx3 expression consequences both in Treg and cancer cells will require further elucidation, especially in the context of new therapeutic strategies targeting Treg cells, and particularly Fcpx3 expression [30].

Taken together, our data suggest that Fcpx3 expression in breast cancer cells could be a prognostic marker for patient outcome. However, our results also indicate that the influence of Fcpx3 was dependent on the molecular subtype of breast cancer. Indeed, Fcpx3 expression in cancer cells may be a marker of good prognosis in HER2-overexpressing tumors and of poor prognosis in other molecular subtypes of breast cancer. The issue of whether Fcpx3 might become a clinically usable prognostic marker in breast carcinoma will need to be evaluated in other larger series of patients, and analysis will have to be stratified on breast molecular subtype, notably on HER2-overexpressing subtype.

Authors' disclosures of potential conflicts of interest:

No author has any conflict of interest to declare.

Grant support: This study was supported by Ligue contre le Cancer comité de Côte d'Or, Association pour la Recherche Contre le Cancer (ARC), Fondation de France INSERM AVENIR program and GERTI (Groupe d'Etude et de Recherche en Thérapeutique Innovante).

Gregoire Mignot was supported by ARC (Association pour la Recherche contre le Cancer) and Julie Vincent by INCa (Institut National du Cancer).

REFERENCES

1. Hori S, Nomura T, Sakaguchi S. (2003) Control of regulatory T cell development by the transcription factor Foxp3. *Science* 299:1057-61.
2. Fontenot JD, Gavin MA, Rudensky AY. (2003) Foxp3 programs the development and function of CD4+CD25+ regulatory T cells. *Nat Immunol* 4:330-6.
3. Sakaguchi S, Ono M, Setoguchi R, et al. (2006) Foxp3+ CD25+ CD4+ natural regulatory T cells in dominant self-tolerance and autoimmune disease. *Immunol Rev* 212:8-27.
4. Ghiringhelli F, Menard C, Puig PE, et al. (2007) Metronomic cyclophosphamide regimen selectively depletes CD4+CD25+ regulatory T cells and restores T and NK effector functions in end stage cancer patients. *Cancer Immunol Immunother* 56:641-8.
5. Curiel TJ, Coukos G, Zou L, et al. (2004) Specific recruitment of regulatory T cells in ovarian carcinoma fosters immune privilege and predicts reduced survival. *Nat Med* 10:942-9.
6. Ko HJ, Kim YJ, Kim YS, et al. (2007) A combination of chemoimmunotherapies can efficiently break self-tolerance and induce antitumor immunity in a tolerogenic murine tumor model. *Cancer Res* 67:7477-86.
7. Dieckmann D, Plottner H, Berchtold S, Berger T, Schuler G. (2001) Ex vivo isolation and characterization of CD4(+)CD25(+) T cells with regulatory properties from human blood. *J Exp Med* 193:1303-10.
8. Ghiringhelli F, Menard C, Martin F, Zitvogel L. (2006) The role of regulatory T cells in the control of natural killer cells: relevance during tumor progression. *Immunol Rev* 214:229-38.
9. Roux S, Apetoh L, Chalmin F, et al. (2008) CD4+CD25+ Tregs control the TRAIL-dependent cytotoxicity of tumor-infiltrating DCs in rodent models of colon cancer. *J Clin Invest* 118:3751-61.
10. Karanikas V, Speletas M, Zamanakou M, et al. Foxp3 expression in human cancer cells. (2008) *J Transl Med* 6:19.
11. Merlo A, Casalini P, Carcangiu ML, et al. (2009) FOXP3 expression and overall survival in breast cancer. *J Clin Oncol* 27:1746-52.
12. Zuo T, Liu R, Zhang H, et al. (2007) FOXP3 is a novel transcriptional repressor for the breast cancer oncogene SKP2. *J Clin Invest* 117:3765-73.
13. Zuo T, Wang L, Morrison C, et al. (2007) FOXP3 is an X-linked breast cancer suppressor gene and an important repressor of the HER-2/ErbB2 oncogene. *Cell* 129:1275-86.

14. Elston CW, Ellis IO. (1991) Pathological prognostic factors in breast cancer. I. The value of histological grade in breast cancer: experience from a large study with long-term follow-up. *Histopathology* 19:403-10.
15. Chevallier B, Roche H, Olivier JP, Chollet P, Hurteloup P. (1993) Inflammatory breast cancer. Pilot study of intensive induction chemotherapy (FEC-HD) results in a high histologic response rate. *Am J Clin Oncol* 16:223-8.
16. Black MM, Opler SR, Speer FD. (1956) Structural representations of tumor-host relationships in gastric carcinoma. *Surg Gynecol Obstet* 102:599-603.
17. Ladoire S, Arnould L, Apetoh L, et al. (2008) Pathologic complete response to neoadjuvant chemotherapy of breast carcinoma is associated with the disappearance of tumor-infiltrating foxp3+ regulatory T cells. *Clin Cancer Res* 14:2413-20.
18. Coffey PJ, Burgering BM. (2004) Forkhead-box transcription factors and their role in the immune system. *Nat Rev Immunol* 4:889-99.
19. Ormandy LA, Hillemann T, Wedemeyer H, Manns MP, Greten TF, Korangy F. (2005) Increased populations of regulatory T cells in peripheral blood of patients with hepatocellular carcinoma. *Cancer Res* 65:2457-64.
20. Ichihara F, Kono K, Takahashi A, Kawaida H, Sugai H, Fujii H. (2003) Increased populations of regulatory T cells in peripheral blood and tumor-infiltrating lymphocytes in patients with gastric and esophageal cancers. *Clin Cancer Res* 9:4404-8.
21. Bates GJ, Fox SB, Han C, et al. (2006) Quantification of regulatory T cells enables the identification of high-risk breast cancer patients and those at risk of late relapse. *J Clin Oncol* 24:5373-80.
22. Hinz S, Pagerols-Raluy L, Oberg HH, et al. (2007) Foxp3 expression in pancreatic carcinoma cells as a novel mechanism of immune evasion in cancer. *Cancer Res* 67:8344-50.
23. Ebert LM, Tan BS, Browning J, et al. (2008) The regulatory T cell-associated transcription factor FoxP3 is expressed by tumor cells. *Cancer Res* 68:3001-9.
24. Liu Y, Wang Y, Li W, Zheng P. (2009) Activating transcription factor 2 and c-Jun-mediated induction of FoxP3 for experimental therapy of mammary tumor in the mouse. *Cancer Res* 69:5954-60.
25. Chen GY, Chen C, Wang L, Chang X, Zheng P, Liu Y. (2008) Cutting edge: Broad expression of the FoxP3 locus in epithelial cells: a caution against early interpretation of fatal inflammatory diseases following in vivo depletion of FoxP3-expressing cells. *J Immunol* 180:5163-6.

26. Wang L, Liu R, Li W, et al. (2009) Somatic single hits inactivate the X-linked tumor suppressor FOXP3 in the prostate. *Cancer Cell* 16:336-46.
27. Lopes JE, Torgerson TR, Schubert LA, et al. (2006) Analysis of FOXP3 reveals multiple domains required for its function as a transcriptional repressor. *J Immunol* 177:3133-42.
28. McShane LM, Altman DG, Sauerbrei W, Taube SE, Gion M, Clark GM. (2005) Reporting recommendations for tumor marker prognostic studies. *J Clin Oncol* 23:9067-72.
29. Gobert M, Treilleux I, Bendriss-Vermare N, et al. (2009) Regulatory T cells recruited through CCL22/CCR4 are selectively activated in lymphoid infiltrates surrounding primary breast tumors and lead to an adverse clinical outcome. *Cancer Res* 69:2000-9.
30. Nair S, Boczkowski D, Fassnacht M, Pisetsky D, Gilboa E. (2007) Vaccination against the forkhead family transcription factor Foxp3 enhances tumor immunity. *Cancer Res* 67:371-80.

FIGURE LEGENDS

Figure 1: Immunohistochemical Foxp3 staining of paraffin-embedded breast cancer overexpressing HER2. Representative results are shown for (A) Foxp3+ tumor cells ((B): the same tumor stained with isotype-matched control antibody), and (C) Foxp3- tumor cells. Black arrows indicate tumor infiltrating-Foxp3+ Treg cells with typical intense nuclear staining in (D) Foxp3+ tumor cells and (E) Foxp3- tumor cells. Magnification X20.

Figure 2: Presence of Foxp3+ tumor cells in HER2-overexpressing breast cancer predicts better relapse-free survival (RFS) and overall survival (OS) in patients treated with neoadjuvant chemotherapy. Kaplan-Meier curves for (A) RFS, and (B) OS stratified according to presence (Foxp3+) or absence (Foxp3-) of Foxp3 expression in breast cancer cells. *P* values were calculated using the log-rank test.

Figure 1:

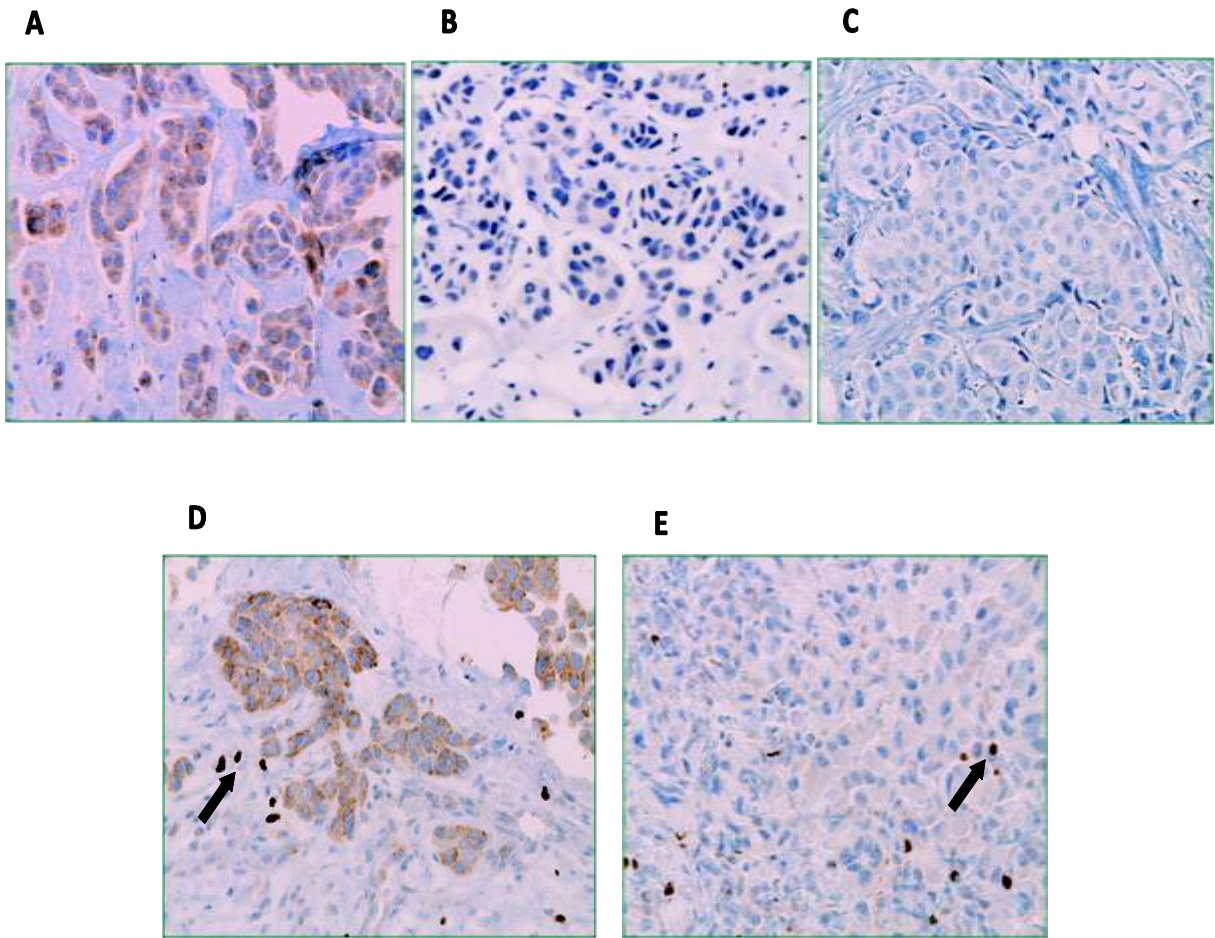
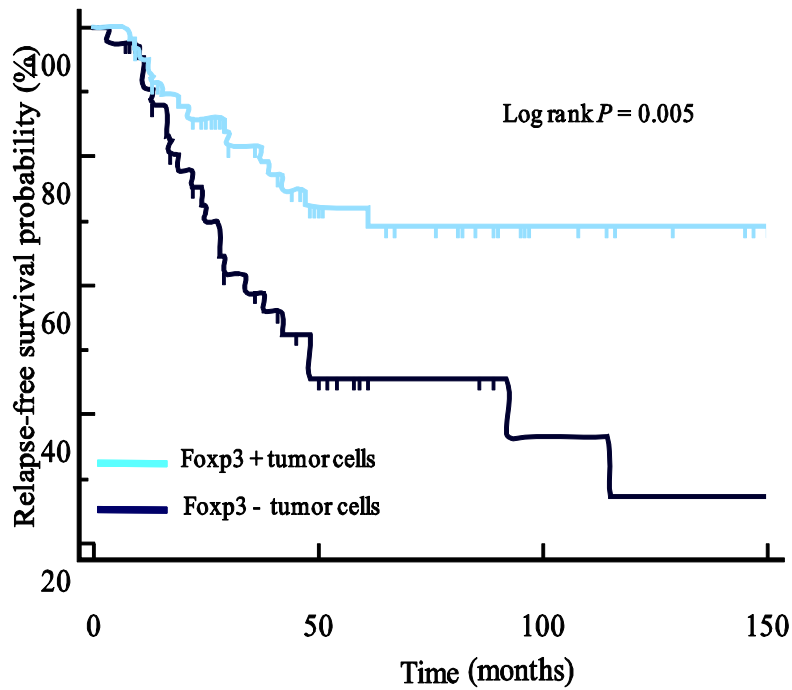


Figure 2:

A



B

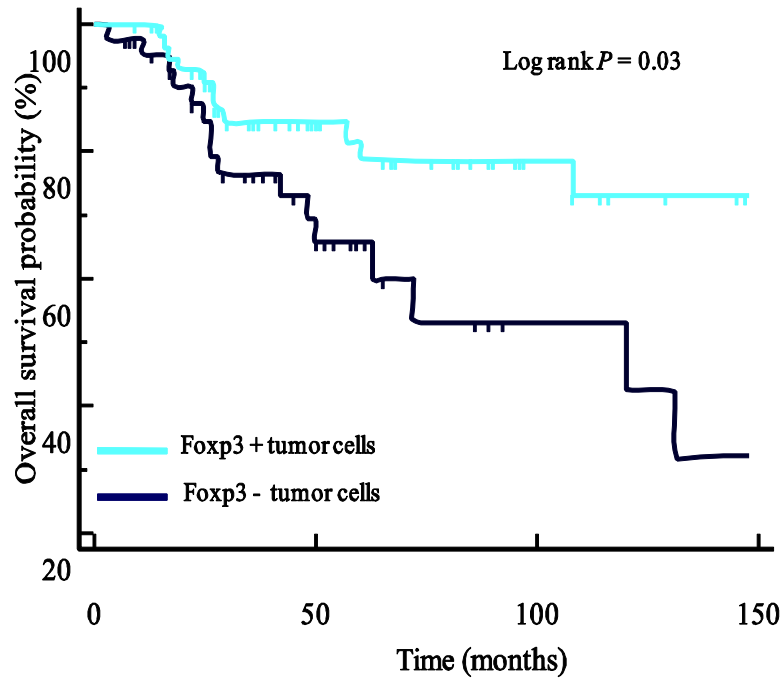


Table 1. *Clinicopathologic Characteristics of Patients*

Characteristic	No./ Total No.	%
. Age (years)		
< 50	57 / 103	55
≥ 50	46 / 103	45
. T stage		
T1-2	55 / 103	53
T3-4	48 / 103	47
. Axillary nodal status		
Positive	74 / 103	72
Negative	29 / 103	28
. Tumor grade		
III	48 / 103	47
I + II	55 / 103	53
. Estrogen receptor status		
Negative	52 / 103	50
Positive	51 / 103	50
. Chemotherapy		
Anthracycline	48 / 103	47
Trastuzumab + Taxane	55 / 103	53
. Response		
Pathological complete response	27 / 103	26
Non complete response	76 / 103	74

Table 2: *Frequency of prognostic clinicopathological characteristics of the 103 patients according to presence or absence of Foxp3 cells*

Characteristic	Presence of Foxp3+ cells		Absence of Foxp3+ cells		P
	No./Total No.	%	No./Total No.	%	

Age (years)					
< 50	29 / 59	49	28 / 44	64	0.21
> 50	30 / 59	51	16 / 44	36	
T stage					
T1-2	31 / 59	52	24 / 44	54	0.68
T3-4	28 / 59	48	20 / 44	46	
Axillary nodal status					
Positive	41 / 59	69	33 / 44	75	0.69
Negative	18 / 59	31	11 / 44	25	
Tumor grade					
I + II	26 / 59	44	29 / 44	66	0.046
III	33 / 59	56	15 / 44	34	
Estrogen receptor					
Positive	27 / 59	46	24 / 44	55	0.49
Negative	32 / 59	54	20 / 44	45	
Chemotherapy					
Anthracyclines	29 / 59	49	19 / 44	43	0.69
Trastuzumab + Taxane	30 / 59	51	25 / 44	57	
Response					
Pathological complete response	20 / 59	34	7 / 44	16	0.07
Non complete response	39 / 59	66	37 / 44	84	

Table 3: Univariate analysis (Cox regression) for relapse-free survival and overall survival in the 103 patients

Variable		RFS			OS		
		Hazard ratio	95% CI	P	Hazard ratio	95% CI	P
Age > 50	No	1			1		
	Yes	0.96	0.50 to 1.85	0.91	1.11	0.53 to 2.34	0.78
T stage ≥ T3	No	1			1		
	Yes	1.13	0.59 to 2.15	0.71	1.20	0.57 to 2.53	0.62
Axillary nodal involvement	No	1			1		
	Yes	1.26	0.71 to 2.22	0.43	2.14	0.74 to 6.20	0.13
Tumor grade III	No	1			1		
	Yes	0.99	0.52 to 1.90	0.99	1.12	0.53 to 2.36	0.76
Estrogen receptor	No	1			1		
	Yes	0.75	0.39 to 1.45	0.39	0.75	0.36 to 1.61	0.46
Pathological complete response	No	1			1		
	Yes	0.31	0.11 to 0.88	0.01	0.53	0.15 to 0.82	0.038
Chemotherapy with Trastuzumab	No	1			1		
	Yes	0.32	0.15 to 0.69	0.001	0.05	0.006 to 0.35	0.002
Foxp3+ tumor cells	No	1			1		
	Yes	0.40	0.21 to 0.78	0.007	0.46	0.22 to 0.95	0.040

RFS : relapse-free survival ; OS : overall survival

Table 4: Multivariate analysis (Cox regression) for relapse-free survival and overall survival in the 103 patients

Variable		RFS			OS		
		Hazard ratio	95% CI	P	Hazard ratio	95% CI	P
Pathological complete response	No	1			1		
	Yes	0.47	0.16 to 1.35	0.16	0.53	0.15 to 1.82	0.32
Chemotherapy with Trastuzumab	No	1			1		
	Yes	0.30	0.14 to 0.64	0.002	0.04	0.006 to 0.33	0.002
Foxp3+ tumor cells	No	1			1		
	Yes	0.39	0.19 to 0.76	0.006	0.42	0.19 to 0.90	0.03

RFS: relapse-free survival ; OS : overall survival

Table 5: Univariate analysis (Cox regression) for relapse-free survival and overall survival in the 103 patients according to presence or absence of high Foxp3+ Treg cells tumor infiltration.

	High Treg infiltration	RFS			OS		
		Hazard ratio	95% CI	P	Hazard ratio	95% CI	P
Whole population	No	1			1		
	Yes	0.86	0.41 to 1.63	0.56	1.27	0.57 to 2.80	0.55
Chemotherapy with Trastuzumab	No	1			1		
	Yes	0.38	0.08 to 1.68	0.20	ND	ND	
Chemotherapy with anthracyclines	No	1			1		
	Yes	1.28	0.58 to 2.80	0.54	1.52	0.68 to 3.36	0.31

RFS: relapse-free survival ; OS : overall survival; ND: not determinable

Copyright Transfer Statement



BREAST CANCER RESEARCH AND TREATMENT

The copyright to this article is transferred to Springer (respective to owner if other than Springer and for U.S. government employees: to the extent transferable) effective if and when the article is accepted for publication. The copyright transfer covers the exclusive right to reproduce and distribute the article, including reprints, translations, photographic reproductions, microform, electronic form (offline, online) or any other reproductions of similar nature.

An author may self-archive an author-created version of his/her article on his/her own website and his/her institution's repository, including his/her final version; however he/she may not use the publisher's PDF version which is posted on www.springerlink.com. Furthermore, the author may only post his/her version provided acknowledgement is given to the original source of publication and a link is inserted to the published article on Springer's website. The link must be accompanied by the following text: "The original publication is available at www.springerlink.com".

Please use the appropriate DOI for the article (go to the Linking Options in the article, then to OpenURL and use the link with the DOI). Articles disseminated via www.springerlink.com are indexed, abstracted, and referenced by many abstracting and information services, bibliographic networks, subscription agencies, library networks, and consortia.

The author warrants that this contribution is original and that he/she has full power to make this grant. The author signs for and accepts responsibility for releasing this material on behalf of any and all co-authors.

Financial Disclosure/Conflict of Interest Statement

I, the undersigned author, certify that the authors of the Article have no commercial associations (e.g., consultancies, stock ownership, equity interests, patent/licensing arrangements, etc.) that might pose a conflict of interest in connection with the submitted article, except as disclosed on a separate attachment. All funding sources supporting the work and all institutional or corporate affiliations of the authors are acknowledged in a footnote.

Check here if a separate attachment is enclosed.

After submission of this agreement signed by the corresponding author changes of authorship or in the order of the authors listed will not be accepted by Springer.

Title of article: Presence of *Erp3* expression in human cells predicts better survival in
HER-2 overexpressing breast cancer patients treated with trastuzumab class

Authors: Ludovic S, Arnold L, Miguel G, Guadalupe B, Róbal C, Clavero F, Viciu
B, Milant M, Jankovic B, Manes F, Gonzalez P, Ghislanzoni F

Author's signature:

Date:

5/12/2003