



HAL
open science

Necrotizing fasciitis and acute kidney injury in a patient with acute myelogenous leukemia-case presentation and review of the literature

Johan M. Lorenzen, Jürgen Krauter, Florian Länger, Hermann Haller,
Wilfried Gwinner

► To cite this version:

Johan M. Lorenzen, Jürgen Krauter, Florian Länger, Hermann Haller, Wilfried Gwinner. Necrotizing fasciitis and acute kidney injury in a patient with acute myelogenous leukemia-case presentation and review of the literature. *Annals of Hematology*, 2010, 90 (2), pp.235-238. 10.1007/s00277-010-0995-0 . hal-00554992

HAL Id: hal-00554992

<https://hal.science/hal-00554992>

Submitted on 12 Jan 2011

HAL is a multi-disciplinary open access archive for the deposit and dissemination of scientific research documents, whether they are published or not. The documents may come from teaching and research institutions in France or abroad, or from public or private research centers.

L'archive ouverte pluridisciplinaire **HAL**, est destinée au dépôt et à la diffusion de documents scientifiques de niveau recherche, publiés ou non, émanant des établissements d'enseignement et de recherche français ou étrangers, des laboratoires publics ou privés.

Editorial Manager(tm) for Annals of Hematology
Manuscript Draft

Manuscript Number: AOHE-D-10-00224R1

Title: Necrotizing fasciitis and acute kidney injury in a patient with acute myelogenous leukemia - case presentation and review of the literature

Article Type: Letter to the Editor

Keywords: acute kidney injury, acute myelogenous leukaemia, necrotizing fasciitis

Corresponding Author: Dr. Johan M Lorenzen, MD

Corresponding Author's Institution: Hanover Medical School

First Author: Johan M Lorenzen, MD

Order of Authors: Johan M Lorenzen, MD; Jürgen Krauter, MD, PhD; Florian Länger, MD; Hermann Haller, MD, PhD; Wilfried Gwinner, MD, PhD

Abstract: Introduction: Necrotizing fasciitis is characterized by fulminant destruction of soft tissue. Patients present with signs of systemic inflammation as well as local tense edema along with bullae and subcutaneous gas.

Case presentation: A 46 year-old male was transferred to our tertiary-care center with a necrotizing fasciitis of the right forearm and acute kidney injury. To find causative pathogens/conditions of the necrotizing fasciitis microbiological, viral tests as well as immunological parameters (ANCA, ANA, cryoglobulines, anti-SM antibodies) were analyzed, but were all negative. A kidney biopsy revealed a non-putride interstitial nephritis. Despite adequate surgical therapy of the fasciitis and empiric antibiotic therapy, the patient's condition did not improve significantly. He developed fever up to 39 degrees Celsius while being under continued antibiotic therapy. A progressive increase of the white blood cell count was observed with predominance of monocytes (44%). A bone marrow biopsy showed an acute myelogenous leukaemia. With successful treatment of the leukaemia, the patient recovered from his fasciitis.

Conclusion: Necrotizing fasciitis in patients with leukemia has been occasionally reported, relating the fasciitis to an infection in the immunocompromised condition. Our case is most likely the first reported case of true paraneoplastic fasciitis in leukemia because all other potential causes including infection were negative.

Response to Reviewers: We thank the reviewer for his/her valuable comments.

The title was changed according to the suggestion of the reviewer. In addition, we shortened the manuscript by 30% as suggested by the editor.

1 **Necrotizing fasciitis and acute kidney injury in a patient with**
2 **acute myelogenous leukemia - case presentation and review of the**
3 **literature**
4
5
6
7
8
9

10 Johan M. Lorenzen¹, Jürgen Krauter², Florian Länger³, Hermann Haller¹ and
11 Wilfried Gwinner¹
12
13

14
15
16 Department of Medicine, ¹Division of Nephrology & Hypertension, ²Division of Hematology/Oncology, ³Department
17 of Pathology, Hanover Medical School
18
19

20
21
22 Corresponding author:

23 Johan M, Lorenzen MD

24 Division of Nephrology,

25 Department of Medicine

26 Hanover Medical School

27 Carl-Neuberg-Strasse 1

28 30625 Hanover, Germany

29 Phone: (49) 511 – 532 6319

30 Fax: (49) 511 – 55 23 66

31 E-mail: J.M.Lorenzen@gmail.com
32
33
34
35
36
37
38
39
40
41
42
43
44

45 Key words: acute kidney injury, acute myelogenous leukaemia, necrotizing fasciitis
46
47
48
49
50
51
52
53
54
55
56

57 Word count: main body (not including references, tables and figure legends): 974 words, 1
58 table, 1 figure, 3 references
59
60
61
62
63
64
65

Dear Editor,

Necrotizing fasciitis is characterized by fulminant destruction of soft tissue. Associated conditions include intravenous drug use, diabetes mellitus, obesity and immunosuppression [1]. It is divided into two types: type I is a mixed aerobic and anaerobic bacterial infection. Type II refers to a mono-microbial infection caused by group A streptococci. While type I primarily occurs in immuno-compromised patients, type II can manifest in any age group and among patients who do not have complicated medical illnesses [2]. Therapy consists of early and complete surgical debridement and sufficient antibiotic therapy. Antibiotic therapy alone is associated with a mortality rate approaching 100 percent [1]. We report a patient with severe fasciitis of the right arm suggestive of paraneoplastic fasciitis and acute renal failure.

A 46 year-old male was transferred to our tertiary-care center with a necrotizing fasciitis of the right forearm and an elevated serum creatinine value of 400 $\mu\text{mol/L}$. The patient had been healthy until four weeks prior to admission when he presented to a general practitioner with pharyngitis and fever. He received penicillin for 7 days and recovered from the pharyngitis. However, undulating fever up to 39 degrees Celsius recurred after cessation of antibiotic therapy, together with generalized joint pain and myalgias. He took nonsteroidal anti-inflammatory drugs (ibuprofen) over several days, which relieved his symptoms. Two weeks prior to admission the patient developed local pain and swelling of the right forearm. Initial laboratory parameters showed a C-reactive protein (CRP) level of 310 mg/L, a white blood cell count of 25,000 cells/uL and a creatine kinase (CK) of 602 U/L. Computed tomography showed massive edema of subcutaneous tissue of the right forearm. Several aerobic and anaerobic blood culture samples remained sterile. Tissue from repeated surgical debridements was cultured and stained for micro-organisms, but showed negative results (**Figure 1a, b**). A transthoracic and transesophageal echocardiography did not reveal signs of endocarditis. Viral tests, including hanta virus were unremarkable. ANCA, ANA,

1 cryoglobulines and anti-SM antibodies were all negative. A kidney biopsy was performed and
2 showed a non-putride interstitial nephritis. No leukaemic infiltrates were present. The
3
4 affected tissue of the right forearm was immediately surgically removed. A systemic anti-
5
6 infectious treatment regimen including intravenous penicillin, clindamycin, meropenem,
7
8 amphotericin B and fluconazole was initiated. Moreover, the interstitial nephritis was treated
9
10 with prednisolone in a concentration of 1 mg/kg body weight, which was tapered over 15
11
12 weeks to 5 mg once daily. Over the next two weeks the white leukocyte count showed a
13
14 transient fall to a minimum of 17.700/ μ L, C-reactive protein levels fell to 170 mg/L.
15
16 Nevertheless, the patient's overall clinical condition improved only temporarily. He
17
18 developed fever up to 39 degrees Celsius while being under continued antibiotic therapy. A
19
20 progressive increase of the white blood cell count to 82.200 cells/ μ L was observed. The
21
22 differential blood cell count revealed rising numbers of monocytes, from a minimum value of
23
24 10.200/ μ L on day 5 after admission to 36.000/ μ L on day 18 (44% of the white blood cells). A
25
26 bone marrow biopsy showed a myelodysplastic-myeloproliferative disorder with an excessive
27
28 proliferation of the monopoiesis (**Figure 1c, d**). Cytogenetics revealed a normal karyotype
29
30 with a constitutional inv(9). Molecular analysis of the bone marrow cells revealed an *NPM1*
31
32 exon 12 mutation and thus the diagnosis of a molecular defined acute myeloblastic leukemia
33
34 according to the current WHO-classification was established. Induction chemotherapy with
35
36 cytarabin, daunorubicin and vesanoid was initiated resulting in a complete remission.
37
38 Following chemotherapy, the inflammation of the right forearm gradually regressed and the
39
40 wound was successfully skin-grafted with autologous tissue from the thigh within three
41
42 weeks. Also, renal function recovered to normal values and remained stable.
43
44
45
46
47
48
49
50
51
52

53 At the initial presentation, the clinical symptoms and course of the patient's condition
54
55 was most compatible with a bacteria-associated (e.g. group A streptococci) respiratory
56
57 infection. In that context, the most likely cause of acute renal failure was post-streptococcal
58
59 glomerulonephritis or tubulointerstitial nephritis due to the infection or hypersensitivity to the
60
61
62
63
64
65

1 pharmacological therapy. We believe that the interstitial nephritis found in the biopsy is most
2 likely associated with the pharmacological treatment. The fact that bacteria could not be
3
4 isolated in multiple specimens of the resected tissue and in blood cultures does not support
5
6 bacteria-associated nephritis. In light of the final diagnosis of the patient –acute myeloblastic
7
8 leukemia- tubulointerstitial nephritis could have been associated with this disease as reported
9
10 by Elsurer et al. in two cases of acute interstitial nephritis secondary to acute leukaemia [3].
11
12
13 However, we did not detect any leukemic infiltrates in the kidney.
14
15
16
17
18

19 Leukemia could only be suspected by the patient's individual clinical course.
20
21 Particularly, the recurrence of fever while being on intense antibiotic therapy in combination
22
23 with the dramatic increase in white blood cell count, which was predominated by monocytes,
24
25 led to the suspicion of an underlying malignant disorder. The bone marrow biopsy and
26
27 molecular analysis finally showed an acute myeloblastic leukemia.
28
29
30

31 The exact cause of the necrotizing fasciitis in the presented case is unclear. We believe that
32
33 the fasciitis in our case is a true paraneoplastic phenomenon. To this end, we did not identify
34
35 other causes like vasculitis, cryoglobulinaemia, polymyositis or viral infections. Also, drug-
36
37 induced fasciitis is unlikely. Type I necrotizing fasciitis would have been an attractive
38
39 explanation. We did, however, not have any positive microbiological results in multiple blood
40
41 cultures, swabs and tissue cultures.
42
43
44
45

46 We performed a literature search to find cases with necrotizing fasciitis secondary to
47
48 leukaemia (**Table 1**). Necrotizing fasciitis secondary to leukaemia has been reported in few
49
50 instances. Most of the reported patients had acute forms of leukaemia and were at very young
51
52 or relatively old age. Half of the cases had pseudomonas aeruginosa as the putative trigger of
53
54 the fasciitis. However, no patient with leukaemia was reported to develop necrotizing fasciitis
55
56 without a bacterial trigger. In our patient, we were not able to identify a bacterial cause
57
58
59
60
61
62
63
64
65

Therefore, our case is most likely the first reported patient with paraneoplastic fasciitis
secondary to leukaemia.

1
2
3
4
5
6
7
8
9
10
11
12
13
14
15
16
17
18
19
20
21
22
23
24
25
26
27
28
29
30
31
32
33
34
35
36
37
38
39
40
41
42
43
44
45
46
47
48
49
50
51
52
53
54
55
56
57
58
59
60
61
62
63
64
65

REFERENCES

- 1
2 1. Anaya, DA, Patchen Dellinger, E. Necrotizing soft-tissue infection: diagnosis and
3
4 management. Clin Infect Dis 2007; 44:705.
5
6
- 7 2. Wong, CH, Chang, HC, Pasupathy, S, et al. Necrotizing fasciitis: clinical presentation,
8
9 microbiology, and determinants of mortality. J Bone Joint Surg Am 2003; 85-A:1454.
10
- 11 3. Elsurer R, Afsar B, Ozdemir HB, Ozdemir NF, Sezer S, Haberal M. J Nephrol: Acute
12
13 tubulointerstitial nephritis and acute leukemia: report of 2 cases. 2006 Jul-Aug;19(4):521-4.
14
15
16
17
18
19
20
21
22
23
24
25
26
27
28
29
30
31
32
33
34
35
36
37
38
39
40
41
42
43
44
45
46
47
48
49
50
51
52
53
54
55
56
57
58
59
60
61
62
63
64
65

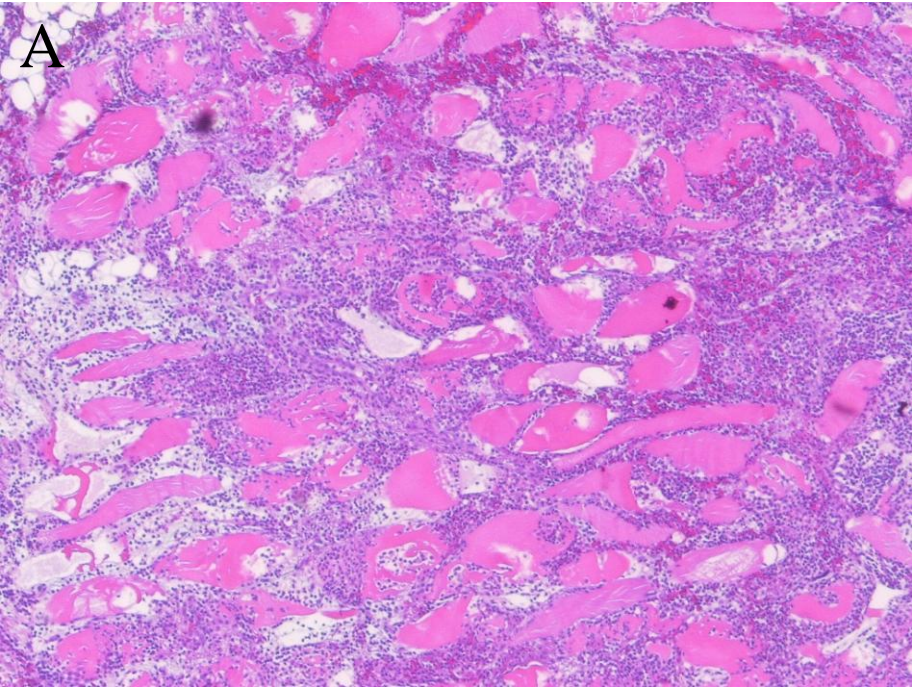
1
2
3
4
5
6
7
8
9
10
11
12
13
14
15
16
17
18
19
20
21
22
23
24
25
26
27
28
29
30
31
32
33
34
35
36
37
38
39
40
41
42
43
44
45
46
47
48
49

Table 1. Reported cases of necrotizing fasciitis secondary to leukaemia

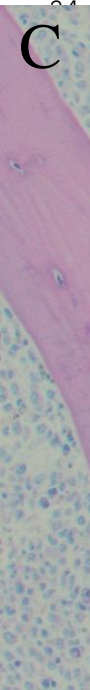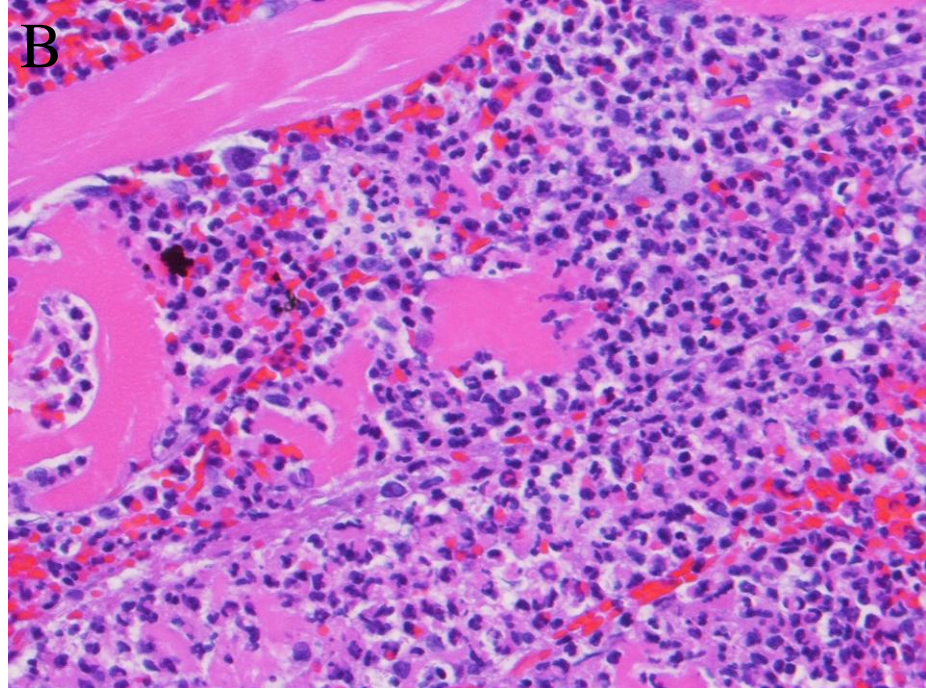
Age (years), gender (m/f)	localization of fasciitis	underlying malignancy	pathogen	Journal
8, m	maxillofacial	acute myeloid leukemia	not attempted	J Plast Reconstr Aesthet Surg. 2008 Dec;61(12)
80, m	lower right leg	acute myeloid leukemia	Aeromonas veronii biovar sobria infection	Surg Infect (Larchmt). 2007 Oct;8(5):523-8
74, m	lower right leg	chronic lymphatic leukemia	Streptococcus agalacticae	Actas Dermosifiliogr. 2006 Dec;97(10):644-6
21, m	Fournier's gangrene	acute lymphatic leukemia	Pseudomonas aeruginosa	Pediatr Blood Cancer. 2007 Nov;49(6):862-4
0.6, m	perianal region	acute lymphatic leukemia	Pseudomonas aeruginosa	Acta Derm Venereol. 2005 85(6):538-9
13, m	buccal mucosa/pharynx	acute myeloid leukemia	Pseudomonas aeruginosa	Eur J Pediatr. 2005 Feb;164(2):113-4
16, m	Fournier's gangrene	acute myeloid leukemia	Pseudomonas aeruginosa	Ann Hematol. 2002 Sep;81(9):538-9
3, f	Vulva	acute lymphatic leukemia	Pseudomonas aeruginosa	J Pediatr Surg. 2001 Jun;36(6):948-50
35, f	sacroccygeal pilonidal sinus	acute myeloid leukemia	not attempted	Ann Chir Plast Esthet. 1999 Oct;44(5):552-5

1
2
3
4
5
6
7
8
9
10
11
12
13
14
15
16
17
18
19
20
21
22
23
24
25
26
27
28
29
30
31
32
33
34
35
36
37
38
39
40
41
42
43
44
45
46
47
48
49

54, m	Fournier's gangrene	promyelocytic leukaemia	not reported	Ned Tijdschr Geneeskd. 1999 Oct 30;143(44):2177-81
41, m	Fournier's gangrene	acute non-lymphatic leukaemia	Staphylococcus aureus	Bone Marrow Transplantation 1998 (22), 1023–26
26, f	right labium majorum	acute non-lymphatic leukaemia	Pseudomonas aeruginosa	Bone Marrow Transplantation 1998 (22), 1023–26
25, f	perineal area	acute non-lymphatic leukaemia	Pseudomonas aeruginosa	Bone Marrow Transplantation 1998 (22), 1023–26
44, m	Fournier's gangrene	promyelocytic leukaemia	Streptococcus faecalis	Ann Hematol. 1998 Feb;76(2):91-2
64, m	left leg	acute myeloid leukemia	Enterobacter agglomerans	J Dermatol. 1993 Jun;20(6):378-80
3, f	left labium majorum	acute lymphatic leukemia	Pseudomonas aeruginosa	J Pediatr Surg. 1992 May;27(5):668-71
1.5, f	sacral region	acute lymphatic leukemia	E.coli	J Pediatr Surg. 1992 May;27(5):668-71
49, f	right thumb	acute myeloid leukemia	E.coli, Pseudomonas aeruginosa, Klebsiella	Am J Med. 1988 Oct;85(4):490-4



22
23
24



47
48
49

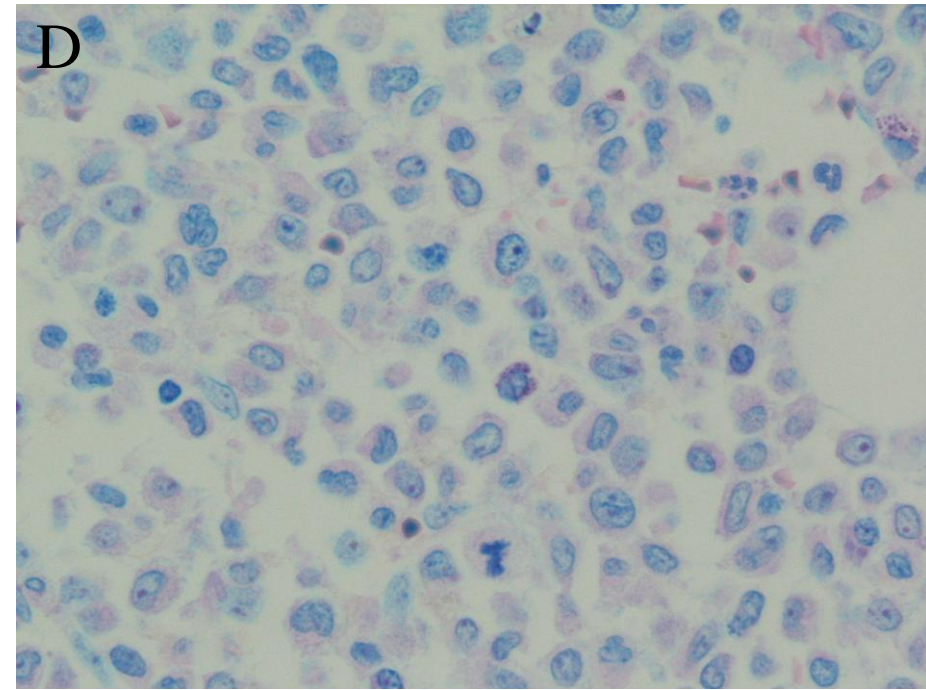


Figure 1:

A: (H&E, 20x):

Necrotizing fasciitis/myositis in low power magnification showing necrobiotic striated muscle fibres with adjacent and multifocal dense inflammatory infiltrate.

B: (H&E, 100x):

In higher magnification remnants of necrotic muscle fibres are encased in dense infiltrates of neutrophilic granulocytes.

C: (Giemsa, 40x):

Bone marrow biopsy showing a hypercellular marrow with prominent (non-neoplastic) megakaryocytes. Even at low power a rather monotonous mononuclear proliferation and a loss of the regular erythro- and granulopoiesis can be appreciated.

D: (Giemsa, 400x):

Here the monotonous proliferation of blasts including mitotic forms is shown at higher magnification. Regular elements of hematopoiesis are lacking, blasts with nuclear clearing, prominent nucleoli and sometimes rather convoluted nuclear outlines predominate.

***Conflict of interest**

[Click here to download Conflict of interest: COI.pdf](#)