



A Case Of Duplicitous Diplococci

Malini Raychaudhuri, Adrian Peall, Charlotte Page, Mary Browning

► To cite this version:

Malini Raychaudhuri, Adrian Peall, Charlotte Page, Mary Browning. A Case Of Duplicitous Diplococci. Sexually Transmitted Infections, 2009, 85 (6), pp.441. 10.1136/sti.2008.035444 . hal-00552810

HAL Id: hal-00552810

<https://hal.science/hal-00552810>

Submitted on 6 Jan 2011

HAL is a multi-disciplinary open access archive for the deposit and dissemination of scientific research documents, whether they are published or not. The documents may come from teaching and research institutions in France or abroad, or from public or private research centers.

L'archive ouverte pluridisciplinaire **HAL**, est destinée au dépôt et à la diffusion de documents scientifiques de niveau recherche, publiés ou non, émanant des établissements d'enseignement et de recherche français ou étrangers, des laboratoires publics ou privés.

Title: A Case Of Duplicitous Diplococci

Authors:

Malini Raychaudhuri MRCOG, DFFP, Dip GUM¹

Adrian. Peall MRCP(UK)²

Charlotte Page MRCP(UK)²

Mary Browning Dip Ven, MRCP(I)¹

Affiliation for all authors:

¹Department of Genitourinary Medicine, Cardiff Royal Infirmary, Newport Road, Cardiff CF24 0SZ.

²Department of Rheumatology, University Hospital of Wales, Heath Park , Cardiff CF14 4XZ.

Correspondence:

Dr. Malini Raychaudhuri, Specialist Registrar in Genitourinary Medicine, Cardiff Royal Infirmary, Newport Road, Cardiff - CF24 0SZ

E-mail: rcmalini@yahoo.co.uk

Tel: 02920335169

Fax: 02920487096

Word Count: Summary: 67

Case report: 828

References:164

References:7

No Conflicts of interest

Key words: systemic lupus erythematosus, disseminated gonorrhoea, hypocomplementaemia, contraception.

SUMMARY

Disseminated gonococcal infection (DGI) is an uncommon complication of acute gonorrhoea which occurs more frequently in women than in men.

Inherited complement deficiency or episodic complement deficiency in association with flare up of other diseases such as systemic lupus erythematosus (SLE) may predispose individuals to gonococcal bacteremia.

We report a case of DGI in a patient with pre-existing lupus which was initially masked by a lupus flare.

CASE REPORT

A 17-year old Caucasian female with SLE presented to the Rheumatologists feeling generally unwell for seven days following a holiday in Greece. She had painful swelling of the left wrist and ankle, sore throat, a sparsely distributed papular rash on her arms and trunk and mild erythema on her cheeks and bridge of the nose. The first episode of SLE two years previously had manifested as arthritis of wrist and proximal inter-phalangeal joints but no major organs were involved. At that time, the diagnosis had been confirmed by elevated dsDNA, 29IU/ml (<20 IU/mL); low complement C4, 0.08g/l (0.14-0.54 g/l); C3, 0.91g/l (0.75-1.65 g/l) and positive ANA (titre 1/1600).

In view of her previous history, this most recent presentation was thought to be a flare of SLE. Full blood count, urea, creatinine, electrolytes and liver function test were normal. The dsDNA was 59 IU/ml; C4, 0.07 g/l; C3, 0.90 g/l and CRP, 158 mg/l (<6 mg/l). Methotrexate, 10mg weekly and a 4 week reducing course of prednisolone from 15 mg daily was initiated in addition to her usual medications of folic acid 5 mg, hydroxychloroquine 200mg and meloxicam 15 mg daily.

Meanwhile, her male sexual partner of 2 months had been assessed for urethral discharge and dysuria by his General Practitioner. This knowledge led the Rheumatology team to refer our index patient to the Genito-urinary medicine (GUM) clinic for assessment. Between assessments at the Rheumatology and GUM clinics she developed new right knee pain and

swelling. Her other symptoms had also failed to respond to the additional immunosuppression.

On presentation at the GUM clinic she gave no history of fever, headache, chest pain, dyspnoea or worsening rash. She denied any vaginal discharge, dysuria or pelvic pain. She was using the progestogen-only contraceptive pill and had never used any barrier method of contraception.

On examination she was afebrile but had oral candidiasis. Two small centrally crusted non-pruritic maculopapular, haemorrhagic skin lesions were noted on the lower abdomen (figure1A) and right elbow (figure1B). There was also soft tissue swelling of the dorsum of the left wrist, and a tender swollen right knee with a palpable effusion and reduced range of movement. General and systemic examination was unremarkable. External genital and vaginal speculum examination looked normal.

Immediate gram staining and microscopy of urethral, cervical and vaginal slides in the clinic revealed only vaginal yeast cells. Urethral, rectal, oral and cervical swabs for gonococcal culture and a cervical swab for *Chlamydia trachomatis* for testing by nucleic acid amplification were sent. Nystatin mouth wash and clotrimazole vaginal pessaries were commenced pending laboratory results.

Urgent admission was arranged under Rheumatology. Aspirate from the right knee showed polymorphonuclear leucocytosis but no organisms on gram

stain. She was commenced empirically on intravenous cefotaxime 1g bid. At 48 hours, blood cultures showed no growth. However, the cervical swab was culture positive for *Neisseria gonorrhoea*. Culture of the knee aspirate revealed a light growth of the same. The cervical swab was positive for *Chlamydia trachomatis* by polymerase chain reaction. HIV antibody and serological tests for syphilis were negative. The chlamydial infection was treated with a single dose of azithromycin 1g. Cefotaxime was continued as the isolated gonococcus was sensitive to this. She rapidly improved over 5 days and was discharged home on oral cefixime 400mg daily for 7 days. Her partner was subsequently diagnosed with gonorrhoea and treated with single dose of cefixime 400mg and azithromycin 1g.

DISCUSSION

In patients with SLE, distinguishing disease flare up and disseminated Neisserial infection may be difficult. The initial impression of a flare of the patient's SLE was supported by the elevated dsDNA levels and hypocomplementaemia. The increased sun exposure on her foreign holiday provided a trigger for the flare up.¹ The elevated CRP, skin pustules and the inflammatory arthritis (arthritis-dermatitis syndrome) suggested a possibility of disseminated gonococcal infection, hence the benefit of initiation of antibiotic therapy prior to the confirmation of culture results. An elevated CRP is an uncommon finding during flares of lupus without serositis.

In a case series of SLE patients with disseminated neisserial infection, those affected tended to be young female patients on oral steroids with

hypocomplementaemia and renal involvement .² The underlying hypocomplementaemia of active SLE can be worsened during flare ups by increased complement consumption³ and high levels of immunosuppression, in particular high dose corticosteroids.⁴ Deficiency of the components of the complement cascade and impaired clearance of immune complexes by the reticuloendothelial system, leads to decreased effectiveness of bacteriolysis and opsonization.⁵ This further predisposes patients to bacterial infection,² including sexually transmissible infections for which sexually active young people have the highest risk.

The prevalence of hypocomplementaemia in patients presenting with disseminated gonococcal disease is reported to be higher than in the general population, suggesting that such patients should be screened for complement deficiency and SLE.⁶

Though barrier methods were the most popular contraceptive choice in patients with SLE, only 29% were reported as actually using condoms.⁷ Improved awareness of this particular sexual health risk in these patients is important for GUM physicians and Rheumatologists alike.

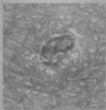
References

- 1) T Hasan, M Pertovaara, U Yli-Kerttula, T Luukkaala, M Korpela
Seasonal variation of disease activity of systemic lupus erythematosus
in Finland: a 1 year follow up study. *Ann Rheum Dis.* 2004;
63(11):1498-500.
- 2) Mitchell S R, Nguyen P Q, Katz P. Increased risk of neisserial
infections in systemic lupus erythematosus. *Seminars in arthritis and
rheumatism* 1990; 20(3): 174-184.
- 3) Truedsson L, Bengtsson AA, Sturfelt G. Complement deficiencies and
systemic lupus erythematosus. *Autoimmunity.* 2007; 40(8): 560-6.
- 4) Nived O, Sturfelt G, Wolheim F; Systemic lupus erythematosus and
infection: A controlled and prospective study including an
epidemiological group. *Q J Med.* 1985; 218: 271-287.
- 5) Walport MJ. Complement deficiency and disease. *Br J Rheumatol*
1993; 32: 269-73
- 6) Ellison RT 3rd, Curd JG, Kohler PF, Reller LB, Judson FN. Underlying
complement deficiency in patients with disseminated gonococcal
infection. *Sex Transm Dis.* 1987; 14(4): 201-4.
- 7) Julkunen HA, Kaaja R, Friman C. Contraceptive practice in women with
systemic lupus erythematosus; *Br J Rheumatol.* 1993; 32(3): 227-30.

Figure Legend.

Figure 1. Small centrally crusted maculopapular, haemorrhagic skin lesions of DGI on left lower abdomen (A) and right elbow (B).

A



B

