



HAL
open science

Long-term outcome of lesional posterior cortical epilepsy surgery in adults

Alaa Eldin Elsharkawy, Nasser M F El-Ghandour, Heinz Pannek, Falk Oppel, Friedrich G Woermann, Mohamed Nayel, Matthias Hoppe, Reinhard Schulz, Ahmed Issa, Alois Ebner

► To cite this version:

Alaa Eldin Elsharkawy, Nasser M F El-Ghandour, Heinz Pannek, Falk Oppel, Friedrich G Woermann, et al.. Long-term outcome of lesional posterior cortical epilepsy surgery in adults. *Journal of Neurology, Neurosurgery and Psychiatry*, 2009, 80 (7), pp.773. 10.1136/jnnp.2008.164145 . hal-00552732

HAL Id: hal-00552732

<https://hal.science/hal-00552732>

Submitted on 6 Jan 2011

HAL is a multi-disciplinary open access archive for the deposit and dissemination of scientific research documents, whether they are published or not. The documents may come from teaching and research institutions in France or abroad, or from public or private research centers.

L'archive ouverte pluridisciplinaire **HAL**, est destinée au dépôt et à la diffusion de documents scientifiques de niveau recherche, publiés ou non, émanant des établissements d'enseignement et de recherche français ou étrangers, des laboratoires publics ou privés.

Long-term outcome of lesional posterior cortical epilepsy surgery in adults

Authors' names and affiliations

- Alaa Eldin Elsharkawy, MSc, MD, 1 & 3
- Nasser: M. F. El-Ghandour, MD, PhD, 3
- Falk Oppel, MD, PhD, 2
- Heinz Pannek, MD, 2
- Reinhard Schulz, MD, 1
- Matthias Hoppe, MD, 1
- Friedrich G. Woermann MD 4
- Mohamed Nayel, MD, PhD, 3
- Ahmed Issa, MD, PhD, 3
- Alois Ebner, MD, 1

1- Department of Presurgical Evaluation, Bethel Epilepsy Centre, Germany

2- Neurosurgical Department, Bethel Epilepsy Centre, Germany

3- Neurosurgical Department, Cairo University, Cairo, Egypt

4- MRI Unit, Bethel Epilepsy Centre, Germany

Corresponding Author: Dr. Alois Ebner

Phone: +49+52177278870

Fax: +49+52177278872

Email: alois.ebner@mara.de

Address: Klinik Mara, Maraweg 21, 33617 Bielefeld, Germany

Running Title: Long-term outcome of lesional PCEs

Key Words: Epilepsy surgery, posterior cortical epilepsies, outcome, lesional

Abstract

Objective: The aim of this study was to evaluate the short and long-term seizure outcome and to find predictors of outcome after epilepsy surgery in lesional posterior cortical epilepsies (PCEs).

Methods: We retrospectively studied the operative outcome in 80 consecutive adult patients with lesional PCEs who underwent resective surgery for intractable partial epilepsy between 1991 and 2006.

Results: The probability of remaining in Engel Class I was 66.3% (95% CI 60-72) at 6 months, 52.5% (95% CI 47-57) at 2 years, 52.9% (CI 45-59) at 5 years, and 47.1% (CI 42-52) at 10 years. Factors predicting poor outcome were the presence of a somatosensory aura, extra-regional spikes, incomplete resection, interictal epileptiform discharge (IED) in EEG 6 months and 2 years postsurgery, history of generalized tonic-clonic seizure (GT-CS) and the presence of focal cortical dysplasia in the resected specimen. Factors predicting good outcome were childhood onset of epilepsy, short epilepsy duration, ipsilateral spikes, visual aura, presence of well-circumscribed lesion in preoperative MRI, and a pathologically defined tumour. In the multivariate analysis, predictors were different in long and short term as follows: incomplete resection as proven by postoperative MRI (HR 2.059 (CI 1.195-3.673) predicts seizure relapse in short-term follow-up. The presence of IED in the EEG performed 6 months after surgery (HR 2.3 (CI 1.128 -4.734) predicts seizure relapse in the long-term follow-up. However, the absence of a history of GT-CS independently predicts seizure remission in short and long-term follow-up.

Conclusions: Surgery in PCEs proved to be effective in short and long-term follow-up. Lesional posterior cortical epilepsy may be a progressive process in a substantial number of cases.

Introduction

Posterior cortex epilepsies (PCEs) encompass a group of epilepsies originating from the occipital, parietal, or occipital border of the temporal lobe, or from any combination of these regions. As no clear anatomic or neurophysiological distinctions are apparent between posterior cortical areas, epilepsies originating from these areas are probably better analyzed and understood when grouped together.[2-4] Surgery is becoming increasingly popular in PCE patients and superiority of surgical treatment has been proved.[5,6]

PCEs are not well studied in the literature. Previous reports of PCEs included a small number of surgical patients [2], only a subgroup of PCEs was studied,[7] and they included only occipital lobe[5,8] or parietal lobe[9]. Some previous studies merely focused on the surgical technique in PCEs,[10] and most of them included only short-term follow-up results.[1]

In a meta-analysis of studies of long-term outcome after epilepsy surgery, the incidence of parietal and occipital epilepsy surgery was very minimal, each constituting only 1%. [11] No reports were found addressing the long-term outcome in lesional PCEs. Moreover, some studies that have been published included heterogeneous groups of patients (adults and pediatrics), and combined both lesional and non-lesional epilepsy.[2] Available data concerning the predictors of outcome and AEDs after surgery in these groups are limited.[2] Therefore, reports especially addressing surgical outcome for lesional PCEs are still necessary.

We present the first longitudinal study in the literature reporting the outcome in adult patients with lesional PCEs. The aim of this study was to evaluate the short and long-term outcome and to find predictors of the outcome taking into consideration the above-mentioned problems.

Clinical material and methods

We retrospectively reviewed the records of all adult patients (16 years of age and older) who underwent posterior cortical epilepsy (PCE) surgery at the Epilepsy Centre Bethel in Bielefeld, Germany, within the period from 1991 to 2006. Here we found 97 consecutive patients who had undergone PCE surgery and were followed up for more than 2 years. We excluded patients who only had biopsies, patients without a lesion in preoperative MRI or who had resected specimens, as well as patients who had surgery performed due to recurrent malignant tumours. This left 80 patients who met the inclusion criteria.

Patient characteristics

Of the 80 patients included in our study, 44 were male (55%) and 36 female (45%). The mean age at epilepsy onset was 11.9 years (range 0.08-49 years), the mean age at epilepsy surgery was 29.5 years (range 16-54 years), the mean duration of epilepsy was 17.5 years (range 1-44 years), and the mean follow-up duration was 7.3 years (range 2-16 years). Seventy patients (87.5%) had auras: 29 (36.3%) had visual auras, 14 (17.5%) had somatosensory auras, 12 (15%) had psychic auras. There were 7 patients (8.85) who had gustatory auras, 8(10%) had auditory auras 10 (12.5) had unspecific auras and 10 patients had more than one type of aura. We recorded psychomotor seizures in 49 patients (61.3%), tonic seizures in 16 patients (20%), clonic seizures in 11 patients (13.8%), hypermotor seizures in 7 patients (8.8%) and absence-like seizures in 7 patients (8.8%). The clinical characteristics of these patients are detailed in table 1.

Table 1: patient characteristics

Variable	Male	Female	Total
Mean age at epilepsy onset (years)	10.8 ±8.0	13.2±13	11.9±10.6
Mean age at epilepsy surgery (years)	28.6±9.5	30.7±11	29.5±10.2
Mean duration of epilepsy (years)	17.6±10.2	17.5±10.4	17.5±10.2
Mean follow-up duration (years)	7.6±4.2	7.4±3.5	7.3±3.9
Pathology			
Tumours	16(36.4%)	13(36.1%)	29(36.3%)
most frequent tumours			
DNT grade I WHO	6(13.6%)	2(5.6%)	8(10%)
ganglioma grade I	3(6.8%)	5(13.9%)	8(10%)
astrocytoma grade II WHO	4(9.1%)	2(5.6%)	6(7.5%)
FCD	12(27.3%)	12(33.3%)	24(30%)
Vascular	6(13.6%)	7(19.4%)	13(16.3%)
Gliosis	8(18.2%)	3(8.3%)	11(13.8%)
Inflammation	0	1(2.8%)	1(1.3%)
Others	2(4.5%)	0	2(2.5%)
Dual pathology	4(9.1.0%)	5(13.9%)	9(11.3%)
Predisposing factors			
History of CNS infection	2(4.5%)	1(2.8%)	3(3.8%)
History of head trauma	2(4.5%)	1(2.8%)	3(3.8%)
History of prenatal infarction	2(4.5%)	5(13.9%)	7(8.8%)

EEG and MRI characteristics

In non-invasive EEG recordings, abnormalities were most prominent over posterior cortical regions even though diffuse changes were frequent. In 23 patients (28.8%) interictal epileptiform discharges were restricted to the suspected area of the epileptic focus. However, in 11 patients (13.8%) we did not detect any interictal epileptiform discharges (IED). Generalized spikes were detected in 7 patients (8.8%) ([Generalized spikes in this study means bilateral synchronous discharges which did not show preceding focal activity](#)) and in another 21 patients (26.3%) there were contralateral IED. In 45 patients (56.3%) EEG seizure onset was localized to the lesion region, and 25 patients (31.3%) were classified as having multiregional EEG seizure onset. In 10 patients (12.5%) there were no seizure patterns in the EEGs.

In follow-up EEGs performed six months after epilepsy surgery, interictal epileptiform discharges were detected in 23 patients (28.8%). All our patients had a suspected structural abnormality in preoperative MRI and pathological findings in the resected specimen. The postoperative control MRI showed that resection was complete in 47 patients (58.8%). In 32 patients (40%) the resection was deemed incomplete, and data were missing in 1 patient (1.2%). Pre- and postoperative differences as seen on EEG and MRI finding are shown in table 2.

Preoperative evaluation

All patients underwent presurgical evaluation at the Epilepsy Centre Bethel in Bielefeld, Germany, following the local protocol, which includes EEG-video monitoring, high resolution MRI, neuropsychological testing, ophthalmological assessment (perimetry) and, if necessary, additional optional imaging including PET and SPECT. To display speech and motor functions, functional MRI and/or the intracarotid amobarbital test (Wada test) were used. Invasive monitoring using subdural grids was performed in 28 patients (35%).

Lesions have been categorized into well-circumscribed lesions or less-well-circumscribed lesions based on the MRI shape of the lesions. For all patients, preoperative MRI was reevaluated visually in the case conference by two epileptologists and an epilepsy neurosurgeon to determine whether the appearance of a lesion was well circumscribed or less well circumscribed.

Table 2: Pre and postoperative MRI and EEG

	non-seizure free	seizure free	Sig.,
Spikes in interictal EEG			0.612
Absent	5(45.5%)	6(54.5%)	
Present	31(44.9%)	38(55.1%)	
Generalized spikes			0.387
Absent	32(43.8%)	41(56.2%)	
Present	4(57.1%)	3(42.9%)	
Contralateral spikes			0.488
Absent	26(44.1%)	33(55.9%)	
Present	10(47.6%)	11(52.4%)	
Extra-regional spikes			0.038
Absent	14(34.1%)	27(65.9%)	
Present	22(56.4%)	17(43.6%)	
Ictal rhythm			0.504
Absent	4(40%)	6(60%)	
Present	32(45.7%)	38(54.3%)	
Ipsilateral ictal EEG seizure pattern			0.106
Absent	19(54.3%)	16(45.7%)	
Present	17(37.8%)	28(62.2%)	
Multiple EEG seizure types			0.058
Absent	21(38.2%)	34(61.8%)	
Present	15(60%)	10(40%)	
Preoperative MRI			0.159
Well-circumscribed	18(39.1%)	28(60.9%)	
Less well-circumscribed	18(52.9%)	16(47.1%)	
Post operative MRI			0.007
Incomplete resection	20(62.5%)	12(37.5%)	
Complete resections	15(31.9%)	32(68.1%)	
EEG 6 months postoperative			0.009
IED absent	20(35.7%)	36(64.3%)	
IED present	15(68.2%)	7(31.8%)	
EEG 2 years postoperative			0.019
IED absent	19(36.5%)	33(63.5%)	
IED present	14(66.7%)	7(33.3%)	

Surgical procedure and postoperative evaluation

All patients underwent resective epilepsy surgery, namely lesionectomy, cortical resections, lobectomies and lesionectomy with multiple subpial transections (MST), all of which were restricted to the posterior cortical area. The type of surgery, extent of resection areas and side of operation are shown in table 3.

Intraoperative electrocorticography (ECoG) was performed routinely in the majority of patients. Sometimes somatosensory evoked potential (SSEP) was used intraoperatively. Following our local protocol, postoperative follow-up examinations took place for all patients 6 months and 2 years after surgery including EEG, MRI, neurological and psychological evaluation. After the 2-year visits, a special

questionnaire was sent to all patients assessing the seizure situation and quality of life at 3, 5, 10 and 15 years.

Data collection

Information on the variables we intended to investigate was provided either from data in the patients' charts (age, gender, age at epilepsy onset, various risk factors, preoperative seizure semiology, and pathological reports) or electronically from the EDP system of the hospital (EEG-video monitoring, side of surgery, intraoperative and early postoperative complications). Moreover, we reviewed the answers to the questionnaires mailed to the patients and drew information from telephone calls that had been made as a part of the postoperative follow-up programme. For patients with intellectual impairments or psychic disorders, information was usually provided by their family members. We excluded patients who did not complete their 2-year checkups (most of these were from outside Germany). The data for long-term outcome was not available for 5 patients (6.3%).

Table 3: Resection area, type of surgery and side of the operation

Variable	Male	Female	Total
Resection area			
Occipital	6(13.6%)	3(8.3%)	9(11.3%)
Parietal	3(6.8%)	6(16.7%)	9(11.3%)
Temporo-occipital	24(54.5%)	12(33.3%)	36(45%)
Temporo-parietal	5(11.4%)	6(16.7%)	11(13.8%)
Parieto-occipital	5(11.4%)	6(17.6.6%)	11(13.8%)
Temporo-parieto-occipital	1(2.3%)	3(8.8%)	4 (5.0%)
Type of surgery			
Lesionectomy	38(86.4%)	27(75%)	65(81.3%)
Cortical resection	2(4.5%)	4(11.1%)	6(7.5%)
Lobectomy+ MST	3 (6.5%)	3(8.8%)	6(7.5%)
Multilobar resection	1(2.3%)	2(5.6%)	3(3.8%)
Side of operation			
Right	19(43.2%)	22(61.1%)	41 (51.3%)
Left	25(56.8%)	14(38.9)	39(48.8%)

Evaluation of outcome

Outcome was evaluated using modified Engel seizure classification [12]. Patients in Engel Class 1 were considered seizure free. Seizures that occurred within 1 month after surgery were not included in this analysis. Seizure types were

classified according to the semiological seizure classification suggested by Lüders et al., 1998.[13] Our protocol for antiepileptic drug (AED) withdrawal was as follows: Patients generally continued on their preoperative levels of AEDs for 2 years after surgery. If they remained seizure free and if the patient wished to discontinue medication, AEDs was systematically reduced. If the patient had a seizure during AED withdrawal, AEDs were restarted. However, many seizure-free patients refused to stop taking AEDs. Dual pathology was diagnosed if the resected specimen contained two different pathologies.

Statistical analysis

Due to the wide range of 2-14 years in following up these patients, time-to-event and Kaplan-Meier methods were used to estimate the probability of remaining in Class I as a function of time. Cox Multivariate Stepwise Logistic Regression Analysis was used to estimate hazard ratios and 95% CIs for each risk factor concerned. We reported seizure recurrence by obtaining survival estimates at 0.5, 2, 5, and 10 years after surgery. Univariate analysis was used to detect the factors affecting the long-term outcome and stepwise logistic regression was used to evaluate the predictors.

Results

Overall outcome

The majority of seizure recurrences took place during the first 2 years after surgery. Overall, 42 out of 80 patients were seizure-free 2 years after surgery. The number of patients in each Engel Class is summarized in table 4.

The probability of remaining in Class I was 66.3% (95% CI 60-72) at 6 months, 52.5% (95% CI 47-57) at 2 years, 52.9% (CI 45-59) at 5 years, and 47.1% (CI 42-52) at 10 years. The rate of Class I outcome remained 47% for the 34 patients with more than 10 years of follow-up.

Regarding Engel 1a outcome (completely seizure free), 47 patients (58.8%) were in Engel 1a at the 6-month follow-up, 37(46.3%) at 2 years, 29 (41.1%) at 5 years, and 14 (41.2%) at the 10-year follow-up.

Table 4: Number of patients and percentage in each Engel Class, whole sample, tumours FCD and vascular lesions

Outcome	6 months	2 years	5 years	10 years
Engel Class 1	53(66.3%)	42(52.5%)	37(52.9%)	16(47.1%)
Engel Class 2	6(7.5%)	16(20%)	14(17.5%)	10(29.4%)
Engel Class 3	13(16.3%)	10(12.5%)	10(12.5%)	4(11.8%)
Engel Class 4	8(10%)	12(15%)	9(11.3%)	4(11.8%)
Number of patients and percentage in each Engel Class in patients with tumours				
Engel Class 1	22(75.9%)	21(72.4%)	18(78.3%)	
Engel Class 2	1 (3.4%)	4 (13.8%)	2 (8.7%)	
Engel Class 3	5 (17.2%)	2 (6.9%)	2 (8.7%)	
Engel Class 4	1 (3.4%)	2 (6.9%)	1 (4.3%)	
Number of patients and percentage in each Engel Class in patients with FCD				
Engel Class 1	13(50.0%)	8(30.8%)	9(39.1%)	
Engel Class 2	3(11.5%)	7(26.9%)	4(17.4%)	
Engel Class 3	5(19.2%)	4(15.4%)	4(17.4%)	
Engel Class 4	5(19.2%)	7(26.9%)	6(26.1%)	
Number and percentage in patients with vascular lesion				
Engel class 1	10(76.9%)	8(61.5%)	4(36.4%)	
Engel class 2	1(7.7%)	3(23.1%)	5(45.5%)	
Engel class 3	2(15.4%)	0	0	
Engel class 4	0	2(15.4%)	2(18.2%)	

Recurrence after surgery

In our study 37 patients had a relapse of seizures postsurgically. Twenty-seven patients relapsed within the first 2 years, 10 patients (27%) relapsed later than 2 years. The greatest risk of recurrence (73%) was in the first 2 years after surgery. If the patient was seizure free at the 2-year follow-up, the probability of remaining seizure free up to 10 years was 70% (95% CI 65-75). The greatest risk of recurrence was among patients with FCD with an estimated risk of recurrence 2.3 times higher (95%CI 1.173-4.545).

Outcome in relation to pathological findings

Among the cohort in whom FCD was diagnosed, the likelihood of remaining in Class I after 0.5, 2, and 5 years was 50% (95% CI 45–55%), 30.8% (CI 28–30%), and 39.1% (CI 35–44%) respectively.

In the group with tumours, the likelihood of being in Engel Class I was 75.9% (95% CI 72–78%) at 6 months, 72.4% (CI 68–76%) at 2 years and 78.3% (CI 70–86%) at 5 years. Table 4 shows the number and percentages of Engel Class 1 as compared to Classes 2, 3 and 4. Among tumour subtypes the best outcome was observed in patients with DNT WHO grade I and ganglioma grade 1. There were 8 patients with DNT WHO grade I, 7(87.5%) of them were in remission after surgery. The same results were found among patients with ganglioma grade 1 where 6 of 7 were in

remission over the whole period of follow-up. There was a significant difference among patients in relation to the type of tumour pathology ($p=0.003$).

Outcome in relation to resection area

Patients who had surgery in the temporo-occipital and temporo-parietal areas had the highest rate of seizure freedom, and patients who were operated on in the parietal lobe had the lowest rate of seizure freedom, but there was only a slight significant difference in outcome ($p= 0. 053$).

In the group with temporo-occipital resections, the likelihood of being in Engel Class I was 52.8% (95% CI 46–58%) at 2 years and 56.3% (CI 50–62%) at 5 years. However, in the group with temporo-parietal resections, the probability of Engel Class 1 was 81.8% (95% CI 80–90%) and 72.7 % (95% CI 67–77%) at 2 and 5 years respectively. In temporo-parietal resections group 7/11 (64%) of the operations were done in non-dominant hemisphere

There was no significant difference between patients who had a temporal resection as part of surgery and patients who had PCEs without temporal lobe resection ($p=0.217$). The estimated risk of being non-seizure free in patients without temporal resection was 1.3 (95% CI 0.762–2.407) times higher.

Antiepileptic drug withdrawal

Fifteen patients (18.75%) were withdrawn from antiepileptic drugs. In the interval between 2 and 5 years follow up 2 patients (2.5%) had seizure with AEDs withdrawal, AEDs restarted again, both of them have controlled again with AEDs.

There was a low risk of recurrence during withdrawal with an estimated risk ratio of 1.02 (95%CI 0.53-2.88). Patients with cavernomas fared best with AED withdrawal.

Predictors for outcome (univariate analysis)

A favourable outcome was correlated with childhood epilepsy onset, short preoperative epilepsy duration, ipsilateral spikes, a visual aura, the presence of well-circumscribed lesion in preoperative MRI, and a tumour in the resected specimen (p -value <0.05). Presence of somatosensory aura, extra-regional spikes, incomplete resection, IED in EEG at 6 months and 2 years after surgery, GTCS during video EEG monitoring and the presence of FCD in the resected specimen correlated to

unfavourable outcome. Table 5 shows the factors which have importance in the univariate analysis.

Multivariate analysis

Variables that were significant in univariate analysis were investigated by using Cox Stepwise Logistic Regression. This showed that in short-term outcome (2-5 years' follow-up) incomplete resection as documented by postoperative MRI independently predicts seizure relapse (HR 2.059 (CI 1.195-3.673); p-values were 0.007, and 0.024 at 2 years and 5 years respectively, and 0.437, 0.286 and 0.057 at 10 years, 16 years and the last follow-up visit respectively). However, in long-term outcome (6-16 years), the presence of IED in EEG 6 months after surgery predicts seizure relapse, HR 2.3 (CI 1.128 -4.734). The absence of a history of generalized tonic-clonic seizure independently predicts seizure remission. Figure 1, 2, and 3

Among patients with IED 6 months after surgery, 70% were non-seizure free at 5 years, 71.4% at 10 years and 100% at follow-ups of more than 10 years.

Table 5: univariate and multivariate analysis showing the significance, hazard ratio and confidence intervals of the variable related to the outcome

Univariate	Sig.	HR	95.0% CI	
Age at epilepsy onset	0.039	31.492	1.182	838.788
Epilepsy duration	0.004	0.205	0.069	0.603
Age at epilepsy surgery	0.003	4.862	1.700	13.900
Extra-regional spike	0.016	0.192	0.036	1.01
Ipsilateral spike	0.07	0.067	0.007	0.606
Visual aura	0.025	9.134	2.262	36.887
Somatosensory aura	0.000	7.149	1.065	46.216
GTCS	0.027	0.141	0.025	0.804
Preoperative MRI	0.001	0.24	0.064	0.891
Invasive	0.013	15.46	1.795	133.162
Resection area	0.000	3.38	1.64	5.24
Tumour	0.00	0.18	0.000	0.41
FCD	0.00	0.377579	0.000	0.71
Postoperative MRI	0.000	3.556	1.385	9.152
EEG 2 years postoperative	0.008	2.22	0.6	7.20
EEG 6 months postoperative	0.019	1.5	0.4	5.38
Multivariate analysis (short-term)				

Incomplete resection in Postoperative MRI	0.007	2.059	1.195	3.673
EEG 6 months after surgery	0.009	4.051	1.418	11.574
Multivariate analysis (long-term)				
Absence of history of GTCS	0.001	3.240	1.633	6.430
EEG 6 months after surgery	0.036	0.465	0.232	0.931

Complications

Eleven patients (13.75%) had unexpected complications as a result of surgery, three of them (3.7%) had permanent complications and in 8 patients (10%) the complications were transient. Among the permanent complications 2 patients developed permanent pareses, and one patient had a visual field defect. Four patients developed transient pareses which could be successfully treated. Two patients developed subdural haematomas which were resolved conservatively without the need for any surgical interference. One patient developed postoperative wound infection and one patient developed facial paralysis. Moreover, 4 patients had contralateral sensory deficits; all of them had resections involving parietal structures. These sensory deficits did not lead to a significant impairment of the patients' daily activities and were not considered to be significant complications. Visual field defects were only taken into consideration in unexpected cases.

Discussion

Overall outcome

We present the first longitudinal study addressing the long-term outcome of epilepsy surgery for lesional PCEs. Our results showed that the long-term favourable outcome after surgery of lesional PCEs is 47%. This study confirms and extends the reliability of the 2-year follow-up as a predictor for long-term outcome. Several reports have published the long-term outcome after epilepsy surgery in posterior cortex. Two articles have reported the long-term outcome in the occipital and parietal lobes.[5,14]

In general, outcome in short and long-term follow-up was in the large range of 23-85%,[2,7,9,16-19] making comparison difficult. Variations are attributed to considerable differences in follow-up periods, varying from 0.3 to 61 years:[5] different outcome classifications,[18] the fact that old reports included patients evaluated before the availability of high resolution MRI:[9,18] some studies partly

focused on particular subgroups,[7] although most studies included heterogeneous groups of pathological entities; and surgical techniques often changed over time, reflecting the state of the art and different surgeons' individual preferences.[19] Moreover, all previous studies were cross-sectional and carried out using limited statistical tools.[17]

Factors related to outcome

Our results are concordant with others: there was a correlation of good outcome with early surgery,[2] short duration of epilepsy.[20] visual aura, EEG epileptic activity arising from the site of resection[1,20] and the lack of an extralesional or generalized EEG seizure pattern.[21] We also found that seizure outcome was significantly associated with etiology, that outcome was poor in FCD and tumours fared significantly better than other lesions.[22]

Some authors reported a high seizure-freedom rate after FCD but most of these studies included a combination of temporal and extratemporal patients as well as both pediatric and adult patients.[23] Many investigators have shown that the postoperative outcome in pediatric series is consistently better than in adult series of FCD-patients.[24]

The unfavourable outcome in patients with FCD may be due to widespread pathological findings going beyond the MRI identified changes a different subtype of the FCD, and the extension of the epileptogenic zone beyond the lesional pathology[25]

Like others, we found that the presence of a preoperative well-circumscribed lesion is associated with good outcome. Poor surgical outcome is associated with extralesional EEG seizure pattern and the presence of interictal epileptiform discharges extending beyond the area of resection [26].

Electrocorticography

In our analysis, application of ECoG was not a predictor of outcome. In all cases our neurosurgeon planned the resection based on preoperative MR imaging and the preoperative EEG findings. The second step of planning was based on the

intraoperative ECoG results sometimes leading to a more extended resection when dense epileptiform activity occurred.

Predictors for short-term and long-term follow-ups

In our series, the absence of a history of GTCS and incomplete resection in postoperative MRI independently predicted the short-term outcome. However, the absence of a history of GTCS and IED in EEG at the 6-month follow-up predicted the long-term outcome. The absence of a history of GTCS is the most important predictor for long-term surgical outcome. This difference between the short-term and long-term predictors has been reported in temporal lobe epilepsy with HS.[27] Our results showed the same difference after lesional PCE surgery. In our study, postoperative MRI independently predicts the outcome in the short-term follow-up.

Previous publications demonstrated that partial excision of the lesion is associated with a worse outcome compared with a total excision.[28] In some studies, extension of resection predicted the outcome.[1,14] Controversially, others reported that total lesionectomy does not predict the outcome.[24]

In our series, the outcome is clearly better in patients with a complete resection of the lesion, but completeness of resection for the preoperative MRI lesion cannot explain the fact that 12 patients (37.5%) achieved a seizure-free state despite incomplete resection, while 15 patients (31.9%) did not become seizure free despite the completeness of their resection as proven by postoperative MRI. The p-value was significant in the short term (0.007) but not in long-term follow-up (0.437).

Incomplete resection may be due to location of the lesion beside or within the functional area; 6 of our patients had additional MST but it failed to control the seizure.[29] The possibility remains that even standard high-resolution MRI may fail to reveal the entire extent of some lesions like FCD or residual microscopic lesions, accounting for persistent seizures arising adjacent to an apparently completely removed lesion as judged by pre- and postoperative MRI.[30] Perceived complete resection, in fact, does not necessarily mean complete resection of all the pathology present.[16] The possibility that a structural lesion may be unrelated to the epilepsy must also be taken into consideration. Scalp EEG may give a misleading impression as to the location of the source of the epileptiform activity.[31] This was suggested in a report of excision of the focus contralateral to the lesion in the case of frontal lobe epilepsy. [30]

Epileptogenicity of the lesion due to the alterations in neuronal structure and functions is probably a progressive process and it does not necessarily stop when spontaneous seizures appear. [31,32] There are frequent examples of epileptogenic zones that shrink or disappear with maturation. A progressive extension of the epileptogenic zone over time can also be observed.[33] The definition of the epileptogenic zone has been modified to explain both completeness and incompleteness of resection, that seizure freedom could be achieved when the resection includes “the minimum amount of cortical tissue that must be resected to produce seizure-freedom”. It does not mean that the resection of the complete preoperative MRI lesion produces seizure-freedom.[32] Our findings showed that completeness of resection is not a reliable predictor for long-term outcome.

Postoperative EEG

IED present in the EEG 6 months after surgery independently predicts seizure relapse in the long-term outcome. It is interesting that the majority of patients who had epileptogenic activities in the EEG at the 6-month follow-up relapsed after 2 years' follow-up. The role of EEG after surgery of occipital lobe epilepsy has been reported. It has been found that inactive postoperative scalp EEG predicts a better surgical outcome.[5,34,35] Postoperative routine EEG is a good prognostic investigation for the prediction of long-term seizure outcome.[36,37] In frontal lobe epilepsy we found that the presence of IED at EEG 6 months after surgery is correlated with a poor outcome.[36,37] After temporal lobe epilepsy, postoperative ipsilateral EEG spikes over the resected side was associated with long-term worsening.[36]

One study reported that EEG performed a few months after epilepsy surgery is not a useful predictor for long-term seizure outcome.[38] This report studied temporal resection in heterogeneous group of patients, followed by EEGs that were carried out 2 and 4 months after the surgery. Our results confirm and extend this observation for the role of EEG after surgery as a predictor for the outcome. IED in the EEG 6 months after surgery is a sign of the ability of the epileptogenic zone to rebuild itself and generate seizures again, or the ability to reactivate the pace-makers and/or activate the epileptogenic network.[39] This may be a time-dependent process and explain why EEG showing IED 6 months after surgery is more predictive for long-term outcome.

Tonic-clonic seizure

The absence of a history of GTCS independently predicts short and long-term seizure remission. It is the most powerful predictor in our study. This result has also been shown in a multi-centre study in temporal epilepsy where it was the only predictor of 2-year remission.[40] In frontal lobe epilepsy, it has been found that secondarily generalized seizures are risk factors for poor surgical outcome.[35] We assume that the absence of tonic-clonic seizures indicates that the spread of focal activity is inhibited to other areas and /or that the epileptogenic network is limited to a focal area.

Conclusions

Our study supports the effectiveness of surgery in PCEs in short and long-term follow-up with seizure freedom rates of 47% up to 10 years, with low risks of permanent neurologic complications. The study confirms and extends the reliability of seizure outcome at the 2-year follow-up in predicting seizure outcome after lesional PCEs for long-term follow-up. Completeness of the resection by postoperative MRI and the absence of a history of GTCS predict the short-term outcome. Moreover, the absence of a history of GTCS and postoperative EEG predicts long-term outcome after epilepsy surgery.

Two main points can be concluded from our study. First, predictors in the short term are not the same as in the long-term outcome, which means that lesional epilepsy is a dynamic process in a substantial numbers of cases. Remission or relapses after surgery depend on the ability of surgical interference to stop this dynamic process. The second point is that etiology and the type of lesion play an important role in determining the seizure outcome after surgery.

References

1. Blume WT, Whiting SE, Girvin JP: Epilepsy surgery in the posterior cortex. *Ann Neurol* 1991;29:638-645.
2. Dalmagro CL, Bianchin MM, Velasco TR, Alexandre V, Jr., Walz R, Terra-Bustamante VC, Inuzuka LM, Wichert-Ana L, Araujo D, Jr., Serafini LN,

- Carlotti CG, Jr., Assirati JA, Jr., Machado HR, Santos AC, Sakamoto AC: Clinical features of patients with posterior cortex epilepsies and predictors of surgical outcome. *Epilepsia* 2005;46:1442-1449.
3. Sveinbjornsdottir S, Duncan JS: Parietal and occipital lobe epilepsy: A review. *Epilepsia* 1993;34:493-521.
 4. Kim SK, Lee DS, Lee SK, Kim YK, Kang KW, Chung CK, Chung JK, Lee MC: Diagnostic performance of [18f]fdg-pet and ictal [99mtc]-hmpao spect in occipital lobe epilepsy. *Epilepsia* 2001;42:1531-1540.
 5. Salanova V, Andermann F, Olivier A, Rasmussen T, Quesney LF: Occipital lobe epilepsy: Electroclinical manifestations, electrocorticography, cortical stimulation and outcome in 42 patients treated between 1930 and 1991. Surgery of occipital lobe epilepsy. *Brain* 1992;115 (Pt 6):1655-1680.
 6. Kim CH, Chung CK, Lee SK, Lee YK, Chi JG: Parietal lobe epilepsy: Surgical treatment and outcome. *Stereotact Funct Neurosurg* 2004;82:175-185.
 7. Aykut-Bingol C, Spencer SS: Nontumoral occipitotemporal epilepsy: Localizing findings and surgical outcome. *Ann Neurol* 1999;46:894-900.
 8. Blume WT, Wiebe S, Tapsell LM: Occipital epilepsy: Lateral versus mesial. *Brain* 2005;128:1209-1225.
 9. Salanova V, Andermann F, Rasmussen T, Olivier A, Quesney LF: Parietal lobe epilepsy. Clinical manifestations and outcome in 82 patients treated surgically between 1929 and 1988. *Brain* 1995;118 (Pt 3):607-627.
 10. Daniel RT, Meagher-Villemure K, Farmer JP, Andermann F, Villemure JG: Posterior quadrant epilepsy surgery: Technical variants, surgical anatomy, and case series. *Epilepsia* 2007;48:1429-1437.
 11. Tellez-Zenteno JF, Dhar R, Wiebe S: Long-term seizure outcomes following epilepsy surgery: A systematic review and meta-analysis. *Brain* 2005;128:1188-1198.
 12. Engel J, Van Ness P, Rasmussen T: Outcome with respect to epileptic seizures; in Engel J (ed *Surgical treatment of the epilepsies*. New York, Raven Press, 1993, pp 609-621.
 13. Lüders H, Acharya J, Baumgartner C, Benbadis S, Bleasel A, Burgess R, Dinner DS, Ebner A, Foldvary N, Geller E, Hamer H, Holthausen H, Kotagal P, Morris H, Meencke HJ, Noachtar S, Rosenow F, Sakamoto A,

- Steinhoff BJ, Tuxhorn I, Wyllie E: Semiological seizure classification. *Epilepsia* 1998;39:1006-1013.
14. Aykut-Bingol C, Bronen RA, Kim JH, Spencer DD, Spencer SS: Surgical outcome in occipital lobe epilepsy: Implications for pathophysiology. *Ann Neurol* 1998;44:60-69.
 15. Elsharkawy AE, Behne F, Oppel F, Pannek H, Schulz R, Hoppe M, Pahs G, Gyimesi C, Nayel M, Issa A, Ebner A: Long-term outcome of extratemporal epilepsy surgery among 154 adult patients. *J Neurosurg* 2008;108:676-686.
 16. Zentner J, Hufnagel A, Wolf HK, Ostertun B, Behrens E, Campos MG, Elger CE, Wiestler OD, Schramm J: Surgical treatment of neoplasms associated with medically intractable epilepsy. *Neurosurgery* 1997;41:378-386; discussion 386-377.
 17. Williamson PD, Thadani VM, Darcey TM, Spencer DD, Spencer SS, Mattson RH: Occipital lobe epilepsy: Clinical characteristics, seizure spread patterns, and results of surgery. *Ann Neurol* 1992;31:3-13.
 18. Rasmussen T: Surgery for central, parietal and occipital epilepsy. *Can J Neurol Sci* 1991;18:611-616.
 19. Binder DK, Von Lehe M, Kral T, Bien CG, Urbach H, Schramm J, Clusmann H: Surgical treatment of occipital lobe epilepsy. *J Neurosurg* 2008;109:57-69.
 20. Boesebeck F, Schulz R, May T, Ebner A: Lateralizing semiology predicts the seizure outcome after epilepsy surgery in the posterior cortex. *Brain* 2002;125:2320-2331.
 21. Devaux B, Chassoux F, Landre E, Turak B, Abou-Salma Z, Mann M, Pallud J, Baudouin-Chial S, Varlet P, Rodrigo S, Nataf F, Roux FX: [surgical resections in functional areas: Report of 89 cases.]. *Neurochirurgie* 2008;54:409-417.
 22. Sinclair DB, Aronyk K, Snyder T, McKean JD, Wheatley M, Gross D, Bastos A, Ahmed SN, Hao C, Colmers W: Extratemporal resection for childhood epilepsy. *Pediatr Neurol* 2004;30:177-185.
 23. Kral T, von Lehe M, Podlogar M, Clusmann H, Sussmann P, Kurthen M, Becker A, Urbach H, Schramm J: Focal cortical dysplasia: Long term

- seizure outcome after surgical treatment. *J Neurol Neurosurg Psychiatry* 2007;78:853-856.
24. Sisodiya SM: Surgery for malformations of cortical development causing epilepsy. *Brain* 2000;123 (Pt 6):1075-1091.
 25. Fauser S, Schulze-Bonhage A, Honegger J, Carmona H, Huppertz HJ, Pantazis G, Rona S, Bast T, Strobl K, Steinhoff BJ, Korinthenberg R, Rating D, Volk B, Zentner J: Focal cortical dysplasias: Surgical outcome in 67 patients in relation to histological subtypes and dual pathology. *Brain* 2004;127:2406-2418.
 26. Bautista RE, Cobbs MA, Spencer DD, Spencer SS: Prediction of surgical outcome by interictal epileptiform abnormalities during intracranial eeg monitoring in patients with extrahippocampal seizures. *Epilepsia* 1999;40:880-890.
 27. Janszky J, Janszky I, Schulz R, Hoppe M, Behne F, Pannek HW, Ebner A: Temporal lobe epilepsy with hippocampal sclerosis: Predictors for long-term surgical outcome. *Brain* 2005;128:395-404.
 28. Wyllie E, Luders H, Morris HH, 3rd, Lesser RP, Dinner DS, Hahn J, Estes ML, Rothner AD, Erenberg G, Cruse R, et al.: Clinical outcome after complete or partial cortical resection for intractable epilepsy. *Neurology* 1987;37:1634-1641.
 29. Devinsky O, Romanelli P, Orbach D, Pacia S, Doyle W: Surgical treatment of multifocal epilepsy involving eloquent cortex. *Epilepsia* 2003;44:718-723.
 30. Krsek P, Tichy M, Hajek M, Dezortova M, Zamecnik J, Zedka M, Stibitzova R, Komarek V: Successful epilepsy surgery with a resection contralateral to a suspected epileptogenic lesion. *Epileptic Disord* 2007;9:82-89.
 31. Engel J, Jr., Wilson C, Bragin A: Advances in understanding the process of epileptogenesis based on patient material: What can the patient tell us? *Epilepsia* 2003;44 Suppl 12:60-71.
 32. Lüders HO, Najm I, Nair D, Widdess-Walsh P, William B: The epileptogenic zone: General principles. *epileptic discord* 2006;8:suppl.2:s1-9.
 33. Hildebrandt M, Schulz R, Hoppe M, May T, Ebner A: Postoperative routine eeg correlates with long-term seizure outcome after epilepsy surgery. *Seizure* 2005;14:446-451.

34. Taylor I, Scheffer IE, Berkovic SF: Occipital epilepsies: Identification of specific and newly recognized syndromes. *Brain* 2003;126:753-769.
35. Elsharkawy AE, Alabbasi AH, Pannek H, Schulz R, Hoppe M, Pahs G, Nayel M, Issa A, Ebner A: Outcome of frontal lobe epilepsy surgery in adults. *Epilepsy Res* 2008;doi:10.1016/j.eplepsyres.2008.1004.1017.
36. Kelemen A, Barsi P, Eross L, Vajda J, Czirjak S, Borbely C, Rasonyi G, Halasz P: Long-term outcome after temporal lobe surgery--prediction of late worsening of seizure control. *Seizure* 2006;15:49-55.
37. Patrick S, Berg A, Spencer SS: Eeg and seizure outcome after epilepsy surgery. *Epilepsia* 1995;36:236-240.
38. Mintzer S, Nasreddine W, Passaro E, Beydoun A: Predictive value of early eeg after epilepsy surgery. *J Clin Neurophysiol* 2005;22:410-414.
39. Spencer SS: Neural networks in human epilepsy: Evidence of and implications for treatment. *Epilepsia* 2002;43:219-227.
40. Spencer SS, Berg AT, Vickrey BG, Sperling MR, Bazil CW, Shinnar S, Langfitt JT, Walczak TS, Pacia SV: Predicting long-term seizure outcome after resective epilepsy surgery: The multicenter study. *Neurology* 2005;65:912-918.

List of figures

Figure 1: Kaplan-Meier Curve showing the probability of seizure remission based on the presence or absence of a history of GTCS (The probability is high and continuous over time among patients with an absence of a history of GTCS).

Figure 2: Kaplan-Meier Curve showing the probability of seizure relapse based on the presence or absence of IED in EEG performed 6 months after surgery (The probability of relapse is high among patients with the presence of IED in the 6-month postoperative EEG. Lines cross at the 6-year follow-up. Relapses are more likely in the long term).

Figure 3: Kaplan-Meier Curve showing the probability of seizure relapse based on the completeness of the resection as seen in postoperative MRI (The probability of relapse is high among patients with incomplete resection).

Cumulative probability of seizure remission

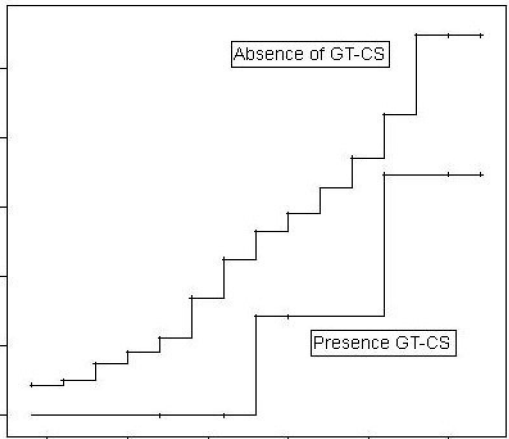
1,25
1,00
0,75
0,50
0,25
0,00

Absence of GT-CS

Presence GT-CS

2,5 5 7,5 10 12,5 15

Time since surgery



Cumulative probability of seizure relapses

