



HAL
open science

Cranial pachymeningitis: a rare neurological syndrome with heterogeneous etiology

Norbert Brüggemann, Stefan Gottschalk, Konstanze Holl-Ulrich, Jan Stewen,
Wolfgang Heide, Günter Seidel

► **To cite this version:**

Norbert Brüggemann, Stefan Gottschalk, Konstanze Holl-Ulrich, Jan Stewen, Wolfgang Heide, et al.. Cranial pachymeningitis: a rare neurological syndrome with heterogeneous etiology. *Journal of Neurology, Neurosurgery and Psychiatry*, 2010, 81 (3), pp.294. 10.1136/jnnp.2008.160457. hal-00552722

HAL Id: hal-00552722

<https://hal.science/hal-00552722>

Submitted on 6 Jan 2011

HAL is a multi-disciplinary open access archive for the deposit and dissemination of scientific research documents, whether they are published or not. The documents may come from teaching and research institutions in France or abroad, or from public or private research centers.

L'archive ouverte pluridisciplinaire **HAL**, est destinée au dépôt et à la diffusion de documents scientifiques de niveau recherche, publiés ou non, émanant des établissements d'enseignement et de recherche français ou étrangers, des laboratoires publics ou privés.

“short reports” in *JNNP (Journal of Neurology, Neurosurgery, and Psychiatry with Practical Neurology)*

Title: Cranial pachymeningitis: a rare neurological syndrome with heterogeneous etiology

N Brüggemann¹, S Gottschalk², K Holl-Ulrich³, J Stewen⁴, W Heide⁴, G Seidel¹

¹*Department of Neurology, University of Lübeck, Lübeck, Germany*

²*Institute of Neuroradiology, University of Lübeck, Lübeck, Germany*

³*Institute of Pathology, University of Lübeck, Lübeck, Germany*

⁴*Department of Neurology, General Hospital Celle, Celle, Germany*

Correspondence to:

Prof Dr Günter Seidel, MD

Department of Neurology, University of Lübeck

Ratzeburger Allee 160, 23538 Lübeck, Germany

Phone: +49-451-500-3334; Fax: +49-451-500-5457

Email: guenter.seidel@neuro.uni-luebeck.de

Character count of title:	81
Word count of abstract:	171
Word count of text:	1500
Number of references:	11
Number of figures:	1
Number of tables:	1

Running title: Etiology of pachymeningitis

Keywords: pachymeningitis, rheumatoid arthritis, central nervous system vasculitis, leptomeningeal inflammation, leptomeningeal enhancement

ABSTRACT

Cranial pachymeningitis is a poorly understood syndrome defined by leptomeningeal thickening and typical Gadolinium-enhanced magnetic resonance imaging (MRI). We present the heterogeneous clinical and aetiological features of five patients with both focal and diffuse pachymeningitis. The initial symptoms included headache (n = 3), sensory Jackson seizures (n = 1), hemiparesis (n = 1), episodes of short-lasting hemiataxia (n = 1), hemihypaesthesia (n = 1), aphasia (n = 1) and confusion (n = 2). MRI scans revealed focal (n = 3) or diffuse (n = 2) leptomeningeal Gadolinium enhancement and cortical swelling (n = 4). In addition, one case presented with a subarachnoid and a second with an intracerebral haemorrhage. CSF findings were variable and showed clear lymphomonocytic pleocytosis in 3/5 cases. Infectious diseases were extensively excluded in all cases. Leptomeningeal biopsies of two cases revealed perivascular inflammation indicating central nervous system vasculitis. In the cases presented, pachymeningitis was caused by primary central nervous system vasculitis (n = 2) and rheumatoid arthritis (n = 2). In one case, the cause remained unclear.

MAIN TEXT

Cranial pachymeningitis is a rare neurological condition, typically characterised by diffuse or localised meningeal thickening and chronic inflammation. Frequent clinical features are caused by compression and include headache, cranial neuropathies, hemiparesis and seizures. Pachymeningitis is associated with granulomatous diseases such as tuberculosis [1,2] and Wegener's granulomatosis [3]; rheumatoid arthritis (RA) [4,5] and vasculitides, especially temporal arteritis [6-8]. Our aim is to delineate the heterogeneous aetiological background of pachymeningitis by demonstrating five new cases. The clinical characteristics, diagnostic findings and specific treatments are summarised in the table 1.

TABLE

Table 1: Clinical characteristics, laboratory findings, MRI and biopsy results and therapeutic options in five patients with pachymeningitis. A temporal profile of the CSF cell count is provided in the table. Day0 (d0) is defined as the day of first lumbar puncture and does not indicate the onset of first clinical symptoms. Infectious agents were either analysed by serology tests (S, antigen or antibody), (C) culture or PCR. n/a, not applicable

No.	Patient 1	Patient 2	Patient 3	Patient 4	Patient 5	
Age at onset	78	76	83	45	69	
Sex	Female	Male	Male	Male	Female	
Clinical presentation	Alert, headache, aphasia	Alert, headache, short-lasting unilateral acroataxia	Alert, hemiparesis	Alert, sensory epileptic seizures	Alert, headache, confusion, blurred vision	
CSF	Cell count [$<12/3$]	255/3 (d0, single siderophages), 234/3 (d7), 55/3 (d26)	13/3 (d0), 1/3 (d48)	0/3 (d0), 10/3 (d5)	111/3 (d0), 45/3 (d10)	180/3 (d0), 102/3 (d12), 72/3 (d28)
	Protein [<45 mg/dl]	575-760	61-84	38 -42.4	46-56.3	57-583
	DLQ [<0.75]	0.5-0.9	0.44-0.46	0.3	<0.75	Intrathecal IgA- and IgM-synthesis
	Microbiology	Negative culture (aerob, anaerob, yeasts). Negative for mycobacterium tuberculosis (PCR, C), borrelia burgdorferi (S), cryptococcus neoformans (S), HSV-(PCR, S), VZV-(S) and toxoplasma-IgM (S)	Negative for borrelia burgdorferi (S), brucella (S), leptospira (S), toxoplasma gondii (S), cryptococcus neoformans (S), treponema pallidum (S), CMV (S), EBV (S), HSV (S), VZV (S)	n/a	Negative culture (aerob, anaerob). Negative microscopy for acid resistant rods. Negative for mycobacterium tuberculosis (PCR)	Negative for mycobacterium tuberculosis (PCR, C), VZV (S), HSV (S)
Serum	ESR [mm n.W.]	28/77	15/29	80/90	n/a	Normal
	Rheumatoid factor [<20 IU/ml]	Negative	1,010	<20	178	Negative
	ANA [$<1:80$]	Negative	1:320 (anti-dsDNA, -histon and ENA negative)	Marginal	Negative	1:320 (anti-dsDNA negative)
	CRP [<5 mg/l]	3.1-10.9	0.5-60.6	25-79	46-79	Normal
	ANCA	Negative	Negative	Negative	n/a	Negative
	ACE	Normal	Normal	Normal	Normal	n/a
Microbiology (supplemental to CSF)	Negative for leptospira (S), treponema pallidum (S), toxoplasma gondii (S), aspergillus fumigatus (S), HIV (S).	Positive for CMV (S). Negative for treponema pallidum (S), HIV (S), negative blood culture.	Positive for borrelia burgdorferi-IgG, negative for IgM (S). Negative for treponema pallidum (S), HIV (S), hepatitis B and C (S).	Negative for borrelia burgdorferi (S), treponema pallidum (S), toxoplasma gondii (S), listeria (C), HIV (S), hepatitis B and C (S), cryptococcus neoformans (S), aspergillus fumigatus (S), candida (S).	Negative for listeria (C), HIV (S), VZV (S), HSV (S), hepatitis B and C (S)	
MRI	Focal bulging of the left parieto-occipital cortex, superficial enhancement.	Temporo-parieto-occipital bulging and leptomeningeal enhancement on the right. Residual of a right-sided frontal MCA infarction. Distinct cerebral microangiopathy.	Central and postcentral focal leptomeningeal enhancement on the left for approx. 3 cm. Slight cortical swelling. Distinct cerebral microangiopathy.	Initially frontal leptomeningeal enhancement of the right side, later also on the left and diffuse.	Diffuse bilateral leptomeningeal enhancement and swelling of the adjacent cortex.	
Intracranial MRA and optionally cerebral DSA/Duplex	MRA: Hypoplastic A1-segment of the right anterior cerebral artery. No profound stenoses.	MRA: No profound stenoses of basal brain arteries.	MRA: Poor quality due to artifacts (profound macroangiopathic changes of extracranial arteries).	MRA: No evidence for stenoses and caliber changes of basal brain arteries.	DSA: No evidence for cerebral vasculitis of the left basal brain arteries.	
Temporal artery biopsy/Ultrasound	Negative/negative	n/a	n/a	n/a	n/a	
Leptomeningeal biopsy	Chronic inflammatory perivascular infiltrates according to a vasculitis of small vessels. No amyloid deposition.	n/a	n/a	Mild chronic leptomeningeal inflammation, subpial astrogliosis and moderate leptomeningeal fibrosis.	Mixed necrotizing and granulomatous angitis.	
Therapy	Initially ceftriaxon (2 g/die), ampicillin (3x1.5 g/die) and acyclovir (3x625 mg/die).. Steroid-pulse-therapy (3x1000 mg/die), subsequent oral cyclophosphamide (150 mg/m ² /die) for 6 months and prednisolone (60 mg)	No antibiotics, Prednisolone 5-10 mg, etanercept 2x25 mg/w s.c. and methotrexate 15 mg/w i.v.	Initially ceftriaxon (2 g/die). Steroid-pulse-therapy (5x500 mg) and subsequent oral prednisolone for 21 days (starting with 100 mg)	Initially no antibiotics, Prednisolone and cyclophosphamide-pulse-therapy (planned)	Initially acyclovir (3x750 mg/die). Steroid- (initially 5x1000 mg) and cyclophosphamide-pulse-therapy (750 mg/m ²) in 4-weeks periods	
Clinical course	Resolved aphasia, persistent headache	Fluctuating and recurrent symptoms (hemiparesis, suspected focal seizures)	Improvement of hemiparesis	Decline of seizure frequency due to antiepileptic drugs	Distinct improvement of neurological symptoms.	

Case 1

A 78-year-old woman suffering from headache for 3 weeks was admitted because of sudden onset of global aphasia and amentia with an otherwise unremarkable neurological examination. The magnetic resonance imaging (MRI) scan revealed an extensive gyral swelling of the left parieto-occipital region with superficial Gadolinium (Gad) enhancement (figure 1). Repeated lumbar punctures showed a distinct lymphomonocytic pleocytosis and a massive dysfunction of the blood-cerebrospinal fluid (CSF) barrier. It was noteworthy that the first CSF analysis showed a sanguineous specimen with the detection of several siderophages, indicating an accessory (CT negative) subarachnoid haemorrhage. Microbiological examination of CSF and serum was unremarkable (table 1). The blood chemistry showed increased erythrocyte sedimentation rate (ESR) and C-reactive protein as well as a slight leucocytosis. The remaining results were normal, including angiotensin-converting enzyme (ACE) and immunologic parameters. Ultrasonography of the extra- and intracranial arteries including the temporal vessels and arterial and venous magnetic resonance angiography (MRA) showed normal results. Biopsy of the temporal artery revealed no evidence for giant cell arteritis.

The histopathological analysis of the leptomenigeal biopsy and adjacent cortical tissue indicated the presence of chronic inflammatory perivascular infiltrates due to small-vessel vasculitis without amyloid deposition (figure 1). We diagnosed a primary central nervous system vasculitis (PCNSV) with leptomenigeal and gyral manifestation. We initiated immunosuppressive therapy with methylprednisolone, initially with a pulse-therapy, and cyclophosphamide. Serial MRI follow-up under ongoing immunosuppressive treatment revealed a distinct regression of the cranial lesions; the clinical symptoms disappeared except for the persistent headache.

Case 2

A 76-year-old man reported experiencing a headache over several weeks and short-lasting episodes of left-sided acroataxia. The medical history included a clinically stable RA for 5 years. The clinical examination of the alert patient revealed hypaesthesia and reduced fine motor skills of the left extremities. Serial cranial MRI scans showed swelling and disturbed diffusion of the right temporal, parietal and occipital lobes, as well as focal leptomenigeal enhancement after Gad application. The Duplex of the brain-supplying arteries revealed marked arteriosclerotic plaques at the carotid bifurcation level but no evidence of vascular obliteration or stenoses. The lumbar puncture showed normal findings, except for an

increased CSF protein level. The CSF and serum results were negative for several infectious agents. There was no cytological evidence of carcinomatous meningitis. Further blood analysis showed a positive antinuclear antibody (ANA) titre and a high titre rheumatoid factor (RF), whereas further immunological markers were unremarkable. The patient declined leptomeningeal biopsy. Serial cranial MRI scans over the course of 2 years revealed stable findings; the clinical features fluctuated with the appearance of short-lived, left-sided hemiparesis and suspected focal seizures under immunosuppressive treatment with oral low-dose prednisolone, etanercept and methotrexate.

In summary, despite the absence of biopsy, we presume that the patient had rheumatic pachymeningitis. It is noteworthy that pulmonary squamous cell carcinoma was diagnosed 3 years after onset of the first symptoms at which stage the patient decided against further diagnostic and therapeutic approaches. Paraneoplastic CNS syndromes can occur up to 4 years before carcinoma manifestation.

Case 3

The third case describes an 83-year-old alert man who presented with a right-sided hemiparesis and slight dysidiadochokinesis on the right. His medical history included idiopathic polyneuropathy. The cranial MRI scan revealed leptomeningeal enhancement of the left central and precentral regions as well as a slight gyral bulging. The CSF results were normal. The value for ANA was marginally increased, and the RF was qualitatively positive. The clinical profile, however, argued against systemic vasculitis and collagenosis. The chest CT revealed a possible tumour in the left lingula that did not change over 2 months. The patient was no longer available for pulmonary workup afterwards.

He was treated with a combination of intravenous ceftriaxon and methylprednisolone. Pragmatic antibiotic treatment was initially started due to an elevated C-reactive protein, highly increased ESR and a positive serum IgG against *Borrelia burgdorferi*. The hemiparesis and the MRI findings resolved after continuation of immunosuppressive treatment for two months, supporting the assumption of an autoimmune cause for the leptomeningeal inflammation. Unfortunately, longer follow-up was not available. Nevertheless, despite normal CSF findings, a neoplastic process could not be definitely excluded. The patient declined leptomeningeal biopsy.

Case 4

A 45-year-old patient experienced recurrent episodes of ascending left-sided numbness

beginning in the leg, with each episode lasting several minutes. The symptoms were attributed to sensory epileptic Jackson seizures with the detection of an epileptogenic focus in the right frontal region. The neurological examination was unremarkable at each time. The medical history comprised RA since 1999 that involved joints only. Initially, the brain MRI revealed leptomeningeal enhancement in the right frontal region. Over the course of 6 weeks, the process began to affect the left frontal area on MRI, as well. He also developed right-sided focal sensory seizures. The CSF showed a lymphocytic pleocytosis. CSF cultures and further microbiologic diagnostics were negative. A leptomeningeal biopsy specimen revealed mild chronic inflammation with consecutive fibrosis and subpial astrogliosis but no evidence of vasculitic changes. The patient experienced iatrogenic bacterial meningitis after biopsy and was successfully treated with a combination of antibiotics (intravenous application of meropenem 3 x 2 g, vancomycin 2 x 1 g, rifampicin 1 x 600 mg and fluconazole 1 x 200 mg for 12 days and subsequent imipenem 3x500 mg, clindamycin 3x600 mg and ampicillin 3x2 g for 12 days due to fever relapse).

In summary, after performing an extensive excluding workup, we diagnosed the patient as having rheumatoid pachymeningitis. We have planned immunosuppressive therapy with cyclophosphamide and steroid pulses and will perform serial clinical controls and MRI scans.

Case 5

A 69-year-old woman developed headache, two episodes of ascending hemihypaesthesia and confusion associated with blurred vision caused by MRI-proven diffuse pachymeningitis with leptomeningeal enhancement and cortical oedema overlying both hemispheres and a small haemorrhage in the right frontal region with a subarachnoid component (figure 1). The medical history included breast cancer, which had occurred decades before. Subsequent CSF analyses showed lymphocytic pleocytosis with intrathecal Ig synthesis. The workup for infectious causes remained negative. A biopsy specimen showed vasculitis with perivascular infiltrates and necrotic as well as granulomatous components because of small vessel involvement while cerebral digital subtraction angiography (DSA) of the left hemisphere excluded vasculitic changes. Although the serum ANA titre was elevated, we did not detect specific antibodies indicating collagenosis. Furthermore, a recurrence of breast cancer with CNS manifestation was excluded with negative tumour markers as well as the leptomeningeal biopsy and we

diagnosed the patient as having PCNSV. Immunosuppressive treatment with methylprednisolone resulted in obvious regression of MRI-proven leptomeningeal enhancement. Headache and impaired vision resolved, while confusion improved distinctively, but persisted. CSF cell count decreased considerably from 180/3 to 72/3. Cyclophosphamide pulses in regular intervals of 4 weeks over 6 months and subsequent treatment with mycophenolate mofetil will be applied for therapeutic consolidation.

DISCUSSION

Pachymeningitis consists of meningeal thickening due to chronic inflammation. Clinical symptoms of the affected brain or cranial nerves are not diagnostic. In most cases the condition is diagnosed by MRI. The spectrum of MRI findings includes focal (case 1), hemispheric and bilaterally hemispheric (case 5) meningeal enhancement and in part, cortical swelling (case 1) and focal brain oedema. Dependent on the aetiology, other MRI changes can be observed, such as haemorrhage (case 5) and ischaemia in case of CNS vasculitis. Contrast-enhanced MRA can reveal vasculitic changes of brain-supplying arteries.

Pachymeningitis should be considered as a neurological syndrome with heterogeneous aetiology attributed to one of the following causative groups: (a) PCNSV [9, 10], (b) secondary CNS vasculitis [3,6-8], (c) general systemic inflammation, especially tuberculosis [1, 2] (d) neoplastic disorders and (e) idiopathic causes [11].

We suggest a gradual diagnostic workup for comparable patients, including the MRI sequences T1 ± GAD, T2, FLAIR, DWI, T2* and CE-MRA as well as colour-coded duplex sonography of extra- and intracranial arteries and high-resolution sonography of temporal and occipital arteries. Next steps imply transoesophageal echocardiography, 24 hour-ECG, chest x-rays, ultrasonography of the upper abdomen and a tumour PET in case of an assumed but not yet diagnosed neoplasm. Laboratory serum analysis should include screening for immunological disorders (ESR, CRP, differential blood count, RF, ANA, anti-SS-A, -SS-B and -ds-DNA, c-ANCA, p-ANCA, anti-phospholipid antibodies) and infectious diseases (serology for *treponema pallidum*, *borrelia burgdorferi*, hepatitis B and C, HIV, *mycoplasma*, *chlamydia*, *toxoplasma gondii*). Furthermore, occult blood testing and urinalysis (proteinuria, erythrocyturia) should be performed. CSF should be examined for cell count, protein, lactate, glucose, ink-stained microscopic slides (*cryptococcus*) and other infectious agents (microscopy incl. acid resistant rods, PCR for *mycobacterium tuberculosis* and HSV, serology for *toxoplasma gondii*, culture (including culture for *mycobacterium tuberculosis*). Subsequent medical workup requires optionally cerebral

DSA (vasculitic changes), biopsy of temporal artery and, as the gold standard, combined leptomeningeal and cortical biopsy. To emphasize, tuberculosis is very important in the differential diagnosis and should be definitively excluded before starting high-dose immunosuppressive treatment. Specific treatment and prognosis depends on the underlying disease.

FIGURE**Figure 1**

Brain MRI images and histological findings of patients with pachymeningitis. (A) The axial images reveal swelling of the left parieto-occipital cortex (FLAIR) and superficial Gad-enhancement (T1 + GAD) in patient 1. (B, C) Hematoxylin/ Eosin staining (B, 1:100) and lymphocytic (CD3+)-staining (C, 1:200) indicate perivascular lymphocytic infiltrates due to chronic inflammation of leptomeningeal and adjacent cortical tissue in keeping with a central nervous system vasculitis. (D) T1 weighted coronar axial image of patient 5 shows a bilateral pachymeningitis with leptomeningeal thickening and considerable enhancement after Gad application. The T2* image illustrates the small right frontal haemorrhage.

Disclosure: The authors declare that they have no conflicts of interest.

Exclusive license: The Corresponding Author has the right to grant on behalf of all authors and does grant on behalf of all authors, an exclusive licence (or non exclusive for government employees) on a worldwide basis to the BMJ Publishing Group Ltd and its Licensees to permit this article (if accepted) to be published in JNNP and any other BMJ PGL products to exploit all subsidiary rights, as set out in the licence (<http://jnnp.bmj.com/ifora/licence.pdf>).

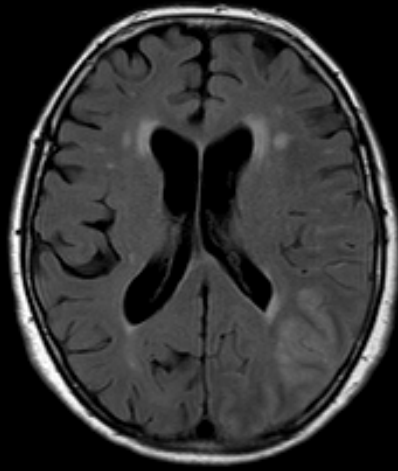
REFERENCES

1. Thurtell MJ, Keed AB, Yan M, Gottlieb T, Spies JM, Halmagyi GM. Tuberculous cranial pachymeningitis. *Neurology*. 2007;**68**:298-300.
2. Shobha N, Mahadevan A, Taly AB, et al. Hypertrophic cranial pachymeningitis in countries endemic for tuberculosis: Diagnostic and therapeutic dilemmas. *J Clin Neurosci* 2008;**15**:418-27.
3. Nagashima T, Maguchi S, Terayama Y, et al. P-ANCA-positive Wegener's granulomatosis presenting with hypertrophic pachymeningitis and multiple cranial neuropathies: case report and review of literature. *Neuropathology* 2000;**20**:23-30.
4. Tian D, Chou RC, Henson JW, et al. A case report of rheumatoid leptomenigitis and pachymeningitis. *J Neuropathol Exp Neurol* 2005;**64**:465.
5. Starosta MA, Brandwein SR. Clinical manifestations and treatment of rheumatoid pachymeningitis. *Neurology* 2007;**68**:1079-80.
6. Joelson E, Ruthrauff B, Ali F, Lindeman N, Sharp FR. Multifocal dural enhancement associated with temporal arteritis. *Arch Neurol*. 2000;**57**:119-22.
7. Marano E, D'Armiento FP, Scarano V, Tortora F, Mignogna C, Briganti F. Focal hypertrophic cranial pachymeningitis associated with temporal arteritis: a new case report. *J Neurol* 2003;**250**:98-100.
8. Kuhn J, Harzheim A, Brockmann M, Mahkorn D, Bewermeyer H. Focal hypertrophic pachymeningitis in association with temporal arteritis. *Headache* 2004;**44**:1045-1048.
9. Salvarani C BR, Calamia KT, Christianson TJ, Weigand SD, Miller DV, Giannini C, Meschia JF, Huston J, Hunder GG. Primary Central Nervous System Vasculitis: Analysis of 101 Patients. *Ann Neurol* 2007;**62**:442-451.
10. Salvarani C, Brown RD, Calamia KT, Christianson TJ, Huston J, Meschia JF, Giannini C, Miller DV, Hunder GG. Primary central nervous vasculitis with prominent leptomenigeal enhancement: a subset with a benign outcome. *Arthritis Rheum* 2008;**58**:595-603.
11. Kupersmith MJ, Martin V, Heller G, Shah A, Mitnick HJ. Idiopathic hypertrophic pachymeningitis. *Neurology*. 2004;**62**:686-94.

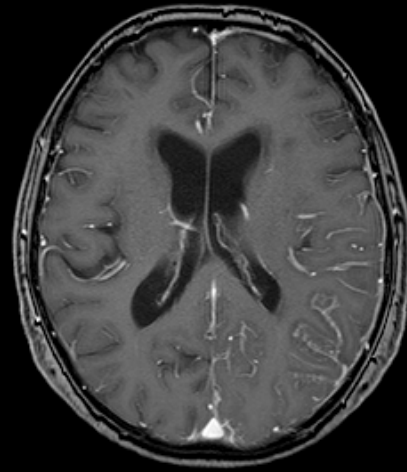
Case 1

(A)

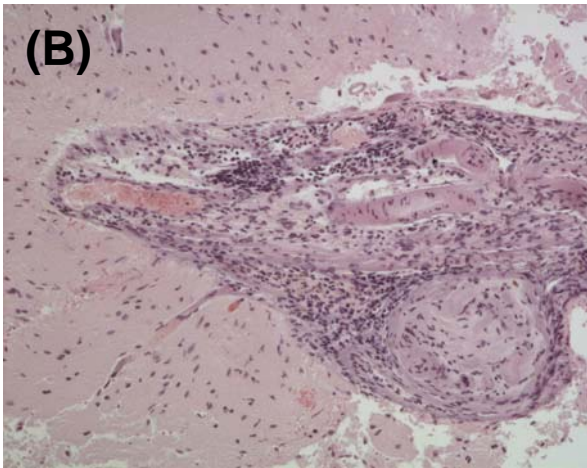
FLAIR



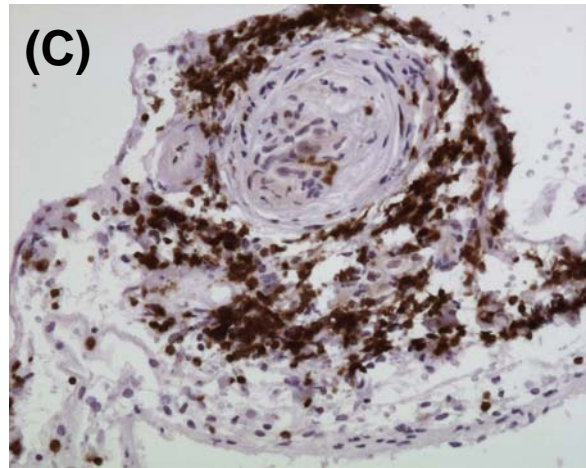
T1 + GAD



(B)



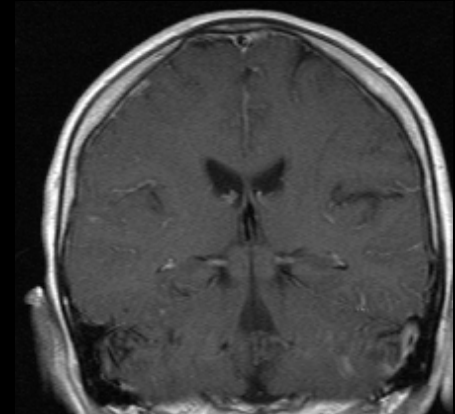
(C)



Case 5

(D)

T1 + GAD



T2*

