



HAL
open science

The Role of DAT-SPECT in Movement Disorders

Georg Kaegi, Kailash Bhatia, Eduardo Tolosa

► **To cite this version:**

Georg Kaegi, Kailash Bhatia, Eduardo Tolosa. The Role of DAT-SPECT in Movement Disorders. Journal of Neurology, Neurosurgery and Psychiatry, 2009, 81 (1), pp.5. 10.1136/jnnp.2008.157370 . hal-00552713

HAL Id: hal-00552713

<https://hal.science/hal-00552713>

Submitted on 6 Jan 2011

HAL is a multi-disciplinary open access archive for the deposit and dissemination of scientific research documents, whether they are published or not. The documents may come from teaching and research institutions in France or abroad, or from public or private research centers.

L'archive ouverte pluridisciplinaire **HAL**, est destinée au dépôt et à la diffusion de documents scientifiques de niveau recherche, publiés ou non, émanant des établissements d'enseignement et de recherche français ou étrangers, des laboratoires publics ou privés.

The Role of DAT-SPECT in Movement Disorders

Georg Kägi, MD,¹ Kailash P Bhatia, MD,¹ Eduardo Tolosa, MD, MRCP²

1 Sobell Department of Motor Neuroscience and Movement Disorders, Institute of Neurology, University College London, National Hospital for Neurology and Neurosurgery, Queen Square, London WC1N 3BG, UK

2 Parkinson's Disease and Movement Disorders Unit, Department of Neurology, Hospital Clínic, Institut d'Investigacions Biomèdiques August Pi i Suñer, Universitat de Barcelona, Centro de Investigación Biomédica en Red sobre Enfermedades Neurodegenerativas (CIBERNED), Barcelona, Spain

Address for Correspondence:

Eduardo Tolosa M.D.

Neurology Service, Institut Clínic de Neurociències, Hospital Clínic Universitari

Villarroel 170, Barcelona, Spain.

e-mail: etolosa@clinic.ub.es

Fax 34 93 2275783

Word counts: Abstract:180, Manuscript:4866, Tables:1, References:80

Abstract

Dopamine transporter (DAT) imaging is a sensitive method to detect presynaptic dopamine neuronal dysfunction which is a hallmark of neurodegenerative parkinsonism. DAT imaging can therefore assist the differentiation between conditions with and without presynaptic dopaminergic deficit. Diagnosis of Parkinson's disease or tremor disorders can be achieved with high degrees of accuracy in cases with full expression of classical clinical features, however, diagnosis can be difficult since there is a substantial clinical overlap especially in monosymptomatic tremor (dystonic tremor, essential tremor, Parkinson tremor). The use of DAT-SPECT can prove or excludes with high sensitivity nigrostriatal dysfunction in those cases and facilitates early and accurate diagnosis. Furthermore a normal DAT SPECT is helpful to support a diagnosis of drug-induced-, psychogenic- and vascular parkinsonism by excluding underlying true nigrostriatal dysfunction. This review addresses the value of DAT-SPECT and its impact on diagnostic accuracy in movement disorders presenting with tremor and/or parkinsonism.

Key words: dopamine transporter; SPECT; Parkinson's disease; tremor; differential diagnosis; movement disorders

Introduction

Parkinson's disease is clinically diagnosed based on the presence of the classical motor features (i.e. bradykinesia, rigidity, rest tremor), the presence of supportive features and the absence of exclusion criteria. In most of the cases the diagnosis is straight forward and no ancillary tests required. Two clinicopathological studies published in the early 1990s both found an accuracy of clinical diagnosis of PD of 76%. A more recent study in a tertiary referral centre in the UK, using ascertainment and methodology comparable with one of the earlier studies, has shown an improvement in this diagnostic accuracy, with a positive predictive value for those fulfilling pre-established diagnostic criteria of 90%.¹ Assessment of the clinical features suggests that an accuracy of 90% may be the highest that can be expected using current diagnostic criteria. Accurate identification of parkinsonism involving presynaptic degeneration is important for patient management, because the disease course, therapy and prognosis differ substantially from nondegenerative diseases.

In the recent years, a number of ancillary tests have been developed to improve diagnostic accuracy of parkinsonism with focus on early stages. These tests include testing for dopaminergic responsiveness using levodopa or apomorphine, autonomic function tests, based on magnetic resonance (MR) or positron emission tomography (PET) and single photon emission computed tomography (SPECT) imaging techniques. For SPECT studies dopamine transporter (DAT) ligands ($[^{123}\text{I}]\text{FP-CIT}$, $[^{123}\text{I}]\beta\text{-CIT}$, $[^{99\text{m}}\text{Tc}]\text{-TRODAT-1}$) have become very popular.

In the early 90ies the cocaine analogue β -CIT has been developed and has proven to have a high affinity to DAT and serotonin transporter (SERT). Pharmacological characterisation of tracer uptake in primate brains has shown that striatal activity is associated mainly with DAT, whereas midbrain activity is mainly associated with SERT.² One of the main problems with the use of [¹²³I] β -CIT is that the uptake in human striatum is characterised by slow kinetics, with an increase in striatal activity for 15-20 hours after injection which requires a delay between injection and scan of ~24 hours. The flouropropyl derivate of β -CIT, FP-CIT has been developed and has proven to be selective and reliable to measure human brain striatal DAT with SPECT cameras.³ ([¹²³I]FP-CIT SPECT (DaTSCANTM)) has the main advantage of faster striatal kinetics which allow imaging 3-6 hours after injection. The popularity of this method in the differential diagnosis of Parkinson's disease is explained by the exclusive localisation of DAT in dopamine synthesising neurons⁴, by a very high sensitivity to detect presynaptic dopaminergic dysfunction and by the widespread availability of SPECT scanners. In clinical practice modifying factors on DAT density like gender, smoking and age are of low importance. A big advantage is, that dopaminergic therapy can be continued because it has only minor or no influence on DAT binding. However, dopaminergic CNS-stimulants are known to have a significant influence on DaTSCANTM and therefore need to be stopped prior to the scan (see table 1).

This review will critically address the role of the DAT-SPECT in clinical practice.

Table 1. Relevant drug interaction with DAT SPECT

minor* effect on DAT SPECT	to be stopped prior DAT SPECT (days)	significant** effect on DAT SPECT	to be stopped prior DAT SPECT (days)
----------------------------	--------------------------------------	-----------------------------------	--------------------------------------

citalopram	8	cocaine	2
fluoxetine	45	amfetamine	7
paroxetine	5	methylamfetamine	3
venlafaxine	3	methylphenidate	1
duloxetine	3	methylphenidate	2
escitalopram	8	dexamfetamine	7
fluvoxamine	5	mazindol	3
sertraline	6	phentermine	14
imipramine	5	modafinil	3
clomipramine	21	bupropion or amfebutamone	8
pimozide	28	benzotropine	5
ziprasidone	2		
memantine	5		
amantadine	6		
budipine	6		
ephedrine, epinephrine phenylephrine pseudoephedrine xylometazoline	6-10 hours		

* may have a small effect on uptake (at most 15%). This is acceptable for routine DAT SEPCT but not for research

** all of these drugs are likely to alter (usually decrease) radioligand uptake by at least 20% and often substantially more and therefore have to be stopped prior routine DAT SPECT

Parkinsonism

Parkinson's disease

Although clinical diagnosis of Parkinson's disease is often straight forward and robust in cases with classic presentation of cardinal clinical signs and symptoms, 10-20% of patients diagnosed with PD have an alternative diagnosis when compared to a pathologic gold standard⁵ underlining the need for additional tests especially in clinically mild or uncertain cases, to improve diagnostic accuracy. Several studies have demonstrated the contribution of DAT-SPECT in early diagnosis of parkinsonism.⁶⁻⁹ However, sensitivity of DAT SPECT imaging to detect presynaptic dopaminergic deficit is reported to be less

than 100%. In a study with 38 patients with a clinical diagnosis of probable PD according to step 1 of the UK PDS Brain Bank Criteria, Benamer and colleagues⁹ found normal FP-CIT-SPECT in 5 patients (13%) presenting with unilateral rest tremor and variable degrees of bradykinesia. Although, diagnosis was changed in 1 patient during follow up, 10% of clinical PD were not detected by DAT SPECT imaging in this study. This number is also reflected in the large drug trials using DAT-SPECT or [¹⁸F]dopa PET imaging as a surrogate marker of disease progression where 5.7-14.7% of the cases clinically diagnosed as early PD had “scans without evidence of dopaminergic deficit” (SWEDDs).¹⁰⁻¹² Follow up scans of those SWEDDs after 2 years in the REAL-PET¹² study ([¹⁸F]dopa PET) and after 4 years in the ELLDOPA study ([¹²³I]β-CIT-SPECT) remained normal.^{13;14} Taking into account that a reduced DAT density can be observed already in preclinical stages (bilaterally reduced DAT density in hemiparkinsonism,⁶ abnormal DAT-SPECT in REM Sleep Behaviour Disorder,¹⁵ and patients with abnormal smell¹⁶) and that first motor symptoms of Parkinson’s disease occur after 80% of striatal and 50% of nigral dopamine cells are lost it is unlikely that DAT-SPECT, which mirrors the decline in striatal dopamine levels, is normal even in early stages of Parkinson’s disease.¹⁷

In a recent report Schneider and colleagues report 12 patients with SWEDD who were initially diagnosed and treated as PD.¹⁸ In those patients DaTSCANTM has been done because of atypical features (atypical clinical presentation, unresponsiveness to levodopa or unusual slow disease progression). Asymmetric tremor at rest and on action was accompanied with subtle signs of dystonia in most of the cases and reduced arm swing or even mild hypomimia was present in some of them. In our clinical experience the

presence of subtle signs of dystonia, the lack of true bradykinesia, the task/position specific tremor with “dystonic flurries” especially during handwriting as well as the lack of the re-emergent tremor are the most useful clinical signs to differentiate SWEDDs from PD. It is very likely that the reported lack of sensitivity to detect presynaptic dopaminergic degeneration in PD using DAT-SPECT is mainly due to the fact that some patients with dystonic tremor are misdiagnosed as PD. It is important to recognize the SWEDDs because dopaminergic therapy is not effective in those patients.¹⁸ Early detection of SWEDDs by including a DAT-SPECT in the initial diagnostic workup in patients with unilateral rest tremor where PD is suspected is very likely to be cheaper than expose a proportion of patients to unnecessary treatment and its side effects.

DAT-SPECT has also been used as a potential biomarker for disease progression in PD and has shown a progressive decline of striatal DAT binding with the duration of PD and with increasing disease severity also in agreement with [¹⁸F]dopa PET studies.¹⁹ Of interest is the lack of correlation between tremor scores and striatal DAT binding, whereas bradykinesia, rigidity as well as gait, posture, facial expression and speech explained a significant part of the variability in striatal FP-CIT binding.²⁰⁻²² Motor scores in the “off” state correlate better with striatal DAT binding contralateral to the less affected side.²² In longitudinal studies assessing PD progression, the annual rate of reduction of striatal DAT uptake is between 6 and 13% in PD patients versus 0-2.5% in healthy controls.^{8;21}

A yet unanswered question is whether dopamine agonists and levodopa have different effects on DAT expression, radiotracer affinity and receptor occupancy because the significant difference in striatal β -CIT uptake after 46 months in a study comparing

levodopa-treatment vs. pramipexole didn't reflect the clinical progression.¹⁰ Before striatal DAT binding can be accepted as a valid biomarker for progression of nigrostriatal pathology in PD, this issue need to be clarified.

In conclusion DAT-SPECT is a highly sensitive (~100%) method to detect presynaptic dopaminergic deficit in PD (taken into account that some of the patients with SWEDDs may have dystonic or other forms of tremor). A normal DAT-SPECT in a symptomatic patient is very strong evidence against Parkinson's disease and favours alternative diagnoses than neurodegenerative parkinsonism. An abnormal DAT-SPECT supports the diagnosis of PD or other neurodegenerative parkinsonism in early disease or uncertain or incomplete parkinsonian syndromes. **Figure 1** depicts images of a normal DAT SPECT and abnormal images in patients with PD.

Inconclusive Parkinsonism

One study²³ addressed the impact of DAT-SPECT on the diagnosis and changes in therapeutic management in patients with inconclusive parkinsonism (patients with uncertainty between PD and MSA or PSP were excluded). DAT imaging lead to a change of the planned management in 72% of cases The most common change was the initiation of a new therapy (35%) and the change of follow-up appointments and in more than half of the patients diagnosis was changed after review of the SPECT image. After imaging, however, 22 patients were classified as inconclusive, which suggests a significant diagnostic impact of DAT-SPECT. After two year follow up, DAT-SPECT images showed a high rate of agreement with clinical diagnosis and the follow-up DAT-SPECT

after 2 years helped to establish a diagnosis in 87.5% with a previously inconclusive diagnosis.²⁴

Genetic Parkinsonism

Patients with PARK2 (*Parkin* gene-related) tend to have a more severe and more symmetric loss of striatal DAT density²⁵ but a slower progression compared to PD^{26;27} which is in keeping with [¹⁸F]flourodopa PET findings. Of interest is that nigrostriatal dopaminergic loss has also been found in asymptomatic carriers of only one mutant gene in [¹⁸F]flourodopa PET-^{25;26} and DAT-SPECT studies.²⁷

The findings of presynaptic dopaminergic imaging described in PARK2 are paralleled with the findings in PARK6 (*pink1*-gene related) of another autosomal-recessive form of young onset parkinsonism with a widespread, rather symmetrical and severe nigrostriatal dysfunction also present in asymptomatic carriers of one single mutation.²⁸ One DAT SPECT study in PARK6 found presynaptic dopaminergic dysfunction similar to PD in symptomatic patients but normal DAT density in asymptomatic carriers of only one mutant gene.²⁹ Symptomatic patients with PARK7 (DJ-1 gene related) have also been found to have abnormal DAT imaging in the range of PD.³⁰

Autosomal dominant PD caused by mutations in the alpha-synuclein gene (PARK1) as well as due to the much more common *Lrrk2* gene (PARK8) showed a similar degree and pattern of nigrostriatal dopaminergic dysfunction using [¹⁸F]flourodopa PET as found in PD.^{31;32}

Spino-cerebellar ataxia 2 and 3 which can present with predominant parkinsonism have nigro-striatal dysfunction in [¹⁸F]flourodopa PET and DAT-SPECT as seen in idiopathic PD^{33;34} and even asymptomatic SCA-3 gene carriers had abnormal DAT binding.³⁴

Dopa-responsive dystonia (DRD) and juvenile Parkinson's disease (JPD) can be difficult to distinguish just on clinical grounds and both have an excellent response to levodopa. Because levodopa causes early and severe motor complications in JPD but not in DRD it is crucial that JPD is excluded before long-term treatment with levodopa. DRD can be caused by different genes, hence genetic testing for all forms of DRD is not widely available. In this regard DAT-SPECT is very useful to separate these two conditions because it is normal in DRD.³⁵

Atypical Parkinsonism (MSA, PSP, CBD)

The differentiation of atypical parkinsonian disorders from PD and between each other can raise considerable difficulties, particularly in early disease stages. This difficulty is reflected in clinicopathological studies where atypical parkinsonism accounts for a large part of misdiagnosis in PD.⁵ MSA especially the parkinsonian subtype (MSA-P) can initially be very difficult to distinguish from PD before more specific symptoms like pronounced autonomic involvement, laryngeal stridor or lack of response to dopaminergic therapy occur. The same is true for the parkinsonian type of PSP (PSP-P) in which the more disease specific signs and symptoms such as supranuclear vertical gaze palsy and imbalance with falls occur. Also cortico-basal degeneration (CBD) can initially easily be mistaken as PD because of its marked asymmetrical akinetic-rigid syndrome before apraxia, myoclonus and cognitive problems occur. A faster disease progression

and a poor responsiveness to levodopa are common features in atypical forms and is explained by the pre-and postsynaptic dopaminergic degeneration. However, some responsiveness to levodopa is not uncommon in early MSA-P or PSP-P. In the past years several studies have been carried out to establish the value of DAT SPECT for the differentiation between PD and atypical PD. It has been shown that DAT SPECT is sensitive to detect presynaptic nigrostriatal degeneration in PD and atypical PD but not useful in the differential diagnosis of PD and atypical PD.³⁶⁻³⁹

The amount and pattern of reduced striatal DAT binding in MSA has been shown to be in the range of PD with a more pronounced loss of DAT binding in the posterior putamen compared to the caudate to be typical for both.⁸ Asymmetry of DAT binding loss tends to be more pronounced in PD^{36;37} and progression is faster in MSA compared to PD. PET and DAT SPECT studies have shown that even clinically pure forms of MSA-C have some decrease of DAT binding but less compared to MSA-P or PD.⁴⁰ This finding could be of some diagnostic impact in the differential diagnosis of MSA-C to idiopathic late onset cerebellar ataxia (ILOCA). For separating MSA from PD other techniques such as voxel-wise analysis of DAT-SPECT combined DAT/D2 receptor SPECT (IBZM, Epidepride, Iodolisuride and IBF) or D2 PET (raclopride) can provide more information although D2 receptor binding imaging methods are influenced by dopaminergic therapy and are therefore most useful in drug naïve patients. In drug naïve PD D2 binding exceeds normal levels because of D2 receptor up-regulation whereas D2 binding is reduced in MSA from early on because of postsynaptic degeneration. PET studies **may contribute in the differential diagnosis of these entities. Striatal metabolic studies using FDG have shown to be of value in the differential diagnosis of atypical parkinsonism**

with hypermetabolism in the dorsolateral putamen in PD, bilateral hypometabolism in the putamen in MSA and hypometabolism of the brainstem and the middle frontal cortex in PSP.⁴¹ In CBD, unlike PSP or PD, unilateral balanced (caudate/putamen) reduction in tracer uptake has been observed.⁴² In addition cardiac imaging with MIBG has shown changes consistent of heart denervation in patients with PD which are not present in patients with MSA or PSP.

DAT-SPECT is also of limited value in the differential between PD and PSP³⁶ although PSP seem to have a more symmetrical and profound DAT loss in the whole striatum whereas in PD the posterior part of the putamen shows more loss of DAT density compared to the anterior part and the caudate.⁴³

DAT loss in CBD is in the same range as it is in PD and atypical PD^{36;44} although DAT loss is much more asymmetrical and less pronounced than seen in MSA and PSP³⁶. D2 SPECT seem to be of less value compared to MSA and PSP because D2 binding in CBD is more often in normal range than it is in MSA and PSP.³⁶

In conclusion, DAT-SPECT imaging does not help to differentiate between the neurodegenerative parkinsonian disorders. Hence, in clinical practice DAT-SPECT's are not useful to differentiate PD from atypical parkinsonian syndromes (MSA, PSP, CBD).

Dementia with Lewy bodies

In Dementia with Lewy Bodies (DLB) the extent of DAT loss in the striatum is in the range of PD⁴⁵ and therefore not useful in the differential of PD and atypical PD.

Neuropathological data suggest that 50-60% of dementia in people aged 65 or older are due to Alzheimer's disease, with a further 10-20% each attributable to DLB or vascular

cognitive impairment. Operationalised clinical diagnostic criteria have been agreed for all of these syndromes, but even in specialist research settings they have limited accuracy when compared with neuropathological autopsy findings. Distinguishing Alzheimer's disease from DLB is clinically relevant in terms of prognosis and appropriate treatment. A striking biological difference between DLB and Alzheimer's disease is the severe nigrostriatal degeneration and consequent DAT loss that occurs in DLB, but not to any significant extent in Alzheimer's disease.⁴⁶ Several imaging studies have shown that DAT imaging improves diagnostic accuracy with a sensitivity of 78% and a specificity of up to 94% in the separation between DLB and AD.^{47,48} Most of these studies have used clinical diagnosis as the gold standard and the results have to be taken with some caution. One study with 20 cases with pathologically proven dementias (DLB/non-DLB) and with an FP-CIT SPECT at initial clinical workup showed that the DAT imaging substantially enhanced the accuracy of diagnosis of DLB by comparison with clinical criteria alone.⁴⁹ Abnormal DAT imaging has therefore also been included as a suggestive feature in the DLB consensus criteria in 2005.⁵⁰

In conclusion, DAT-SPECT cannot discriminate between PD/PD-Dementia and DLB but can be very useful in the differential diagnosis between DLB and Alzheimer's disease and can also be of some value in the differential diagnosis between DLB and vascular dementia.

Vascular Parkinsonism

The diagnosis of vascular Parkinsonism (VP) often causes problems in the daily clinical work not only for general neurologists but also for movement disorders specialists and

has remained a controversial clinical concept. The classical sudden onset lower body parkinsonism is present only in the minority of cases and often appears slowly progressive as seen in neurodegenerative causes of parkinsonism. Furthermore, vascular lesions are a common incidental finding in pathologically confirmed PD. Thus, a large proportion of patients with late onset PD have some white matter changes on CT/MRI brain scans. Hence, the diagnosis of VP cannot be reliably confirmed on the basis of clinical features or anatomic imaging modalities alone although the introduction of clinical diagnostic criteria for VP⁵¹ has improved diagnostic accuracy. The criteria for VP include (1) bradykinesia, (2) cerebrovascular disease visualized by CT or MRI, and (3) a temporal relationship between the location of vascular lesions and the appearance of parkinsonian symptoms or the presence of extensive subcortical white matter lesions and bilateral symptoms at onset. Strategic infarcts which can cause parkinsonism involve the substantia nigra, the ventro-lateral nucleus of the thalamus (VL), the globus pallidum (GPe) or a large frontal lesion. The proposed criteria suggest the exclusion of other causes of parkinsonism such as space occupying lesions, drugs and toxins, head trauma, or encephalitis. However, a confirmatory test in addition to the proposed clinical criteria would facilitate further management in a number of patients presenting with parkinsonism and cerebrovascular disease by either excluding or proving underlying presynaptic nigrostriatal degeneration. The value of DAT-SPECT has been explored in several studies with different results. One study included 20 patients with lower body parkinsonism and cerebrovascular disease but without lesions affecting the basal ganglia. Abnormal DAT-SPECT has been found in more than half of the patients.⁵² Half of the patients with abnormal DAT-SPECT had a good response to levodopa. However, some

response to levodopa does not exclude VP because in a series of pathologically proven VP a substantial number had a good response to levodopa, especially those with lesions in or close to the nigrostriatal pathway.⁵³ Another study found significant lower [¹²³I]FP-CIT uptake compared to controls and in the range of PD⁵⁴ and only the rather symmetrical FP-CIT uptake in VP was different to PD. Other DAT-SPECT studies found mild reduction of striatal tracer uptake ([¹²³I]β-CIT/[^{99m}Tc]-TRODAT-1) in VP which were significant different from PD.^{55;56}

In summary, one can conclude that a normal or mild and symmetrical reduction of [¹²³I]FP-CIT uptake supports the diagnosis of VP if clinical criteria are fulfilled and marked cerebrovascular disease or strategic infarction is present on MRI/CT. Strictly unilateral reduced uptake in the region of a defined vascular lesion on the MRI/CT can also be considered as VP. However, PD can only be excluded if DAT-SPECT is normal because there is considerable overlap in striatal [¹²³I]FP-CIT uptake between VP and PD.

Drug-Induced Parkinsonism

Drug induced Parkinsonism (DIP) is a common, underdiagnosed and a serious health problem accounting for 24-35% of the causes of parkinsonism⁵⁷ and for up to 50% of hospital admissions due to parkinsonism. DIP is more common in female and in elderly patients. Common offending drugs are neuroleptics and calcium-channel blockers (flunarizine and cinnarizine). All neuroleptics, the so called atypical included, can cause DIP although clozapine followed by quetiapine carry the lowest risk. Neuroleptics for nausea, vomiting or vertigo, such as prochlorperazine, thiethylperazine and metoclopramide are frequently responsible for DIP and commonly overlooked.

Neuroleptic induced parkinsonism is due to a blockade of postsynaptic D2 receptors whereas calcium-channel blockers and tetrabenazine have additional presynaptic effects. The mechanism why tetrabenazine only causes parkinsonism but not tardive dyskinesias is not entirely known. DIP invariably develops if more than 80% of striatal dopamine postsynaptic receptors are blocked.⁵⁸ Because there is no clear correlation between the development of DIP and neuroleptic dosage or length of exposure, additional individual susceptibility has to be assumed.⁵⁷ There is evidence from patients with presymptomatic Parkinson's disease that antidopaminergic drugs can unmask PD. After withdrawal of the offending drug there is the possibility that parkinsonism resolves to reoccur later on or that some parkinsonism persists or even worsens. In pathological studies the incidence of incidental Lewy body disease is 14 to 16 times the incidence of PD.⁵⁹ Such a subclinical nigro-striatal dysfunction could also explain some individual susceptibility.

DIP sometimes can be diagnosed quite easily if parkinsonism develops quickly after introduction of an antidopaminergic drug and resolves within weeks after drug withdrawal or if other movement disorders like oro-lingual dyskinesias, stereotypies or akathisia coexist.

In clinical practice a reliable drug history is often lacking. Furthermore in a patient with prolonged neuroleptic therapy for psychosis who gradually develops parkinsonism the question often arises whether this is true PD or whether it is DIP. In these situations DAT-SPECT can be particularly helpful because although neuroleptics have a marked effect on brain dopaminergic system they have a negligible affinity for DAT⁶⁰ and do not change DAT density⁶¹ and therefore have a negligible effect on DAT-SPECT. One study in schizophrenia using [¹²³I]FP-CIT SPECT did not show significantly different striatal

binding between antipsychotic-naïve patients, patients with risperidone, drug-free patients and controls.⁶² Another report indirectly addresses DAT-SPECT in DIP using [¹²³I]FP-CIT SPECT in inconclusive parkinsonism and 3 out of the 19 cases with normal DAT SPECT were diagnosed as DIP.⁶³

Despite these limited data, it can be concluded that DAT-SPECT is likely to be normal in DIP unless presymptomatic PD is present or there is another unrelated cause of nigrostriatal dopamine damage.⁵⁷

Psychogenic Parkinsonism

Psychogenic movement disorders can present with a whole variety of movements seen in movement disorders of organic origin (tremor, dystonia, chorea, bradykinesia, myoclonus, tics, athetosis, ballism, incoordination) and can affect speech and gait. The estimated frequency in movement disorders clinics is 2-3% or even higher (own observation). In an analysis of 88 patients with psychogenic movement disorders abnormal gait was the most common phenomenon and present in 60% of the patients followed by action tremor (48%) and resting tremor (39%).⁶⁴ Psychogenic parkinsonism (PsyP) is a rare syndrome accounting for 0.17-0.5% of all parkinsonism cases.^{65:66} The clinical characteristics of PsyP are atypical variable tremor which lessens with distraction or concentration, in contrast with the usual enhancement seen in typical parkinsonian tremor. In addition extremely slow movements (“deliberate slowness of movement”) often accompanied by grimacing, sighing, or whole-body movements when patients do simple motor tasks may be observed. Onset is usually abrupt with a precipitating event and the progression to maximum symptom severity and disability is usually fast.

Although there are usually hints, that a patient has PsyP, it can be difficult to rule out organic parkinsonism just on clinical grounds. Psychogenic movement disorders can co-exist with an underlying organic parkinsonism and tend to have a good placebo effect.^{65;66} Hence a positive levodopa challenge can be misleading. Early and accurate diagnosis is important to provide an adequate and potentially effective treatment but also to avoid unnecessary, and potentially harmful, diagnostic or therapeutic procedures. With this regard patients with clinically suspected PsyP (Fahn and Williams criteria for psychogenic movement disorders^{66;67}) underwent [¹⁸F]flourodopa PET imaging. All of the patients with a clinically established degree of diagnostic certainty (n=5) had normal imaging and among the 4 patients with probable degree of certainty, imaging was normal in 3 and abnormal in 1 who turned out to have *Parkin* gene related parkinsonism.⁶⁸ In other studies of patients with suspected PsyP DAT-SPECT was also normal.^{63;69} Although data are limited normal DAT-SPECT in PsyP is the rule and a decreased striatal tracer uptake strongly suggest degenerative parkinsonism.

Tremor

Tremor is a rhythmical, involuntary oscillatory movement of a one or more body parts and is produced by alternating and sometimes also synchronous contractions of agonist and antagonistic muscles. Physiological tremor has a frequency of 8-13 Hz on outstretched fingers and is barely visible to the naked eye. If the same postural tremor is easily visible but only present with endogenous or exogenous factors (stress, intoxication, metabolic factors) it is classified as enhanced physiologic tremor.

Essential tremor

Classical essential tremor (ET) mainly affects both hands with no or only mild asymmetry, is classically present on posture, is not strikingly made worse during visually guided movements. Only rarely and in more advanced cases tremor can be present at rest. The tremor can also affect the chin and lips, neck and voice. According to the accepted definition, “essential” tremor should have no associated features. Hence true parkinsonism or dystonia should not be seen in typical ET. However, some authors describe an association with dystonia (cervical dystonia, spasmodic dysphonia or writer’s cramp) in up to 47% of their patients with ET,⁷⁰ whereas others exclude patients with concomitant dystonia.⁷¹ Another debate is whether patients with ET are at increased risk of PD. This link is supported by the observation that in some PD patients, a long-standing postural tremor precedes the onset of parkinsonism by years or even decades⁷² and that DAT imaging was abnormal in some patients diagnosed with ET.³⁸ Because different diagnostic criteria have been applied, ET is probably a heterogeneous disorder with differences in sex distribution, rate of progression and anatomic distribution of tremor as well as the associated features. This heterogeneity is probably the reason why linkage has been found to three different loci but no gene has as yet been found. It has been speculated that ET is over diagnosed and that some subgroups have another condition.⁷³ It is well known, that in autosomal-recessive parkinsonism (PARK2,6,7) young onset bilateral hand tremor without associated features of parkinsonism precedes the onset of true parkinsonism by years or decades and can easily be mistaken as ET.²⁷

Cases fulfilling ET criteria and without overlapping clinical features have invariably been found to have normal DAT-SPECT.^{39;74} It can be concluded that abnormal DAT-SPECT can be considered as an exclusion criteria for ET.

Dystonic tremor and tremor associated with dystonia

According to the current MDS consensus criteria on tremor, dystonic tremor (DT) is defined as a slow (usually less than 7Hz), in frequency and amplitude irregular position- or task specific tremor in an extremity or body part that is affected by dystonia. A more heterogeneous entity is tremor associated with dystonia, which is defined as tremor in a body part not affected by dystonia, but dystonia is present elsewhere. Uni-/or bilateral position-/action tremor of the hands is for example a common feature in patients with cervical dystonia. It should be recognized that patients with DT often have a rest tremor, sometimes even with classical pill-rolling, jaw tremor, facial hypomimia and impaired arm swing in the affected arm—all features that may suggest PD to the unwary.^{18;73} In addition, some dystonia patients have increased limb tone (distinct from cogwheeling alone in a tremulous limb). This does not necessarily equate with parkinsonian rigidity, but may be difficult to distinguish. What such patients do not have is true akinesia, as defined by progressive fatiguing and decrement of alternating repetitive movements. Patients with DT or tremor associated with dystonia have normal DAT-SPECT. As discussed before, DT can sometimes mimic PD (SWEDDs).¹⁸ Diagnosis only on clinical grounds can be very difficult or even impossible also for experts in movement disorders and a normal DAT-SPECT is the clue for accurate diagnosis and treatment.

Orthostatic tremor

Orthostatic tremor (OT) is characterized by a subjective feeling of unsteadiness during stance but only in severe cases during gait. No such problems are present when seated. Tremor is barely visible but usually palpable by touching the quadriceps muscle or detectable by stethoscope. The frequency is fast with a typical 13-18 Hz pattern which can be confirmed only by EMG. A study of 41 patients with OT found that 25% had additional neurological features (OT-plus) such as parkinsonism, restless legs syndrome, VP or DIP.⁷⁵ One DAT-SPECT study of 11 patients with pure OT showed significant reduction of mean striatal FP-CIT uptake in OT compared to controls.⁷⁶ A study of 41 patients with OT found that 25% had additional neurological features (OT-plus) such as parkinsonism, restless legs syndrome, VP or DIP.⁷⁵ One DAT-SPECT study of 11 patients with pure OT showed significant reduction of mean striatal FP-CIT uptake in OT compared to controls.⁷⁶ In summary, OT is an heterogenous condition. As a group patient with pure OT may show a minor but significant reduction on DAT SPECT, however in the individual case, in the clinical setting, images would be reported as normal or near normal. On the other hand DAT-SPECT could be abnormal in patients with OT and additional VP or PD (OT-plus).

Others

Cerebellar-, rubral- and neuropathic tremor have normal DAT-SPECT⁷⁷ whereas it is abnormal in patients with tremor due to Wilson's disease.⁷⁸ Patients with fragile X-associated tremor/ataxia syndrome (FXTAS) have been reported with both normal and abnormal DAT-SPECT.^{79;80}

Conclusions. We conclude that DAT-SPECT can provide valuable additional information in patients with clinically inconclusive parkinsonism or tremor, particularly early in disease. Abnormal DAT-SPECT imaging supports nigrostriatal degeneration (PD, MSA, PSP, CBD) in patients presenting with parkinsonism or supports alternative diagnosis like psychogenic-or drug induced parkinsonism, vascular parkinsonism, dystonic tremor, essential tremor or dopamine responsive dystonia if DAT-SPECT is normal (see figure 2). Early and accurate diagnosis has implications not only for the choice of treatment but also cost-efficiency for national health care systems. Additional potential roles of DAT-SPECT that have not yet been validated include (1) the use as a secondary screen for persons at risk for developing PD and (2) its use in the longitudinal monitoring of the striatal dopaminergic dysfunction in treated PD patients as a measure for disease progression.

Competing interests: none

Funding : Georg Kaegi was supported by a grant from the Swiss Parkinson's Disease Association.

Acknowledgements: This work was supported by grant 2003 SRG00387 Generalitat de Catalunya, Spain and by the award “Distinció per la promoció de la Recerca Universitària Generalitat de Catalunya”, Spain, both to Eduardo Tolosa.

Reference List

1. Hughes AJ, Daniel SE, Lees AJ. Improved accuracy of clinical diagnosis of Lewy body Parkinson's disease. *Neurology* 2001;**57**:1497-9.
2. Laruelle M, Baldwin RM, Malison RT, Zea-Ponce Y, Zoghbi SS, al Tikriti MS, Sybiraska EH, Zimmermann RC, Wisniewski G, Neumeyer JL, . SPECT imaging of dopamine and serotonin transporters with [123I]beta-CIT: pharmacological characterization of brain uptake in nonhuman primates. *Synapse* 1993;**13**:295-309.
3. Abi-Dargham A, Gandelman MS, DeErausquin GA, Zea-Ponce Y, Zoghbi SS, Baldwin RM, Laruelle M, Charney DS, Hoffer PB, Neumeyer JL, Innis RB. SPECT imaging of dopamine transporters in human brain with iodine-123-fluoroalkyl analogs of beta-CIT. *J.Nucl.Med.* 1996;**37**:1129-33.
4. Ciliax BJ, Heilman C, Demchyshyn LL, Pristupa ZB, Ince E, Hersch SM, Niznik HB, Levey AI. The dopamine transporter: immunochemical characterization and localization in brain. *J.Neurosci.* 1995;**15**:1714-23.
5. Hughes AJ, Daniel SE, Kilford L, Lees AJ. Accuracy of clinical diagnosis of idiopathic Parkinson's disease: a clinico-pathological study of 100 cases. *J Neurol Neurosurg Psychiatry* 1992;**55**:181-4.

6. Marek KL, Seibyl JP, Zoghbi SS, Zea-Ponce Y, Baldwin RM, Fussell B, Charney DS, van DC, Hoffer PB, Innis RP. [123I] beta-CIT/SPECT imaging demonstrates bilateral loss of dopamine transporters in hemi-Parkinson's disease. *Neurology* 1996;**46**:231-7.
7. Marshall VL, Reiningger CB, Marquardt M, Patterson J, Hadley DM, Oertel WH, Benamer HT, Kemp P, Burn D, Tolosa E, Kulisevsky J, Cunha L, Costa D, Booij J, Tatsch K, Chaudhuri KR, Ulm G, Pogarell O, Hoffken H, Gerstner A, Grosset DG. Parkinson's disease is overdiagnosed clinically at baseline in diagnostically uncertain cases: A 3-year European multicenter study with repeat [(123)I]FP-CIT SPECT. *Mov Disord.* 2008.
8. Pirker W, Djamshidian S, Asenbaum S, Gerschlager W, Tribl G, Hoffmann M, Brucke T. Progression of dopaminergic degeneration in Parkinson's disease and atypical parkinsonism: a longitudinal beta-CIT SPECT study. *Mov Disord.* 2002;**17**:45-53.
9. Benamer HT, Oertel WH, Patterson J, Hadley DM, Pogarell O, Hoffken H, Gerstner A, Grosset DG. Prospective study of presynaptic dopaminergic imaging in patients with mild parkinsonism and tremor disorders: part 1. Baseline and 3-month observations. *Mov Disord.* 2003;**18**:977-84.
10. Dopamine transporter brain imaging to assess the effects of pramipexole vs levodopa on Parkinson disease progression. *JAMA* 2002;**287**:1653-61.

11. Fahn S, Oakes D, Shoulson I, Kieburtz K, Rudolph A, Lang A, Olanow CW, Tanner C, Marek K. Levodopa and the progression of Parkinson's disease. *N.Engl.J.Med.* 2004;**351**:2498-508.
12. Whone AL, Watts RL, Stoessl AJ, Davis M, Reske S, Nahmias C, Lang AE, Rascol O, Ribeiro MJ, Remy P, Poewe WH, Hauser RA, Brooks DJ. Slower progression of Parkinson's disease with ropinirole versus levodopa: The REAL-PET study. *Ann.Neurol.* 2003;**54**:93-101.
13. Marek K, Jennings D, Seibyl J. Long-term follow-up of patients with scans without evidence of dopaminergic deficit (SWEDD) in the ELLDOPA study. *Neurology* 64(Suppl 1). 2005.
Ref Type: Abstract
14. Marek K, Seibyl J and Parkinson's Study Group. B-CIT scans without evidence of dopaminergic deficit (SWEDD) in the ELLDOPA-CIT and CALM-CIT study: longterm imaging assessment. *Neurology* 60(Suppl 1). 2003.
Ref Type: Abstract
15. Stiasny-Kolster K, Doerr Y, Moller JC, Hoffken H, Behr TM, Oertel WH, Mayer G. Combination of 'idiopathic' REM sleep behaviour disorder and olfactory dysfunction as possible indicator for α -synucleinopathy demonstrated by dopamine transporter FP-CIT-SPECT. *Brain* 2005;**128**:126-37.

16. Sommer U, Hummel T, Cormann K, Mueller A, Frasnelli J, Kropp J, Reichmann H. Detection of presymptomatic Parkinson's disease: combining smell tests, transcranial sonography, and SPECT. *Mov Disord.* 2004;**19**:1196-202.
17. Bezard E, Dovero S, Prunier C, Ravenscroft P, Chalon S, Guilloteau D, Crossman AR, Bioulac B, Brotchie JM, Gross CE. Relationship between the appearance of symptoms and the level of nigrostriatal degeneration in a progressive 1-methyl-4-phenyl-1,2,3,6-tetrahydropyridine-lesioned macaque model of Parkinson's disease. *J.Neurosci.* 2001;**21**:6853-61.
18. Schneider SA, Edwards MJ, Mir P, Cordivari C, Hooker J, Dickson J, Quinn N, Bhatia KP. Patients with adult-onset dystonic tremor resembling parkinsonian tremor have scans without evidence of dopaminergic deficit (SWEDDs). *Mov Disord.* 2007;**22**:2210-5.
19. Morrish PK, Sawle GV, Brooks DJ. An [18F]dopa-PET and clinical study of the rate of progression in Parkinson's disease. *Brain* 1996;**119**:585-91.
20. Seibyl JP, Marek KL, Quinlan D, Sheff K, Zoghbi S, Zea-Ponce Y, Baldwin RM, Fussell B, Smith EO, Charney DS, . Decreased single-photon emission computed tomographic [123I]beta-CIT striatal uptake correlates with symptom severity in Parkinson's disease. *Ann.Neurol.* 1995;**38**:589-98.
21. Benamer HT, Patterson J, Wyper DJ, Hadley DM, Macphee GJ, Grosset DG. Correlation of Parkinson's disease severity and duration with 123I-FP-CIT SPECT striatal uptake. *Mov Disord.* 2000;**15**:692-8.

22. Pirker W. Correlation of dopamine transporter imaging with parkinsonian motor handicap: how close is it? *Mov Disord.* 2003;**18 Suppl 7**:S43-S51.
23. Catafau AM, Tolosa E. Impact of dopamine transporter SPECT using 123I-Ioflupane on diagnosis and management of patients with clinically uncertain Parkinsonian syndromes. *Mov Disord.* 2004;**19**:1175-82.
24. Tolosa E, Borghet TV, Moreno E. Accuracy of DaTSCAN (123I-Ioflupane) SPECT in diagnosis of patients with clinically uncertain parkinsonism: 2-year follow-up of an open-label study. *Mov Disord.* 2007;**22**:2346-51.
25. Varrone A, Pellecchia MT, Amboni M, Sansone V, Salvatore E, Ghezzi D, Garavaglia B, Brice A, Brunetti A, Bonavita V, De MG, Salvatore M, Pappata S, Barone P. Imaging of dopaminergic dysfunction with [123I]FP-CIT SPECT in early-onset parkin disease. *Neurology* 2004;**63**:2097-103.
26. Khan NL, Brooks DJ, Pavese N, Sweeney MG, Wood NW, Lees AJ, Piccini P. Progression of nigrostriatal dysfunction in a parkin kindred: an [18F]dopa PET and clinical study. *Brain* 2002;**125**:2248-56.
27. Pellecchia MT, Varrone A, Annesi G, Amboni M, Cicarelli G, Sansone V, Annesi F, Rocca FE, Vitale C, Pappata S, Quattrone A, Barone P. Parkinsonism and essential tremor in a family with pseudo-dominant inheritance of PARK2: an FP-CIT SPECT study. *Mov Disord.* 2007;**22**:559-63.

28. Khan NL, Valente EM, Bentivoglio AR, Wood NW, Albanese A, Brooks DJ, Piccini P. Clinical and subclinical dopaminergic dysfunction in PARK6-linked parkinsonism: an 18F-dopa PET study. *Ann.Neurol* 2002;**52**:849-53.
29. Kessler KR, Hamscho N, Morales B, Menzel C, Barrero F, Vives F, Gispert S, Auburger G. Dopaminergic function in a family with the PARK6 form of autosomal recessive Parkinson's syndrome. *J.Neural Transm.* 2005;**112**:1345-53.
30. Hedrich K, Djarmati A, Schafer N, Hering R, Wellenbrock C, Weiss PH, Hilker R, Vieregge P, Ozelius LJ, Heutink P, Bonifati V, Schwinger E, Lang AE, Noth J, Bressman SB, Pramstaller PP, Riess O, Klein C. DJ-1 (PARK7) mutations are less frequent than Parkin (PARK2) mutations in early-onset Parkinson disease. *Neurology* 2004;**62**:389-94.
31. Samii A, Markopoulou K, Wszolek ZK, Sossi V, Dobko T, Mak E, Calne DB, Stoessl AJ. PET studies of parkinsonism associated with mutation in the {alpha}-synuclein gene. *Neurology* 1999;**53**:2097.
32. Adams JR, van Netten H, Schulzer M, Mak E, Mckenzie J, Strongosky A, Sossi V, Ruth TJ, Lee CS, Farrer M, Gasser T, Uitti RJ, Calne DB, Wszolek ZK, Stoessl AJ. PET in LRRK2 mutations: comparison to sporadic Parkinson's disease and evidence for presymptomatic compensation. *Brain* 2005;**128**:2777-85.
33. Furtado S, Farrer M, Tsuboi Y, Klimek ML, Fuente-Fernandez R, Hussey J, Lockhart P, Calne DB, Suchowersky O, Stoessl AJ, Wszolek ZK. SCA-2

- presenting as parkinsonism in an Alberta family: Clinical, genetic, and PET findings. *Neurology* 2002;**59**:1625-7.
34. Yen TC, Tzen KY, Chen MC, Chou YH, Chen RS, Chen CJ, Wey SP, Ting G, Lu CS. Dopamine transporter concentration is reduced in asymptomatic Machado-Joseph disease gene carriers. *J.Nucl.Med.* 2002;**43**:153-9.
 35. Jeon BS, Jeong JM, Park SS, Kim JM, Chang YS, Song HC, Kim KM, Yoon KY, Lee MC, Lee SB. Dopamine transporter density measured by [¹²³I]beta-CIT single-photon emission computed tomography is normal in dopa-responsive dystonia. *Ann.Neurol* 1998;**43**:792-800.
 36. Pirker W, Asenbaum S, Bencsits G, Prayer D, Gerschlager W, Deecke L, Brucke T. [¹²³I]beta-CIT SPECT in multiple system atrophy, progressive supranuclear palsy, and corticobasal degeneration. *Mov Disord.* 2000;**15**:1158-67.
 37. Varrone A, Marek KL, Jennings D, Innis RB, Seibyl JP. [(123)I]beta-CIT SPECT imaging demonstrates reduced density of striatal dopamine transporters in Parkinson's disease and multiple system atrophy. *Mov Disord.* 2001;**16**:1023-32.
 38. A multicenter assessment of dopamine transporter imaging with DOPASCAN/SPECT in parkinsonism. Parkinson Study Group. *Neurology* 2000;**55**:1540-7.
 39. Benamer TS, Patterson J, Grosset DG, Booij J, de Bruin K, van Royen E, Speelman JD, Horstink MH, Sips HJ, Dierckx RA, Versijpt J, Decoo D, Van Der LC, Hadley DM, Doder M, Lees AJ, Costa DC, Gacinovic S, Oertel WH, Pogarell

- O, Hoeffken H, Joseph K, Tatsch K, Schwarz J, Ries V. Accurate differentiation of parkinsonism and essential tremor using visual assessment of [123I]-FP-CIT SPECT imaging: the [123I]-FP-CIT study group. *Mov Disord.* 2000;**15**:503-10.
40. Rinne JO, Burn DJ, Mathias CJ, Quinn NP, Marsden CD, Brooks DJ. Positron emission tomography studies on the dopaminergic system and striatal opioid binding in the olivopontocerebellar atrophy variant of multiple system atrophy. *Ann.Neurol.* 1995;**37**:568-73.
41. Eckert T, Barnes A, Dhawan V, Frucht S, Gordon MF, Feigin AS, Eidelberg D. FDG PET in the differential diagnosis of parkinsonian disorders. *NeuroImage* 2005;**26**:912-21.
42. Sawle GV, Brooks DJ, Marsden CD, Frackowiak rsj. corticobasal degeneration: a unique pattern of regional cortical oxygen hypometabolism and striatal fluorodopa uptake demonstrated by positron emission tomography. *Brain* 1991;**114**:541-56.
43. Antonini A, Benti R, De Notaris R, Tesei S, Zecchinelli A, Sacilotto G, Meucci N, Canesi M, Mariani C, Pezzoli G, Gerundini P. 123I-Ioflupane/SPECT binding to striatal dopamine transporter (DAT) uptake in patients with Parkinson's disease, multiple system atrophy, and progressive supranuclear palsy. *Neurol.Sci.* 2003;**24**:149-50.

44. Klaffke S, Kuhn AA, Plotkin M, Amthauer H, Harnack D, Felix R, Kupsch A. Dopamine transporters, D2 receptors, and glucose metabolism in corticobasal degeneration. *Mov Disord.* 2006;**21**:1724-7.
45. Ransmayr G, Seppi K, Donnemiller E, Luginger E, Marksteiner J, Riccabona G, Poewe W, Wenning GK. Striatal dopamine transporter function in dementia with Lewy bodies and Parkinson's disease. *Eur.J.Nucl.Med.* 2001;**28**:1523-8.
46. Piggott MA, Marshall EF, Thomas N, Lloyd S, Court JA, Jaros E, Burn D, Johnson M, Perry RH, McKeith IG, Ballard C, Perry EK. Striatal dopaminergic markers in dementia with Lewy bodies, Alzheimer's and Parkinson's diseases: rostrocaudal distribution. *Brain* 1999;**122**:1449-68.
47. McKeith I, O'Brien J, Walker Z, Tatsch K, Booij J, Darcourt J, Padovani A, Giubbini R, Bonuccelli U, Volterrani D, Holmes C, Kemp P, Tabet N, Meyer I, Reininger C. Sensitivity and specificity of dopamine transporter imaging with 123I-FP-CIT SPECT in dementia with Lewy bodies: a phase III, multicentre study. *Lancet Neurol.* 2007;**6**:305-13.
48. O'Brien JT, Colloby S, Fenwick J, Williams ED, Firbank M, Burn D, Aarsland D, McKeith IG. Dopamine Transporter Loss Visualized With FP-CIT SPECT in the Differential Diagnosis of Dementia With Lewy Bodies. *Arch Neurol* 2004;**61**:919-25.
49. Walker Z, Jaros E, Walker RWH, Lee L, Costa DC, Livingston G, Ince PG, Perry R, McKeith I, Katona CLE. Dementia with Lewy bodies: a comparison of clinical

- diagnosis, FP-CIT single photon emission computed tomography imaging and autopsy. *J Neurol Neurosurg Psychiatry* 2007;**78**:1176-81.
50. McKeith IG, Dickson DW, Lowe J, Emre M, O'Brien JT, Feldman H, Cummings J, Duda JE, Lippa C, Perry EK, Aarsland D, Arai H, Ballard CG, Boeve B, Burn DJ, Costa D, Del Ser T, Dubois B, Galasko D, Gauthier S, Goetz CG, Gomez-Tortosa E, Halliday G, Hansen LA, Hardy J, Iwatsubo T, Kalaria RN, Kaufer D, Kenny RA, Korczyn A, Kosaka K, Lee VMY, Lees A, Litvan I, Londos E, Lopez OL, Minoshima S, Mizuno Y, Molina JA, Mukaetova-Ladinska EB, Pasquier F, Perry RH, Schulz JB, Trojanowski JQ, Yamada M, for the Consortium on DLB. Diagnosis and management of dementia with Lewy bodies: Third report of the DLB consortium. *Neurology* 2005;**65**:1863-72.
51. Zijlmans JC, Daniel SE, Hughes AJ, Revesz T, Lees AJ. Clinicopathological investigation of vascular parkinsonism, including clinical criteria for diagnosis. *Mov Disord.* 2004;**19**:630-40.
52. Lorberboym M, Djaldetti R, Melamed E, Sadeh M, Lampl Y. 123I-FP-CIT SPECT Imaging of Dopamine Transporters in Patients with Cerebrovascular Disease and Clinical Diagnosis of Vascular Parkinsonism. *J Nucl Med* 2004;**45**:1688-93.
53. Zijlmans JCM, Katzenschlager R, Daniel SE, Lees AJL. The L-dopa response in vascular parkinsonism. *J Neurol Neurosurg Psychiatry* 2004;**75**:545-7.

54. Zijlmans J, Evans A, Fontes F, Katzenschlager R, Gacinovic S, Lees AJ, Costa D. [(123I)] FP-CIT spect study in vascular parkinsonism and Parkinson's disease. *Mov Disord.* 2007;**22**:1278-85.
55. Gerschlager W, Bencsits G, Pirker W, Bloem BR, Asenbaum S, Prayer D, Zijlmans JC, Hoffmann M, Brucke T. [123I]beta-CIT SPECT distinguishes vascular parkinsonism from Parkinson's disease. *Mov Disord.* 2002;**17**:518-23.
56. Tzen KY, Lu CS, Yen TC, Wey SP, Ting G. Differential diagnosis of Parkinson's disease and vascular parkinsonism by (99m)Tc-TRODAT-1. *J.Nucl.Med.* 2001;**42**:408-13.
57. Tolosa E, Coelho M, Gallardo M. DAT imaging in drug-induced and psychogenic parkinsonism. *Mov Disord.* 2003;**18 Suppl 7**:S28-S33.
58. Farde L, Wiesel FA, Halldin C, Sedvall G. Central D2-dopamine receptor occupancy in schizophrenic patients treated with antipsychotic drugs. *Arch.Gen.Psychiatry* 1988;**45**:71-6.
59. Rajput AH, Rozdilsky B, Hornykiewicz O, Shannak K, Lee T, Seeman P. Reversible drug-induced parkinsonism. Clinicopathologic study of two cases. *Arch.Neurol.* 1982;**39**:644-6.
60. Valchar M, Hanbauer I. Comparison of [3H]WIN 35,428 binding, a marker for dopamine transporter, in embryonic mesencephalic neuronal cultures with striatal membranes of adult rats. *J.Neurochem.* 1993;**60**:469-76.

61. Reader TA, Ase AR, Huang N, Hebert C, van Gelder NM. Neuroleptics and dopamine transporters. *Neurochem.Res.* 1998;**23**:73-80.
62. Lavalaye J, Linszen DH, Booij J, Dingemans PM, Reneman L, Habraken JB, Gersons BP, van Royen EA. Dopamine transporter density in young patients with schizophrenia assessed with [123I]FP-CIT SPECT. *Schizophr.Res.* 2001;**47**:59-67.
63. Booij J, Speelman JD, Horstink MW, Wolters EC. The clinical benefit of imaging striatal dopamine transporters with [123I]FP-CIT SPET in differentiating patients with presynaptic parkinsonism from those with other forms of parkinsonism. *Eur.J.Nucl.Med.* 2001;**28**:266-72.
64. Hinson VK, Cubo E, Comella CL, Goetz CG, Leurgans S. Rating scale for psychogenic movement disorders: scale development and clinimetric testing. *Mov Disord.* 2005;**20**:1592-7.
65. Factor SA, Podskalny GD, Molho ES. Psychogenic movement disorders: frequency, clinical profile, and characteristics. *J.Neurol.Neurosurg.Psychiatry* 1995;**59**:406-12.
66. Lang AE, Koller WC, Fahn S. Psychogenic parkinsonism. *Arch.Neurol.* 1995;**52**:802-10.
67. Fahn S, Williams DT. Psychogenic dystonia. *Adv.Neurol.* 1988;**50**:431-55.

68. Gaig C, Marti MJ, Tolosa E, Valldeoriola F, Paredes P, Lomena FJ, Nakamae F. 123I-Ioflupane SPECT in the diagnosis of suspected psychogenic Parkinsonism. *Mov Disord.* 2006;**21**:1994-8.
69. Factor S, Seibyl JP, Innis R, Marek K. Psychogenic parkinsonism: confirmation of diagnosis with ^{123}I CIT SPECT scans. *Mov Disord.* 1998;**13**:860.
70. Lou JS, Jankovic J. Essential tremor: clinical correlates in 350 patients. *Neurology* 1991;**41**:234-8.
71. Bain PG, Findley LJ, Thompson PD, Gresty MA, Rothwell JC, Harding AE, Marsden CD. A study of hereditary essential tremor. *Brain* 1994;**117**:805-24.
72. Chaudhuri KR, Buxton-Thomas M, Dhawan V, Peng R, Meilak C, Brooks DJ. Long duration asymmetrical postural tremor is likely to predict development of Parkinson's disease and not essential tremor: clinical follow up study of 13 cases. *J Neurol Neurosurg Psychiatry* 2005;**76**:115-7.
73. Schrag A, Munchau A, Bhatia KP, Quinn NP, Marsden CD. Essential tremor: an overdiagnosed condition? *J Neurol.* 2000;**247**:955-9.
74. Asenbaum S, Pirker W, Angelberger P, Bencsits G, Pruckmayer M, Brucke T. [^{123}I]beta-CIT and SPECT in essential tremor and Parkinson's disease. *J. Neural Transm.* 1998;**105**:1213-28.

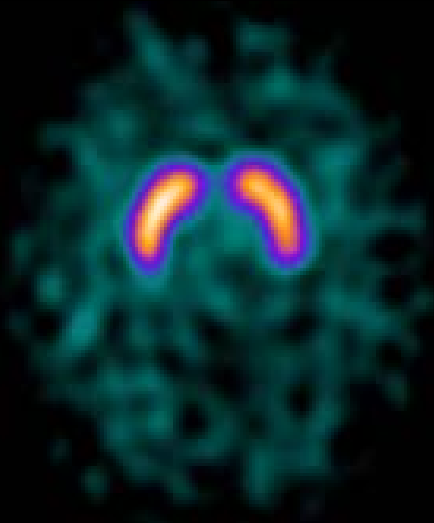
75. Gerschlagel W, Munchau A, Katzenschlager R, Brown P, Rothwell JC, Quinn N, Lees AJ, Bhatia KP. Natural history and syndromic associations of orthostatic tremor: a review of 41 patients. *Mov Disord.* 2004;**19**:788-95.
76. Katzenschlager R, Costa D, Gerschlagel W, O'Sullivan J, Zijlmans J, Gacinovic S, Pirker W, Wills A, Bhatia K, Lees AJ, Brown P. [123I]-FP-CIT-SPECT demonstrates dopaminergic deficit in orthostatic tremor. *Ann.Neurol.* 2003;**53**:489-96.
77. Marshall V, Grosset DG. Role of dopamine transporter imaging in the diagnosis of atypical tremor disorders. *Mov Disord.* 2003;**18 Suppl 7**:S22-S27.
78. Barthel H, Hermann W, Kluge R, Hesse S, Collingridge DR, Wagner A, Sabri O. Concordant Pre- and Postsynaptic Deficits of Dopaminergic Neurotransmission in Neurologic Wilson Disease. *AJNR Am J Neuroradiol* 2003;**24**:234-8.
79. Ceravolo R, Antonini A, Volterrani D, Rossi C, Goldwurm S, Di Maria E, Kiferle L, Bonuccelli U, Murri L. Dopamine transporter imaging study in parkinsonism occurring in fragile X premutation carriers. *Neurology* 2005;**65**:1971-3.
80. Scaglione C, Ginestroni A, Vella A, Dotti MT, Nave RD, Rizzo G, De Cristofaro MT, De Stefano N, Piacentini S, Martinelli P, Mascalchi M. MRI and SPECT of midbrain and striatal degeneration in fragile X-associated tremor/ataxia syndrome. *J.Neurol.* 2008;**255**:144-6.

Legend to Figure 2

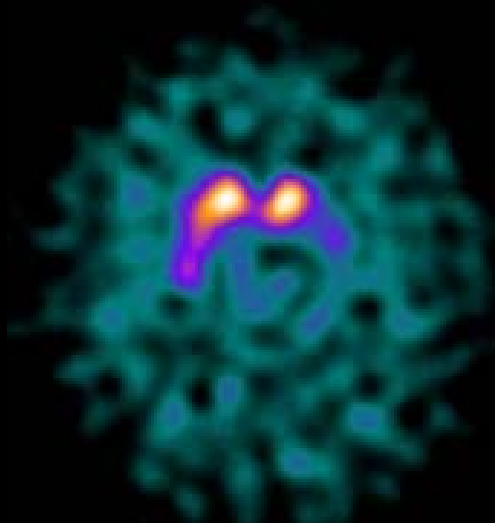
Striatal dopamine transporter binding. ET: essential tremor; DT: dystonic tremor; PD Parkinson's disease; DIP: drug induced parkinsonism; PsyP: psychogenic parkinsonism; PSP: progressive supranuclear palsy; MSA-P: multiple system atrophy-parkinsonism; OT: orthostatic tremor; DLB: dementia with Lewy bodies; VP: vascular parkinsonism; CBD: corticobasal degeneration;; MSA-C: multiple system atrophy- cerebellar

Legend to figure 1

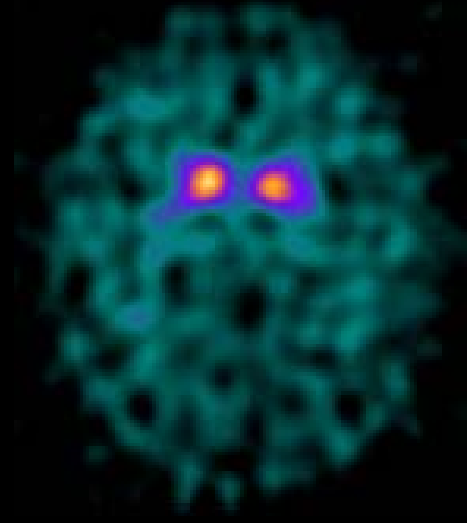
Single -photon emission 123I-FP-CIT from a healthy subject (A), a patient with hemi-Parkinson disease. Only 10% of patients presenting with unilateral parkinsonism have have a unilateral abnormality on imaging. (B) and from a Parkinson patient with bilateral symptoms (C).



Healthy
subject



Unilateral PD
(Left putamen)



Bilateral PD
(left and right putamen)

Figure 2.

